

iREVIEWS

STATE-OF-THE-ART PAPERS

Myocardial Perfusion Imaging With Contrast Ultrasound

Thomas R. Porter, MD, Feng Xie, MD

Omaha, Nebraska

This report reviews the development and clinical application of myocardial perfusion imaging with myocardial contrast echocardiography (MCE). This includes the development of microbubble formulations that permit the detection of left ventricular contrast from venous injection and the imaging techniques that have been invented to detect the transit of these microbubbles through the microcirculation. The methods used to quantify myocardial perfusion during a continuous infusion of microbubbles are described. A review of the clinical studies that have examined the clinical utility of myocardial perfusion imaging with MCE during rest and stress echocardiography is then presented. The limitations of MCE are also discussed. (J Am Coll Cardiol Img 2010;3: 176–87) © 2010 by the American College of Cardiology Foundation

A series of inventions and scientific breakthroughs are responsible for the development of myocardial perfusion imaging with myocardial contrast echocardiography (MCE). First, there was the invention of stable microbubble shells using either electromechanical sonication of albumin or lipid emulsions (1,2). Second there was the stabilization of these microbubbles following venous injection by the incorporation of a high molecular weight insoluble gas within the shell, which permitted consistent left ventricular opacification following venous injection (3). Then, it was discovered that the typical ultrasound imaging techniques at a high mechanical index (MI) were destroying these microbubbles as they transited through the myocardial microcirculation. By either triggering ultrasound to one frame every cardiac cycle or by utilizing a very low mechanical index and harmonic imaging, myocardial contrast enhancement from a venous injection of microbubbles

was consistently visualized (4). With harmonic triggered imaging, myocardial perfusion abnormalities were visualized in humans using very small intravenous bolus injections of perfluorocarbon containing microbubbles (5). Finally, a team of investigators headed by Kevin Wei and Sanjiv Kaul at the University of Virginia made the landmark discovery that these ultrasound triggering techniques could be utilized to quantify myocardial blood flow, and even examine the components responsible for myocardial blood flow (6). This has led to clinical studies demonstrating how MCE can provide important bedside information on myocardial blood flow during stress echocardiography laboratory (7–10), in the acute and chronic assessment of myocardial viability (11–14), and in the emergency department (15). This paper will review the technical aspects of myocardial perfusion imaging with MCE, and how it has been utilized to detect coronary artery disease and guide management.

From the University of Nebraska Medical Center, Omaha, Nebraska. Dr. Porter has received modest grant support from Lantheus Medical Imaging and Astellas Pharma Inc., significant grant support from NuVox Pharma Inc., and other grant support (i.e., equipment, drugs, and software) from Siemens Medical Imaging, and has served as a consultant or received honorarium from Lantheus Medical Imaging and Point BioMed. Sanjiv Kaul, MD, served as Guest Editor for this paper.

Manuscript received May 29, 2009; revised manuscript received August 6, 2009, accepted September 17, 2009.

Perfusion Imaging Techniques With Myocardial Contrast Echocardiography

Microbubbles in an ultrasonic field are strong scatterers, sending compression and rarefaction waves back to the scanner. At peak negative pressures above 0.1 MPa, the microbubbles respond in a nonlinear manner. In general, what nonlinear behavior means is that the magnitude of compression and rarefaction waves are not the same with each oscillation. At these low incident pressures, the microbubbles exhibit both linear and nonlinear returning waves, whereas the myocardium and other structures primarily exhibit linear responses (16). The nonlinear responses occur in both the fundamental and harmonic frequencies and can be received and filtered by the echocardiographic system. Ultrasound imaging software that selectively receives the nonlinear responses produces a much better signal-to-noise ratio and more sensitive detection of microbubbles than what would be received from conventional imaging software (17).

Microbubbles are destroyed by real-time ultrasound when it is transmitted at higher intensities (MIs >0.3). Destruction can be reduced by decreasing the frame rate to 1 out of every 1 to several cardiac cycles, usually with triggering the frame to the electrocardiogram. This has been referred to as intermittent imaging, and has been used with both harmonic and power Doppler systems (18–21). When the intermittent ultrasound impulse is at a high intensity (>0.9 MI), there is a strong and brief nonlinear echo from the bubble. Interrupting the high-intensity ultrasound for a short period of time allows for replacement of microbubbles, which serve to produce contrast enhancement for the subsequent triggered frame. When microbubbles are administered as a continuous infusion and the ultrasound pulsing interval is incrementally varied, the reappearance of bubbles in the myocardium permits the calculation of mean microbubble velocity and plateau (or peak) myocardial signal intensity (5). Multiplying these 2 variables together, one can quantify myocardial blood flow changes. With these intermittent imaging techniques, it has become possible to noninvasively examine myocardial perfusion in animals and humans using a wide variety of intravenous higher molecular weight microbubbles (22,23). Significant achievements have been made in low MI real-time visualization of myocardial function. Pulse inversion Doppler is a multipulse technique that separates linear and nonlinear scattering using the radiofrequency domain.

When used at a very low MI, linear scatterers like myocytes and tissue will have their signals canceled, whereas nonlinear scatterers (like microbubbles) will produce summated signals (24). Pulse inversion Doppler overcomes motion artifacts by sending multiple pulses of alternating polarity into the myocardium. This allows one to visualize wall thickening and contrast enhancement simultaneously at very low MIs (<0.2) while maintaining an excellent signal-to-noise ratio. Because it can receive only even order harmonics, however, there is significant attenuation, especially in basal myocardial segments in apical windows.

Power modulation is another technique that improves the signal-to-noise ratio at very low mechanical indices. This technique, developed by Philips (Andover, Massachusetts), is also a multipulse cancellation technique; however, with power modulation, the power of each pulse is varied. Contrast pulse sequencing (Siemens Acuson Sequoia; Mountain View, California) extends these multipulse techniques by interpulse phase and amplitude modulation (25). Both power modulation and contrast pulse sequencing can be used at a very low MI to assess myocardial contrast in real time with excellent spatial resolution at higher bandwidths (Fig. 1). In these examples, note that background signals from the myocardium are virtually absent.

Qualitative and quantitative methods of myocardial perfusion analysis. Regardless of the route of microbubble injection, an accurate definition of microbubble concentration in the myocardium requires that the relationship between concentration and signal intensity be linear. This precondition is fulfilled at low intramyocardial microbubble concentrations. At a certain microbubble concentration, however, echocardiographic systems normally reach a saturation point, where videointensity is no longer proportional to the microbubble concentration (26). This becomes a factor with bolus injections of microbubbles, in which transient high concentrations can be reached even in regions with reduced myocardial blood flow, leading to a brief period during which contrast enhancement falsely appears normal in these regions. It is not until microbubble concentration falls during the washout period that differences in microbubble concentration are visually evident. It is during this time period that there is a linear relationship between concentration and signal intensity. With bolus intravenous injections

ABBREVIATIONS AND ACRONYMS

CAD = coronary artery disease

LBBB = left bundle branch block

MCE = myocardial contrast
echocardiography

MI = mechanical index

PET = positron emission
tomography

SPECT = single-photon emission
computed tomography

RT = real-time perfusion

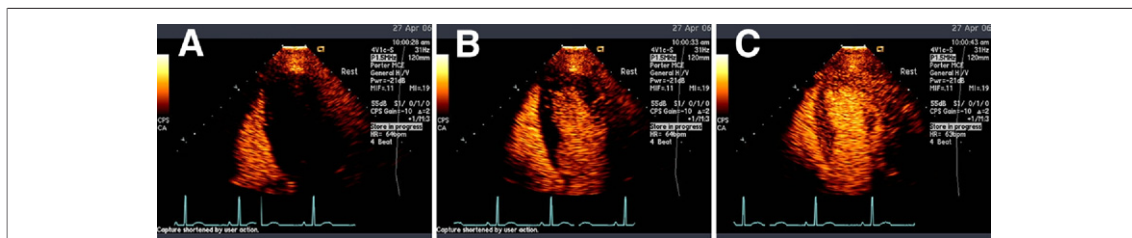


Figure 1. An Example of the Excellent Background Subtraction

The images are achieved with low-mechanical index pulse sequence schemes designed to assess myocardial perfusion. In this apical 4-chamber view, note that there are virtually no signals from the myocardium before contrast administration (A), but excellent left ventricular cavity opacification (B) and eventual myocardial contrast (C) after venous infusion of ultrasound contrast. The attenuation in the basal segments is most likely due to a high initial concentration of microbubbles in the left ventricular cavity.

of microbubbles, the myocardial contrast intensity during this washout period is a reflection of myocardial blood volume. Estimates of myocardial blood flow cannot be ascertained from bolus injections, because mean transit times cannot be obtained from time intensity curves due to dispersion of the bolus by intrapulmonary filtering.

The difficulties arising with thresholding effect and saturation point of echocardiography systems can partly be avoided by using a continuous peripheral venous infusion for microbubbles instead of a bolus injection. This method assumes that the input of microbubbles into the myocardium is constant. The practical advantage of a continuous infusion is that attenuation artifacts due to high contrast intensity in the left ventricular cavity can be reduced (27–29). Moreover, the contrast dosage administered can easily be adjusted on the basis of what is seen during imaging (29).

The ultrasound beam destroys these microbubbles when a high MI is used, so that insonation at high MIs results in almost complete bubble destruction with every pulse. Triggering ultrasound to 1 frame timed to end systole in the cardiac cycle at a sequence of incrementally longer cardiac cycles allows a replenishment of contrast agent corresponding to flow to the given region during that time sequence. The longer the triggering intervals are set, the more microbubbles replenish the capillaries and the higher the signal intensity to be registered in the tissue, until finally a plateau phase is reached. Alternatively, if one is imaging at a low MI in real time, brief high-MI impulses can be applied to the imaging plane, after which replenishment can be visualized in real time at the low MI (Fig. 2). Regardless of the technique, the plateau background-subtracted myocardial contrast intensity of a respective myocardial region is related to the capillary cross-sectional area. The initial slope at which this plateau stage is achieved is proportional to the blood flow velocity in that region. The slope times

peak or plateau myocardial videointensity, therefore, represents a measure of myocardial blood flow (6).

Factors such as attenuation, underlying tissue signals, incomplete microbubble destruction with high MI impulses, and difficulties with software quantification techniques have prevented the widespread use of quantification during myocardial contrast echocardiography (MCE). Models have been proposed and validated that correct for attenuation in the plateau myocardial signal intensity by dividing it by the adjacent left ventricular cavity intensity. These normalized plateau intensities, when multiplied by the rate of contrast replenishment and divided by tissue density, can be used to compute myocardial blood flow (30). Continuous infusion techniques can be done with infusion pumps or hand-held infusions. With either of the commercially available contrast agents, one can mix them at the bedside with saline and infuse them either as a continuous drip or as a hand-held infusion.

Clinical Application of Ultrasonographic Contrast for Perfusion Imaging

With Vasodilator Stress Perfusion Imaging

Detection of coronary artery disease. Radionuclide scintigraphy is still considered by the majority of cardiologists as the diagnostic tool to assess myocardial perfusion during stress testing. This method, when performed with technetium-99m (99mTc) or 201Tl, has been reported to detect coronary artery disease (CAD) with high sensitivity during exercise or vasodilator stress imaging. Despite its widespread use, however, both radionuclide single-photon emission computed tomography (SPECT) and positron emission tomography (PET) are limited by poor spatial resolution. SPECT is also limited by frequent attenuation artifacts. With intravenous perfluorocarbon contrast agents and nonlinear ultrasonographic imag-

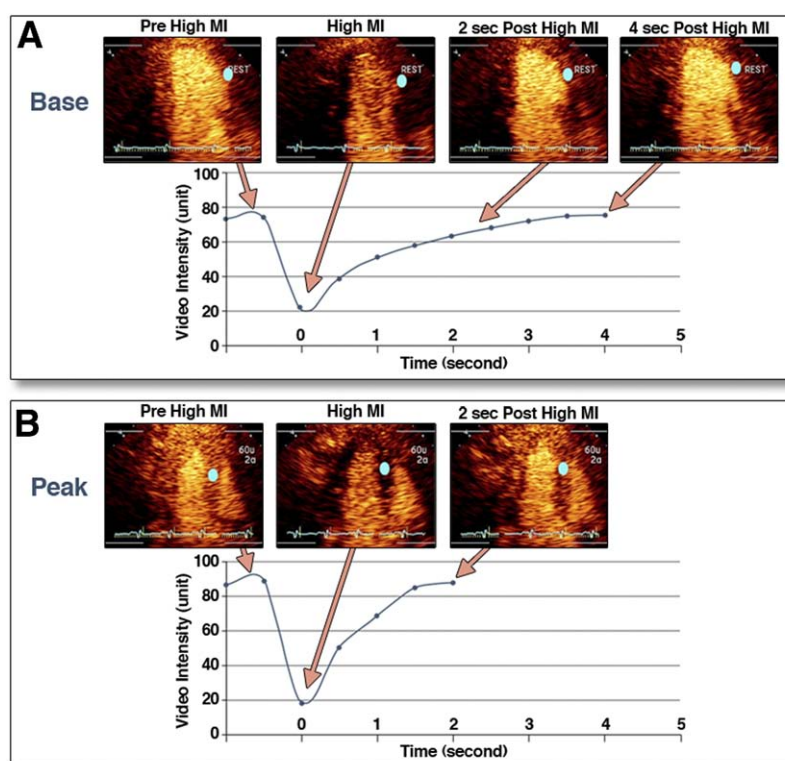


Figure 2. An Example of Normal Myocardial Replenishment (Apical 3-Chamber)

With real-time perfusion image, the myocardial replenishment is after a high-mechanical index (MI) impulse. Note under resting conditions (A) that normal replenishment occurs within 4 s of the high MI impulse, whereas during stress (vasodilator, dobutamine, exercise), replenishment normally occurs within 2 s (B).

ing techniques, detection of underperfused myocardial segments during stress echocardiography has become a feasible alternative. Initial studies deployed intermittent harmonic or power Doppler imaging techniques to detect coronary stenoses during vasodilator stress. Using intravenous Optison and intermittent high MI harmonic imaging, Kaul et al. (7) described a 92% concordance between segmental perfusion scores by MCE and ^{99m}Tc -sestamibi SPECT at rest and during dipyridamole stress. Heinle et al. (9) used an intravenous Optison infusion and harmonic power Doppler imaging at long pulsing intervals during adenosine stress testing to compare perfusion with ^{99m}Tc -sestamibi SPECT in 123 patients with suspected CAD. There was an overall concordance between both techniques of 83%; concordance was higher in patients with no or multivessel CAD.

Real-time perfusion and other lower MI imaging techniques have been applied to vasodilator stress as well (Table 1) (10,31–43). Recently, the first multicenter studies compared MCE (triggered replenishment imaging) with radionuclide SPECT. These demonstrated a similar sensitivity and specificity be-

tween the 2 techniques, regardless of stenosis severity (31). Quantitative measurements of myocardial blood flow reserve have yielded sensitivities and specificities for the detection of CAD that exceeded both visual and quantitative assessments of dipyridamole stress with radionuclide SPECT (32). The better spatial resolution of MCE has been shown to improve the detection of subendocardial perfusion defects that would otherwise go undetected with lower-resolution SPECT imaging. An example of this is shown in Figure 3, where an anteroapical and apical perfusion defect during adenosine stress is evident during the replenishment phase of contrast with real-time MCE. The corresponding radionuclide image appeared normal, despite the presence of a significant left anterior descending lesion at quantitative angiography (33). In the majority of these studies, the analysis of perfusion with MCE was performed independent of wall motion analysis. As might be expected with vasodilator stress, myocardial perfusion analysis consistently has had higher sensitivity for detecting CAD than wall motion analysis. Proposed protocols for perfusion imaging with either dipyridamole or adenosine stress

Table 1. Vasodilator Myocardial Perfusion Stress Imaging Studies Performed With Intravenous Ultrasound Contrast During Stress Echocardiography in the Last 5 Years

Author (Ref #)	Year	Test	N	Sensitivity	Specificity	Accuracy	Bolus or CI	Mode	Gold Standard
Peltier (32)	2004	Dipy	35	—	—	97% for stenosis 82% for normal	—	Low MI	Angio
Janardhanan (10)	2004	Dipy	73	73%	86%	—	CI		Angio
Yu (35)	2004	Dipy	46	—	—	83%		TRI	SPECT
Moir (36)	2004	Dipy+EX	70	91%	70%	—	CI	RT	Angio
Tsutsui (37)	2005	Dipy or Adeno	36	—	—	TRI 81% RT 85%	Bolus	TRI and RT	SPECT
Jeetley (38)	2006	Dipy	123	80%	63%	—	CI	TRI	Angio
Korosoglou (39)	2006	Dipy or Adeno	89	83%	72%	—	CI	RT	Angio
Malm (40)	2006	Adeno	43	77%	69%	73%	CI	RT	Angio
Xie (33)	2007	Adeno	40	73%	90%	84%	CI	RT	Angio
Wasmeier (41)	2008	Adeno	24	67%	67%	—	Bolus	RT	Angio
Lipiec (42)	2008	Dipy	103	67%	86%	70%	Bolus	RT	Angio
Mor-Avi (43)	2008	Adeno	48	71%	94%	90%	CI	RT	Angio
Hayat (34)	2008	Dipy	63	92%	95%	—	CI	RT	Angio
Senior (31)	2009	Dipy	285*	61%	74%	68%	CI	RT	Angio
			377*	71%	64%	69%	CI	RT	Angio
Pooled (average sensitivity, specificity, and accuracy)			1,455	76%	78%	78%			

*RAMP 1 and RAMP 2.
Adeno = adenosine; Angio = angiography; CI = continuous infusion; Dipy = dipyridamole; EX = exercise; MI = mechanical index; RT = real time; SPECT = single-photon emission computed tomography; TRI = triggered.

are displayed in Figure 4. Note that due to the beam width elevation and capillary blood flow, normal myocardial blood flow under resting conditions should be within 5 s of a high-MI impulse, whereas during vasodilator or exercise stress replenishment, it should be within 2 s (Fig. 2).

During Dobutamine Stress Echocardiography

Animal studies have shown that perfusion defects appear before wall-thickening abnormalities during dobutamine infusion and better delineate the area at risk (44). Clinical MCE studies comparing myocardial perfusion with wall motion during dobutamine stress have confirmed this better sensitivity (Table 2) (44–52). In predominately single-center studies, real-

time perfusion echocardiography has been shown to increase the sensitivity of the dobutamine stress test when compared with wall motion analysis (44–46,53) and improve the ability of the test to predict death or nonfatal myocardial infarction (4). Dolan et al. (54) recently published multicenter data confirming the prognostic value of perfusion imaging during dobutamine stress echocardiography. In their study, an inducible perfusion defect, even in the absence of a wall motion abnormality, was an independent predictor of risk for subsequent death or nonfatal myocardial infarction (54).

Newer clinical studies have suggested that real-time perfusion imaging may assist in the detection of subendocardial ischemia during dobutamine stress. In

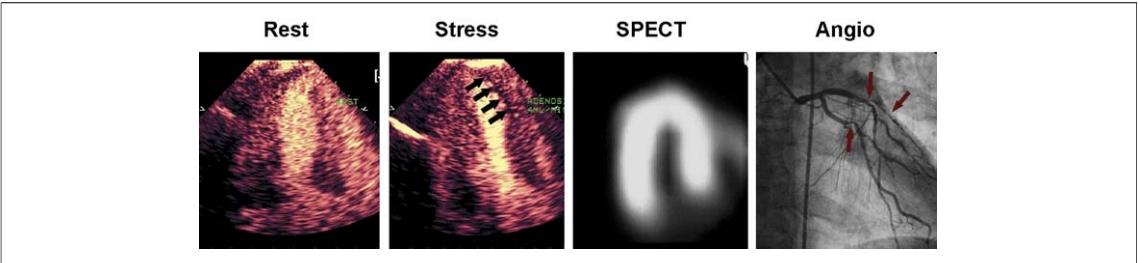
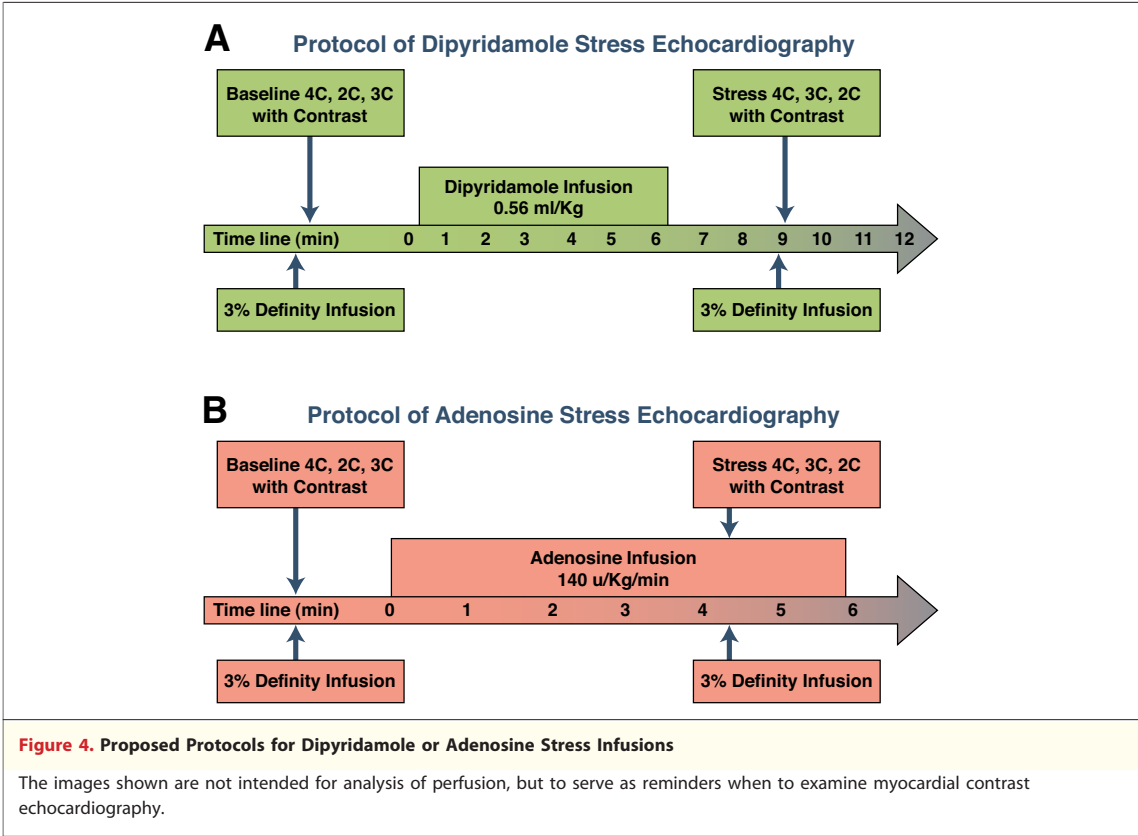


Figure 3. An Example of a Subendocardial Perfusion Defect

The defect is evident in the anteroapical and apical segments of the left ventricle during the replenishment phase of contrast after a high-mechanical index impulse during adenosine stress imaging. Note that because the defect was confined to the subendocardium (black arrows), there was no evident defect noted on the lower-resolution radionuclide single-photon emission computed tomography (SPECT) image despite the presence of significant coronary artery disease at angiography (Angio) (red arrows). Reprinted, with permission, from Xie et al. (33).



patients with significant left anterior descending CAD, subendocardial wall-thickening abnormalities were detected in 35 of 45 patients with subendocardial perfusion defects despite the presence of normal transmural wall thickening (55). Because dobutamine will recruit the subepicardial layers to contract, these wall-thickening abnormalities would have gone undetected if contrast were only used to enhance endocardial borders. An example of this is demonstrated in Figure 5, where the presence of a subendocardial perfusion defect in the apex and apical

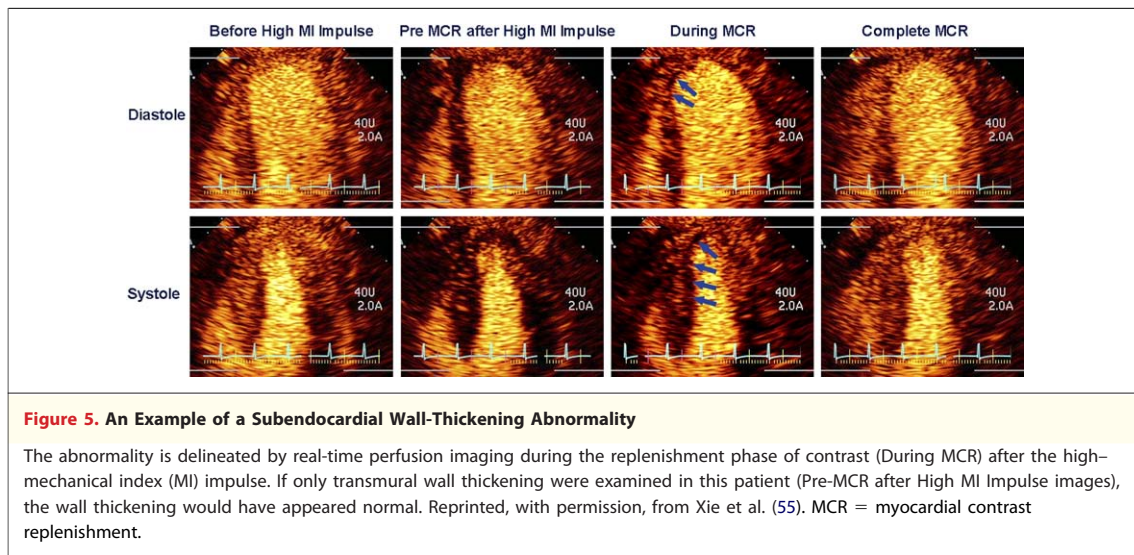
lateral segments permitted the detection of a wall-thickening abnormality when transmural wall thickening appeared normal.

Real-time MCE during exercise stress echocardiography. There are greater challenges when attempting to use real-time perfusion imaging during treadmill or bicycle exercise stress echocardiography. These include increased frequency of respiratory artifacts and the brief period of time when a patient can be examined at peak stress. Nonetheless, multicenter studies using treadmill and supine bicycle stress have

Table 2. Dobutamine or Exercise Myocardial Perfusion Stress Imaging Studies Performed With Intravenous Ultrasound Contrast During the Last 5 Years

Author (Ref #)	Year	Test	N	Sensitivity	Specificity	Accuracy	Bolus or CI	Mode	Gold Standard
Porter (45)	2001	Dob	40	—	—	83%	Bolus	RT	Angio
Shimoni (47)	2001	EX	100	—	—	76%	Bolus	RT	SPECT
Olzowska (49)	2003	Dob	44	97%	93%	—	Bolus	RT	Angio
Tsutsui (46)	2005	Dob		—	—	84%	Bolus	RT	Angio
Elhendy (50)	2005	Dob	128	89%	53%	81%	Bolus	RT	Angio
Xie (51)	2005	Dob	27	66%	50%	65%	Bolus	RT	Angio
Miszalski-Jamka (48)	2007	EX	42	88%	88%	—	CI	RT	Angio
Hacker (52)	2008	Dob	32	86%	91%	—	CI	RT	Angio
Lønnebakken (44)	2009	Dob	37	70%	87%	—	CI	RT	Angio
Pooled (average sensitivity, specificity, and accuracy)			526	83%	77%	78%			

Dob = dobutamine; other abbreviations as in Table 1.



demonstrated the incremental value of myocardial perfusion assessment using low-MI imaging during exercise testing (47). Indeed, recent data have suggested that real-time perfusion imaging, by delineating subendocardial wall-thickening abnormalities, may further improve the sensitivity of wall motion analysis during treadmill exercise stress (56). Supine bicycle exercise studies during a continuous infusion of ultrasound contrast have shown that replenishment delays in contrast enhancement after high-MI impulses have 88% sensitivity and accuracy for the detection of significant CAD (48). An example of a treadmill exercise-induced perfusion defect is delineated in Figure 6. Figure 7 illustrates proposed protocols for real-time perfusion imaging during dobutamine or exercise stress.

Assessment of myocardial viability in the acute and chronic setting. MCE has proven useful in evaluating patients after interventional or thrombolytic treatment in acute myocardial infarction. Identification of pa-

tients with the “no-reflow” phenomenon has proven to be an important clinical application for MCE (57–59). This phenomenon, described first in an animal setting by Kloner et al. in 1974 (57), is characterized by a lack of recovery in microvascular perfusion, although the occluded coronary artery is successfully reopened by percutaneous intervention or thrombolysis. Ito et al. (58) were the first to systematically examine myocardial microvascular perfusion with intracoronary microbubbles in patients with acute anteroseptal myocardial infarction immediately after restoration of antegrade flow in the left anterior descending artery. Several investigators have succeeded in detecting the no-reflow phenomenon from intravenous administration of microbubbles (Table 3) (13,60–68). In patients undergoing primary coronary stenting, homogenous myocardial contrast enhancement within the infarct zone by continuous-infusion intravenous MCE has been shown to be highly predictive of regional recovery of function (10). Res-

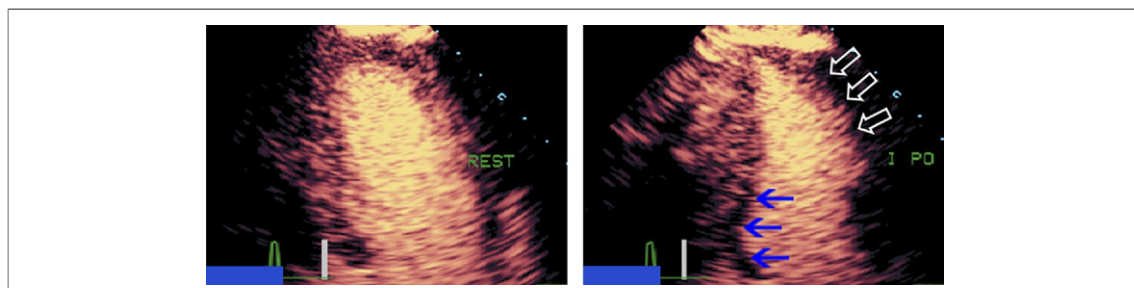
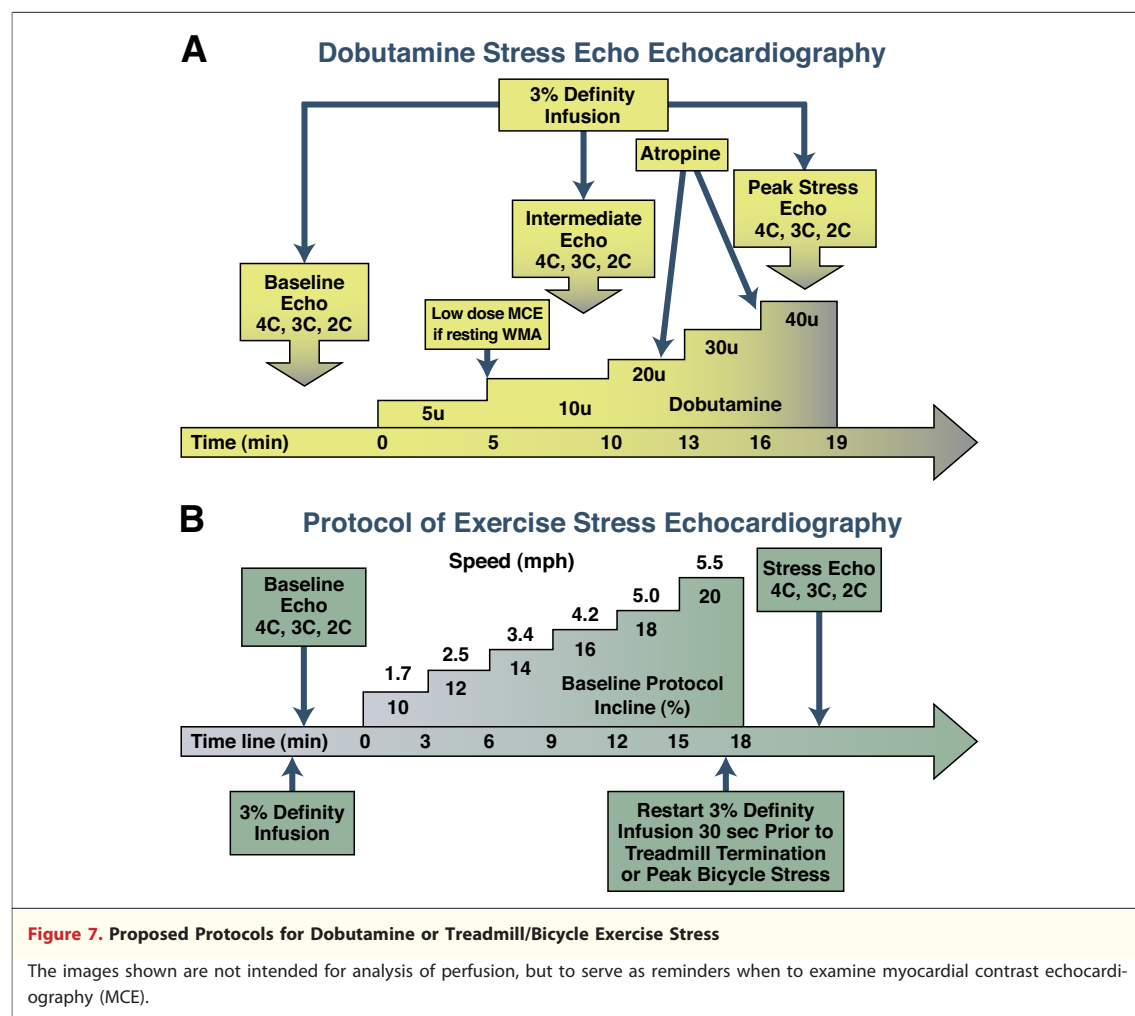


Figure 6. An Example of an Inferior Wall Perfusion Defect

The defect was confined to the subendocardium after treadmill exercise stress, where a subendocardial wall-thickening abnormality was also observed (blue arrows). Note also the end-systolic shape change that accompanies the perfusion defect. The open arrows indicate an area of rib shadowing that prevented delineation of perfusion in the basal to mid-anterior segments. A foreshortened apical 2-chamber view can be used to delineate perfusion in these segments.



toration of microvascular perfusion was most likely to occur if patients demonstrated at least partial perfusion to the risk area before primary stenting. MCE performed during dipyridamole infusion 1 week after

acute myocardial infarction in patients receiving primary fibrinolytic therapy has been shown to be useful in detecting both a significant residual stenosis within the infarct vessel and predicting when multivessel

Table 3. Viability Studies Examining the Predictive Value of MCE Examined Within 7 Days of Acute Myocardial Infarction in Predicting Outcome (Both Recovery of Regional Function and Clinical Outcome)

Author (Ref #)	N	FU (months)	Sensitivity	Specificity	Outcome
Swinburn (13)	96	3–6	59%	76%	RF
Main (60)	34	2	77%	83%	RF
Hillis (61)	37	2	80%	67%	RF
Janardhanan (62)	50	3	87%	78%	RF
Korosoglou (63)	32	1	81%	88%	RF
Huang (64)	34	4	83%	82%	RF
Sbano (65)	50	6	95%	52%	RF
Abe (66)	21	6	98%	32%	RF
Dwivedi (67)	95	46	80%	76%	CO
Galiuto (68)	110	6	70%	74%	RF

CO = clinical outcome (death or nonfatal myocardial infarction); FU = follow-up; RF = regional function.

coronary disease is present (67). The extent and severity of myocardial contrast defect size, determined with real-time perfusion, has been shown to be an independent predictor of both death and recurrent myocardial infarction at a mean of nearly 4 years post-infarction (11). Multicenter studies have recently demonstrated that the extent of microvascular damage, assessed on day 1 after reperfusion therapy in acute myocardial infarction, is the most powerful independent predictor of whether left ventricular remodeling will occur (68).

In patients with chronic CAD and left ventricular dysfunction, both the visual and quantitative assessment of MCE during a continuous infusion of intravenous microbubbles has provided significant independent data on the effects of revascularization to that segment. In this setting, the product of the slope of myocardial replenishment and plateau myocardial contrast intensity (an index of myocardial blood flow) in dysfunctional segments correlated with contractile reserve by low-dose dobutamine, as well as >60% thallium uptake with radionuclide SPECT. More importantly, this index of myocardial blood flow by MCE was able to identify viable myocardium in segments that did not exhibit contractile reserve by dobutamine stress (69,70). However, these studies were small ($n = 20$ patients) and have yet to be verified in multicenter studies.

Real-time MCE to detect CAD in clinical scenarios where radionuclide imaging and wall motion are limited. Patients with left bundle branch block (LBBB) or pacemaker-dependent patients represent clinical scenarios where both the assessment of wall thickening and conventional myocardial perfusion imaging with radionuclide SPECT are not helpful in the detection of CAD (47). In these patients, there are difficulties with interpretation of wall thickening in the septum (in LBBB) or, in pacemaker-dependent patients, in the septum and entire apex. In LBBB patients, perfusion defects in the interventricular septum are seen on radionuclide SPECT despite normal myocardial blood flow with real-time perfusion and no significant CAD by angiography (Fig. 8). The reason for this appears to be the partial volume effect, as the false-positive perfusion defects seen with radionuclide SPECT had a normal perfusion appearance with higher-resolution real-time MCE and were independently associated with smaller septal systolic wall-thickness measurements (34). Similar wall-thickness abnormalities encompassing a larger territory (the septum and apex) are seen in pacemaker-dependent patients. Although real-time MCE may be useful for ruling in or ruling out significant CAD in these patients, it has yet to be determined in published clinical studies.

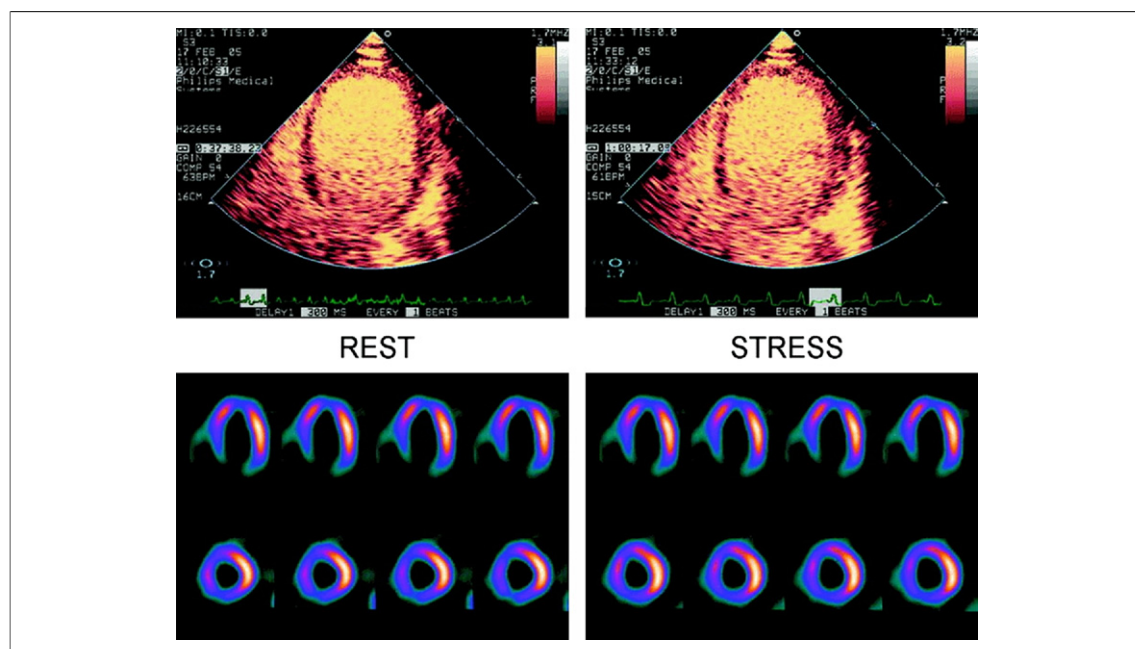


Figure 8. An Example of a Patient With Left Bundle Branch Block

An example of a patient with left bundle branch block who exhibited normal perfusion with myocardial contrast echocardiography but abnormal perfusion in the septum during radionuclide single-photon emission computed tomography despite no significant coronary artery disease. See text for details. Reprinted, with permission, from Hayat et al. (34).

Artifacts in myocardial perfusion assessments. One must be able to differentiate potential artifacts that create the appearance of perfusion defects. The most common source of artifacts is attenuation. This typically occurs in basal segments and is differentiated from true defects by its location. Attenuation typically masks not only the myocardium, but adjacent epicardial and endocardial borders as well. Attenuation is usually present both at rest and during stress, whereas inducible defects are present only during stress and typically involve just the subendocardium. Other potential artifacts are lung shadows, which will often mask an entire region (e.g., the anterior wall in the apical 2-chamber view) (Fig. 6). A second location where artifacts tend to occur is in the apical region. If the near-field gains (time gain compensation) are set too low, the apex will appear hypoperfused. Unlike true defects, this can be corrected by increasing the near-field potentiometer settings. Near-field destruction of microbubbles can also cause the false appearance of perfusion defects in the apex. This can be corrected by moving the focus to the near field, which decreases the scan-line density in this region and reduces destruction.

Conclusions

MCE is a bedside imaging technique that has very high resolution and can be performed without the

need of ionizing radiation. The use of intravenous microbubbles for perfusion imaging is now a reality. Unfortunately, the U.S. Food and Drug Administration still has not approved the use of ultrasound contrast for myocardial perfusion imaging. Nonetheless, the real-time methods used to achieve optimal left ventricular opacification (the approved U.S. Food and Drug Administration indication) often result in myocardial opacification, which permits the simultaneous analysis of perfusion. Consensus documents from both the U.S. and Europe have also clearly summarized the incremental value of myocardial perfusion imaging in detecting CAD both during rest and stress echocardiography (71,72). Clinical studies have demonstrated the potential for this technique in the emergency department, during stress echocardiography, and in the detection of viability, and prospective studies are underway to examine the prognostic value of real-time perfusion imaging during stress echocardiography as compared with conventional echocardiographic imaging.

Reprint requests and correspondence: Dr. Thomas R. Porter, University of Nebraska Medical Center, Cardiology, 981165 Nebraska Medical Center, Omaha, Nebraska 68198-1165. *E-mail:* trporter@unmc.edu.

REFERENCES

1. Keller MW, Feinstein SB, Watson DD. Successful left ventricular opacification following peripheral venous injection of sonicated contrast agent: an experimental evaluation. *Am Heart J* 1987;114:570–5.
2. Unger EC, Lund PJ, Shen DK, Fritz TA, Yellowhair D, New TE. Nitrogen-filled liposomes as a vascular US contrast agent. *Radiology* 1992; 185:453–6.
3. Porter TR, Xie F. Visually discernible myocardial echocardiographic contrast following intravenous injection of sonicated dextrose albumin microbubbles containing high molecular weight less soluble gases. *J Am Coll Cardiol* 1995;25:509–15.
4. Tsutsui JM, Elhendy A, Anderson JR, Xie F, McGrain AC, Porter TR. Prognostic value of dobutamine stress myocardial contrast perfusion echocardiography. *Circulation* 2005;112: 1444–50.
5. Porter TR, Li S, Kricsfeld D, Armbruster RW. Detection of myocardial perfusion in multiple echocardiographic windows with one intravenous injection of microbubbles using transient response second harmonic imaging. *J Am Coll Cardiol* 1997;29: 791–9.
6. Wei K, Jayaweera AR, Firoozan S, Linka A, Skyba DM, Kaul S. Quantification of myocardial blood flow with ultrasound-induced destruction of microbubbles administered as a constant venous infusion. *Circulation* 1998;97:473–83.
7. Kaul S, Senior R, Dittrich H, Raval U, Khattar R, Lahiri A. Detection of coronary artery disease with myocardial contrast echocardiography: comparison with 99mTc-sestamibi single-photon emission computed tomography. *Circulation* 1997; 96:785–92.
8. Cwajg J, Xie F, O'Leary E, Kricsfeld D, Dittrich H, Porter TR. Detection of angiographically significant coronary artery disease with accelerated intermittent imaging after intravenous administration of ultrasound contrast material. *Am Heart J* 2000; 139:675–83.
9. Heinle SK, Noblin J, Goree-Best P, et al. Assessment of myocardial perfusion by harmonic power Doppler imaging at rest and during adenosine stress: comparison with (99m) Tc-sestamibi SPECT imaging. *Circulation* 2000;102:55–60.
10. Janardhanan R, Senior R. Accuracy of dipyridamole myocardial contrast echocardiography for the detection of residual stenosis of the infarct-related artery and multivessel disease early after acute myocardial infarction. *J Am Coll Cardiol* 2004;43:2247–52.
11. Balcells E, Powers ER, Lepper W, et al. Detection of myocardial viability by contrast echocardiography in acute infarction predicts recovery of resting function and contractile reserve. *J Am Coll Cardiol* 2003;41:827–33.
12. Main ML, Magalski A, Morris BA, Coen MM, Skolnick DG, Good TH. Combined assessment of microvascular integrity and contractile reserve improves differentiation of stunning and necrosis after acute anterior wall myocardial infarction. *J Am Coll Cardiol* 2002;40:1079–84.

13. Swinburn JM, Lahiri A, Senior R. Intravenous myocardial contrast echocardiography predicts recovery of dys-synergic myocardium early after acute myocardial infarction. *J Am Coll Cardiol* 2001;38:19–25.
14. Shimon S, Frangogiannis NG, Aggeli CJ, et al. Identification of hibernating myocardium with quantitative intravenous myocardial contrast echocardiography: comparison with dobutamine echocardiography and thallium-201 scintigraphy. *Circulation* 2003;107:538–44.
15. Tong KL, Kaul S, Wang XQ, et al. Myocardial contrast echocardiography versus thrombolysis in myocardial infarction score in patients presenting to the emergency department with chest pain and a nondiagnostic electrocardiogram. *J Am Coll Cardiol* 2005;46:920–7.
16. de Jong N, Ten Cate FJ, Lancee CT, Roelandt JR, Bom N. Principles and recent developments in ultrasound contrast agents. *Ultrasonics* 1991;29:324–30.
17. Burns P, Becher H. *Handbook of Contrast Echocardiography LV Function and Myocardial Perfusion*. New York, NY: Springer Verlag, 2000.
18. Macsweeny JE, Cosgrove DO, Arenson J. Colour Doppler energy (power) mode ultrasound. *Clin Radiol* 1996;51:387–90.
19. Powers JE, Burns PN, Souquet J. Imaging instrumentation for ultrasound contrast agents. In: Nanda NC, Schlieff R, Goldberg BB, editors. *Advances in Echo Imaging Using Contrast Enhancement*. 2nd edition. Dordrecht, the Netherlands: Kluwer Academic Publishers, 1997:139.
20. Broillet A, Puginier J, Ventrone R, Schneider M. Assessment of myocardial perfusion by intermittent harmonic power Doppler using SonoVue, a new ultrasound contrast agent. *Invest Radiol* 1998;33:209–15.
21. Senior R, Kaul S, Soman P, Lahiri A. Power Doppler harmonic imaging: a feasibility study of a new technique for the assessment of myocardial perfusion. *Am Heart J* 2000;139:245–51.
22. Binder T, Assayag P, Baer F, et al. NC100100, a new echo contrast agent for the assessment of myocardial perfusion: safety and comparison with technetium-99m sestamibi single-photon emission computed tomography in a randomized multicenter study. *Clin Cardiol* 1999;22:273–82.
23. Main ML, Escobar JF, Hall SA, Killam AL, Grayburn PA. Detection of myocardial perfusion defects by contrast echocardiography in the setting of acute myocardial ischemia with residual antegrade flow. *J Am Soc Echocardiogr* 1998;11:228–35.
24. Simpson DH, Burns PN. Pulse inversion Doppler: a new method for detecting nonlinear echoes from microbubble contrast agents. *Proc IEEE Ultrason Symp* 1997;2:1597–1600.
25. Rafter P, Phillips P, Vannan MA. Imaging technologies and techniques. *Cardiol Clin* 2004;22:181–97.
26. Skyba DM, Jayaweera AR, Goodman NC, Ismail S, Camarano G, Kaul S. Quantification of myocardial perfusion with myocardial contrast echocardiography during left atrial injection of contrast: implication for venous injection. *Circulation* 1994;90:1513–21.
27. Lindner JR, Villanueva FS, Dent JM, Wei K, Sklenar J, Kaul S. Assessment of resting perfusion with myocardial contrast echocardiography: theoretical and practical considerations. *Am Heart J* 2000;139:231–40.
28. Weissman NJ, Mylan CC, Hack TC, et al. Infusion versus bolus contrast echocardiography: a multicenter, open-label, crossover trial. *Am Heart J* 2000;139:399–404.
29. Wei K, Jayaweera AR, Firoozan S, Linka A, Skyba DM, Kaul S. Basis for detection of stenosis using venous administration of microbubbles during myocardial contrast echocardiography: bolus or continuous infusion? *Circulation* 1998;32:252–60.
30. Vogel R, Indermuhle A, Reinhardt J, et al. The quantification of absolute myocardial perfusion in humans by contrast echocardiography. *J Am Coll Cardiol* 2005;45:754–62.
31. Senior R, Monaghan M, Main ML, et al. Detection of coronary artery disease with perfusion stress echocardiography using a novel ultrasound imaging agent: two phase 3 international trials in comparison with radionuclide perfusion imaging. *Eur J Echocardiogr* 2009;10:26–35.
32. Peltier M, Vancraeynest D, Pasquet A, et al. Assessment of the physiologic significance of coronary disease with dipyridamole real-time myocardial contrast echocardiography. Comparison with technetium-99m sestamibi single-photon emission computed tomography and quantitative coronary angiography. *J Am Coll Cardiol* 2004;43:257–64.
33. Xie F, Hankins J, Mahrous HA, Porter TR. Detection of coronary artery disease with a continuous infusion of definity ultrasound contrast during adenosine stress real time perfusion echocardiography. *Echocardiography* 2007;24:1044–50.
34. Hayat SA, Dwivedi G, Jacobsen A, Lim TK, Kinsey C, Senior R. Effects of left bundle branch block on cardiac structure, function, perfusion, and perfusion reserve: implications for myocardial contrast echocardiography versus radionuclide perfusion imaging for the detection of coronary artery disease. *Circulation* 2008;117:1832–41.
35. Yu EH, Skyba DM, Leong-Poi H, et al. Incremental value of parametric quantitative assessment of myocardial perfusion by triggered Low-Power myocardial contrast echocardiography. *J Am Coll Cardiol* 2004;43:1807–13.
36. Moir S, Jaluska BA, Jenkins C, Fathi R, Marwick TH. Incremental benefit of myocardial contrast to combined dipyridamole-exercise stress echocardiography for the assessment of coronary artery disease. *Circulation* 2004;110:1108–13.
37. Tsutsui JM, Xie F, McGrain AC, et al. Comparison of low-mechanical index pulse sequence schemes for detecting myocardial perfusion abnormalities during vasodilator stress echocardiography. *Am J Cardiol* 2005;95:565–70.
38. Jeetley P, Hickman M, Kamp O, et al. Myocardial contrast echocardiography for the detection of coronary artery stenosis. *J Am Coll Cardiol* 2005;47:141–5.
39. Korosoglou G, Dubart AE, DaSilva KG Jr., et al. Real time myocardial perfusion imaging for pharmacologic stress testing: added value to single photon emission computed tomography. *Am Heart J* 2006;151:131–8.
40. Malm S, Frigstad S, Torp H, Wiseth R, Skjærpe T. Quantitative adenosine real-time myocardial contrast echocardiography for detection of angiographically significant coronary artery disease. *J Am Soc Echocardiogr* 2006;19:365–72.
41. Wasmeier GH, Asmussen S, Voigt JU, Flachskampf FA, Daniel WG, Nixdorff U. Real-time myocardial contrast stress echocardiography using bolus application. *Ultrasound Med Biol* 2008;34:1724–31.
42. Lipiec P, Wejner-Mik P, Krzemińska-Pakuła M, et al. Accelerated stress real-time myocardial contrast echocardiography for the detection of coronary artery disease: comparison with 99mTc single photon emission computed tomography. *J Am Soc Echocardiogr* 2008;21:941–7.
43. Mor-Avi V, Koch R, Holper EM, et al. Value of vasodilator stress myocardial contrast echocardiography and magnetic resonance imaging for the differential diagnosis of ischemic versus nonischemic cardiomyopathy. *J Am Soc Echocardiogr* 2008;21:425–32.
44. Lønnebakken MT, Bleie O, Strand E, Staal EM, Nygard OK, Gerds E. Myocardial contrast echocardiography in assessment of stable coronary artery disease at intermediate dobutamine-induced stress level. *Echocardiography* 2009;26:52–60.

45. Porter TR, Xie F, Silver M, Kricsfeld D, O'Leary E. Real-time perfusion imaging with low mechanical index pulse inversion Doppler imaging. *J Am Coll Cardiol* 2001;37:748–53.
46. Tsutsui JM, Elhendy A, Xie F, O'Leary EL, McGrain AC, Porter TR. Safety of dobutamine stress real-time myocardial contrast echocardiography. *J Am Coll Cardiol* 2005;45:1235–42.
47. Shimoni S, Zoghbi WA, Xie F, et al. Real-time assessment of myocardial perfusion and wall motion during bicycle and treadmill exercise echocardiography: comparison with single photon emission computed tomography. *J Am Coll Cardiol* 2001;37:741–7.
48. Misalski-Jamka T, Kuntz-Hehner S, Schmidt H, et al. Real time myocardial contrast echocardiography during supine bicycle stress and continuous infusion of contrast agent. Cutoff values for myocardial contrast replenishment discriminating abnormal myocardial perfusion. *Echocardiography* 2007;24:638–48.
49. Olszowska M, Kostkiewicz M, Tracz W, Przewlocki T. Assessment of myocardial perfusion in patients with coronary artery disease. Comparison of myocardial contrast echocardiography and 99mTc MiBI single photon emission computed tomography. *Int J Cardiol* 2003;90:49–55.
50. Elhendy A, Tsutsui JM, O'Leary EL, Xie F, Porter TR. Noninvasive diagnosis of coronary artery disease in patients with diabetes by dobutamine stress real-time myocardial contrast perfusion imaging. *Diabetes Care* 2005;28:1662–7.
51. Xie F, Tsutsui JM, McGrain AC, et al. Comparison of dobutamine stress echocardiography with and without real-time perfusion imaging for detection of coronary artery disease. *Am J Cardiol* 2005;96:506–11.
52. Hacker M, Hoyer HX, Uebleis C, et al. Quantitative assessment of cardiac allograft vasculopathy by real-time myocardial contrast echocardiography: a comparison with conventional echocardiographic analyses and [Tc99m]-sestamibi SPECT. *Eur J Echocardiogr* 2008;9:494–500.
53. Elhendy A, O'Leary EL, Xie F, McGrain AC, Anderson JR, Porter TR. Comparative accuracy of real-time myocardial contrast perfusion imaging and wall motion analysis during dobutamine stress echocardiography for the diagnosis of coronary artery disease. *J Am Coll Cardiol* 2004;44:2185–91.
54. Dolan M, Gala SS, Dodla S, et al. Safety and efficacy of commercially available ultrasound contrast agents for rest and stress echocardiography: a multicenter experience. *J Am Coll Cardiol* 2009;53:32–8.
55. Xie F, Dodla S, O'Leary E, Porter TR. Detection of subendocardial ischemia in the left anterior descending coronary artery territory with real-time myocardial contrast echocardiography during dobutamine stress echocardiography. *J Am Coll Cardiol* 2008;1:271–8.
56. Dodla S, Xie F, O'Leary E, Smith M, Porter T. Detection of CAD with real time perfusion imaging during exercise and dobutamine stress echocardiography. *Circulation* 2008;118S:850.
57. Kloner RA, Ganote CE, Jennings RB. The “no-reflow” phenomenon after temporary coronary occlusion in the dog. *Clin Invest* 1974;54:1496–1508.
58. Ito H, Tomooka T, Sakai N, et al. Lack of myocardial perfusion immediately after successful thrombolysis: a predictor of poor recovery of left ventricular function in anterior myocardial infarction. *Circulation* 1992;85:1699–1705.
59. Lepper W, Hoffmann R, Kamp O, et al. Assessment of myocardial reperfusion by intravenous myocardial contrast echocardiography and coronary flow reserve after primary percutaneous transluminal coronary angiography in patients with acute myocardial infarction. *Circulation* 2000;101:2368–74.
60. Main ML, Magalski A, Chee NK, et al. Full-motion pulse inversion power Doppler contrast echocardiography differentiates stunning from necrosis and predicts recovery of left ventricular function after acute myocardial infarction. *J Am Coll Cardiol* 2001;38:1390–4.
61. Hillis GS, Mulvagh SL, Gunda M, et al. Contrast echocardiography using intravenous octafluoropropane and real-time perfusion imaging predicts function recovery after acute myocardial infarction. *J Am Soc Echocardiogr* 2003;16:638–45.
62. Janardhanan R, Swinburn JM, Greaves K, et al. Usefulness of myocardial contrast echocardiography using low-power continuous imaging early after acute myocardial infarction to predict late functional left ventricular recovery. *Am J Cardiol* 2003;92:493–7.
63. Korosoglou G, Labadze N, Giannitsis E, et al. Usefulness of real-time myocardial perfusion imaging to evaluate tissue level reperfusion in patients with non ST-elevation myocardial infarction. *Am J Cardiol* 2005;95:1033–8.
64. Huang WC, Chiou KR, Liu CP, et al. Comparison of real-time contrast echocardiography and low-dose dobutamine stress echocardiography in predicting the left ventricular functional recovery in patients after acute myocardial infarction under different therapeutic intervention. *Int J Cardiol* 2005;104:81–91.
65. Sbrano JC, Tsutsui JM, Andrade JL, et al. Detection of functional recovery using low-dose dobutamine and myocardial contrast echocardiography after acute myocardial infarction treated with successful thrombolytic therapy. *Echocardiography* 2005;22:496–502.
66. Abe Y, Muro T, Sakanoue Y, et al. Intravenous myocardial contrast echocardiography predicts regional and global left ventricular remodeling after acute myocardial infarction: comparison with low dose dobutamine stress echocardiography. *Heart* 2005;91:1578–83.
67. Dwivedi G, Janardhanan R, Hayat SA, Swinburn JM, Senior R. Prognostic value of myocardial viability detected by myocardial contrast echocardiography early after acute myocardial infarction. *J Am Coll Cardiol* 2007;50:327–34.
68. Galiuto L, Garramone B, Scara A, et al. The extent of microvascular damage during myocardial contrast echocardiography is superior to other known indexes of post-infarct reperfusion in predicting left ventricular remodeling. *J Am Coll Cardiol* 2008;51:552–9.
69. Shimoni S, Frangogiannis NG, Aggeli CJ, et al. Microvascular structural correlates of myocardial contrast echocardiography in patients with coronary artery disease and left ventricular dysfunction: implications for the assessment of myocardial hibernation. *Circulation* 2002;106:950–6.
70. Shimoni S, Frangogiannis NG, Aggeli CJ, et al. Identification of hibernating myocardium with quantitative intravenous myocardial contrast echocardiography: comparison with dobutamine echocardiography and thallium-201 scintigraphy. *Circulation* 2003;107:538–44.
71. Senior R, Becher H, Monaghan M, et al. Contrast echocardiography: evidence-based recommendations by European Association of Echocardiography. *Eur J Echocardiogr* 2009;10:194–212.
72. Mulvagh SL, Rakowski H, Vannan MA, et al. American society of echocardiography consensus statement on the clinical applications of ultrasonic contrast agents in echocardiography. *J Am Soc Echocardiogr* 2008;21:1179–201.

Key Words: myocardial contrast echocardiography ■ ultrasound contrast.