

# CT Angiography for the Prediction of Hemodynamic Significance in Intermediate and Severe Lesions

## Head-to-Head Comparison With Quantitative Coronary Angiography Using Fractional Flow Reserve as the Reference Standard

Matthew J. Budoff, MD,<sup>a</sup> Ryo Nakazato, MD,<sup>b</sup> G.B. John Mancini, MD,<sup>c</sup> Heidi Gransar, PhD,<sup>b</sup> Jonathon Leipsic, MD,<sup>c</sup> Daniel S. Berman, MD,<sup>b</sup> James K. Min, MD<sup>d</sup>

### ABSTRACT

**OBJECTIVES** The goal of this study was to compare the diagnostic performance of coronary computed tomography angiography (CTA) versus quantitative coronary angiography (QCA) for the detection of lesion-specific ischemia using fractional flow reserve (FFR) as the gold standard.

**BACKGROUND** Coronary CTA has emerged as a noninvasive method for accurate detection and exclusion of high-grade coronary stenoses. FFR is the gold standard for determining lesion-specific ischemia and has been shown to improve clinical outcomes when guiding revascularization.

**METHODS** A total of 252 patients from 5 countries were prospectively enrolled (mean age 63 years; 71% male). Patients underwent coronary CTA and invasive coronary angiography (ICA) with FFR in 407 lesions. Coronary CTA, QCA, and FFR were interpreted by independent core laboratories. Stenosis severity according to coronary CTA and QCA were graded as 0% to 29%, 30% to 49%, 50% to 69%, and 70% to 100%; stenosis  $\geq 50\%$  was considered anatomically obstructive. Lesion-specific ischemia was defined according to FFR  $\leq 0.8$ , whereas QCA and coronary CTA stenosis  $\geq 50\%$  were considered obstructive. Diagnostic accuracy and areas under the receiver-operating characteristics curve (AUC) for lesion-specific ischemia was assessed.

**RESULTS** According to FFR, ischemia was present in 151 (37%) of 407 lesions. Diagnostic accuracy, sensitivity, specificity, positive predictive value, and negative predictive value were 69%, 79%, 63%, 55%, and 83% for coronary CTA; and 71%, 74%, 70%, 59%, and 82% for QCA. AUC for identification of ischemia-causing lesions was similar: 0.75 for coronary CTA and 0.77 for QCA ( $p = 0.6$ ). No differences between CTA and QCA existed for discrimination of ischemia within the left anterior descending artery (AUC 0.71 vs. 0.73;  $p = 0.6$ ), left circumflex artery (AUC 0.78 vs. 0.85;  $p = 0.4$ ), and right coronary artery (AUC 0.80 vs. 0.83;  $p = 0.6$ ).

**CONCLUSIONS** CTA and ICA exhibited similar diagnostic performance for the detection and exclusion of lesion-specific ischemia. Using a true reference standard to determine appropriate revascularization targets, 3-dimensional coronary CTA performed as well as 2-dimensional ICA. (J Am Coll Cardiol Img 2016;■:■-■) © 2016 by the American College of Cardiology Foundation.

**ABBREVIATIONS  
AND ACRONYMS****AUC** = area under the curve**CAD** = coronary artery disease**CT** = computed tomography**CTA** = computed tomography  
angiography**FFR** = fractional flow reserve**FFR<sub>CT</sub>** = fractional flow reserve  
by computed tomography**ICA** = invasive coronary  
angiography**NPV** = negative predictive  
value**PPV** = positive predictive value**QCA** = quantitative coronary  
angiography

Measurement of fractional flow reserve (FFR) provides hemodynamic assessment of coronary artery lesions, facilitating clinical decision-making regarding coronary artery revascularization (1-3). Decisions based on specific FFR values significantly affect patient morbidity and mortality, resulting in the incorporation of FFR-guided intervention for intermediate stenoses in interventional guidelines with a Class IIa, Level of Evidence A, recommendation (4). Until recently, invasive angiography has been considered a gold standard for obstructive disease and need for revascularization, but these intervention trials clearly show that functional ischemia, as defined by FFR, improves outcomes. Coronary

computed tomography angiography (CTA) has been shown to be a highly diagnostic test that results in better cardiovascular outcomes than functional testing (5,6) but has been perpetually compared with invasive angiography as a reference standard for diagnostic accuracy (7,8). The development of fractional flow reserve derived from resting computed tomography (FFR<sub>CT</sub>) has led to studies being performed to evaluate the diagnostic accuracy of FFR<sub>CT</sub> compared with invasive FFR (9). This approach allows for a large cohort of patients with coronary CTA and invasive coronary angiography (ICA) to be compared with invasive FFR to identify physiologically significant lesions that would benefit from revascularization.

The objective of the present study was to compare the diagnostic accuracy of quantitative coronary angiography (QCA) and coronary CTA versus invasive FFR measurements. To the best of our knowledge, QCA- and coronary CTA-derived stenosis measurements have not previously been compared head-to-head for the prediction of ischemia as categorized by FFR in a large multicenter cohort.

**METHODS**

The rationale, design, and overall results of the DeFACTO (Determination of Fractional Flow Reserve by Anatomic Computed Tomographic Angiography) study have been reported previously (9,10). Briefly,

DeFACTO was designed to evaluate the accuracy of FFR<sub>CT</sub> in diagnosing hemodynamically significant coronary artery disease (CAD), as defined by an invasive FFR reference standard, in a targeted population of subjects with suspected CAD who were referred for clinically indicated ICA. Patients with prior revascularization were excluded, and the final population consisted of 252 patients with 407 vessels. The DeFACTO study was conducted at 17 centers in 5 countries.

All patients provided written informed consent. The study was consistent with the principles of the Declaration of Helsinki. Coronary CTA, ICA, FFR, and FFR<sub>CT</sub> were interpreted in a blinded fashion by independent core laboratories as previously described (9).

**CORONARY CTA IMAGE ACQUISITION AND ANALYSIS.**

Coronary CTA was performed on  $\geq 64$  detector row scanners with prospective or retrospective electrocardiographic gating in accordance with Society of Cardiovascular Computed Tomography guidelines (11,12). Computed tomography (CT) angiograms were interpreted at the central CT core laboratory (Los Angeles Biomedical Center, Torrance, California) for blinded interpretation by using an 18-segment coronary model. Investigators evaluated CT scans by visual assessment for maximal patient- and vessel-diameter stenosis, which was categorized as 0%, 1% to 29%, 30% to 49%, 50% to 69%, and  $>70\%$  stenosis, or totally (100%) occluded. Per-patient and per-vessel CAD stenosis were the maximal stenoses identified in all segments or in all segments within a vessel distribution, respectively. Use of beta-blockers and nitroglycerin was left to individual site practices.

**ICA IMAGE ANALYSIS.** Invasive coronary angiograms were transferred to a central angiographic core laboratory (University of British Columbia, Vancouver, British Columbia, Canada) for blinded QCA of all vessels using commercially available software (Discovery System, Quinton, Bothell, Washington). The angiographic core laboratory visualized each coronary artery by multiple projections. QCA measurements were performed of every lesion  $\geq 30\%$  in coronary segments  $\geq 1.5$  mm in diameter.

**FRACTIONAL FLOW RESERVE.** FFR was performed at the time of ICA (PressureWire Certus, St. Jude

Dr. Budoff has received grant support from GE Healthcare and the National Institutes of Health. Dr. Min has served as a consultant for Abbott Vascular, Neograft Technologies, MyoKardia, and CardioDx; member of the Scientific Advisory Board for Arineta; has a research agreement with GE Healthcare; ownership in MDDX and AutoPlaq; and has received grants from the National Institutes of Health/National Heart, Lung, and Blood Institute (R01HL111141, R01HL115150, and R01HL118019). All other authors have reported that they have no relationships relevant to the contents of this paper to disclose. David Bluemke, MD, served as Guest Editor for this paper.

Manuscript received June 2, 2015; revised manuscript received July 30, 2015, accepted August 5, 2015.

Medical Systems, Uppsala, Sweden; ComboWire, Volcano Corporation, San Diego, California). Investigators performed FFR in vessels deemed clinically indicated for evaluation and demonstrating an ICA stenosis between 30% and 90%. Vessels deemed not clinically indicated for FFR were not interrogated. After administration of nitroglycerin, a pressure-monitoring guidewire was advanced distal to a stenosis. Hyperemia was induced by administration of intravenous adenosine at a rate of 140  $\mu\text{g/kg/min}$ . FFR was calculated by dividing the mean distal coronary pressure by the mean aortic pressure during hyperemia. FFR was considered diagnostic of ischemia at a threshold  $\leq 0.80$  (13). Accuracy of coronary CTA for diagnosis of ischemia was compared with QCA with an invasive FFR reference standard. Ischemia was defined by an FFR  $\leq 0.80$ , whereas anatomically obstructive CAD was defined by a stenosis  $\geq 50\%$  on coronary CTA and ICA. Correlation receiver-operating characteristic analysis was used to assess the relation between anatomic measurements and FFR.

**STATISTICAL ANALYSIS.** Endpoints included assessment of diagnostic accuracy, sensitivity, specificity, positive predictive value (PPV), and negative predictive value (NPV) of coronary CTA and invasive angiography for all patients. Vessel- and patient-based analyses were conducted by using invasive FFR as the reference standard. Furthermore, diagnostic performance was assessed on a per-patient basis by using a stenosis threshold of 70% for coronary CTA and ICA. AUC comparisons were performed on per-patient and per-vessel levels according to the method described by DeLong et al. (14). Diagnostic accuracy, sensitivity, specificity, PPV, and NPV were calculated as simple proportions with 95% confidence intervals (CIs). A patient was considered positive for the presence of ischemia if any evaluable vessel had an FFR value  $\leq 0.80$ . Patient-level comparison of diagnostic performance characteristic accuracy, sensitivity, specificity, PPV, and NPV was conducted by using the McNemar's test for paired samples or the percentile bootstrap method with 100,000 resamples as appropriate. To account for potential correlation between multiple vessels in the same subject, the generalized estimating equation method (with an exchangeable correlation structure) was used to compare paired samples at a per-vessel level. All analyses were performed by using SAS version 9.3 (SAS Institute, Inc., Cary, North Carolina).

## RESULTS

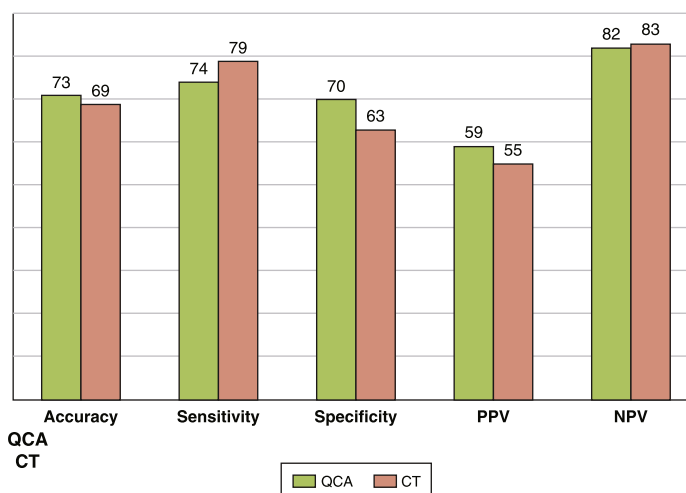
Among study participants, 137 (54.4%) had an abnormal FFR determined by ICA. According to FFR,

ischemia was present in 151 (37%) of 407 lesions. As described in the paper by Min et al. (10), among 285 patients who underwent coronary CTA, ICA, FFR, and FFR<sub>CT</sub>, 31 were excluded by the CT core laboratory for nonevaluable CT scans, and 2 patients were excluded for unresolvable integration of the FFR wire transducer location by ICA to its corresponding location on CT scans; thus, 252 patients were included in the analyses. The median duration between coronary CTA and ICA plus FFR was 15.5 days (interquartile range: 5 to 33 days).

Two enrolled patients experienced coronary dissection during FFR wire crossing that required percutaneous coronary intervention, and 1 patient experienced a retroperitoneal bleeding episode requiring blood transfusion and corrective surgery. No untoward events were identified after CT scanning, with no episodes of serious contrast reactions or contrast-induced nephropathy noted. The median radiation dose of coronary CTA was 6.4 mSv (interquartile range: 4.4 to 15.0 mSv).

Per-patient diagnostic accuracy, sensitivity, specificity, PPV, and NPV were 69% (95% CI: 62 to 76), 79% (95% CI: 72 to 84), 63% (95% CI: 57 to 70), 55% (95% CI: 48 to 83), and 83% (95% CI: 77 to 88) for coronary CTA; and 71% (95% CI: 69 to 80), 74% (95% CI: 68 to 79), 70% (95% CI: 64 to 75), 59% (95% CI: 52 to 82), and 82% (95% CI: 72 to 88) for QCA (Figure 1). AUC for identification

**FIGURE 1 Per-Patient Diagnostic Performance of Both Cardiac CT Scans and Invasive Angiography**



Both tests demonstrated similar diagnostic accuracy for detecting ischemia-causing lesions by FFR. CT = computed tomography; FFR = fractional flow reserve; NPV = negative predictive value; PPV = positive predictive value; QCA = quantitative coronary angiography.

of ischemia-causing lesions was similar: 0.75 (95% CI: 0.70 to 0.81) for coronary CTA and 0.77 (95% CI: 0.71 to 0.84) for QCA ( $p = 0.6$ ). Per-vessel analysis was not significantly different from the per-patient values. No differences between coronary CTA and QCA existed for discrimination of ischemia in a per-vessel analysis (AUC: 0.75) or by individual vessel AUC: within the left anterior descending artery, AUC: 0.71 versus 0.73 ( $p = 0.6$ ); left circumflex artery, AUC: 0.78 versus 0.85 ( $p = 0.4$ ); or right coronary artery, AUC 0.80 versus 0.83 ( $p = 0.6$ ). There was no significant difference between evaluation of 50% and 70% cutpoints for coronary CTA (AUC: 0.75 vs. 0.77;  $p = \text{NS}$ ).

## DISCUSSION

A comparison predicting FFR abnormalities (inferring lesion-specific ischemia) based on noninvasive coronary CTA and ICA has not been well evaluated contemporarily in a large-scale multicenter study. The aim of the present study was to assess the diagnostic value of coronary CTA compared with ICA to detect lesion-specific ischemia. This study is the first prospective, head-to-head multicenter analysis of 2 widely used anatomic modalities (QCA and coronary CTA) compared with invasive FFR. In this large, multicenter study using blinded core laboratories for each of the 3 modalities, QCA and coronary CTA had similar correlation and predictive accuracy for ischemia ( $\text{FFR} \leq 0.80$ ). Overall, our study confirmed that QCA- and coronary CTA-derived measurements perform similarly for the prediction of lesion-specific ischemia. Although this study validates the continued use of invasive angiography for anatomic assessment of stenosis, it strongly supports the use of coronary CTA for similar diagnoses (15–18). The main findings of our study were that coronary CTA measurements performed similarly to QCA-derived measurements, suggesting that coronary CTA may be used as an alternative to assess luminal stenosis and to serve as gatekeeper to FFR measurements in patients presenting with chest pain syndromes. Furthermore, per-vessel and per-patient results were comparable for coronary CTA in evaluating ischemia-causing lesions. This was also true in another study comparing coronary CTA versus FFR in which 251 patients underwent both tests. Nørgaard et al. (15) showed that per-vessel performance of coronary CTA was similar to per-patient performance (0.79 vs. 0.81;  $p = \text{NS}$ ).

Each of the 2 modalities evaluated have individual strengths. Invasive angiography has a higher spatial and temporal resolution than coronary CTA, and the general opinion is that it does not quantify stenosis

severity as accurately as QCA. However, coronary CTA has higher contrast resolution, allowing plaque to be seen, which has been shown to improve prediction of FFR (19). Furthermore, the 3-dimensional nature of coronary CTA may allow for differential assessment of stenosis severity compared with the 2-dimensional ICA. This approach may answer the question as to why lower anatomical accuracy does not affect the accuracy in assessing hemodynamic significance.

Coronary CTA also allows for a surrogate FFR measure to be derived ( $\text{FFR}_{\text{CT}}$ ), which adds to the diagnostic potential of coronary CTA without additional scanning, radiation, or contrast injection. The DeFACTO study and the NXT (Analysis of Coronary Blood Flow Using CT Angiography: Next Steps) study suggests that  $\text{FFR}_{\text{CT}}$  is a useful surrogate for invasive FFR and is clearly associated with lower costs and increased patient safety (20). There are important clinical implications of this study. On the basis of recent national guidelines, the assessment of the functional significance of lesions should guide management decisions for medical therapy and revascularization (21). We found that the predictive accuracy of coronary CTA-derived measurements of stenosis severity had similar diagnostic accuracy compared with QCA. This finding suggests that, due to lower costs and improved safety, coronary CTA may act as a gatekeeper and first-line test to triage patients to medical therapy or invasive evaluation with FFR (with potential revascularization). Due to excellent validation and correlation with invasive FFR, computational fluid dynamic approaches could supplement the anatomic information obtained by coronary CTA by providing accurate estimation of FFR based on the resting coronary CTA dataset alone (22).

Several studies have reported on the comparison of coronary CTA versus FFR. Sarno et al. (19) evaluated the diagnostic accuracy of coronary CTA based on visual assessment of stenosis ( $>50\%$  diameter stenosis) using  $\text{FFR} \leq 0.75$  in 81 patients. The sensitivity and specificity of CTA was 79% and 64%. In another study, Meijboom et al. (20) evaluated 89 lesions in 79 patients, again using 50% diameter stenosis as the cutpoint and  $\text{FFR} \leq 0.75$  as the reference for obstructive CAD. They found that visual coronary CTA analysis had higher sensitivity (94%), and quantitative coronary CTA analysis had higher specificity (75%). Rossi et al. (21) performed a coronary CTA and FFR study in 99 patients. They concluded that “no significant difference” in sensitivity was found between visual coronary CTA and quantitative coronary CTA parameters ( $p > 0.05$ ). The specificity of visual

coronary CTA was lower than other quantitative measures. However, virtually all clinical reads and all reported accuracy studies have relied on visual assessment of coronary CTA; this approach is therefore more practical for assessing clinical cases. More recently, Voros et al. (22) evaluated quantitative coronary CTA to FFR, demonstrating a sensitivity and specificity of 81% and 75%, respectively, and the receiver-operating characteristic curve-derived minimal lumen area cutpoint of 3.11 mm<sup>2</sup> had a sensitivity and specificity of 81% and 81%. The paper by Voros et al. (22) differs significantly from the present study, as only lesions of 40% to 70% severity were evaluated, whereas all lesions >30% were included in the present study.

**STUDY LIMITATIONS.** First, although all studies were performed on ≥64 detector scanners, more advanced imaging now exists; therefore, it is possible that the diagnostic accuracy of coronary CTA will be higher using more contemporary scanners and advanced image acquisition techniques. Second, we did not vary FFR severity levels. Some studies have suggested that QCA measurements were slightly better to predict FFR of 0.75 compared with 0.80 (15). To date, 3 prospective studies investigating the diagnostic performance of FFR<sub>CT</sub> were examined. DISCOVERFLOW (Diagnosis of Ischemia-Causing Stenoses Obtained Via Noninvasive Fractional Flow Reserve) examined the diagnostic accuracy of FFR<sub>CT</sub> among 103 patients (23). Second, the larger multicenter DeFACTO study examined the diagnostic accuracy among 252 patients with stable CAD (10). Both studies reported high accuracy of 73% to 87%, sensitivity of 90% to 93%, and NPV of 84% to 90%, respectively. In the most recent study of 254 patients (15), the AUC for FFR<sub>CT</sub> demonstrated a greater diagnostic performance compared with that for CTA stenosis alone (0.9 vs. 0.81;  $p = 0.0008$ ).

In clinical practice, QCA is rarely used. An alternative comparison would be visual CT versus visual invasive angiography; however, the study design used QCA. Area stenosis by quantitative coronary CTA (19), although more specific in a single study, is not used clinically in coronary CTA, and it is not measured in the DeFACTO trial. The conclusion that QCA and coronary CTA yield similar results is drawn from the lack of a significant difference. The study was not prospectively designed to demonstrate this finding of noninferiority. Regardless, a noninvasive method that produces reliable information on both the anatomy and the functional significance of coronary artery stenosis would decrease the need for ICA, improving the safety, cost, and participant burden to

acquire anatomic information. The 2014 American College of Cardiology/American Heart Association guidelines (24) state that “CCTA can result in a more rapid, more cost-effective diagnosis than stress myocardial perfusion imaging.” Furthermore, European guidelines state (25) that “CCTA should be considered as an alternative to invasive angiography to exclude ACS when there is a low to intermediate likelihood of CAD and when troponin and ECG are inconclusive.” Current appropriate use criteria for coronary CTA (26) include evaluation of stable chest pain of low to intermediate probability, as well as acute coronary syndromes, when the initial electrocardiogram and troponin levels are normal or non-diagnostic. Finally, use of coronary CTA is common when results of functional tests are equivocal or discordant; thus, its utility is increasing. The results of our study reassure clinicians that the data from coronary CTA may be equivalent to those of invasive angiography in terms of diagnosing ischemic lesions.

## CONCLUSIONS

Coronary CTA, applied in lieu of ICA, provides similar diagnostic accuracy for detection and exclusion of lesion-specific ischemia. This has potential for coronary CTA largely replacing ICA for diagnosing obstructive coronary artery disease in low and intermediate risk patients. Importantly, invasive angiography should remain the dominant diagnostic strategy in high risk individuals, where pre-test probability of obstructive disease is very high.

**REPRINT REQUESTS AND CORRESPONDENCE:** Dr. Matthew J. Budoff, Department of Medicine, Harbor-UCLA Medical Center, Los Angeles Biomedical Research Center, 1124 W. Carson Street, Torrance, California 90502. E-mail: [mbudoff@labiomed.org](mailto:mbudoff@labiomed.org).

## PERSPECTIVES

**COMPETENCY IN MEDICAL KNOWLEDGE:** The use of coronary CTA as a diagnostic tool is much less invasive, safer, and less expensive and provides similar accuracy for ischemia-causing lesions as ICA. The 2 tests (coronary CTA and ICA) were similar in diagnostic accuracy for per-patient and per-vessel analyses.

**TRANSLATIONAL OUTLOOK:** The utility of a noninvasive angiogram has the potential to improve health care delivery by reducing costs and complications associated with invasive angiography. Future randomized trials should be conducted to prospectively compare the 2 modalities for accuracy, safety, radiation dose, and cost.



## REFERENCES

1. Pijls NH, van Schaardenburgh P, Manoharan G, et al. Percutaneous coronary intervention of functionally nonsignificant stenosis: 5-year follow-up of the DEFER Study. *J Am Coll Cardiol* 2007;49:2105-11.
2. Tonino PA, Fearon WF, De Bruyne B, et al. Angiographic versus functional severity of coronary artery stenoses in the FAME study fractional flow reserve versus angiography in multivessel evaluation. *J Am Coll Cardiol* 2010;55:2816-21.
3. De Bruyne B, Pijls NH, Kalesan B, et al. Fractional flow reserve-guided PCI versus medical therapy in stable coronary disease. *N Engl J Med* 2012;367:991-1001.
4. Levine GN, Bates ER, Blankenship JC, et al. 2011 ACCF/AHA/SCAI guideline for percutaneous coronary intervention: a report of the American College of Cardiology Foundation/American Heart Association Task Force on Practice Guidelines. *J Am Coll Cardiol* 2011;58:e44-122.
5. Budoff MJ, Li D. Coronary CT angiography again results in better patient outcomes. *J Am Coll Cardiol* 2014;64:741-2.
6. Min JK, Gilmore A, Budoff MJ, Berman DS, O'Day K. Cost-effectiveness of coronary CT angiography versus myocardial perfusion SPECT for evaluation of patients with chest pain and no known coronary artery disease. *Radiology* 2010;254:801-8.
7. Budoff MJ, Dowe D, Jollis JG, et al. Diagnostic performance of 64-multidetector row coronary computed tomographic angiography for evaluation of coronary artery stenosis in individuals without known coronary artery disease: results from the prospective multicenter ACCURACY (Assessment by Coronary Computed Tomographic Angiography of Individuals Undergoing Invasive Coronary Angiography) trial. *J Am Coll Cardiol* 2008;52:1724-32.
8. Mark DB, Berman DS, Budoff MJ, et al. ACCF/ACR/AHA/NASCI/SAIP/SCAI/SCCT 2010 expert consensus document on coronary computed tomographic angiography: a report of the American College of Cardiology Foundation Task Force on Expert Consensus Documents. *J Am Coll Cardiol* 2010;55:2663-99.
9. Min JK, Berman DS, Budoff MJ, et al. Rationale and design of the DeFACTO (Determination of Fractional Flow Reserve by Anatomic Computed Tomographic Angiography) study. *J Cardiovasc Comput Tomogr* 2011;5:301-9.
10. Min JK, Leipsic J, Pencina MJ, et al. Diagnostic accuracy of fractional flow reserve from anatomic CT angiography. *JAMA* 2012;308:1237-45.
11. Abbara S, Arbab-Zadeh A, Callister TQ, et al. SCCT guidelines for performance of coronary computed tomographic angiography: a report of the Society of Cardiovascular Computed Tomography Guidelines Committee. *J Cardiovasc Comput Tomogr* 2009;3:190-204.
12. Halliburton SS, Abbara S, Chen MY, et al. Society of Cardiovascular Computed Tomography. SCCT guidelines on radiation dose and dose-optimization strategies in cardiovascular CT. *J Cardiovasc Comput Tomogr* 2011;5:198-224.
13. Tonino PA, De Bruyne B, Pijls NH, et al., FAME Study Investigators. Fractional flow reserve vs angiography for guiding percutaneous coronary intervention. *N Engl J Med* 2009;360:213-24.
14. DeLong ER, DeLong DM, Clarke-Pearson DL. Comparing the areas under two or more correlated receiver operating characteristic curves: a nonparametric approach. *Biometrics* 1988;44:837-45.
15. Nørgaard BL, Leipsic J, Gaur S, et al. Diagnostic performance of noninvasive fractional flow reserve derived from coronary computed tomography angiography in suspected coronary artery disease. *J Am Coll Cardiol* 2014;63:1145-55.
16. Nakazato R, Park HB, Berman DS, et al. Non-invasive fractional flow reserve derived from CT angiography (FFRCT) for coronary lesions of intermediate stenosis severity: results from the DeFACTO study. *Circ Cardiovasc Imaging* 2013;6:881-9.
17. Andreini D, Pontone G, Bartorelli AL, et al. Sixty-four slice multidetector computed tomography: an accurate imaging modality for the evaluation of coronary arteries in dilated cardiomyopathy of unknown etiology. *Circ Cardiovasc Imaging* 2009;2:199-205.
18. Patel MR, Dai D, Hernandez AF, et al. Prevalence and predictors of nonobstructive coronary artery disease identified with coronary angiography in contemporary clinical practice. *Am Heart J* 2014;167:846-52.
19. Sarno G, Decraemer I, Vanhoenacker PK, et al. On the inappropriateness of noninvasive multidetector computed tomography coronary angiography to trigger coronary revascularization: a comparison with invasive angiography. *J Am Coll Cardiol Intv* 2009;2:550-7.
20. Meijboom WB, Van Mieghem CA, van Pelt N, et al. Comprehensive assessment of coronary artery stenoses: computed tomography coronary angiography versus conventional coronary angiography and correlation with fractional flow reserve in patients with stable angina. *J Am Coll Cardiol* 2008;52:636-43.
21. Rossi A, Papadopoulos SL, Pugliese F, et al. Quantitative computed tomographic coronary angiography: does it predict functionally significant coronary stenoses? *Circ Cardiovasc Imaging* 2014;7:43-51.
22. Voros S, Rinehart S, Vazquez-Figueroa JG, et al. Prospective, head-to-head comparison of quantitative coronary angiography, quantitative computed tomography angiography, and intravascular ultrasound for the prediction of hemodynamic significance in intermediate and severe lesions, using fractional flow reserve as reference standard (from the ATLANTA I and II Study). *Am J Cardiol* 2014;113:23-9.
23. Koo BK, Erglis A, Doh JH, et al. Diagnosis of ischemia-causing coronary stenoses by non invasive fractional flow reserve computed from coronary computed tomography angiograms. Results from the prospective multicenter Discover-Flow study. *J Am Coll Cardiol* 2011;58:1989-97.
24. Amsterdam EA, Wenger NK, Brindis RG, et al., American College of Cardiology, American Heart Association Task Force on Practice Guidelines; Society for Cardiovascular Angiography and Interventions; Society of Thoracic Surgeons; American Association for Clinical Chemistry. 2014 ACC/AHA guideline for the management of patients with non-ST-elevation acute coronary syndromes: a report of the American College of Cardiology/American Heart Association Task Force on Practice Guidelines. *J Am Coll Cardiol* 2014;64:e139-228.
25. Hamm CW, Bassand JP, Agewall S, et al. ESC guidelines for the management of acute coronary syndromes in patients presenting without persistent ST-segment elevation. *Eur Heart J* 2011;32:2999-3054.
26. Taylor AJ, Cerqueira M, Hodgson JM, et al. ACCF/SCCT/ACR/AHA/ASE/ASNC/NASCI/SCAI/SCMR 2010 appropriate use criteria for cardiac computed tomography: a report of the American College of Cardiology Foundation Appropriate Use Criteria Task Force the Society of Cardiovascular Computed Tomography, the American College of Radiology, the American Heart Association, the American Society of Echocardiography, the American Society of Nuclear Cardiology, the North American Society for Cardiovascular Imaging, the Society for Cardiovascular Angiography and Interventions, and the Society for Cardiovascular Magnetic Resonance. *J Am Coll Cardiol* 2010;56:1864-94.

**KEY WORDS** coronary angiography, coronary CT, diagnostic accuracy, fractional flow reserve, multidetector computed tomography