



Original Research

Serum amyloid a as an indicator of impending xenograft failure: Experimental studies

Guoqiang Zhang^{a,b}, Hidetaka Hara^b, Takayuki Yamamoto^b, Qi Li^b, Abhijit Jagdale^b, Yong Li^{a,1,**}, David K.C. Cooper^b, Hayato Iwase^{b,*,1}

^a Department of General Surgery, The First Affiliated Hospital of Nanchang University, Nanchang, Jiangxi Province, China

^b Xenotransplantation Program, Department of Surgery, University of Alabama at Birmingham, Birmingham, AL, USA

ARTICLE INFO

Keywords:

Amyloid A
C-reactive protein
Inflammation
Kidney, Pig
Serum amyloid A
Xenotransplantation

ABSTRACT

Background: There is well-documented systemic inflammatory response in xenograft recipients to the presence of a pig graft. Serum amyloid A (SAA) is an inflammatory marker that is elevated in various pathological states. The assay used to measure it is (i) simple, (ii) relatively inexpensive, and (iii) provides an answer within minutes. **Method:** The levels of SAA (n = 11) and C-reactive protein (C-RP) (n = 8) were measured retrospectively in the serum of baboons with pig kidney transplants, who received therapy with an IL-6R inhibitor and a TNF- α antagonist. Immunohistochemistry (IHC) was used to identify amyloid A and C-RP expression in the native livers and deposition in the pig kidney grafts.

Results: One kidney graft underwent hyperacute rejection, 6 (55%) underwent acute antibody-mediated rejection, 3 baboons (27%) were euthanized for serious systemic infections, and one was euthanized for acute gastric dilatation. The SAA increased temporarily after kidney transplantation, and increased again by the day of euthanasia, indicating moderate (n = 3) or significant (severe) (n = 8) inflammation. In contrast, as the baboons were receiving tocilizumab, C-RP did not increase. There was greater expression of amyloid A in baboon livers (by IHC) than of C-RP (mean OD 53 vs 1, p < 0.01), and greater deposition of amyloid A than C-RP in the pig kidney grafts (mean OD 24 vs 2, p < 0.001). Plasma fibrinogen negatively correlated with the expression of amyloid A in the liver (r = -0.72, p < 0.05). The results of the SAA assay correlated with amyloid A expression in the liver and deposition in the kidney grafts.

Conclusions: SAA is a sensitive, but non-specific, marker for inflammation in baboons with pig kidney grafts, and is not affected by therapy that suppresses the response of C-RP. The SAA assay is a rapid, reliable, and relatively inexpensive method of following the inflammatory state of baboons with pig xenografts.

1. Introduction

In recent years, considerable progress has been made in the results of pig organ xenotransplantation in nonhuman primates, with survival of heterotopic heart and life-supporting kidney transplants now extending for months or even years [1–4]. The indicators of impending graft failure are different from those seen after allotransplantation. Monitoring of the adaptive immune response, e.g., lymphocytes, T and B cells, is unhelpful, whereas indicators of coagulation dysregulation (e.g., reductions in platelet counts and plasma fibrinogen), and

inflammation appear to be valuable [1,5].

As there is a well-documented systemic inflammatory response in xenograft recipients (that has been termed systemic inflammation in xenograft recipients, SIXR) in response to the presence of a pig graft [5–7], we have searched for a reliable marker of this response. Initially, we suggested that C-reactive protein (C-RP) would be a reliable indicator that SIXR was occurring, but this was found to be unhelpful when the interleukin-6 receptor (IL-6R) was blocked by the specific IL-6R monoclonal antibody, tocilizumab [8]. Although the C-RP remained in the normal range, giving us a false picture of the state of

* Corresponding author. Xenotransplantation Program, University of Alabama at Birmingham (UAB), ZRB 701, 1720 2nd Avenue South, Birmingham, AL, 35294-0007, USA.

** Corresponding author. Department of General Surgery, the First Affiliated Hospital of Nanchang University, No. 17, Yongwai Zhengjie, Nanchang, Jiangxi Province, 330006, China.

E-mail addresses: yfylyong@163.com (Y. Li), hiwase@uabmc.edu (H. Iwase).

¹ Joint corresponding authors.

<https://doi.org/10.1016/j.ijss.2018.11.027>

Received 19 November 2018; Accepted 30 November 2018

Available online 03 December 2018

1743-9191/ © 2018 IJS Publishing Group Ltd. Published by Elsevier Ltd. All rights reserved.

Abbreviations

C-RP	C-reactive protein
IHC	immunohistochemistry
IL-6R	interleukin-6 receptor
MOD	mean optical density
SAA	serum amyloid A
SIXR	systemic inflammation in xenograft recipients

inflammation in the recipient, other indicators, e.g., cytokines, chemokines, histones, suggested that a state of inflammation was continuing.

We also investigated extracellular histones and serum amyloid A (SAA) as potential markers of impending graft failure [8,9]. SAA is an inflammatory marker that is elevated in various pathological states [10–13], and in recipients of kidney or heart allografts in the presence of rejection or infection [14–17]. SAA has the advantage that the assay used to measure it is (i) simple, (ii) relatively inexpensive, (iii) provides an answer within minutes, and (iv) can be carried out ‘at the bedside’ or, in the case of the experimental laboratory, at the side of the cage. Furthermore, it is not affected by the administration of tocilizumab or of soluble IL-6 blockade agents, such as siltuximab (unpublished data).

We therefore believe it has potential as an indicator that a xenograft may be at risk for injury, and thus would enable steps to be taken to prevent or reverse this. We have reviewed our most recent results of measuring SAA retrospectively in baboons with pig kidney grafts.

2. Materials and methods

2.1. Animals

Baboons ($n = 11$) (*Papio species*, Oklahoma University Health Sciences Center, Oklahoma City, OK) received a life-supporting kidney [1,2]. All grafts were from genetically-engineered pigs (Revivicor, Blacksburg, VA). All were from GTKO pigs that expressed one or more human complement-regulatory proteins, and all except one expressed one or more human coagulation-regulatory proteins in the kidneys. Five expressed the human anti-apoptotic/anti-inflammatory protein, hemeoxygenase-1 (HO-1).

Anesthesia, intravascular catheter placement in baboons, and pig-to-baboon surgical procedures have been described previously [1,2,18,19]. All animal care was in accordance with the Guide for the Care and Use of Laboratory Animals prepared by the National Research Council (8th edition, revised 2011), and was conducted in an AAALAC-accredited facility. Protocols were approved by the University of Pittsburgh and University of Alabama at Birmingham Institutional Animal Care and Use Committees.

2.2. Immunosuppressive, anti-inflammatory, and adjunctive therapy

Two immunosuppressive regimens were used, with the only difference being in the maintenance immunosuppressive therapy administered (Table 1). Five baboons received only FDA-approved agents (e.g., various combination of CTLA4-Ig, tacrolimus, rapamycin, mycophenolate mofetil), termed ‘conventional’ therapy, whereas the remaining 6 baboons received a regimen based on anti-CD40 mAb (2C10R4; NIH NHP Reagent Resource, Boston, MA), which is not yet FDA-approved.

Anti-inflammatory therapy included the IL-6R inhibitor, tocilizumab (Actemra, Genentech, South San Francisco, CA), administered throughout the post-transplant course, and the TNF- α antagonist, etanercept (Enbrel, Amgen Pfizer, Thousand Oaks, CA), administered for only the first two weeks.

2.3. Measurement of serum C-RP and SAA

Serum samples were obtained from the baboons before and at intervals after pig kidney transplantation. C-RP ($n = 8$) was measured by standard methods in two laboratories; samples were measured by the UPMC Central Laboratory in Pittsburgh (B9313, B17315, B17615, B17415), or by Antech Diagnostics (Atlanta, GA) (B10815, B5415, B15815, B9015). SAA ($n = 11$) was measured with an OmniChek™-SAA kit (Multispecies Rapid Test for Inflammation, Accuplex Diagnostics, Co Kildare, Ireland), as per the manufacturer's instructions. The level of SAA was assessed by the number of red bands that appear and the intensity of the red color (Fig. 1).

2.4. Measurement of coagulation parameters

Blood samples were collected for platelet counts, and plasma fibrinogen and D-dimer were measured by the UPMC Central Laboratory in Pittsburgh or by Antech Diagnostics [5].

2.5. Immunohistochemistry (IHC) for C-RP and amyloid A

After tissues were obtained at euthanasia, samples were immediately fixed in formalin and embedded in paraffin, and sections with a thickness of 4 μ m were cut. Expression of C-RP and amyloid A in the baboon liver ($n = 8$) and deposition of C-RP and amyloid A in the pig kidney ($n = 11$) were measured by IHC. Negative controls were naïve pig liver and kidney tissues. Positive controls were baboon liver and kidney tissues from (i) a baboon that experienced an intense anaphylactic response to anti-thymocyte globulin (and thus was euthanized without undergoing pig kidney transplantation), and (ii) a baboon (that received tocilizumab) in which the pig kidney graft underwent hyperacute rejection [20].

The primary and secondary antibodies used were (i) for amyloid A, rat anti-amyloid A (Accuplex Diagnostics) (1:100), and goat anti-rat (Ab#97057, Abcam, Cambridge, MA) (1:200), and (ii) for C-RP, rabbit anti-C-RP (Cat#Ab32412, Abcam) (1:50), and goat anti-rabbit (Cat#Ab6721, Abcam) (1:1000). All slides were examined with an optical microscope (Olympus Optical, Tokyo, Japan).

Expression of amyloid A and C-RP was measured by two methods.

- (i) *Intensity and extent of staining*: The intensity of stain was graded by two independent observers as (i) negative (–) = score 0; (ii) weakly positive (+) = score 1; moderately positive (++) = score 2; strongly positive (+++) = score 3. The percentage of

Table 1

Maintenance immunosuppressive (IS) therapy, survival (in days), and cause for euthanasia in baboons with pig kidney grafts.

Baboon Number	Maintenance IS therapy	Survival (days)	Cause for euthanasia
Long survival group			
B10815	Anti-CD40 mAb-based	90	AHXR
B9313	Anti-CD40 mAb-based	136	Systemic Infection
B17315	Anti-CD40 mAb-based	237	Systemic Infection
B17615	Anti-CD40 mAb-based	260	Systemic Infection
Short survival group			
B17415	Anti-CD40 mAb-based	12	AHXR
B3115	Anti-CD40 mAb-based	4	Acute gastric dilatation
B14214	Conventional therapy ^a	32	AHXR
B5415	Conventional therapy ^a	15	AHXR
B15815	Conventional therapy ^a	12	AHXR
B9015	Conventional therapy ^a	13	AHXR
B14115	Conventional therapy ^a	1	Hyperacute rejection

AHXR = acute humoral xenograft rejection.

^a Conventional therapy consisted of only FDA-approved agents (various combinations of CTLA4-Ig, tacrolimus, rapamycin, mycophenolate mofetil).




Fig. 1. Representative results of assay for SAA showing (A) 3 lines (negative), indicating no active inflammation, (B) 2 lines, indicating mild-to-moderate inflammation, (C) 1 line, indicating significant inflammation.

positively-stained cells was graded as (i) $< 5\%$ = score 0; 5–25% = score 1; 25–50% = score 2; 50–75% = score 3; $> 75\%$ = score 4. The formula for the total IHC score was determined by calculating the score of staining intensity \times the score of positive-staining cells. A total score of 0 was negative (–); scores of

1–4 were considered weakly-positive (+); scores of 5–8 were moderately-positive (++); scores of 9–12 were highly-positive (+++).

- (ii) **Quantitative analysis of expression:** Measurement was made of the mean optical density using ImageJ software (National Institute of Mental Health, Bethesda, MA). Five visual fields of each sample were randomly selected, and 5 visual areas were randomly selected from each visual field. The mean optical density (MOD) was calculated.

2.6. Serum assays for TNF- α and IL-1 β cytokines in baboons

The serum levels of serum TNF- α and IL-1 β at specific time-points (before any therapy or procedure [Naïve] and at euthanasia) were measured using cytometric bead array (CBA) with a human Inflammatory Cytokine Kit (#551811, BD Biosciences, San Jose, CA). LSR II flow cytometry (BD Biosciences) was used to collect data, and the data were analyzed using CBA analysis software (BD Bioscience).

2.7. Statistical analyses

Statistical analyses were performed using social sciences software GraphPad Prism 5.0 (GraphPad Software, San Diego, CA). The quantity variables were expressed as mean \pm SD and were performed using a *t*-test or nonparametric test. The numerical variables were expressed as n (%) or median (range), and were analyzed with χ^2 test or Fisher's exact test. Spearman's rank correlation was used to analyze the correlation between MOD of amyloid A and coagulation parameters or cytokines.

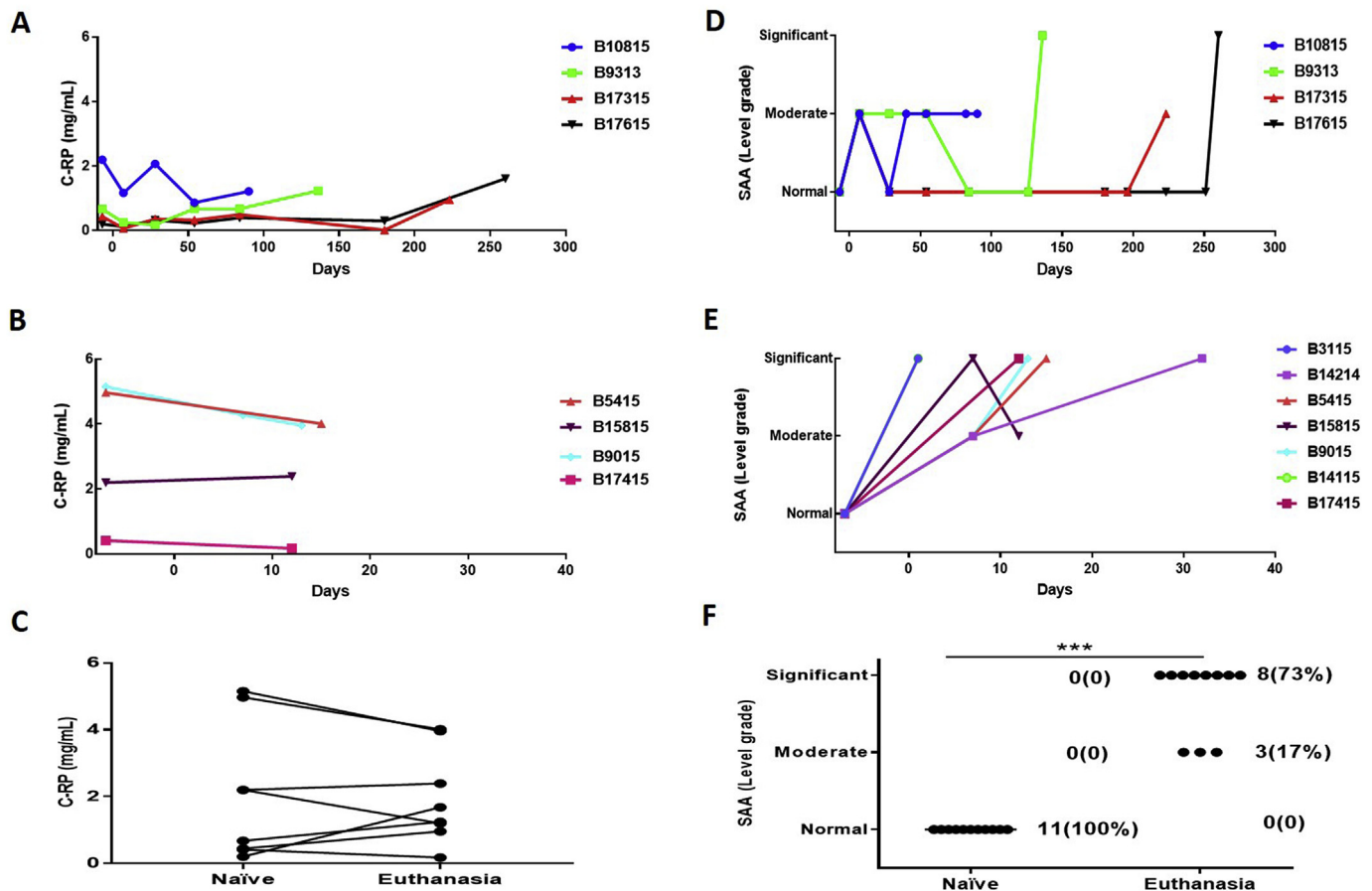


Fig. 2. Serum C-RP (left) and SAA (right) levels in baboons with pig kidney xenografts. (A, B) The levels of C-RP in long-survival (A) and short-survival (B) baboons. (D, E) The levels of SAA in long-survival (D) and short-survival (E) baboons. (C, F) Comparisons of baboon serum C-RP (C) and SAA (F) pre-transplant (naïve) and at euthanasia. Although there was no significant change in the level of C-RP between these two time-points ($p = 0.08$), the level of SAA increased significantly (** $p < 0.001$). (With regard to SAA, the results were categorized as normal [no inflammation], moderate, or significant [severe] inflammation).

Values of $p < 0.05$ were considered statistically significant.

3. Results

3.1. Clinical course

Based on the clinical course and graft histopathology, the baboons were divided into 2 groups – (i) short-term survivors ($n = 7$) and long-term survivors ($n = 4$). In the short-survival group, 1 pig kidney underwent hyperacute rejection, 5 underwent acute humoral xenograft rejection, and 1 was euthanized on day 4 for acute gastric dilatation (Table 1). In the long-survival group, 3 baboons were euthanized for systemic infection, and 1 lost graft function at 90 days when immunosuppressive therapy was reduced too quickly (Table 1). Mean survival in the short survival group was 13 days (range 1–32 days), and in the long-survival group was 181 days (90–260 days).

The baboons that received the anti-CD40 mAb-based immunosuppressive regimen ($n = 6$) included one with acute gastric dilatation (survival 4 days), one that underwent early antibody-mediated rejection with consumptive coagulopathy (as the graft was subsequently found *not* to express a human coagulation-regulatory protein), and 3 that required euthanasia for systemic infection (at 136, 237, and 260 days). Mean survival was 123 days. In those that received conventional immunosuppressive therapy, none survived longer than 32 days, and all underwent either hyperacute ($n = 1$) or acute antibody-mediated ($n = 4$) rejection. Mean survival was 15 days.

3.2. Serum C-RP and SAA levels in baboon recipients

The baboons were divided into two groups based on their survival (a long-survival group: ≥ 90 days ($n = 4$), and a short-survival group: $<$

35 days ($n = 7$) (Fig. 2A, E). SAA levels were measured in 11 baboons and CRP in 8 baboons.

3.2.1. Serum C-RP

As all of the baboons received tocilizumab, no significant increase in C-RP was observed after transplantation, though some increase occurred in the presence of systemic infection (B9313, B17315, B17615) (Fig. 2A and B). Overall, there was no significant difference in the level of C-RP between pre-transplantation (naïve) and at the time of euthanasia (Fig. 2C).

3.2.2. SAA

Before xenotransplantation, the SAA assay indicated no inflammation. In both the long- and short-survival groups, the SAA showed an immediate moderate inflammatory response after the surgical procedure. In the long-survival baboons, there was no further increase (and usually a reduction) until the baboon developed either systemic infection ($n = 3$) or antibody-mediated rejection ($n = 1$) (Fig. 2D). In contrast, in the short-survival group, after the initial increase after the surgical procedure, the SAA continued to increase until the baboon was euthanized for antibody-mediated rejection or acute gastric dilatation (Fig. 2E). In all baboons in both groups, the SAA was increased at the time of euthanasia (moderate inflammation $n = 3$, significant [severe] inflammation $n = 8$) (Fig. 2F).

3.3. C-RP and amyloid A expression in baboon liver tissue

Neither C-RP nor amyloid A was detected in naïve pig livers (negative controls) (Fig. 3A, E). In contrast, both C-RP and amyloid A were intensely expressed in the livers from the experiments considered positive controls (see Methods) (Fig. 3B, C, F, G). In all other baboons,

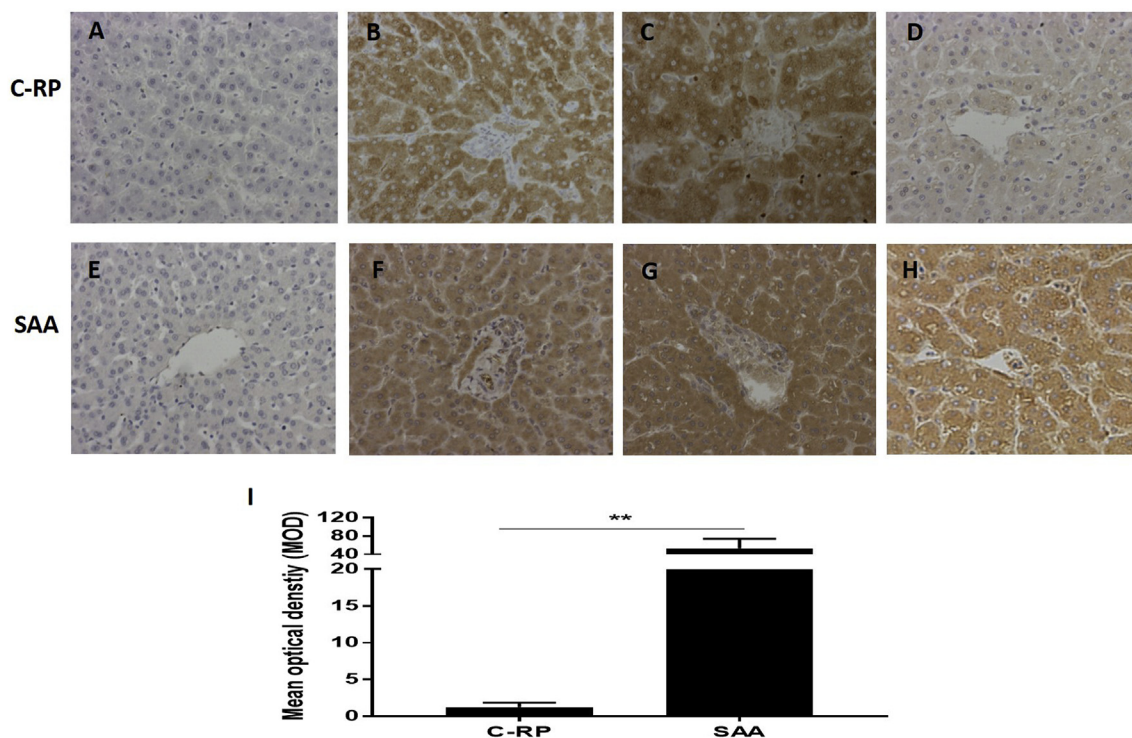


Fig. 3. Expression of C-RP (above) and amyloid A (below) in liver tissue detected by IHC (magnification x200). (A, E) Expression of C-RP and amyloid A in a naïve pig liver (negative control); (B, F) Expression of C-RP and amyloid A in the liver of a baboon that experienced anaphylactic shock (without transplantation) (positive control). (C, G) Expression of C-RP and amyloid A in the liver of a baboon with a pig kidney graft that underwent hyperacute rejection (while receiving the IL-6R inhibitor, tocilizumab, and the TNF- α antagonist, etanercept) (positive control). (D, H) Expression of C-RP and amyloid A in the liver of a representative baboon with a pig kidney graft that was undergoing antibody-mediated rejection (while receiving tocilizumab). There is considerable expression of amyloid A, but not C-RP, in the liver. (I) Comparison of C-RP and amyloid A expression in the livers of baboons with pig kidney grafts (while receiving tocilizumab). The difference in expression is significant (** $p < 0.01$).

expression of amyloid A was much greater than of C-RP (Fig. 3D, H), with the MOD of amyloid A being significantly higher than of C-RP (53 vs 1, $p < 0.01$) (Fig. 3I).

3.4. C-RP and amyloid A deposition in pig kidney tissue

There was no deposition of C-RP or amyloid A in naïve pig kidneys (negative controls) (Fig. 4A, E). In the kidneys considered to be positive controls, deposition of both C-RP and amyloid A was intense (Figs. 4B, C, F, G). In the pig kidneys in all other baboons, deposition of amyloid A, but not C-RP was considerable (Fig. 4D, H), with the MOD of amyloid A being significantly greater than of CRP (24 vs 2, $p < 0.001$) (Fig. 4I).

3.5. Parameters of coagulation and cytokines

In the short-survival baboons, platelet counts and plasma fibrinogen fell rapidly and D-dimer rose, whereas in the long-survival baboons these parameters remained largely stable until infection or rejection occurred [1,2,20]. Compared to naïve baboons, the platelet counts significantly decreased in the short-survival baboons ($p < 0.05$), but this did not occur in the long-survival baboons (Fig. 5A). Plasma fibrinogen levels decreased by the time of euthanasia ($p < 0.05$) (Fig. 5B), and levels of D-dimer were significantly higher at euthanasia than pre-transplantation ($p < 0.01$) (Fig. 5C).

All baboons received the IL-6R inhibitor, tocilizumab, and the TNF- α antagonist, etanercept. The serum level of IL-6 significantly increased after the administration of tocilizumab (Zhang G et al. manuscript in progress). Both the levels of TNF- α and IL-1 β were significantly increased by the day of euthanasia (Fig. 5D, E).

3.6. Correlation between amyloid A expression in baboon livers and coagulation parameters or inflammatory cytokine levels

Our previous study indicated that, in baboons with pig organ grafts, systemic inflammation can activate coagulation [7]. Amyloid A is mostly produced by the liver, and so expression in the baboon liver provides an indication of the state of inflammation in the recipient. Therefore, we investigated correlations between amyloid A expression in the baboon liver with (i) coagulation parameters, and (ii) inflammatory cytokine levels.

Although the plasma fibrinogen level negatively correlated with the expression of amyloid A in the liver ($r = -0.72$, $p < 0.05$) (Fig. 6B), there was no correlation between platelet counts or D-dimer with amyloid A expression (Fig. 6A, C). We could not demonstrate a correlation between the expression of amyloid A in the liver and serum cytokine levels (TNF- α , IL-1 β) (Fig. 6D and E).

Comparison of the results of the SAA assay with (i) expression of amyloid A in the baboon liver and (ii) deposition of amyloid A on the pig kidney graft.

The results of the SAA assay correlated with the expression of amyloid A in the baboon liver (Table 2A) and with the deposition of amyloid A on the pig kidney grafts (Table 2B).

4. Discussion

It is well-known that inflammation leads to activation of the immune system, and is also associated with dysregulation of coagulation [21,22]. After pig kidney xenotransplantation in baboons, inflammation may play an important role in exacerbating the immune response and coagulation dysregulation [7]. Therefore, prevention of, or the early identification and treatment of, inflammation may be important

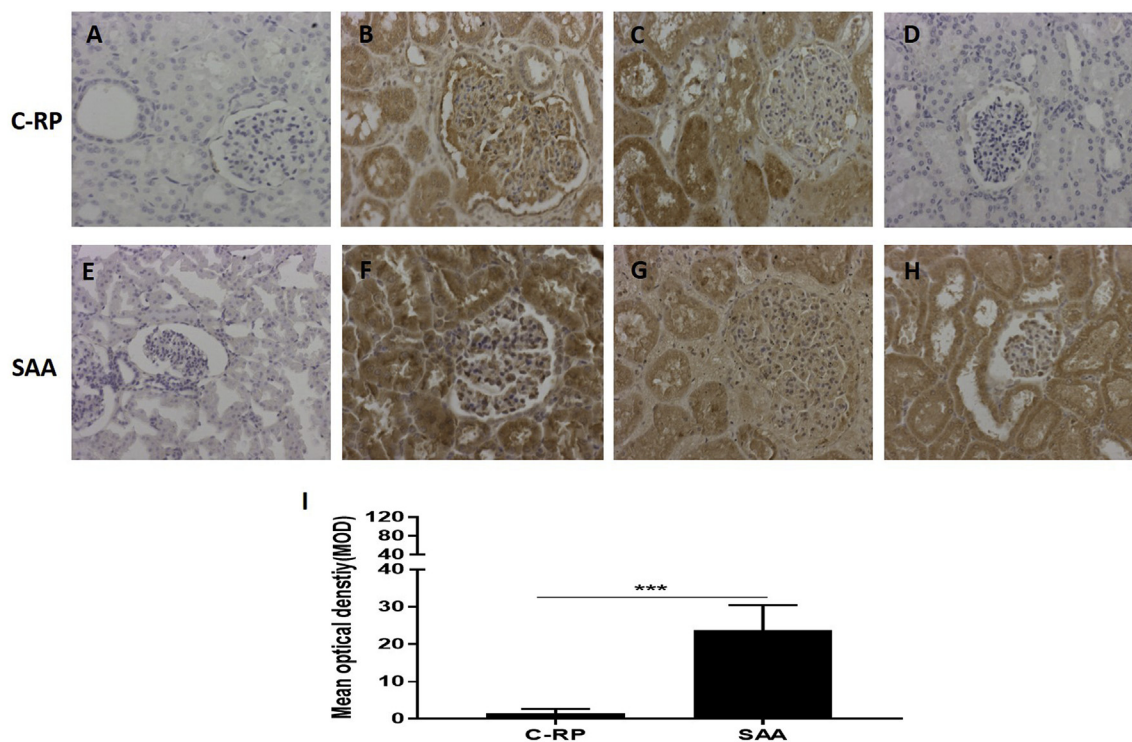


Fig. 4. Deposition of C-RP (above) and amyloid A (below) in kidney tissue detected by IHC (magnification x200). (A, E) Expression of C-RP and amyloid A in a naïve pig kidney (negative control); (B, F) Deposition of C-RP and amyloid A in the kidney in a baboon that experienced anaphylactic shock (without transplantation) (positive control). (C, G) Deposition of C-RP and amyloid A in a pig kidney xenograft that underwent hyperacute rejection after transplantation into a baboon (while receiving the IL-6R inhibitor, tocilizumab, and the TNF- α antagonist, etanercept) (positive control). (D, H) Deposition of C-RP and amyloid A in a representative pig kidney xenograft (in a baboon with rejection, while receiving tocilizumab). There is considerable deposition of amyloid A, but not C-RP, in the kidney. (I) Comparison of C-RP and amyloid A deposition in pig kidney xenografts in baboons (that were receiving tocilizumab). The difference in deposition is significant (** $p < 0.001$).

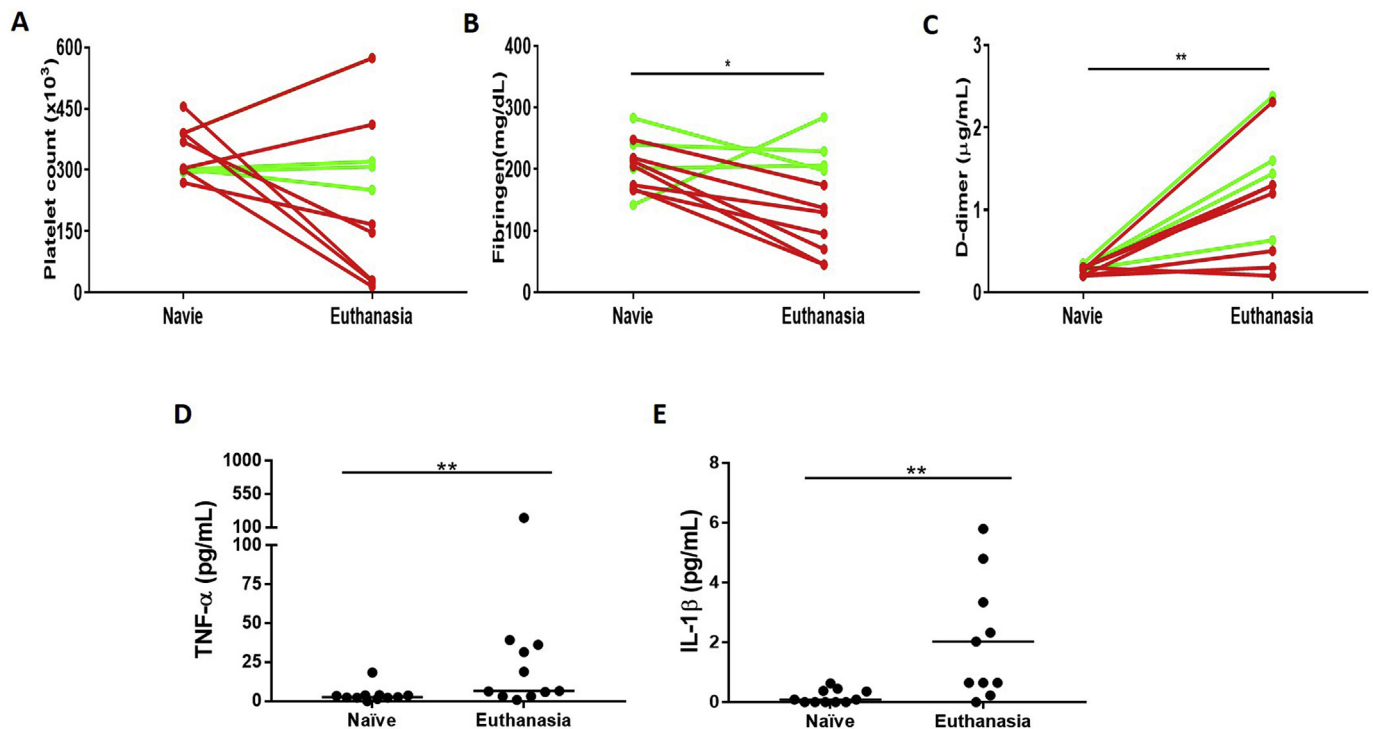


Fig. 5. Comparisons of selected coagulation parameters or cytokine levels in baboons with pig kidney grafts. (A, B, C) Comparison of platelet count (left), plasma fibrinogen (middle), and D-dimer (right) at 2 time-points (pre-transplantation [Naïve] and at euthanasia). The plasma fibrinogen was significantly decreased (*p < 0.05) and the D-dimer was significantly increased by the day of euthanasia (**p < 0.01). (Red lines = short-survival baboons; green lines = long-survival baboons.) (D, E) Comparison of serum TNF-α (left) and serum IL-1β (right) in baboons (receiving tocilizumab) at 2 time-points (pre-transplantation [Naïve] and at euthanasia). Both TNF-α and IL-1β were significantly increased at euthanasia (**p < 0.01). (For interpretation of the references to color in this figure legend, the reader is referred to the Web version of this article.)

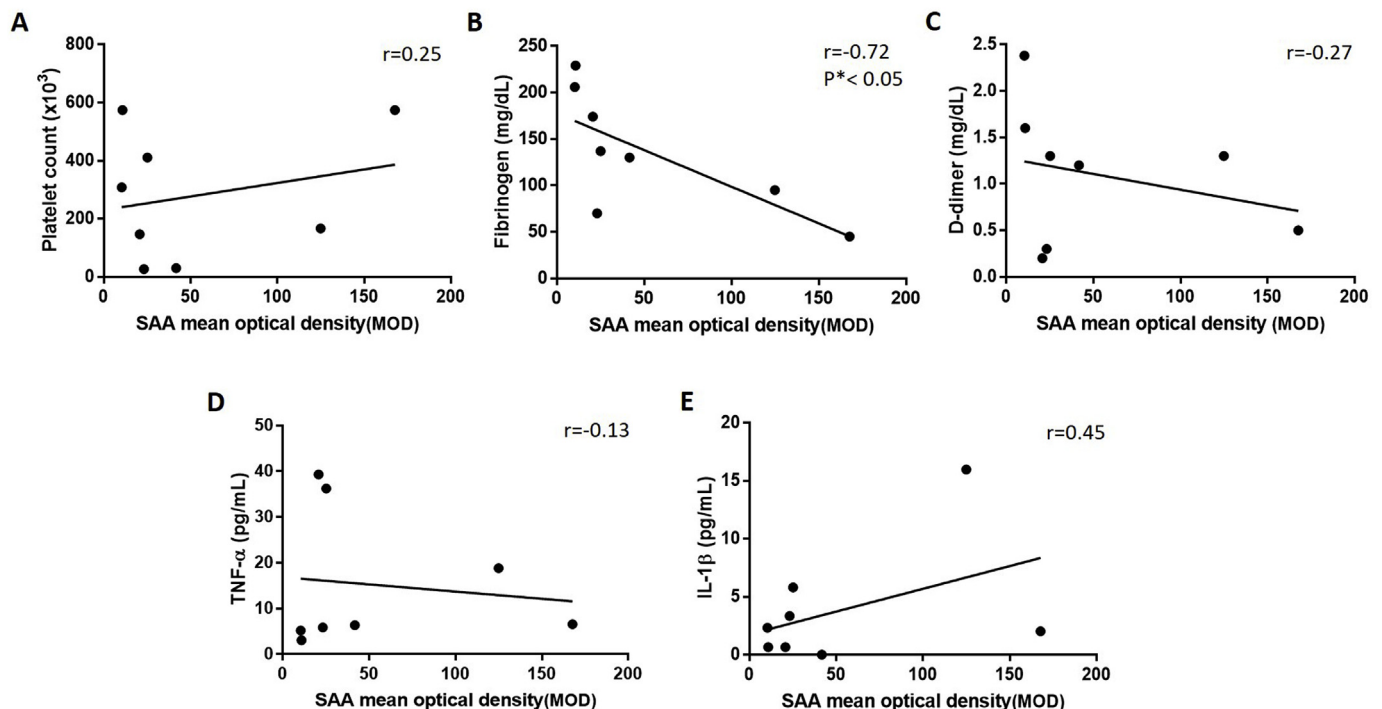


Fig. 6. Correlation between amyloid A expression in the livers of baboons (with pig kidney xenografts) and selected coagulation parameters and serum cytokine levels. (A, B, C) Correlation of the expression of amyloid A in the baboon liver (n = 8) with platelet count (left), plasma fibrinogen (middle), and D-dimer (right). The expression of amyloid A in the baboon liver negatively correlated with the change in plasma fibrinogen ($r = -0.72$, *p < 0.05). (D, E) Correlation of amyloid A expression in the baboon liver with TNF-α and IL-1β. The expression of amyloid A in the baboon liver did not correlate significantly with the change in TNF-α ($r = -0.13$, p > 0.05) or IL-1β ($r = 0.45$, p > 0.05).

Table 2

Comparison of the results of the SAA assay with (A) amyloid A expression in the recipient baboon livers, and (B) amyloid A deposition in the pig kidney grafts.

A			
Degree of inflammation	SAA	Amyloid A expression (IHC)	P (SAA vs IHC)
	Serum (n = 8) n (%)	Liver (n = 8) n (%)	
Significant	6 (75)	7 (88)	NS
Moderate	2 (25)	1 (12)	
Normal or negative	0 (0)	0 (0)	
B			
Degree of inflammation	SAA	Amyloid A deposition (IHC)	P (SAA vs IHC)
	Serum (n = 11) n (%)	Kidney (n = 11) n (%)	
Significant	8 (73)	10 (91)	NS
Moderate	3 (27)	0 (0)	
Normal or negative	0 (0)	1 (9)	

in prolonging survival of pig organ xenografts.

Measurement of serum C-RP is considered a sensitive marker of inflammation, and is monitored in inflammatory diseases [23]. In human organ allotransplantation, C-RP has been monitored to detect inflammation [24–26]. In pig organ xenotransplantation, our previous studies indicated that C-RP was a sensitive marker of acute inflammation [7], but, if the baboon recipients received the IL-6R inhibitor, tocilizumab, monitoring of C-RP no longer provided an indication of the state of the inflammatory response [5,8,27]. In vitro studies in our laboratory have confirmed this observation, and have also demonstrated that IL-6-neutralizing antibodies, e.g., sultixumab, also negate C-RP's value as a marker of inflammation (Zhang G et al., manuscript in preparation).

In the present study, in the presence of tocilizumab therapy, the level of C-RP did not significantly increase after pig kidney transplantation, unless terminal severe systemic infection developed, and thus was not a sensitive marker of the state of inflammation. Studies by others have indicated that SAA may be a more sensitive marker of inflammation than C-RP [14,28], and so we monitored SAA in baboons undergoing pig kidney transplantation.

The level of SAA increased as a response to the surgical stress of kidney transplantation, but then decreased if the immunosuppressive therapy was fully effective (anti-CD40 mAb-based regimen), but increased when the regimen was ineffective (conventional therapy) resulting in graft failure. Although a rise in SAA was not specific for rejection (as it occurred when a systemic infectious complication or acute gastric dilatation developed), it would at least inform us that an inflammatory response is developing, alerting us to the need for more intensive investigation (e.g., blood culture, graft biopsy) as to the cause, thus enabling us to take therapeutic steps to reverse the complication.

In our previous study, severe inflammation was associated with antibody-mediated rejection, whether this was early or late in the course of graft survival and whether it was related to inadequate immunosuppressive therapy or absence of expression of a human coagulation-regulatory protein in the graft. Whether the inflammatory response was a causative factor in the development of rejection or merely secondary to the response, remains uncertain, though Ezzelarab et al. provided evidence that inflammation precedes the coagulation dysfunction seen in baboons with xenografts [7], suggesting that inflammation is a causative factor. In the present study, there was some correlation between SAA level and parameters known to indicate impending xenograft failure, e.g., a falling plasma fibrinogen.

Both SAA and CRP are acute phase proteins, produced largely in cells of hepatic origin, that can be induced by a variety of stimuli, including IL-6, TNF- α , and IL-1 β [29–31]. The present study indicates that, in the presence of tocilizumab therapy, the production of C-RP, but not SAA, is inhibited. This difference may be related to (i) C-RP being more specifically stimulated by IL-6 than SAA, or (ii) SAA being more sensitive to cytokine stimulation than C-RP [32], and therefore its production not being inhibited so much by tocilizumab. Although in the present study we did not document a significant correlation between SAA and IL-1 β , it is possible that IL-1 β or other cytokines stimulate SAA production more than they stimulate C-RP production. We have been unable to find any reports in the literature that clarify this point.

There are several methods for measuring SAA, e.g., radio-immunoassay (RIA), enzyme-linked immunosorbent assay (ELISA), and microsphere capture enzyme immunoassay (MEIA). In the present study, we used a simple, rapid, and sensitive assay that can measure SAA in blood or serum, and does not require special equipment. The results of the assay appeared to correlate well with the findings of immunohistochemistry. The assay has recently been modified by the manufacturer to enable it to be more quantitative, with 4 (rather than 3) grades of inflammation now being differentiated. This modification should allow better differentiation between mild, moderate, and severe inflammation, and may possibly identify differences in the response between antibody-mediated rejection and other causes of inflammation, e.g., infection.

In conclusion, our study indicated that SAA is a simple, rapid, relatively inexpensive, and sensitive marker of inflammation in baboons with pig organ xenografts, even when they received anti-inflammatory therapy in the form of the IL-6R blockade agent, tocilizumab. In this respect, it proved a more valuable marker than C-RP. However, it was non-specific and did not differentiate between graft rejection and systemic infection. However, when carried out prospectively, it should prove useful in alerting us to the fact that an inflammatory response is developing or increasing, enabling further investigation of the cause and introduction of suitable therapy.

Disclosure of conflict of interest

No author has a conflict of interest.

Provenance and peer review

Not Commissioned, internally reviewed.

Data statement

The data will be made available on request.

Ethical approval

Protocols were approved by the University of Pittsburgh and University of Alabama at Birmingham Institutional Animal Care and Use Committees (IACUC 20673). All animal care was in accordance with the Guide for the Care and Use of Laboratory Animals prepared by the National Research Council (8th edition, revised 2011), and was conducted in an AAALAC-accredited facility.

Sources of funding

Guoqiang Zhang is supported by the Ph.D. student foreign visiting program project from Nanchang University in China. Work on xenotransplantation at the University of Alabama at Birmingham is supported in part by NIH NIAID U19 grant AI090959. Some of the baboons used in the study were from the University of Oklahoma Health Sciences Center, Division of Animal Resources, which was supported by NIH P40 sponsored grant RR012317-09.

Author contribution

GuoQiang is the first author, Hayato Iwase and Yong Li are joint corresponding Author. Hayato Iwase and Yong Li designed the research and supervised the experiment; Guoqiang Zhang finished experiment, analyzed the data and drafted the article; Takayuki Yamamoto, Qi Li and Abhijit Jagdale assisted to collect samples. David K.C. Cooper and Hidetaka Hara revised the article, David K.C. Cooper, Hayato Iwase and Yong Li approved the final version of the article; All authors have read and approved the final version to be published.

Research registry number

N/A.

Guarantor

Hayato Iwase, Yong Li, Guoqiang Zhang.

Acknowledgements

We thank Dr. Keith Reimann for providing anti-CD40mAb from the NIH NHP Reagent Resource (contract HHSN2722001300031C), funded by A1126683 and OD010976.

Appendix A. Supplementary data

Supplementary data to this article can be found online at <https://doi.org/10.1016/j.ijssu.2018.11.027>.

References

- [1] H. Iwase, H. Liu, M. Wijkstrom, et al., Pig kidney graft survival in a baboon for 136 days: longest life-supporting organ graft survival to date, *Xenotransplantation* 22 (2015) 302–309.
- [2] H. Iwase, H. Hara, M. Ezzelarab, et al., Immunological and physiological observations in baboons with life-supporting genetically engineered pig kidney grafts, *Xenotransplantation* 24 (2) (2017), <https://doi.org/10.1111/xen.12293>.
- [3] L. Higginbotham, D. Mathews, C.A. Breeden, et al., Pre-transplant antibody screening and anti-CD154 costimulation blockade promote long-term xenograft survival in a pig-to-primate kidney transplant mode, *Xenotransplantation* 22 (2015) 221–230.
- [4] M.M. Mohiuddin, A.K. Singh, P.C. Corcoran, et al., Chimeric 2C10R4 anti-CD40 antibody therapy is critical for long-term survival of GTKO.hCD46.hTBM pig-to-primate cardiac xenograft, *Nat. Commun.* 7 (2016) 11138.
- [5] H. Iwase, B. Ekser, H. Zhou, et al., Further evidence for sustained systemic inflammation in xenograft recipients (SIXR), *Xenotransplantation* 22 (2015) 399–405.
- [6] M.B. Ezzelarab, D. Cooper, Systemic inflammation in xenograft recipients (SIXR): a new paradigm in pig-to-primate xenotransplantation? *Int. J. Surg.* 23 (Pt B) (2015) 301–305.
- [7] M.B. Ezzelarab, B. Ekser, A. Azimzadeh, et al., Systemic inflammation in xenograft recipients precedes activation of coagulation, *Xenotransplantation* 22 (2015) 32–47.
- [8] T. Li, W. Lee, H. Hara, et al., An investigation of extracellular histones in pig-to-baboon organ xenotransplantation, *Transplantation* 101 (2017) 2330–2339.
- [9] T. Li, H. Hara, M.B. Ezzelarab, et al., Serum amyloid A as a marker of inflammation in xenotransplantation, *Eur. J. Inflamm.* (2018), <https://doi.org/10.1177/2058739218780046>.
- [10] A.J. Lepedda, G. Nieddu, E. Zinellu, et al., Proteomic analysis of plasma-purified VLDL, LDL, and HDL fractions from atherosclerotic patients undergoing carotid endarterectomy: identification of serum amyloid A as a potential marker, *Oxid. Med. Cell Longev.* 2013 (2013) 385214, <https://doi.org/10.1155/2013/385214>.
- [11] J. Qu, X. L. Y. Liu, et al., Evaluation of procalcitonin, C-reactive protein, interleukin-6 & serum amyloid A as diagnostic biomarkers of bacterial infection in febrile patients, *Indian J. Med. Res.* 141 (2015) 315–321.
- [12] X.Y. Zhang, G. Zhang, Y. Jiang, et al., The prognostic value of serum C-reactive protein-bound serum amyloid A in early-stage lung cancer, *Chin. J. Canc.* 34 (2015) 335–349.
- [13] Y.G. Hwang, G.K. Balasubramani, I.D. Metes, et al., Differential response of serum amyloid A to different therapies in early rheumatoid arthritis and its potential value as a disease activity biomarker, *Arthritis Res. Ther.* 18 (1) (2016) 108, <https://doi.org/10.1186/s13075-016-1009-y>.
- [14] G. Feussner, C. Stech, J. Dobmeyer, et al., Serum amyloid A protein (SAA): a marker for liver allograft rejection in humans, *Clin. Invest.* 72 (1994) 1007–1011.
- [15] A. Hartmann, T.C. Eide, P. Fauchald, et al., Serum amyloid A protein is a clinically useful indicator of acute renal allograft rejection, *Nephrol. Dial. Transplant.* 12 (1997) 161–166.
- [16] T.F. Muller, M. Vogl, M.C. Neumann, et al., Noninvasive monitoring using serum amyloid A and serum neopterin in cardiac transplantation, *Clin. Chim. Acta* 276 (1998) 63–74.
- [17] A.H. Walker, B.G. Keevil, N. Yonan, An investigation of the correlation between C-reactive protein, serum amyloid A concentration, and cardiac allograft rejection, *Transplant. Proc.* 34 (2002) 1279–1280.
- [18] M. Ezzelarab, B. Garcia, A. Azimzadeh, et al., The innate immune response and activation of coagulation in alpha1,3-galactosyltransferase gene-knockout xenograft recipients, *Transplantation* 87 (2009) 805–812.
- [19] M.B. Ezzelarab, B. Ekser, G. Echeverri, et al., Costimulation blockade in pig artery patch xenotransplantation - a simple model to monitor the adaptive immune response in nonhuman primates, *Xenotransplantation* 19 (2012) 221–232.
- [20] Yamamoto T, Hara H, Wang L, et al. Kidney Xenotransplantation from Genetically-engineered Pigs in Baboons: a Comparison of Two Immunosuppressive Regimens. (submitted for publication).
- [21] M. Levi, T.T. Keller, E. van Gorp, et al., Infection and inflammation and the coagulation system, *Cardiovasc. Res.* 60 (2003) 26–39.
- [22] S. Shrivastava, J.H. Mcvey, A. Dorling, The interface between coagulation and immunity, *Am. J. Transplant.* 7 (2007) 499–506.
- [23] W.S. Tillett, T. Francis, Serological reactions in pneumonia with a non-protein somatic fraction of pneumococcus, *J. Exp. Med.* 52 (1930) 561–571.
- [24] D.O. Dahle, G. Mjoen, B. Oqvist, et al., Inflammation-associated graft loss in renal transplant recipients, *Nephrol. Dial. Transplant.* 26 (2011) 3756–3761.
- [25] L. Minculescu, B.T. Kornblit, L.S. Friis, et al., C-reactive protein levels at diagnosis of acute graft-versus-host disease predict steroid-refractory disease, treatment-related mortality, and overall survival after allogeneic hematopoietic stem cell transplantation, *Biol. Blood Marrow Transplant.* 24 (2018) 600–607.
- [26] H. Oweira, I. Lahdou, V. Daniel, et al., Early post-operative acute phase response in patients with early graft dysfunction is predictive of 6-month and 12-month mortality in liver transplant recipients, *Hum. Immunol.* 77 (2016) 952–960.
- [27] B.H. Min, J.S. Shin, J.M. Kim, et al., Delayed revascularization of islets after transplantation by IL-6 blockade in pig to non-human primate islet xenotransplantation model, *Xenotransplantation* 25 (1) (2018), <https://doi.org/10.1111/xen.12374>.
- [28] E. Malle, F.C. De Beer, Human serum amyloid A (SAA) protein: a prominent acute-phase reactant for clinical practice, *Eur. J. Clin. Invest.* 26 (1996) 427–435.
- [29] C.F. Thorn, Z.Y. Lu, A.S. Whitehead, Regulation of the human acute phase serum amyloid A genes by tumour necrosis factor-alpha, interleukin-6 and glucocorticoids in hepatic and epithelial cell lines, *Scand. J. Immunol.* 59 (2004) 152–158.
- [30] M.R. Edbrooke, J. Foldi, J.K. Cheshire, et al., Constitutive and NF-kappa B-like proteins in the regulation of the serum amyloid A gene by interleukin 1, *Cytokine* 3 (1991) 380–388.
- [31] R.R. Giris, A. Ciarleglio, T. Choo, et al., A randomized, double-blind, placebo-controlled clinical trial of tocilizumab, an interleukin-6 receptor antibody, for residual symptoms in schizophrenia, *Neuropsychopharmacology* 43 (2018) 1317–1323.
- [32] T. Yamada, Serum amyloid A (SAA): a concise review of biology, assay methods and clinical usefulness, *Clin. Chem. Lab. Med.* 37 (1999) 381–388.