



Letter to the Editor

MitraClip after heart transplantation: A case report



Annamaria Iorio ^{*}, Concetta Di Nora, Elena Abate, Bruno Pinamonti, Serena Rakar, Giancarlo Vitrella, Vincenzo Tursi, Ugolino Livi, Alessandro Salvi, Gianfranco Sinagra

Cardiovascular Department "Ospedali Riuniti and University of Trieste", Trieste, Italy
Department of Cardiology, Santa Maria della Misericordia Hospital, Udine, Italy

ARTICLE INFO

Article history:

Received 19 October 2014

Accepted 21 October 2014

Available online 22 October 2014

Keywords:

Heart transplantation

Mitral regurgitation

Mitral valve repair

MitraClip

Mitral regurgitation after heart transplantation is not a rare finding, leading often to overt heart failure and poor clinical outcome [1,2]. Medical management can be an unsuccessful strategy, and a redo-surgery could represent a high risk. Percutaneous mitral valve repair using MitraClip has been shown as a safe technique in high surgical risk patients with functional and degenerative mitral regurgitation [3,4]; however, it has been never reported in heart transplanted. We describe for the first time a patient with heart transplantation and severe mitral regurgitation treated with MitraClip.

A 72-year-old man underwent heart transplantation for end-stage ischemic heart disease. One year later he was admitted to our hospital for congestive heart failure (New York Heart Association functional class IV). His medical history was also notable for hypertension, mild kidney disease, chronic anemia and peripheral vascular disease. During the first 3 months after transplantation, routine endomyocardial biopsies revealed mild rejection (grade IIA) that was resolved (grade \leq IA) with increased immunosuppressive therapy. At admission, a 4/6 holosystolic murmur was detected in mitral area. Transthoracic echocardiography showed normal biventricular function and a severe eccentric mitral regurgitation jet related to a prolapse of the posterior leaflet (P1–P2) with incomplete systolic coaptation (leaflets systolic separation: 0.5 cm; jet area: 13.2 cm², vena contracta: 0.7 cm, effective regurgitant orifice area at proximal isovelocity surface area method: 0.41 cm²) (Fig. 1A and B). These data were subsequently confirmed

with transesophageal echocardiography (Fig. 1C and D, Clip 1). Considering the high risk of redo-surgery, the local "Heart Team" decided for percutaneous treatment. Under general anesthesia and conventional fluoroscopy, with continuous invasive hemodynamic monitoring and two-three dimensional transesophageal echocardiography, a single MitraClip was implanted (Fig. 1E). An immediate hemodynamic improvement (stroke volume index from 47 to 63 ml/m²; pulmonary wedge pressures from 26 to 16 mm Hg; complete V-wave disappearance) was observed.

Echocardiography documented a mild residual mitral regurgitation (Fig. 1F, Clip 2). The patient had an uneventful recovery and was discharged asymptomatic six days after MitraClip implantation.

To our knowledge, this is the first report of MitraClip implantation in a transplanted heart. This case demonstrates the feasibility of the technique even in the "distorted" anatomy of orthotopic heart transplantation. Therefore, given the high risk of redo-surgery, MitraClip can be considered in severe mitral regurgitation of heart transplanted patients, where medical therapies are unsatisfactory. This case report suggests that MitraClip could be highly effective in this subset of patients.

Supplementary data to this article can be found online at <http://dx.doi.org/10.1016/j.ijcard.2014.10.099>.

Disclosures

No conflict of interest.

References

- [1] M. Cladellas, A. Oriol, U. Caralps, Quantitative assessment of valvular function after cardiac transplantation by pulsed Doppler echocardiography, *Am. J. Cardiol.* 73 (1994) 1197–1201.
- [2] E. Roig, A. Jacobo, M. Sitges, I. Vallejos, C. Pare, F. Pons, J. Serra, M. Azqueta, J.L. Pomar, F. Perez-Villa, Clinical implications of late mitral valve regurgitation appearance in the follow-up of heart transplantation, *Transplant. Proc.* 39 (2007) 2379–2381.
- [3] P.L. Whitlow, T. Feldman, W.R. Pedersen, D.S. Lim, R. Kipperman, R. Smalling, T. Bajwa, H.C. Herrmann, J. Lasala, J.T. Maddux, M. Tuzcu, S. Kapadia, A. Trento, R.J. Siegel, E. Foster, D. Glower, L. Mauri, S. Kar, EVEREST II Investigators, Acute and 12-month results with catheter-based mitral valve leaflet repair: the EVEREST II (Endovascular Valve Edge-to-Edge Repair) High Risk Study, *J. Am. Coll. Cardiol.* 59 (2012) 130–139.
- [4] L. Mauri, E. Foster, D. Glower, P. Apruzzese, J. Massaro, H. Herrmann, J. Hermiller, W. Gray, A. Wang, W. Pedersen, T. Bajwa, J. Lasala, R. Low, P. Grayburn, T. Feldman, EVEREST II Investigators, 4-year results of a randomized controlled trial of percutaneous repair versus surgery for mitral regurgitation, *J. Am. Coll. Cardiol.* 62 (4) (2013) 317–328.

^{*} Corresponding author at: Cardiovascular Department, "Ospedali Riuniti and University of Trieste", Via Valdoni 1, 34149 Trieste, Italy.

E-mail address: anita.iorio@hotmail.it (A. Iorio).

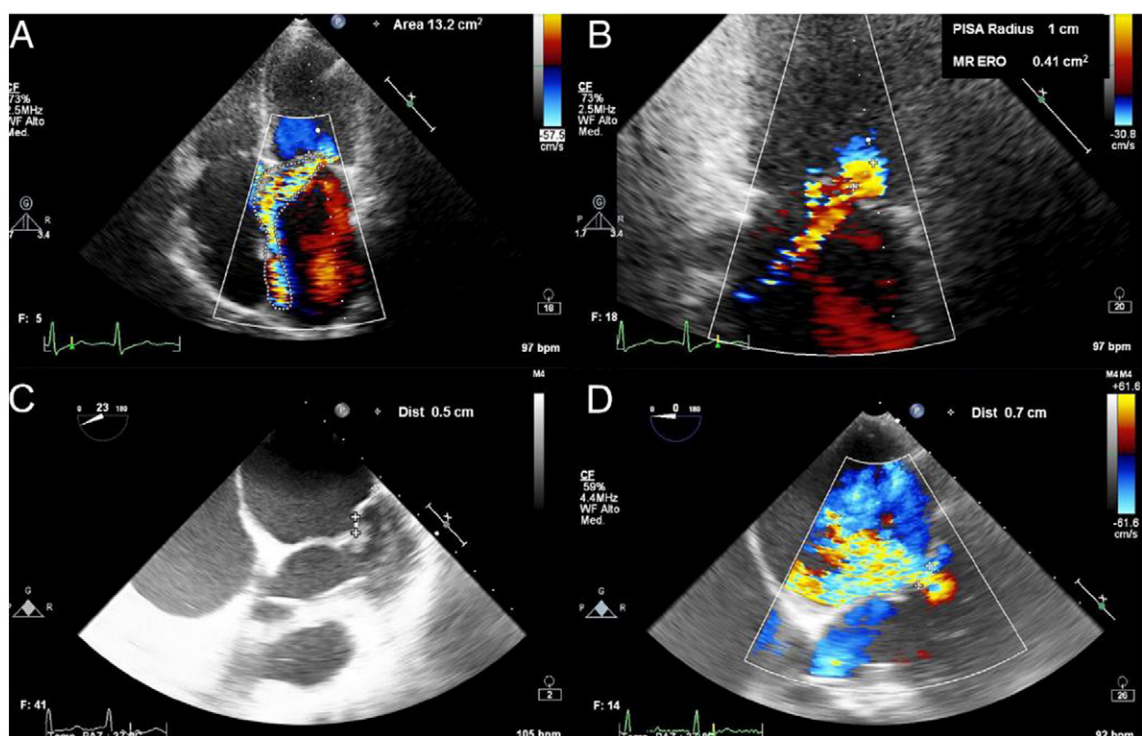


Fig. 1. Transthoracic echocardiography showing a severe eccentric mitral regurgitation jet (panels A and B). The transesophageal study documented posterior mitral leaflet prolapse (P1–P2), with a flail gap of 0.5 cm (panel C) and confirmed the severity of mitral regurgitation (vena contracta of 0.7 cm at color Doppler, panel D). Panel E: three-dimensional echocardiography monitoring the position of the MitraClip above the mitral valve during the procedure. Panel F: mild residual mitral regurgitation after MitraClip implantation. ERO, effective regurgitant orifice, MR, mitral regurgitation, PISA, proximal isovelocity surface area.