

IMAGES IN INTERVENTION

Spontaneous Coronary Artery Dissection

Failure of the Conservative Strategy Due to Predominance of the False Lumen

Felipe Díez-Delhoyo, MD, Ricardo Sanz-Ruiz, MD, Fernando Sarnago-Cebada, MD, Enrique Gutiérrez-Ibañes, MD, PhD, Allan Rivera-Juárez, MD, Jaime Elízaga, MD, PhD, Francisco Fernández-Avilés, MD, PhD



A 50-year-old woman with an inferior ST-segment elevation myocardial infarction was transferred to our institution. Urgent coronary angiography demonstrated several intraluminal filling defects in the proximal segment of the right coronary artery (RCA) (**Figure 1A**, **Online Video 1**), eventually interpreted as thrombi. However, after aspiration, multiple radiolucent lumens together with arterial wall contrast staining were observed. Optical coherence tomography imaging confirmed a type 1 spontaneous coronary artery dissection (SCAD), with the true arterial lumen (TL) compressed by the false lumen (FL) at several points (**Figures 1B and 1C**). Interestingly, intimal-medial layers were severely fragmented and exposed to the blood flow. Being the patient asymptomatic, with normalized ST-segment elevation and normal RCA flow, a conservative management with dual antiplatelet therapy was decided according to general consensus (1).

Four days later a routine angiography confirmed normal epicardial flow (**Figure 1D**, **Online Video 2**). An intraluminal flap was evident, and optical coherence tomography revealed that the FL had completely obstructed the TL (**Figure 1E**). Again, conservative

treatment was decided for the same aforementioned reasons.

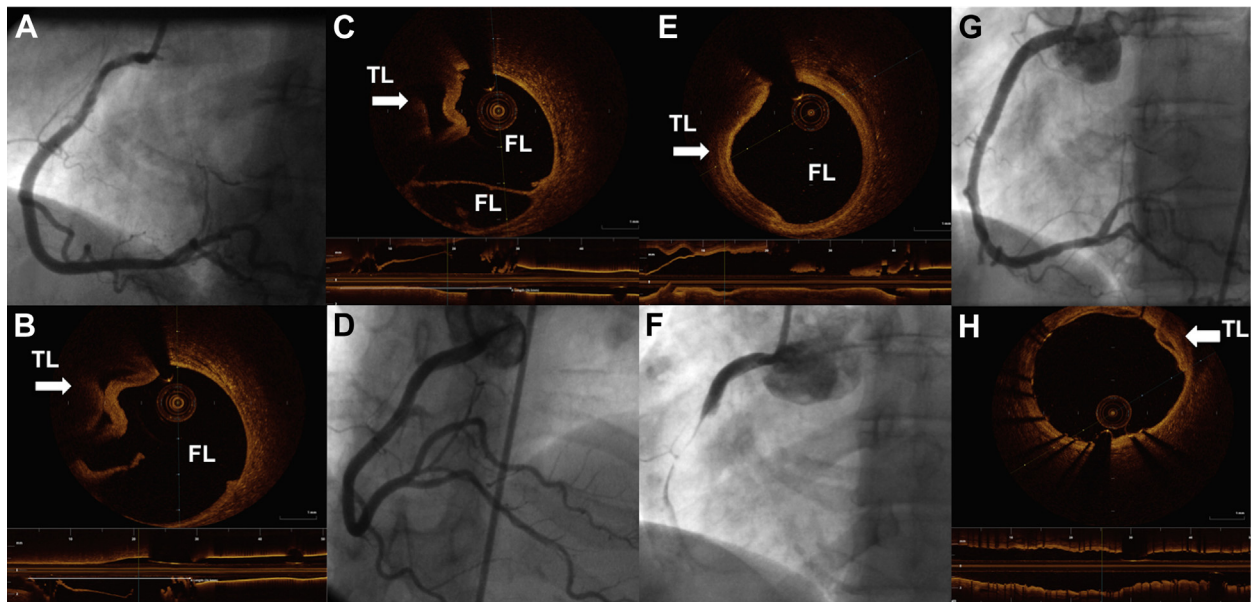
Twenty-four hours later the patient suddenly developed chest pain and inferior ST-segment elevation. An acute occlusion of the RCA was demonstrated on emergent angiography (**Figure 1F**, **Online Video 3**), and 3 drug-eluting stents were implanted, eventually crushing the TL (**Figures 1G and 1H**, **Online Video 4**). Clinical course afterward and 1 year later has been uneventful.

Percutaneous coronary intervention is recommended in SCAD patients when high-risk features are present (1). Significant media exposure and massive intima dissection are not traditionally recognized as indications for stenting despite their prothrombotic potential. Because definitive indications of a conservative strategy in SCAD patients remain unsettled, we hereby hypothesize that predominance of the FL may warrant a more aggressive strategy with stent implantation, if technically feasible.

ADDRESS FOR CORRESPONDENCE: Dr. Ricardo Sanz-Ruiz, Department of Cardiology, Hospital General Universitario Gregorio Marañón, Doctor Esquerdo, 46, 28007 Madrid, Spain. E-mail: rsanzruiz@hotmail.com.

From the Department of Cardiology, Hospital General Universitario Gregorio Marañón, Instituto de Investigación Sanitaria del Hospital Gregorio Marañón, Complutense University of Madrid, Madrid, Spain. The authors have reported that they have no relationships relevant to the contents of this paper to disclose.

Manuscript received April 17, 2017; accepted April 28, 2017.

FIGURE 1 Evolution of the Dissection During the First Five Days by Invasive Imaging

Angiographic and optical coherence tomography findings in the right coronary artery at the 3 time points: **(A to C)** admission ([Online Video 1](#)), **(D, E)** day 4 ([Online Video 2](#)), and **(F to H)** day 5 ([Online Videos 3 and 4](#)) findings. **White arrows** show true lumen (TL). FL = false lumen.

REFERENCE

1. Saw J, Mancini GB, Humphries KH. Contemporary review on spontaneous coronary artery dissection. *J Am Coll Cardiol* 2016; 68:297–312.

KEY WORDS conservative management, optical coherence tomography, percutaneous coronary intervention, spontaneous coronary artery dissection

APPENDIX For supplemental videos and their legends, please see the online version of this article.