

THE PRESENT AND FUTURE

REVIEW TOPIC OF THE WEEK

The Early Repolarization Pattern

A Consensus Paper



Peter W. Macfarlane, DSc,* Charles Antzelevitch, PhD,† Michel Haissaguerre, MD,‡ Heikki V. Huikuri, MD, PhD,§ Mark Potse, PhD,|| Raphael Rosso, MD,¶ Frederic Sacher, MD,‡ Jani T. Tikkanen, MD, PhD,§ Hein Wellens, MD,# Gan-Xin Yan, MD, PhD**

ABSTRACT

The term *early repolarization* has been in use for more than 50 years. This electrocardiographic pattern was considered benign until 2008, when it was linked to sudden cardiac arrest due to idiopathic ventricular fibrillation. Much confusion over the definition of early repolarization followed. Thus, the objective of this paper was to prepare an agreed definition to facilitate future research in this area. The different definitions of the early repolarization pattern were reviewed to delineate the electrocardiographic measures to be used when defining this pattern. An agreed definition has been established, which requires the peak of an end-QRS notch and/or the onset of an end-QRS slur as a measure, denoted Jp, to be determined when an interpretation of early repolarization is being considered. One condition for early repolarization to be present is Jp \geq 0.1 mV, while ST-segment elevation is not a required criterion. (J Am Coll Cardiol 2015;66:470-7)
© 2015 by the American College of Cardiology Foundation.

The electrocardiographic (ECG) pattern of early repolarization has historically been regarded as a benign ECG variant. However, during the past few years, this concept has been challenged on the basis of multiple reports linking the early repolarization pattern in the inferior and/or lateral leads of the standard 12-lead ECG with an increased risk for sudden cardiac death (1,2). Case-control studies have unanimously shown that patients resuscitated from cardiac arrest of unknown etiology have a higher prevalence of the ECG pattern of early repolarization in the inferior and/or lateral leads (i.e., the early repolarization syndrome) than matched control subjects. Epidemiological follow-up studies have also shown that the early repolarization pattern carries an increased risk for future arrhythmic

death (3,4). Therefore, the recognition and correct diagnosis of the ECG pattern of early repolarization has importance for specialists, general cardiologists, and physicians.

The ECG term *early repolarization* has been in use by cardiologists for almost 40 years. Its exact definition has varied according to different investigators, so much so that a recent review (5) showed that the prevalence of early repolarization apparently varied between 2% and 31%. One definition of early repolarization, published in 1976 by Kambara and Phillips (6), which built on earlier work by Wasserburger and Alt (7), suggested that early repolarization was defined by: 1) end-QRS notching or slurring; 2) elevation of the ST-segment; and 3) an upward-sloping ST-segment followed by a tall, symmetrical

From the *Institute of Cardiovascular and Medical Sciences, Electrocardiology Section, University of Glasgow, Glasgow, United Kingdom; †Cardiovascular Research Program, Lankenau Institute for Medical Research, Wynnewood, Pennsylvania; ‡Bordeaux University Hospital, LIRYC Institute, INSERM 1045, Bordeaux University, Bordeaux, France; §Medical Research Center Oulu, Oulu University Central Hospital, and University of Oulu, Oulu, Finland; ||Inria Bordeaux Sud-Ouest, 33405 Talence cedex, France; ¶Tel Aviv Sourasky Medical Center, Tel Aviv, Israel; #Department of Cardiology, University of Maastricht, the Netherlands; and the **Lankenau Institute for Medical Research, Wynnewood, Pennsylvania. The authors have reported that they have no relationships relevant to the contents of this paper to disclose.

[Listen to this manuscript's audio summary by JACC Editor-in-Chief Dr. Valentin Fuster.](#)

Manuscript received February 5, 2015; revised manuscript received April 21, 2015, accepted May 18, 2015.



T-wave. However, many cardiologists have reported the presence of ST-segment elevation alone, most commonly in the inferior and lateral leads in younger persons, as being consistent with early repolarization. This view can be found in respected textbooks on ECG (8).

In the seminal study of Haissaguerre et al. (1), the investigators defined early repolarization as “an elevation of the QRS-ST-segment junction (J-point) in at least 2 leads” (within the same territory; e.g., inferior or lateral leads) as being a sign of early repolarization. The amplitude of the J-point elevation had to be at least 0.1 mV above the baseline level, as either QRS slurring or notching. The amplitude and slope of the ST-segment were not part of the definition.

In subsequent papers, Tikkanen et al. (3,4) followed this definition but also measured the degree of so-called J-point elevation, which was stratified at levels of 0.1 and 0.2 mV. These investigators also introduced the concept of the ST-segment slope having significance in the presence of early repolarization, showing that a horizontal or downward-sloping ST-segment is associated with greater arrhythmic risk (4).

Thus, there has been considerable variation in the definition of early repolarization, as well as some controversy regarding the term itself. Spodick (9), for example, regarded the term as a misnomer, while others believed that it was inappropriate and confusing (10), a view which was challenged (11).

The aim of this paper is essentially to present a unified definition of early repolarization to assist future studies in the field by recommending measurements that should be made to facilitate sharing of data, with the ultimate aim of having a greater understanding of the ECG pattern of early repolarization.

TERMINOLOGY

So that doubt can be avoided, an end-QRS notch is a notch that occurs on the final 50% of the downslope of an R-wave occurring as the final segment of the QRS complex; that is, it links with the ST-segment of the waveform (Figure 1A). It should be distinguished from a notch midway on the downslope of an R-wave (Figure 1B), because this may be due to fragmentation (12). Similarly, an end-QRS slur is an apparent slowing of the inscription of the waveform at the end of the QRS complex that merges with the ST-segment of the complex (Figure 1A). Likewise, in the context of this paper, a slur should occur in the final 50% of the R-wave downslope.

There is considerable variation in the use of the term *J point*. For many cardiologists, this is taken as

the onset of the ST-segment (13), which may equate with the termination of an end-QRS notch, whereas others use the term for the peak (1-3) or the onset (C. Antzelevitch, personal communication, March 28, 2014) of an end-QRS notch. It is proposed that the following terminology be used: 1) *J onset* (Jo) should denote the onset of a notch; 2) *J peak* (Jp) should denote the peak of a notch or onset of a slur; and 3) *J termination* (Jt) should denote the end of a notch or slur.

Figure 2A clarifies these points for an end-QRS notch. In the case of a slur (Figure 2B), Jo and Jp are electrocardiographically the same point. However, for consistency of measurement, it is proposed that the slur onset be regarded as Jp, rather than Jo, because this allows Jp to be used to denote both the peak notch and slur amplitude (Figure 2B). This means that in publications, such as those of Haissaguerre et al. (1), Rosso et al. (2), and Tikkanen et al. (3,4), the term *J amplitude* or *J-point elevation* equates with *Jp amplitude*, as confirmed by these investigators in contributing to this consensus paper. Antzelevitch has used Jo to denote the J point when describing early repolarization (personal communication, March 28, 2014). It also means that in publications such as the “Third Universal Definition of Myocardial Infarction” (14), Jt equates with *ST-segment amplitude* in relation to the definition of ST-segment elevation myocardial infarction. The new terminology should clarify what is being measured in future studies and is recommended for use henceforth.

MEASUREMENT RECOMMENDATIONS

A major aim of this paper is to set out recommendations with respect to measurements relating to the early repolarization pattern. To this end, the following definitions are presented.

NOTCHING AND SLURRING. To facilitate future studies, the following measurements should be made (Figure 2). All amplitude measurements are made with reference to QRS onset.

Notched QRS complex.

1. The amplitude Jo at the onset of the notch
2. The amplitude Jp at the peak of the notch
3. The amplitude Jt at the end of the notch
4. The duration D₁ from Jo to Jp
5. The duration D₂ from Jo to Jt

Slurred QRS complex.

1. The amplitude Jp at the onset of the slur
2. The amplitude Jt at end of the slur
3. The duration D₂ from Jp to Jt

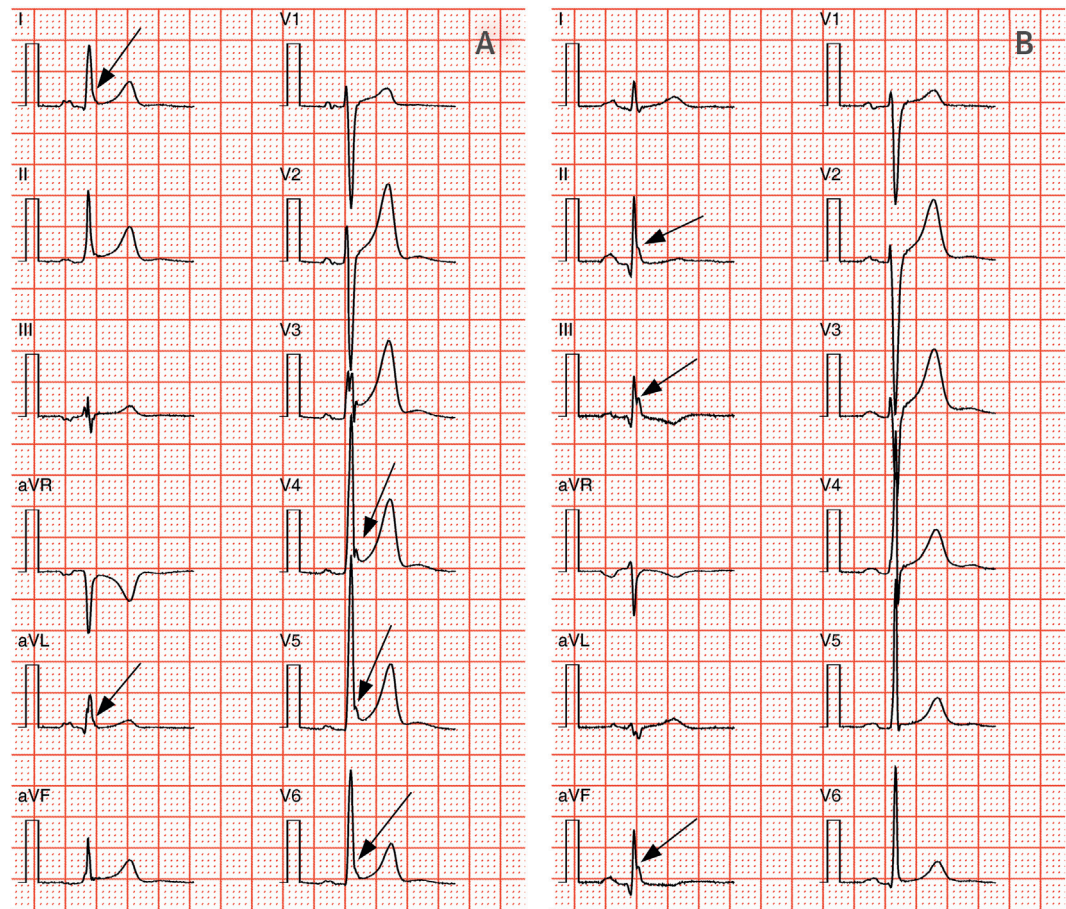
ABBREVIATIONS AND ACRONYMS

ECG = electrocardiography

Jo = J onset

Jp = J peak

Jt = J termination

FIGURE 1 QRS Notching and Slurring

(A) Electrocardiographic leads showing end-QRS notching in lead V₄ progressing to end-QRS slurring in lead V₆. End-QRS slurring is also present in leads I and aVL. The **arrows** localize the notching or slurring. **(B)** Leads III and aVF show notching. In lead III, the notch peak is >50% of the R-wave amplitude and could be regarded as fragmentation. In lead II, appearances on the R-wave downslope take the form of a slur, and there is also a notch in lead aVF. They are most probably due to the same underlying physiological process. The **arrows** indicate the location of the notches and slur.

ST-SEGMENT SLOPE. The following measurements should be recorded when specifying slope (4).

ST-segment slope.

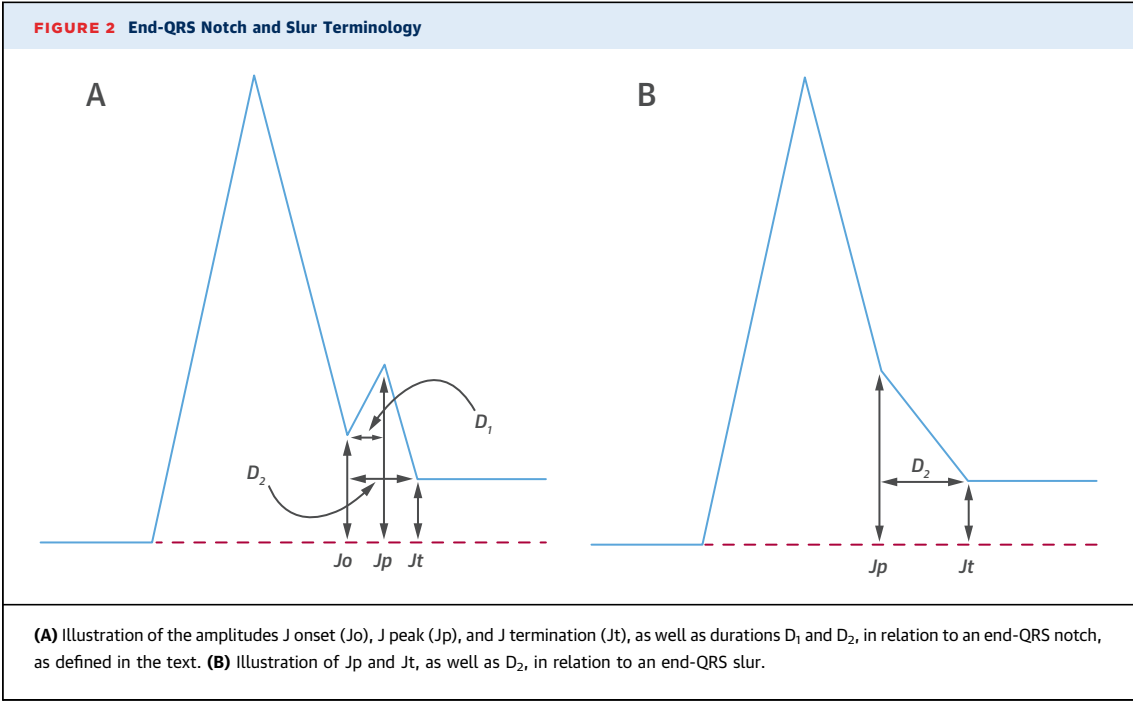
1. ST-segment slope should be measured from J_t.
2. The ST segment should be regarded as horizontal or downward sloping if the amplitude of the ST-segment 100 ms after J_t (interval M) is less than or equal to the amplitude at J_t (Figure 3). The ST-segment should be regarded as upward sloping if the amplitude of the ST-segment 100 ms after J_t (interval M) is greater than the amplitude at J_t.
3. If the researcher has not used J_t when measuring slope, any report must clearly state whether 100-ms intervals such as K, L, and M (Figure 3) have been used.

NEW DEFINITION OF THE EARLY REPOLARIZATION (END-QRS NOTCHING/SLURRING) PATTERN.

A new definition of the early repolarization pattern on the basis of current knowledge is urgently needed. It is entirely feasible that another definition will emerge in the future, when further studies adopting the measurement recommendations of this paper are available.

The majority of publications at the present time (e.g., refs. 1-4) adopt the amplitude of J_p in Figure 2 as the reference point for measuring J-point elevation. The following criteria are therefore proposed until further research clarifies the situation.

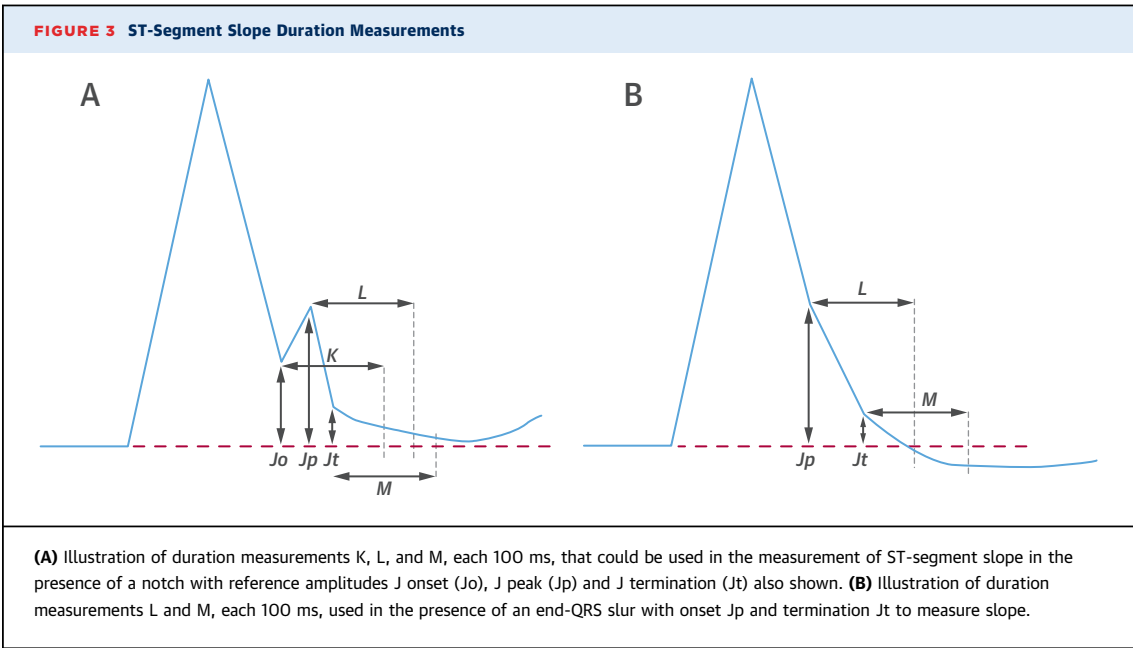
Early repolarization is present if all of the following criteria are met (Central Illustration):



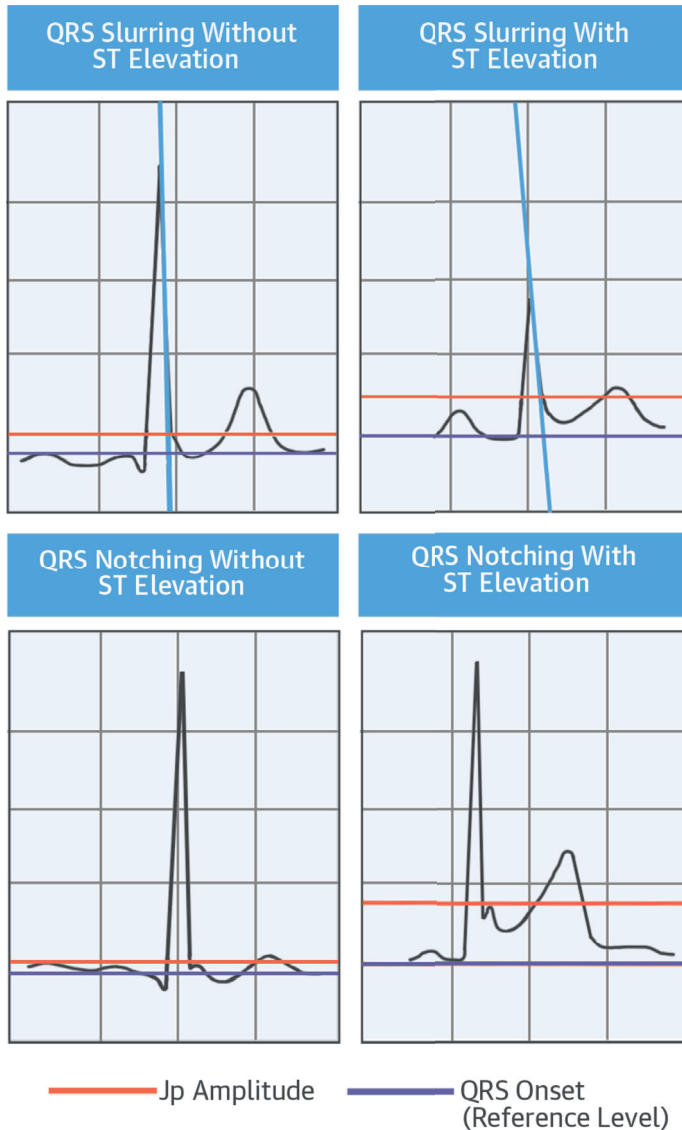
1. There is an end-QRS notch or slur on the down-slope of a prominent R-wave. If there is a notch, it should lie entirely above the baseline. The onset of a slur must also be above the baseline.
2. Jp is ≥ 0.1 mV in 2 or more contiguous leads of the 12-lead ECG, excluding leads V₁ to V₃.
3. QRS duration is <120 ms.

If the ST-segment is upward sloping and followed by an upright T-wave, the pattern should be described as “early repolarization with an ascending ST segment.”

If the ST-segment is horizontal or downward sloping, the pattern should be described as “early repolarization with a horizontal or descending ST segment.”



**CENTRAL ILLUSTRATION The Early Repolarization Pattern:
A Summary of End-QRS Notching and Slurring With and Without
ST-Segment (J Termination) Elevation**



Macfarlane, P.W. et al. J Am Coll Cardiol. 2015; 66(4):470-7.

The upper salmon line indicates the notch or slur amplitude, J peak (Jp), while the lower purple line indicates the baseline used as a reference with respect to which amplitudes should be measured. The blue lines indicate tangents to the initial component of the R-wave downslope. All of these waveforms are illustrations of the early repolarization pattern.

The leads in which the notching or slurring occurs should be used as part of the description, so that, for example, a complete report might state, “Early repolarization with descending ST-segment in leads II, III, and aVF.”

If the ST-segment is ascending in at least 2 leads in each territory and is horizontal or downward sloping in 1 lead, it should be defined as ascending and vice versa. If the ST-segment is horizontal in the inferior leads and ascending in the lateral leads, the final interpretation will depend on the extent (more leads) and the (higher) amplitude of the end QRS slur or notch, that is, on the territory where the early repolarization is most prominent.

ST-SEGMENT ELEVATION WITHOUT NOTCHING OR SLURRING. The consensus view of the group is that ST-segment elevation in the absence of a slur or notch (Figure 4) should not be reported as early repolarization. This is in keeping with the early publications on early repolarization (6,7), which included a notch or slur as part of the description of the pattern.

OVERALL QRS DURATION. It is recommended that QRS duration be measured using those leads that do not exhibit a notch or slur. Whether the early repolarization pattern reflects depolarization or repolarization is, in the consensus opinion, still not completely resolved, and speculation on this point is beyond the scope of this paper. However, the consensus view is that manual measurement of the QRS complex duration from the standard 12-lead ECG should ideally be done from the leads without the early repolarization pattern so that the overall QRS duration will not be overestimated. It is acknowledged that the automated measurement of QRS duration generally uses measurements from all leads, including those with notches, but this point is not elaborated here, other than to note that the normal limits of ECG measurements, as obtained from large population samples, have essentially been derived from the automated approach (15,16).

REGISTRY. It is recommended that a registry of patients with early repolarization and evidence of idiopathic ventricular fibrillation or sudden cardiac arrest be established. This should be accompanied by a control group of subjects with ECGs that meet agreed criteria for early repolarization but who have no histories of sudden cardiac arrest.

A registry is currently in the process of being compiled in the University Hospital of Bordeaux. Entry requires an ECG, a full history, and the completion of a form available on request. Contributions to the inventory are invited.

AUTOMATED MEASUREMENTS. Cardiologists generally obtain a visual impression of waveforms and decide on the presence or absence of certain features. The aforementioned criteria provide guidelines for reporting early repolarization so as to quantitatively characterize visual waveforms. However, automated

methods for ECG analysis require additional precision in the definition of a notch, for example. The following additional guidelines are offered for this purpose.

ONSET OF END-QRS SLUR. With respect to detecting the onset of an end-QRS slur, different methods can be used. One approach (17) is to calculate a tangent from the peak of the R-wave through the following downslope and retain details of the slope. Calculation of the tangent can then progress through the QRS complex after R peak. If the slope moves away from that of the initial tangent by more than a fixed amount, for example, 10° at a time scale equivalent to 25 mm/s, then the slur onset should be accepted as the point at which the slope clearly first deviates from the tangent by 10° (Figure 5).

Other techniques are available; for example, an end-QRS slur can be regarded as the reverse of a delta wave. Therefore, logic that detects a delta wave by looking for slope changes in early QRS inscription can effectively be mirrored to find slur onset at the end of the QRS complex (18).

Similarly, minimum amplitudes and durations of the notch must be used to detect a notch automatically. For example, J_p should exceed 0.05 mV (18) to ensure that noise does not interfere with notch detection.

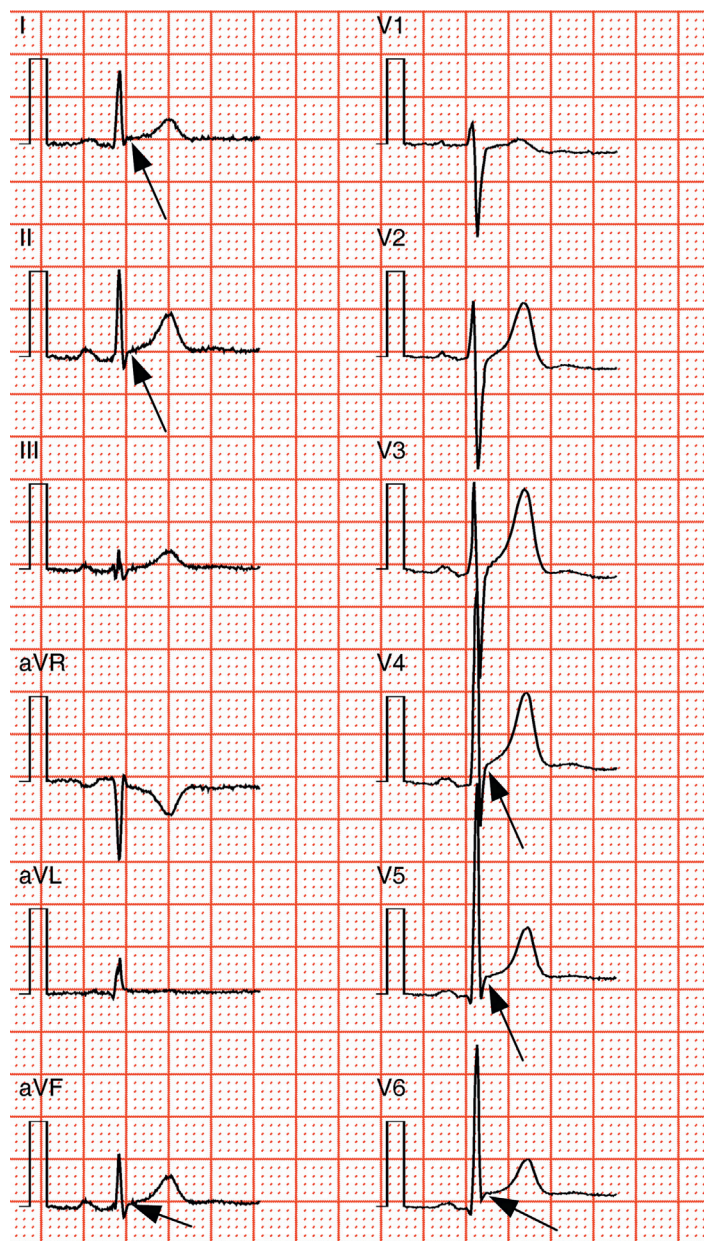
SUMMARY RECOMMENDATIONS.

- It is recommended that researchers reporting end-QRS notching and slurring quote their criteria in terms of J_o , J_p , and J_t . In Figure 2, J_t represents ST-segment onset from an ECG standpoint and should be used when reporting ST-segment elevation.
- Whether a researcher uses all of these measurements or not, it is recommended that they be made available for any cooperative study or international registry.
- With respect to the definition of ST-segment slope, the recommendation is to use the time interval M. If this is not used, researchers must state whether they are using K or L (Figure 3). The onset of M, that is, the location of J_t , is best determined from analysis of all 12 leads displayed in a time-aligned fashion, such that ST-segment onset can be determined across all 12 leads. If any other method of determining ST-segment slope were used, it would need to be defined in detail.

DISCUSSION


In 2000, Gussak and Antzelevitch (19) presented evidence in support of the hypothesis that the early repolarization pattern denoted the presence of a

FIGURE 4 Nonspecific ST-Segment Elevation



An illustration of an electrocardiogram showing moderate ST-segment elevation in leads I, II, and aVF and more marked ST-segment elevation in leads V₄ to V₆, in the absence of any end-QRS notching or slurring. It is recommended that this finding should be described as early repolarization. The **arrows** indicate the points of ST-segment elevation.

substrate that may pre-dispose to development of life-threatening ventricular arrhythmias. Their definition of the pattern included the presence of prominent J waves, or QRS notching or slurring, together with ST-segment elevation. It was 8 years later when idiopathic ventricular fibrillation was first linked with



large numbers of individuals having the early repolarization pattern (1). In addition, there have been many papers (e.g., refs. 19,20) examining the experimental basis for notching and slurring. Not all investigators are in complete agreement about the electrophysiological basis of early repolarization, but there is a consensus that the pattern of end-QRS notching and slurring may, on occasion, be due to late depolarization (9,21) rather than early repolarization (22). Some investigators take the view that the mechanism responsible for end-QRS notching or slurring has not yet been established (23). Indeed, they suggest (23) that the term “early repolarization” should be replaced by “J waves.” There is not space in this paper, which deals with measurement recommendations, to recount all of these discussions.

Leads V_1 to V_3 have been excluded from the new definition of early repolarization set out in this paper to avoid confusion with the Brugada pattern (24), which may occur in leads V_1 to V_3 and is regarded by some as a form of early repolarization.

It is important that in future studies aimed at risk stratification and/or prevalence estimations of early repolarization, investigators all use the same terminology and make the same measurements to describe their findings. It is disconcerting that the prevalence of early repolarization has been described as ranging from 2% to 31% (5). This could be ascribed to misunderstandings in what to measure, differences in ECG recording equipment (e.g., filter settings), and, perhaps, racial variation (25).

None of this should preclude new measurements from being introduced, but they should be presented alongside the measurements recommended in the preceding text.

VISUAL RECOGNITION OF THE EARLY REPOLARIZATION PATTERN. Although this paper focuses principally

on the definitions of a notch and a slur and on terminology, cardiologists must interpret ECGs visually, perhaps assisted by automated interpretations. Visual recognition of a slur can be problematic. For example, if the display time scale is increased from 25 to 50 mm/s, a slur might be considered present simply as a feature of the time scale. It is therefore important to understand that a slur should be reported only if there is a distinct change in the slope of the QRS complex toward J_t .

AUTOMATED DETECTION OF THE EARLY REPOLARIZATION PATTERN. Some of the problems in detecting slurs discussed earlier apply equally well to automated detection techniques. It is therefore important that the developers of software for the detection of notching and slurring adhere to the guidelines presented. Even then, there are still likely to be subtle differences, particularly in the detection of slur onset.

CLINICAL IMPLICATIONS. It is worth reiterating that the original definition of early repolarization referred to a combination of end-QRS notching or slurring together with ST-segment elevation and a tall T-wave. The more recent association between the newer definition of early repolarization, as outlined here, and life-threatening cardiac arrhythmias was independent of increased J_t amplitude (1-3). The work of Tikkanen et al. (4) and Rosso et al. (26) suggests that an upward-sloping ST-segment, followed by an upright T-wave in the presence of end-QRS notching or slurring, is benign, whereas early repolarization with a horizontal or downward-sloping ST-segment is potentially more serious. The ascending ST-segment has not predicted mortality or sudden death in any of the general population samples. However, in the series of Rosso et al. (26), the majority of emergency department cases with idiopathic ventricular fibrillation were associated with horizontal or downward-sloping ST-segments, while the ascending type was less common in the patients with early repolarization syndrome resuscitated from ventricular fibrillation. Further research clearly needs to be undertaken using the measures described in this paper.

Finally, in 1 study (27), notching or slurring plus J_t elevation with $J_t \geq 0.1$ mV occurred in 2.1% of 1,496 apparently healthy, white adults (mean age 37.4 ± 12.6 years), whereas the prevalence was 29.3% if only notching or slurring was present without J_t elevation. This suggests that considerable caution must be exercised in interpreting the early repolarization pattern, as defined earlier.

CONCLUSIONS

In view of the relatively high prevalence of the early repolarization pattern without ST-segment elevation in apparently healthy subjects (27) as per the new definition, we believe it necessary to state that, pending further research, in the absence of syncope or a strong family history of juvenile sudden cardiac death, the finding of the early repolarization pattern does not merit further investigation, irrespective of ST-segment slope. This paper provides a basis on which future research can be undertaken through shared data and standardized measurements.

ACKNOWLEDGMENTS The authors thank Elaine Clark and Brian Devine, of the Electrocardiology Section, Institute of Cardiovascular and Medical Sciences, University of Glasgow, for assistance with preparation of the figures and Pamela Armstrong for attention to detail in the preparation of the final manuscript.

REPRINT REQUESTS AND CORRESPONDENCE: Prof. Peter W. Macfarlane, Institute of Cardiovascular and Medical Sciences, Electrocardiology Section, University of Glasgow, Glasgow Royal Infirmary, New Lister Building, 10 Alexandra Parade, Glasgow G31 2ER, United Kingdom. E-mail: peter.macfarlane@glasgow.ac.uk.

REFERENCES

1. Haissaguerre M, Derval N, Sacher F, et al. Sudden cardiac arrest associated with early repolarization. *N Engl J Med* 2008;358:2016-23.
2. Rosso R, Kogan E, Belhassen B, et al. J-point elevation in survivors of primary ventricular fibrillation and matched control subjects: incidence and clinical significance. *J Am Coll Cardiol* 2008;52:1231-8.
3. Tikkanen JT, Anttonen O, Junttila MJ, et al. Long-term outcome associated with early repolarization and electrocardiography. *N Engl J Med* 2009;361:2529-37.
4. Tikkanen JT, Junttila MJ, Anttonen O, et al. Early repolarization. Electrocardiographic phenotypes associated with favorable long-term outcome. *Circulation* 2011;123:2666-73.
5. Maury P, Rollin A. Prevalence of early repolarization/J wave patterns in the normal population. *J Electrocardiol* 2013;46:411-6.
6. Kambara H, Phillips J. Long-term evaluation of early repolarization syndrome (normal variant RST-T segment elevation). *Am J Cardiol* 1976;38:157-61.
7. Wasserburger RH, Alt WJ. The normal RS-T segment elevation variant. *Am J Cardiol* 1961;8:184-92.
8. Chung EK. *Electrocardiography: Practical Applications With Vectorial Principles*. 2nd edition. Hagerstown, MD: Harper & Row, 1980.
9. Spodick D. Early repolarization: an under-investigated misnomer. *Clin Cardiol* 1997;20:913-4.
10. Surawicz B, Macfarlane PW. Inappropriate and confusing electrocardiographic terms: J-wave syndromes and early repolarization. *J Am Coll Cardiol* 2011;7:1584-6.
11. Antzelevitch C, Yan GX, Viskin S. Rationale for the use of the terms J-wave syndromes and early repolarization. *J Am Coll Cardiol* 2011;7:1587-90.
12. Das MK, Saha C, El Masry H, et al. Fragmented QRS on a 12-lead ECG: a predictor of mortality and cardiac events in patients with coronary artery disease. *Heart Rhythm* 2007;4:1385-92.
13. Perez MV, Friday K, Froelicher V. Semantic confusion: the case of early repolarization and the J point. *Am J Med* 2012;125:843-4.
14. Thygesen K, Alpert JS, Jaffe AS, et al., for the Writing Group on Behalf of the Joint ESC/ACCF/AHA/WHF Task Force for the Universal Definition of Myocardial Infarction. Third universal definition of myocardial infarction. *Circulation* 2012;126:2020-35.
15. Appendix 1: adult normal limits and appendix 2: paediatric normal limits. In: Macfarlane PW, van Oosterom A, Pahlm O, et al., editors. *Specialized Aspects of ECG*. London, UK: Springer-Verlag, 2012:639-778.
16. Mason JW, Ramseth DJ, Chanter DO, et al. Electrocardiographic reference ranges derived from 79,743 ambulatory subjects. *J Electrocardiol* 2007;40:228-34.
17. Macfarlane PW, Clark EN. ECG measurements in end QRS notching and slurring. *J Electrocardiol* 2013;46:385-9.
18. Clark EN, Katibi I, Macfarlane PW. Automatic detection of end QRS notching or slurring. *J Electrocardiol* 2014;47:151-4.
19. Gussak I, Antzelevitch C. Early repolarization syndrome: clinical characteristics and possible cellular and ionic mechanisms. *J Electrocardiol* 2000;33:299-309.
20. Antzelevitch C, Yan GX. J wave syndromes. *Heart Rhythm* 2010;7:549-58.
21. Wellens H. Early repolarization revisited. *N Engl J Med* 2008;358:2063-5.
22. Ghosh S, Cooper DH, Vijayakumar R, et al. Early repolarization associated with sudden death: insights from noninvasive electrocardiographic imaging. *Heart Rhythm* 2010;7:534-7.
23. Hoogendijk MG, Potse M, Coronel R. Critical appraisal of the mechanism underlying J waves. *J Electrocardiol* 2013;46:390-4.
24. Brugada P, Brugada J. Right bundle branch block, persistent ST elevation and sudden cardiac death: a distinct clinical and electrocardiographic syndrome. A multicenter report. *J Am Coll Cardiol* 1992;20:1391-6.
25. Clark EN, Macfarlane PW. Ethnic variation in prevalence of end QRS notching and slurring in apparently healthy populations. Presented at: Computing in Cardiology Conference (CinC); September 7-10, 2014; Cambridge, MA.
26. Rosso R, Glikson E, Belhassen B, et al. Distinguishing "benign" from "malignant early repolarization": the value of the ST-segment morphology. *Heart Rhythm* 2012;9:225-9.
27. Heng SJH, Clark EN, Macfarlane PW. End QRS notching or slurring in the electrocardiogram: influence on the definition of "early repolarization." *J Am Coll Cardiol* 2012;60:947-8.

KEY WORDS cardiac arrhythmias, electrocardiography, end-QRS notching/slurring, heart conduction system, sudden cardiac death, ventricular fibrillation