

Intravascular Ultrasound Versus Optical Coherence Tomography Guidance

Ron Waksman, MD, Hironori Kitabata, MD, Francesco Prati, MD, Mario Albertucci, MD, Gary S. Mintz, MD

Perspective: We Choose Intravascular Ultrasound Over Optical Coherence Tomography to Guide Stent Implantation

Ron Waksman, MD, Hironori Kitabata, MD

After the introduction of coronary stenting, intravascular ultrasound (IVUS) was established as the most reliable imaging tool to guide stenting in complex lesions, including coverage of ostial lesions, bifurcation lesions, left main stenting, and chronic total occlusions; and is helpful in determining the cause of stent failures, including in-stent restenosis. These features once verified by IVUS were critical in the reduction of stent thrombosis of bare-metal stents (BMS) and later of drug-eluting stents (DES). IVUS examinations have significantly increased our knowledge and understanding of the mechanisms of balloon angioplasty, stent implantation, and restenosis. Interestingly, while IVUS is the most used intravascular imaging modality in interventional cardiology, it is used in <20% of percutaneous coronary intervention (PCI) procedures.

As the focus of intracoronary imaging shifted more toward plaque characterization and endothelial coverage post-stenting, the limitation of relatively low resolution (100 to 150 μm) with IVUS was apparent. In contrast, intravascular optical coherence tomography (OCT) has emerged as an attractive new imaging modality, which offers superior resolution (10 to 15 μm) as well as in vivo coronary plaque morphology. Furthermore, the U.S. Food and Drug Administration recently approved frequency domain (FD)-OCT systems to guide stent implantation. The latest OCT technology enables imaging of longer coronary segments without significant ischemia and motion artifact and has excellent reproducibility for consecutive pullbacks. Whether OCT is disruptive or complementary to IVUS has not yet been fully clarified. Here we compare IVUS performance with that of OCT

and review the evidence accumulated thus far on both imaging tools.

IVUS Guidance for BMS Implantation

IVUS imaging provides information on vessel morphology and the need for vessel preparation as well as vessel, lumen, and lesion length measurements. IVUS-guided stent placement leads to better stent expansion with large post-minimal stent areas at higher inflation pressures, thereby reducing the risk of restenosis with BMS. Post-stenting IVUS also verifies apposition to the vessel wall and provides additional information related to the presence of edge dissections, plaque protrusion, and the need for post-dilation or additional stenting. Early on, the use of IVUS was helpful in identifying the lack of stent expansion and inadequate stent apposition to the vessel wall, leading to high rates of subacute stent thrombosis. As a result, high pressure balloons were introduced to improve stent deployment, which was associated with significant reduction of acute and subacute stent thrombosis of BMS. A meta-analysis of the randomized angiographic versus IVUS-guided BMS implantation trials showed that IVUS reduced restenosis and repeat revascularization, but not death or myocardial infarction (1).

IVUS Guidance for DES Implantation

The limited data on IVUS-guided DES deployment suggests that IVUS guidance may be important to ensure optimal stent expansion and stent-strut apposition with DES (Table 1), particularly in the complex PCI era of multivessel and/or left main coronary artery stenting (2–4). The high rate of DES thrombosis initially has led to a revived interest in IVUS guidance for DES deployment.

As in the BMS era, stent underexpansion is a major predictor of in-stent restenosis and subacute stent thrombosis in the DES era (5,6), even though the optimal minimal stent area threshold is smaller in DESs than in BMSs (7–9). However, whether an optimal procedural endpoint (IVUS criteria for optimal DES deployment) exists to achieve the best clinical outcomes after DES implantation has not been elucidated in the randomized studies.

Table 1 IVUS Versus Angiography Guidance for DES Placement

First Author/Study (Ref. #), Year (Study)	n	Study Population	Study Design	IVUS Criteria for Optimal Expansion	Criteria Fulfilled	Main Outcome Measures	Results
Roy et al. (2), 2008	1,768	De novo native coronary lesions, restenotic and SVG lesions	Single-center registry	Discretion of the treating operator	—	Definite stent thrombosis and MACE at 12 months	IVUS better (stent thrombosis and TLR)
Classen et al. (3), 2011 (MATRIX)	1,504 (SES)	De novo native coronary and restenotic lesions	Multicenter registry	Discretion of the treating operator	—	30-day, 1-yr, and 2-yr rates of death/MI, MACE, and stent thrombosis	IVUS better
Park et al. (4), 2009	682	Left main lesions	Multicenter registry	Discretion of the treating operator	—	3-yr mortality	IVUS better
Chieffo et al. (10), 2012 (AVIO)	284	De novo native coronary lesions	Multicenter, randomized	MSA $\geq 70\%$ of post-dilation balloon calculated according to vessel media to media diameters	48%	Post-procedure MLD, TLR, and MACE at 9 months; MACE at 2 yrs	IVUS better (post-procedure MLD)
PODIUM (NCT01103765)	220	De novo native coronary lesions	Prospective, randomized, multicenter	MUSIC criteria	—	Optimal stent deployment defined by IVUS analysis and complications of PCI	Ongoing

DES = drug-eluting stent(s); IVUS = intravascular ultrasound; MACE = major adverse cardiac event(s); MI = myocardial infarction; MLD = minimal lumen diameter; MSA = minimal stent area; MUSIC = Multicenter Ultrasound Stenting in Coronaries; PCI = percutaneous coronary intervention; SES = sirolimus-eluting stent(s); SVG = saphenous vein graft.

Large-scale randomized studies exploring the impact of IVUS-guided optimal stent expansion with DESs on restenosis and stent thrombosis therefore seem warranted. Recently, the AVIO (Angiographic Versus IVUS Optimization) trial demonstrated that, compared with angiographic guidance, IVUS optimized DES implantation in complex lesions is associated with a larger post-procedure minimal lumen diameter; however, this benefit did not lead to a significantly lower occurrence of major adverse cardiac events at 24 months (10). Currently, the PODIUM (Post-dilatation for Optimization of Drug-eluting Stents Deployment Assessed by Intravascular Ultrasound Multicenter) study (NCT01103765) is ongoing. The results of this trial will provide additional important insights into the clinical significance of IVUS-guided stent implantation in the DES era.

OCT Guidance for Coronary Intervention

OCT provides more detailed morphological information for monitoring stent deployment than does IVUS (11). Several reports have shown the usefulness of OCT in complex interventions, such as bifurcation lesions and chronic total occlusions and in the detection of stent underexpansion (12–14). Furthermore, it has been demonstrated that OCT has the potential to detect stent-edge dissection (40% vs. 16%, $p = 0.005$), tissue protrusion (58% vs. 20%, $p < 0.001$), and stent malapposition (47% vs. 8%, $p < 0.001$) compared with IVUS (15). However, the clinical relevance of these small, detailed features detected by OCT has yet to be determined. Radu et al. (16) evaluated the relationship between procedural dissection, stent

malapposition, and delayed stent healing at 26-month median follow-up ($n = 28$).

Tanaka et al. (17) investigated whether OCT could predict no-reflow after PCI in 83 patients with non ST-segment elevation acute coronary syndrome. Thin-cap fibroatheroma was more frequent (50% vs. 16%, $p = 0.005$), and the size of the lipid arc estimated by OCT was significantly greater in the no-reflow group ($166 \pm 60^\circ$ vs. $44 \pm 63^\circ$, $p < 0.001$). Final myocardial blush grade also deteriorated according to the increase in the angle of lipid (especially $>180^\circ$). A multivariable logistic regression model revealed that lipid arc alone was an independent predictor of the angiographic no-reflow (odds ratio [OR]: 1.018, 95% confidence interval [CI]: 1.004 to 1.033, $p < 0.01$).

Yonetsu et al. (18) used OCT to study the relationship between pre-PCI plaque morphology and post-PCI creatine kinase-myocardial band elevation. In the multivariable analysis, a thin-cap fibroatheroma (OR: 4.68, 95% CI: 1.88 to 11.64, $p = 0.001$; OR: 4.20, 95% CI: 1.30 to 13.59, $p = 0.02$) was an independent predictor of post-PCI creatine kinase-myocardial band elevation even in elective stent implantation. Moreover, Gonzalo et al. (19) reported that plaque type at the stent edges, especially lipid-rich plaque, had an impact on the presence of edge dissections. Thus, OCT may be a useful tool for risk stratification of PCI.

Imola et al. (20) assessed the safety and feasibility of FD-OCT to guide decision-making in PCI in a single-center registry and showed that FD-OCT was a safe and feasible tool for guidance of PCI. Furthermore, in a retrospective, multicenter, observational study with a total of 670 patients, Prati et al. (21) reported that angiography plus

OCT guidance versus angiography-only guidance for PCI was associated with a significantly lower risk of cardiac death or myocardial infarction at 1 year, even after adjustment of important potential confounders (OR: 0.49, 95% CI: 0.25 to 0.96, $p = 0.037$). However, further investigations are needed to confirm whether the use of FD-OCT will improve clinical outcomes.

Comparison of IVUS and OCT Guidance for Stent Placement

The strength of OCT lies in its ability to clearly visualize the surface of vessel lumen, although it cannot measure plaque burden because it requires visualization of the external elastic membrane due to its shallow penetration depth (1 to 2 mm). OCT can identify stent failures (e.g., stent malapposition, dissection, tissue protrusion, and thrombus) more clearly than IVUS. However, OCT is a novel imaging modality, and, unlike IVUS, there are few data on the ability of OCT to measure stent lumen area and to identify stent under-expansion. Whether IVUS criteria for optimal stent placement can be translated to OCT-guided stent implantation remains unknown. In fact, several studies reported that lumen dimensions measured by OCT were smaller than those measured by IVUS (22,23). Yamaguchi et al. (22) evaluated in vivo differences of coronary lumen dimensions between IVUS and OCT. Minimal lumen area (MLA) was significantly smaller when measured by time domain-OCT with occlusion technique versus IVUS ($5.2 \pm 2.8 \text{ mm}^2$ vs. $5.6 \pm 2.6 \text{ mm}^2$, $p < 0.0001$; mean difference, 0.4 mm^2). Gonzalo et al. (23) also reported the lumen areas measured by time domain-OCT with and without balloon occlusion were much smaller than those measured by IVUS (mean difference, 1.67 mm^2 for an occlusion technique and 1.11 mm^2 for a nonocclusion technique). Furthermore, Okamura et al. (24) demonstrated that MLA measured by FD-OCT was smaller than IVUS-derived MLA ($5.84 \pm 1.89 \text{ mm}^2$ vs. $6.26 \pm 2.01 \text{ mm}^2$, not significant; mean difference, 0.42 mm^2), despite the highly significant correlation between the 2 measurements ($R^2 = 0.82$, $p < 0.001$). These measurement differences may lead to suboptimal stent expansion when PCI is performed by OCT guidance using IVUS criteria, resulting in adverse events such as restenosis and stent thrombosis.

Unlike IVUS, currently available FD-OCT technology for reliable image acquisition requires injection of contrast media to displace blood from the vessel lumen because the OCT signal is attenuated by the presence of red blood cells. The increased contrast media volume when using FD-OCT during PCI may impair renal function. Contrast-induced acute kidney injury after PCI is one of major causes of in-hospital and long-term mortality and morbidity, especially in patients with coexisting renal dysfunction (25,26), which limits the routine use of FD-OCT during PCI. Hence, flush medium, which substitutes for contrast, will be necessary in the near future (27,28).

It would be helpful if both systems have robust and reliable coregistration software to better orient the operator to the point of interest in the vessel. This software is currently under development and should improve the ease of analysis both for IVUS and OCT.

Conclusions and Final Thoughts

Both IVUS and OCT technologies are useful image-guiding tools during stent implantation. Although OCT has much higher resolution and adds more information, it is not clear whether this additional information helps to improve patient outcome. In contrast, additional information may cause confusion to the operator when he or she is instructed not to change his or her clinical judgment based on the OCT findings. Nevertheless, it is expected that OCT will be a useful imaging tool to guide stent implantation; however, it is not yet ready for prime time. The lack of clinical OCT data and the lack of standardized OCT criteria for optimizing stent implantation may delay the penetration of OCT technology despite its superior resolution capabilities. Until OCT guidance can validate lumen measurements for stent size selection and demonstrate improvement in both early and long-term clinical outcomes after stent implantation, it remains a useful research tool. At present, IVUS remains the more trusted and validated imaging modality and is our first-choice modality to guide optimal stent implantation.

Reprint requests and correspondence: Dr. Ron Waksman, MedStar Washington Hospital Center, Washington Hospital Center, 110 Irving Street, NW, Suite 4B-1, Washington, DC 20010. E-mail: ron.waksman@medstar.net.

From the Division of Cardiology, MedStar Washington Hospital Center, Washington Hospital Center, Washington, DC. Drs. Waksman and Kitabata have reported that they have no relationships relevant to the contents of this paper to disclose.

REFERENCES

1. Parise H, Machara A, Stone GW, Leon MB, Mintz GS. Meta-analysis of randomized studies comparing intravascular ultrasound versus angiographic guidance of percutaneous coronary intervention in pre-drug-eluting stent era. *Am J Cardiol* 2011;107:374-82.
2. Roy P, Steinberg DH, Sushinsky SJ, et al. The potential clinical utility of intravascular ultrasound guidance in patients undergoing percutaneous coronary intervention with drug-eluting stents. *Eur Heart J* 2008;29:1851-7.
3. Claessen BE, Mehran R, Mintz GS, et al. Impact of intravascular ultrasound imaging on early and late clinical outcomes following percutaneous coronary intervention with drug-eluting stents. *J Am Coll Cardiol Interv* 2011;4:974-81.
4. Park SJ, Kim YH, Park DW, et al. Impact of intravascular ultrasound guidance on long-term mortality in stenting for unprotected left main coronary artery stenosis. *Circ Cardiovasc Interv* 2009;2:167-77.
5. Fujii K, Mintz GS, Kobayashi Y, et al. Contribution of stent under-expansion to recurrence after sirolimus-eluting stent implantation for in-stent restenosis. *Circulation* 2004;109:1085-8.

6. Cheneau E, Leborgne L, Mintz GS, et al. Predictors of subacute stent thrombosis: results of a systematic intravascular ultrasound study. *Circulation* 2003;108:43–7.
7. Sonoda S, Morino Y, Ako J, et al. Impact of final stent dimensions on long-term results following sirolimus-eluting stent implantation: serial intravascular ultrasound analysis from the SIRIUS trial. *J Am Coll Cardiol* 2004;43:1959–63.
8. Hong MK, Mintz GS, Lee CW, et al. Intravascular ultrasound predictors of angiographic restenosis after sirolimus-eluting stent implantation. *Eur Heart J* 2006;27:1305–10.
9. Doi H, Machara A, Mintz GS, et al. Impact of post-intervention minimal stent area on 9-month follow-up patency of paclitaxel-eluting stents: an integrated intravascular ultrasound analysis from the TAXUS IV, V, and VI and TAXUS ATLAS Workhorse, Long Lesion, and Direct Stent trials. *J Am Coll Cardiol Interv* 2009;2:1269–75.
10. Chieffo A, Latib A, Caussin C, et al. A prospective, randomized trial of intravascular-ultrasound guided compared to angiography guided stent implantation in complex coronary lesions: the AVIO trial. *Am Heart J* 2013;165:65–72.
11. Gutiérrez H, Arnold R, Gimeno F, et al. Optical coherence tomography. Initial experience in patients undergoing percutaneous coronary intervention. *Rev Esp Cardiol* 2008;61:976–9.
12. Schultz C, van der Ent M, Serruys PW, Regar E. Optical coherence tomography to guide treatment of chronic occlusions? *J Am Coll Cardiol Interv* 2009;2:366–7.
13. Tyczynski P, Kukreja N, Pieri E, di Mario C. Optical frequency domain imaging guided crossing of a stumpless chronic total occlusion. *Int J Cardiol* 2011;148:231–3.
14. Motreff P, Souteyrand G. Optical coherence tomography to diagnose under-expansion of a drug-eluting stent. *J Am Coll Cardiol Img* 2009;2:245–6.
15. Kubo T, Imanishi T, Kitabata H, et al. Comparison of vascular response after sirolimus-eluting stent implantation between unstable angina pectoris and stable angina pectoris: a serial optical coherence tomography study. *J Am Coll Cardiol Img* 2008;1:475–84.
16. Radu M, Jørgensen E, Kelbæk H, Helqvist S, Skovgaard L, Saunamäki K. Optical coherence tomography at follow-up after percutaneous coronary intervention: relationship between procedural dissections, stent strut malapposition and stent healing. *Euro-Intervention* 2011;7:353–61.
17. Tanaka A, Imanishi T, Kitabata H, et al. Lipid-rich plaque and myocardial perfusion after successful stenting in patients with non-ST-segment elevation acute coronary syndrome: an optical coherence tomography study. *Eur Heart J* 2009;30:1348–55.
18. Yonetsu T, Kakuta T, Lee T, et al. Impact of plaque morphology on creatine kinase-MB elevation in patients with elective stent implantation. *Int J Cardiol* 2011;146:180–5.
19. Gonzalo N, Serruys PW, Okamura T, et al. Relation between plaque type and dissections at the edges after stent implantation: an optical coherence tomography study. *Int J Cardiol* 2011;150:151–5.
20. Imola F, Mallus MT, Ramazzotti V, et al. Safety and feasibility of frequency domain optical coherence tomography to guide decision making in percutaneous coronary intervention. *EuroIntervention* 2010;6:575–81.
21. Prati F, Di Vito L, Biondi-Zoccai G, et al. Angiography alone versus angiography plus optical coherence tomography to guide decision-making during percutaneous coronary intervention: the Centro per la Lotta contro l'Infarto-Optimisation of Percutaneous Coronary Intervention (CLI-OPCI) study. *EuroIntervention* 2012;8:823–9.
22. Yamaguchi T, Terashima M, Akasaka T, et al. Safety and feasibility of an intravascular optical coherence tomography image wire system in the clinical setting. *Am J Cardiol* 2008;101:562–7.
23. Gonzalo N, Serruys PW, Garcia-Garcia HM, et al. Quantitative ex vivo and in vivo comparison of lumen dimensions measured by optical coherence tomography and intravascular ultrasound in human coronary arteries. *Rev Esp Cardiol* 2009;62:615–24.
24. Okamura T, Onuma Y, Gracia-Gracia HM, et al. First-in-man evaluation of intravascular optical frequency domain imaging (OFDI) of Terumo: a comparison with intravascular ultrasound and quantitative coronary angiography. *EuroIntervention* 2011;6:1037–45.
25. McCullough PA. Contrast-induced acute kidney injury. *J Am Coll Cardiol* 2008;51:1419–28.
26. Rihal CS, Textor SC, Grill DE, et al. Incidence and prognostic importance of acute renal failure after percutaneous coronary intervention. *Circulation* 2002;105:2259–64.
27. Kataiwa H, Tanaka A, Kitabata H, Imanishi T, Akasaka T. Safety and usefulness of non-occlusion image acquisition technique for optical coherence tomography. *Circ J* 2008;72:1536–7.
28. Ozaki Y, Kitabata H, Tsujioka H, et al. Comparison of contrast media and low molecular dextran for frequency-domain optical coherence tomography imaging. *Circ J* 2012;76:922–7.

Perspective: I Would Choose Optical Coherence Tomography Over Intravascular Ultrasound

Francesco Prati, MD,*† Mario Albertucci, MD†

There is a general consensus that optical coherence tomography (OCT) is a breakthrough technology that increases our understanding of the mechanism of stent failure and provides new insights on the pathophysiology of acute coronary syndromes (ACS) (1).

Many interventional cardiologists also agree that frequency domain (FD)-OCT, with its marked improvement in the acquisition process, promises to have a role in guiding coronary interventions (PCIs) (2).

Assessment of target lesions by intravascular ultrasound (IVUS) can be demanding. In fact, IVUS probes tend to occlude the lumen in tight lesions, and the relatively low 1 mm/s pull-back speed may cause myocardial ischemia. Due to the thinner profile of FD-OCT probes and the faster pull-back imaging that can reach 25 mm/s in the St. Jude Medical system (St. Paul, Minnesota), many severely diseased target lesions can be safely imaged without causing luminal obstruction, thus making symptomatic ischemia much less likely (2). As a main technical drawback, FD-OCT is not suited to address plaques located at the very ostium of the left or right coronary artery. Also, in the presence of very tight stenosis, image quality can be suboptimal (2).

Impact of Plaque Composition on PCI

The accurate identification of plaque components by means of OCT is a key feature to improve PCI (3). The presence, depth, and circumferential extent of calcification can negatively affect the results of PCI (4,5). Unlike angiography, IVUS accurately identifies calcium but is unable to measure its thickness (6). OCT, on the other hand, can measure superficial calcific components with a thickness <1.0 to 1.3 mm, affecting important decisions regarding the operator's strategy, such as avoidance of direct stenting and the use of cutting balloons or rotational atherectomy.

As a relatively new concept, stent positioning should be accomplished, aiming at complete coverage of the lipid pool

(7), avoiding placement of stent edges over lipid formations, which could lead to stent thrombosis and plaque embolization (6). As OCT identifies lipid pool with a greater accuracy than IVUS, its pre-intervention use can also be encouraged to reduce the risk of embolization of plaque components.

Assessment of Ambiguous Angiographic Lesions

In patients with ACS, the presence of 1 or more nonsignificant lesions, exhibiting only haziness on angiography, can pose a problem for the interventional cardiologist. In fact, misinterpretation of culprit lesions could be the cause of ischemic events occurring in the short- and midterm. In angiographically hazy lesions, OCT often detects ruptured plaques with thrombus attached to the site of the fibrous cap rupture (2,3). Under these circumstances, the decision to proceed with treatment can stem more from morphological observations than from the absolute measurement of lumen area (2).

For stable patients, the decision of whether to proceed with intervention in intermediate narrowing can be supported by an exact OCT quantification of the minimal lumen area. Of note, measurements obtained with OCT tend to be slightly lower than those with IVUS (2,3). The fact that lumen contours are easily obtained enables the

online application of an automated algorithm that facilitates operator decision making by displaying the reconstructed segment in a longitudinal view (Fig. 1) (2,4).

Identification of Vulnerable Plaques

One of the future challenges of interventional cardiology is the characterization of vulnerable plaques. Recently, PROSPECT (An Imaging Study in Patients With Unstable Atherosclerotic Lesions) showed for the first time that mild lesions on angiography, with certain morphological IVUS features on grayscale and virtual histology, conferred a higher risk of cardiac events (8). OCT, due to its high accuracy in the detection of superficial plaque components, can directly measure fibrous cap thickness and lipid pool extension. Also, the application of dedicated software promises to identify local signs of inflammation. All these features make OCT the most promising technique in identifying plaques at risk of rupture or progression (9).

Post-Intervention Assessment

The new angle of view. The results of randomized studies that addressed the usefulness of an IVUS-guided approach of bare-metal stent expansion to reduce restenosis have been disappointing (10). Only recently have the potential

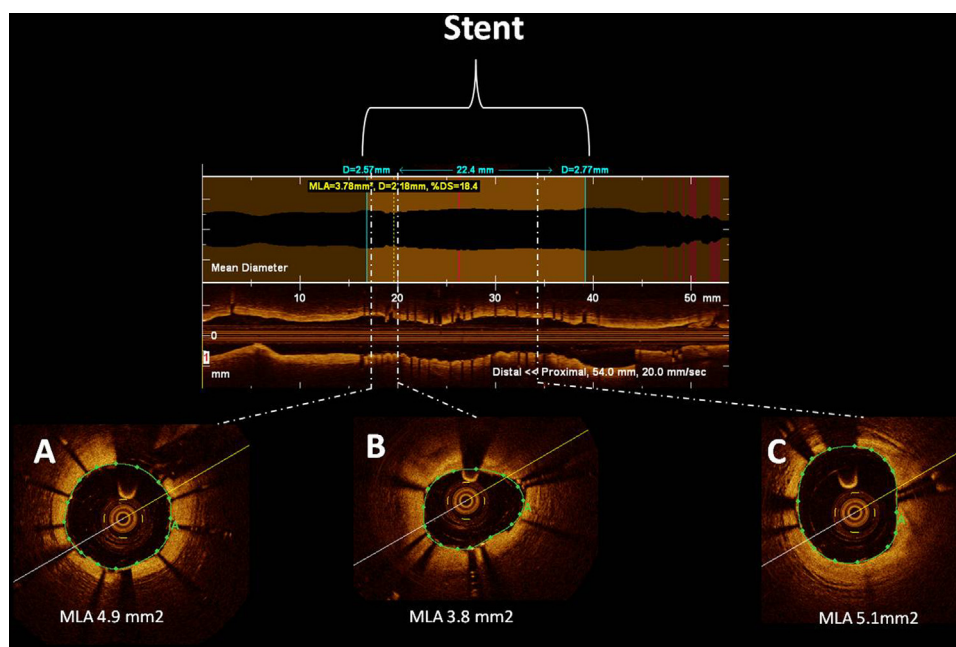


Figure 1 Example of the Optical Coherence Tomography Criteria Indicative of Nonoptimal Stent Deployment That Were Applied in the CLI-OPCI Study

The following definitions were applied: *stent underexpansion*: stent minimal lumen area (MLA) >90% of mean reference lumen area; *stent malapposition* with a distance >200 μ m: intrastent tissue protrusion with a thickness >200 μ m; *edge dissections* with a width >200 μ m; *edge lumen narrowing* with a lumen area <4 mm². CLI-OPCI = Centro per la Lotta contro l'Infarto-Optimisation of Percutaneous Coronary Intervention.

advantages of IVUS become clear, particularly in complex lesions such as in the left main coronary artery. Also, IVUS data obtained in a large propensity score–matched population after drug-eluting stent placement showed that such an approach may reduce the occurrence of thrombosis (11).

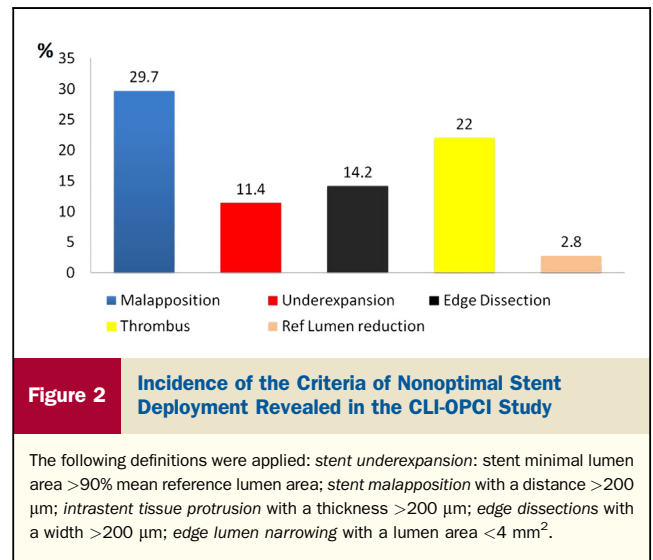
Consistent with this finding, the large IVUS substudy of the ADAPT-DES (Assessment of Dual Antiplatelet Therapy With Drug Eluting Stents) showed that the presence of attenuated plaque, tissue protrusion, reference segment plaque burden, and edge dissection are significant predictors of stent thrombosis (12).

OCT represents a new angle of view as it offers higher resolution at the expense of reduced penetration. Therefore, IVUS-accepted criteria that require assessment of vessel architecture, particularly measurement of the external elastic membrane and plaque burden, cannot be obtained.

Besides enabling the comparison of the minimal stent area with the reference area, OCT can identify details such as stent underexpansion, malapposition, uneven stent strut distribution, intrastent thrombotic formations, and dissections at the edges and inside the stents, with a level of accuracy unmatched by IVUS.

Frequency of OCT findings of suboptimal stenting and clinical role of OCT guidance. The multicenter CLI-OPCI study (13) aimed at verifying whether the use of OCT can improve the 1-year composite event of cardiac death or nonfatal myocardial infarction after PCI in a real-world population. Results from 335 patients who underwent OCT-guided intervention were compared with those from a control group by means of propensity score adjustment, and the data on clinical events were very promising indeed (Table 1).

The study addressed the burning question of how to react to OCT findings indicative of suboptimal stent deployment (13). Of note, OCT was performed after achieving an optimal angiographic result, and decisions to intervene further to optimize stenting were made after having applied quantitative criteria of suboptimal positioning (Fig. 1). In 34.7%



of the stented segments, it was decided, based on the OCT results, to intervene further. This was done to improve stent deployment, either with balloon dilation (22.3%) to correct malapposition, underexpansion, or residual thrombus, or with additional stenting (12.4%) to fix edge dissections or treat residual lumen narrowing (Fig. 2).

Clinical significance of OCT findings of suboptimal stenting. The presence of acute malapposition may be associated with reduced re-endothelialization and neointima formation. In patients with ACS, the occurrence of in-stent tissue protrusion, due to presence of residual thrombus, is a common finding. Recent data revealed that residual intrastent thrombus is related to periprocedural myocardial infarction in a multivariate logistic regression analysis (14). Preliminary data from our group showed that additional OCT-driven in-stent balloon dilation can significantly reduce the amount of in-stent thrombus area without worsening the microcirculatory indexes (15).

Table 1 The CLI-OPCI Study: Clinical Results

	Angiography Guidance Group (N = 335)	Angiography Plus OCT Guidance Group (N = 335)	p Value
In-hospital events			
Cardiac death	3 (0.9)	2 (0.6)	0.010
Nonfatal MI	22 (6.5)	13 (3.9)	0.096
Events at 1-yr follow-up			
Death	23 (6.9)	11 (3.3)	0.035
Cardiac death	15 (4.5)	4 (1.2)	0.010
MI	29 (8.7)	18 (5.4)	0.096
Target lesion repeat vascularization	11 (3.3)	11 (3.3)	1.0
Definite stent thrombosis	2 (0.6)	1 (0.3)	0.624
Cardiac death or MI	43 (13.0)	22 (6.6)	0.006
Cardiac death, MI, or repeat revascularization	50 (15.1)	32 (9.6)	0.034

Values are n (%). Data from Prati et al. (13).

CLI-OPCI = Centro per la Lotta contro l'Infarto-Optimisation of Percutaneous Coronary Intervention; MI = myocardial infarction; OCT = optical coherence tomography.

Table 2 Clinical Significance of OCT Features of Nonoptimal Stent Deployment

Features	CLI-THRO (17)			CLI-OPCI (13)		
	Subacute Thrombosis	Control	p Value	MACE	Control	p Value
Underexpansion	38.1	17.4	0.12	45.4	25.9	0.079
Malapposition	52.4	37.0	0.29	31.8	30	0.815
Edge dissection	52.4	8.7	0.0003	27.3	3.8	<0.001
Reference lumen narrowing	19.0	4.3	0.07	18.2	2.9	0.007
In-stent thrombus				31.8	12.8	0.022

MACE = major adverse cardiac events; OCT = optical coherence tomography.

IVUS findings of stent underexpansion and a plaque burden >70% at the stent margin represent a risk factor for late restenosis and thrombosis. Only the former can be obtained with OCT, as plaque burden at the stent edge cannot be measured in many circumstances due to the limits in penetration of infrared light. Assessment of stent underexpansion by OCT can be obtained comparing the minimal stent area with the reference lumen area. Additionally, a threshold of absolute minimal lumen cross-sectional area within the stent could be applied, with an area of at least 5.0 to 5.5 mm² previously advocated as the target minimal stent area to prevent failure.

It is rational to assume that OCT's potential for studying luminal irregularities along the stent, at the edges, and in the reference segments is a key element for the improvement of clinical outcome and the prevention of thrombosis. This assumption is based on the concept that lumen reduction either in the stented segments or at the references and edge dissections can be a more frequent cause of flow impairment than plaque dimensions per se.

Data from the OCT arm of the CLI-OPCI (16) seem to corroborate these assumptions. Patients who experienced major adverse cardiac events, despite the use of OCT guidance, more often had a nonoptimal stent deployment. Of note, for all of the OCT criteria for nonoptimal positioning, with the exception of malapposition, differences were highly significant ($p < 0.001$). Excluding malapposition, the percentage of patients who met at least 1 of the OCT criteria for nonoptimal stent deployment was significantly higher in the major adverse cardiac event group compared with the control arm (89% vs. 39%, $p < 0.001$ (Table 1).

A recent study, with a different design, provided similar conclusions. The study addressed the incidence of suboptimal OCT results in 21 consecutive patients exhibiting subacute thrombosis. The patients were matched 1:2 with a control group of 42 patients from the Rome Heart Research core laboratory database (17). OCT showed that minimal lumen area and minimal stent area measurements were significantly smaller in the stent thrombosis group ($p = 0.004$ and $p = 0.03$, respectively). Furthermore, in the group with subacute thrombosis, procedure-related problems such as underexpansion, edge dissection, and reference lumen narrowing were significantly more frequent (Table 2). In line with the CLI-OPCI conclusions,

malapposition was not found to be associated with stent thrombosis.

These preliminary findings shed light on the role of OCT in identifying suboptimal stent positioning as an important cause of acute or subacute stent thrombosis. These observations, consistent with the data provided by the CLI-OPCI trial, also stressed the fact that, in the search for OCT criteria for optimal stent positioning, there is a need to apply explicit quantitative thresholds (Fig. 2).

Furthermore, important prospective information will be provided by the large worldwide OCT registry set up by I. K. Jang, with 3,000 patients scheduled for enrollment.

As a crucial application, OCT can clarify mechanisms of restenosis and thrombosis early or late after the index procedure, guiding repeat revascularization and thus minimizing the risk of additional adverse events (15).

Conclusions

OCT is now on the stage and promises to act as a protagonist. There is obviously a need for more data and, in particular, randomized studies versus coronary angiography to better understand the role of OCT during interventional procedures.

Reprint requests and correspondence: Dr. Francesco Prati, Department of Interventional Cardiology, San Giovanni-Addolorata Hospital, Via Amba Aradam 9, 00184 Rome, Italy. E-mail: fprati@hsangiovanni.roma.it.

From the *Department of Interventional Cardiology San Giovanni Hospital, Rome, Italy; and the †CLI Foundation, Rome, Italy. Dr. Prati is a consultant for St. Jude Medical. Dr. Albertucci has reported that he has no relationships relevant to the contents of this paper to disclose.

REFERENCES

- Jang IK, Bouma BE, Kang DH, et al. Visualization of coronary atherosclerotic plaques in patients using optical coherence tomography: comparison with intravascular ultrasound. *J Am Coll Cardiol* 2002;39:604–9.
- Prati F, Guagliumi G, Mintz GS, et al., Experts OCT Review Document. Expert review document part 2: methodology, terminology and clinical applications of OCT for the assessment of interventional procedures. *Eur Heart J* 2012;33:2513–20.
- Prati F, Regar E, Mintz GS, et al. Expert review document on methodology and clinical applications of OCT. Physical principles, methodology of image acquisition and clinical application for assessment of coronary arteries and atherosclerosis. *Eur Heart J* 2010;31:401–15.

4. Martín-Yuste V, Barros A, Leta R, et al. Factors determining success in percutaneous revascularization of chronic total coronary occlusion: multidetector computed tomography analysis. *Rev Esp Cardiol* 2012; 65:334–40.
5. Tenaglia AN, Buller CE, Kisslo KB, et al. Intracoronary ultrasound predictors of adverse outcomes after coronary artery interventions. *J Am Coll Cardiol* 1992;20:1385–94.
6. Mintz GS, Nissen SE, Anderson WD, et al. ACC Clinical Expert Consensus Document on standards for the acquisition, measurement and reporting of intravascular ultrasound studies: a report of the American College of Cardiology Task Force on Clinical Expert Consensus Documents (Committee to Develop a Clinical Expert Consensus Document on Standards for Acquisition, Measurement and Reporting of Intravascular Ultrasound Studies [IVUS]). *J Am Coll Cardiol* 2001;37:1478–92.
7. Tanaka A, Imanishi T, Kitabata H, et al. Lipid-rich plaque and myocardial perfusion after successful stenting in patients with non-ST segment elevation acute coronary syndrome: an optical coherence tomography study. *Eur Heart J* 2009;30:1348–55.
8. Stone GW, Machara A, Lansky AJ, et al., for the PROSPECT Investigators. A prospective natural-history study of coronary atherosclerosis. *N Engl J Med* 2011;364:226–35.
9. Uemura S, Ishigami K, Soeda T, et al. Thin-cap fibroatheroma and microchannel findings in optical coherence tomography correlate with subsequent progression of coronary atheromatous plaques. *Eur Heart J* 2012;33:78–85.
10. Gerber R, Colombo A. Does IVUS guidance of coronary interventions affect outcome? A prime example of the failure of randomized clinical trials. *Catheter Cardiovasc Interv* 2008;71:646–54.
11. Roy P, Steinberg DH, Sushinsky SJ, et al. The potential clinical utility of intravascular ultrasound guidance in patients undergoing percutaneous coronary intervention with drug-eluting stents. *Eur Heart J* 2008;29:1851–7.
12. Witzensichler B, Machara A, Weisz G, et al. TCT-21 Use of IVUS reduces stent thrombosis: results from the prospective, multicenter ADAPT-DES study (abstr). *J Am Coll Cardiol* 2012; 60 Suppl 17:B6.
13. Prati F, Di Vito L, Biondi-Zoccai G, et al. Angiography alone versus angiography plus optical coherence tomography to guide decision-making during percutaneous coronary intervention: the Centro per la Lotta contro l'Infarto-Optimisation of Percutaneous Coronary Intervention (CLI-OPCI) study. *EuroIntervention* 2012;8:823–9.
14. Porto I, Di Vito L, Burzotta F, et al. Predictors of periprocedural (type IVa) myocardial infarction, as assessed by frequency-domain optical coherence tomography. *Circ Cardiovasc Interv* 2012;5:89–96.
15. Di Giorgio A, Capodanno D, Ramazzotti V, et al. Optical coherence tomography guided in-stent thrombus removal in patients with acute coronary syndromes. *Int J Cardiovasc Imaging* 2013;29:989–96.
16. Chisari A, Kodama T, Di Vito L, et al. Comparative incidence of OCT features indicative of improper stent implantation in the two groups, with and without MACE, of patients who entered in the OCT guided arm of the CLI-OPCI study (abstr). *J Am Coll Cardiol* 2013. In press.
17. Prati F, Kodama T, Di Vito L, et al. Suboptimal stent deployment in presence of sub-acute THROMbosis: a comparative FD-OCT study. From the CLI-foundation investigators: the CLI-THRO study (abstr). Presented at: ESC 2013; August 31 to September 4, 2013; Amsterdam, the Netherlands.

Commentary: OCT Versus IVUS, IVUS Versus OCT

How Is the Interventionalist to Choose?

Gary S. Mintz, MD

Drs. Waksman and Kitabata have outlined the case for intravascular ultrasound (IVUS)-guided stent implantation,

whereas Drs. Prati and Albertucci have outlined the case for optical coherence tomography (OCT)-guided stent implantation. Before addressing the pros and cons of (or differences between) these 2 intravascular imaging techniques, it is worth noting that they are more similar than different; the major difference is not between IVUS and OCT, but between IVUS or OCT and coronary angiography. Both IVUS and OCT provide tomographic views of the coronary artery and identify features of stent implantation (e.g., expansion, inflow/outflow disease, apposition, complications) as well as of mechanisms of stent failure (thrombosis and restenosis) that are missed using coronary angiography alone. Therefore, the major clinical issue may not be whether to use IVUS or OCT, but whether to use 1 of these 2 techniques to complement angiography.

That said, what are the advantages of IVUS? 1) It has been used clinically for 2 decades. 2) Pre-intervention imaging is possible in almost all patients without pre-dilation. 3) Penetration to the adventitia allows mid-wall or true vessel stent sizing. 4) The IVUS predictors of stent failure have been well established. 5) There are 7 randomized IVUS versus angiography-guided bare metal stent implantation trials, a meta-analysis of which has shown that IVUS guidance reduces restenosis and repeat revascularization with no impact on death and myocardial infarction (1). 6) There is 1 meta-analysis of 11 IVUS- versus angiography-guided drug-eluting stent studies involving 19,616 patients showing that IVUS guidance was associated with a reduced incidence of death, major adverse cardiac events, and stent thrombosis (2). This is supported by a small randomized trial from Korea (3) as well as the pre-specified IVUS versus no-IVUS analysis from the ADAPT-DES (Assessment of Dual AntiPlatelet Therapy With Drug Eluting Stents) study (4). What are the disadvantages of IVUS? 1) The images can be difficult to interpret. 2) There have been no fundamental advances in the technology in more than a decade. 3) Tissue characterization (especially thrombus detection) is limited. 4) The resolution of IVUS does not allow assessment of stent-strut tissue coverage.

Conversely, what are the advantages of OCT, especially compared with IVUS? 1) The resolution of OCT is 10 times greater than with IVUS such that OCT detects fine details missed by IVUS (e.g., edge dissections, small amounts of malapposition, tissue coverage of stent struts). 2) Tissue characterization is better, and OCT may be the gold standard for thrombus detection. 3) The images are clearer and easier to interpret, in part because the obligatory flushing clears the lumen of blood. What are the disadvantages of OCT? 1) Flushing is necessary to clear the lumen of blood to visualize the vessel wall. 2) Pre-dilation may be necessary before pre-intervention to allow static blood to be flushed from the lumen. Alternatively, some interventionalists forgo pre-intervention imaging and only perform post-stent OCT so that the potential advantage of pre-stent lesion assessment and stent sizing is lost. 3) With the exception of 1 published study cited by Prati et al. (5) stating that OCT guidance is

better than angiography, there currently is a paucity of data on OCT predictors of stent failure, OCT criteria for stent sizing and optimization, and the clinical benefits of OCT-guided stent implantation.

Should OCT replace IVUS? Some opinion leaders such as Prati and Albertucci say “yes,” but the marketplace (as indicated by Waksman and Kitabata) says “not yet.” Clinical OCT stent studies continue to focus on: 1) detailed and enhanced analysis of mechanisms of stent failure (restenosis and thrombosis), especially neoatherosclerosis; 2) long-term comparisons of different stent platforms (extent of tissue coverage and malapposition); and 3) qualitative analysis of the composition of neointimal tissue. Conversely, there are few clinical studies directed at assessing the utility of the OCT, either diagnostically or during stent-implantation procedures. The paradigms for IVUS guidance and criteria for IVUS optimization that have been developed over the past 2 decades do not translate directly to OCT. Much work needs to be done to define the best OCT-guided stent-sizing strategy and the appropriate endpoints for OCT-guided stent optimization.

Given the improvement in second-generation drug-eluting stents, will it be possible to show that one technique is better than the other? Which of the following is a better predictor of clinical outcomes? OCT-detectable findings that are below the resolution of IVUS? Or true vessel or mid-wall stent sizing that increases stent expansion? Or will it always be personal preference and the 2 techniques will coexist in an uncomfortable détente, each with its advocates? Finally, at the end of the day, the question may not be IVUS or OCT, but whether the adoption of intravascular imaging, regardless of the technique, will continue at its current glacial pace.

Reprint requests and correspondence: Dr. Gary S. Mintz, Cardiology, Cardiovascular Research Foundation, 111 East 59th Street, 11th Floor, New York, New York 10022. E-mail: gsm18439@aol.com.

From the Cardiovascular Research Foundation, New York, New York. Dr. Mintz is a consultant for Boston Scientific, Volcano, and St. Jude; and receives grant or research fellowship support from Boston Scientific, Volcano, and InfraRedX.

REFERENCES

1. Parise H, Machara A, Stone GW, Leon MB, Mintz GS. Meta-analysis of randomized studies comparing intravascular ultrasound versus angiographic guidance of percutaneous coronary intervention in pre-drug-eluting stent era. *Am J Cardiol* 2011;107:374-82.
2. Zhang Y, Farooq V, Garcia-Garcia HM, et al. Comparison of intravascular ultrasound versus angiography-guided drug-eluting stent implantation: a meta-analysis of one randomised trial and ten observational studies involving 19,619 patients. *EuroIntervention* 2012 ;8: 855-65.
3. Kim JS, Kang TS, Mintz GS, et al. Randomized comparison of clinical outcomes between intravascular ultrasound and angiography-guided drug-eluting stent implantation for long coronary artery stenoses. *J Am Coll Cardiol Interv* 2013;6:369-76.
4. Witzenbichler B, Machara A, Weisz G, et al. Use of IVUS reduces stent thrombosis: Results from the prospective, multicenter ADAPT-DES study. Available at: <http://www.tctmd.com/show.aspx?id=116703>. Accessed February 1, 2013
5. Prati F, Di Vito L, Biondi-Zoccai G, et al. Angiography alone versus angiography plus optical coherence tomography to guide decision-making during percutaneous coronary intervention: the Centro per la Lotta contro l'Infarto-Optimisation of Percutaneous Coronary Intervention (CLI-OPCI) study. *EuroIntervention* 2012;8:823-9.

Key Words: coronary artery disease ■ drug-eluting stent(s) ■ imaging ■ intravascular ultrasound ■ optical coherence tomography ■ restenosis ■ stent ■ stent expansion ■ stent thrombosis.