



Contents lists available at ScienceDirect

Schizophrenia Research

journal homepage: www.elsevier.com/locate/schres

Adult outcome of preterm birth: Implications for neurodevelopmental theories of psychosis

Lucy D. Vanes^{a,b,*}, Robin M. Murray^c, Chiara Nosarti^{a,b}

^a Centre for the Developing Brain, Department of Perinatal Imaging and Health, King's College London, UK

^b Department of Child and Adolescent Psychiatry, Institute of Psychiatry, Psychology and Neuroscience, King's College London, UK

^c Department of Psychosis Studies, Institute of Psychiatry, Psychology and Neuroscience, King's College London, UK

ARTICLE INFO

Article history:

Received 25 February 2021

Received in revised form 19 April 2021

Accepted 21 April 2021

Available online xxxx

Keywords:

Preterm birth

Psychosis risk

Neurodevelopment

Cognitive function

Motor function

Social function

ABSTRACT

Preterm birth is associated with an elevated risk of developmental and adult psychiatric disorders, including psychosis. In this review, we evaluate the implications of neurodevelopmental, cognitive, motor, and social sequelae of preterm birth for developing psychosis, with an emphasis on outcomes observed in adulthood. Abnormal brain development precipitated by early exposure to the extra-uterine environment, and exacerbated by neuroinflammation, neonatal brain injury, and genetic vulnerability, can result in alterations of brain structure and function persisting into adulthood. These alterations, including abnormal regional brain volumes and white matter macro- and micro-structure, can critically impair functional (e.g. frontoparietal and thalamocortical) network connectivity in a manner characteristic of psychotic illness. The resulting executive, social, and motor dysfunctions may constitute the basis for behavioural vulnerability ultimately giving rise to psychotic symptomatology. There are many pathways to psychosis, but elucidating more precisely the mechanisms whereby preterm birth increases risk may shed light on that route consequent upon early neurodevelopmental insult.

© 2021 The Author(s). Published by Elsevier B.V. This is an open access article under the CC BY license (<http://creativecommons.org/licenses/by/4.0/>).

1. Introduction

Prenatal and perinatal complications have been implicated in the aetiology of psychosis since the 1930s (Rosanoff et al., 1934) but assumed a greater importance with the genesis of the neurodevelopmental hypothesis of schizophrenia (Lewis and Murray, 1987; Murray and Lewis, 1987; Weinberger, 1987). While the hypothesis has evolved over the years to include the complex interactions of a diverse set of genetic, environmental, and social risk factors occurring throughout development (Murray et al., 2017), a recent meta-analysis made it clear that associations between perinatal events and elevated psychosis risk remain important (Davies et al., 2020).

Being born preterm (i.e., before 37 completed weeks of gestation), very preterm (<33 weeks), or extremely preterm (<28 weeks) is associated with a heightened risk of adverse neurological and psychological outcomes from infancy to adulthood. This risk can be at least partly attributed to the sudden and premature exposure of the rapidly developing brain to the extrauterine environment during a critical period for synaptic formation, dendritic differentiation, layering of cortical neurons and glial proliferation (Kostović and Jovanov-Milošević, 2006;

Kostović and Judaš, 2010). Preterm birth has been associated with severe brain injury (Volpe, 2009), but also with more subtle brain alterations involving white matter microstructure (Kelly et al., 2016), global structural topology (Batalle et al., 2017), functional connectivity (Ball et al., 2016) and cortical morphology (Ball et al., 2020). Mirroring this, outcomes of preterm birth range from subclinical psychological characteristics, such as mild inattention, to lifelong neurological disorders, such as cerebral palsy (Fawke, 2007; Johnson and Marlow, 2011).

Preterm birth is also a significant risk factor for psychiatric disorders (Johnson and Wolke, 2013; Nosarti et al., 2012; Walshe et al., 2008), though most research in this regard has focused on developmental childhood disorders such as attention-deficit hyperactivity disorder (ADHD) and autism-spectrum disorders (ASD) (Johnson and Marlow, 2011). Prospective research on adult psychiatric outcomes of preterm birth is more recent (Robinson et al., 2020; Taylor, 2017), as the generation of preterm infants who survived thanks to advances in neonatal intensive care practices (e.g. antenatal corticosteroids, surfactant therapy, and high-frequency ventilation (Manley et al., 2015)) has now reached adulthood. Hence, the need to better understand the long-term sequelae of prematurity is ever increasing.

Epidemiological studies have demonstrated an association between preterm birth and increased psychosis risk (Mathiasen et al., 2011; Nosarti et al., 2012). However, the mechanism and specificity of this link are less clear. Psychosis typically first occurs in early adulthood, but is often preceded by prodromal signs of functional decline and

* Corresponding author at: Centre for the Developing Brain, King's College London, School of Biomedical Engineering & Imaging Sciences, 4th Floor, Lambeth Wing, St Thomas' Hospital, Westminster Bridge Road, London SE1 7EH, UK.
E-mail address: lucy.vanes@kcl.ac.uk (L.D. Vanes).

attenuated psychotic symptoms (Poletti and Raballo, 2020), and is characterised by neural alterations that can be traced back to earlier stages of development (Walker and Bollini, 2002), such as accelerated fronto-temporo grey matter loss (McIntosh et al., 2011) and reduced connectivity of large scale brain networks (Nath et al., 2020). There is a partial but notable overlap between the neural, cognitive, and behavioural profiles of adults with psychosis and those born preterm. In this review, we critically evaluate findings relating to adult outcomes of preterm birth which may shed light on the pathways to psychosis in this population. To this end, we draw in particular (but not exclusively) on findings from an unprecedented longitudinal study of individuals born very preterm and admitted to the neonatal unit of University College London Hospital (UCLH) between 1979 and 1985; this was the first cohort in the world to undergo intensive neonatal brain ultrasonography. The infants were then followed up at several time points into adulthood using neurocognitive and behavioural assessments as well as magnetic resonance imaging (MRI). Studies reporting on outcomes of the UCLH cohort in adulthood are listed in Table 1.

2. General overview: preterm birth and psychopathology

There has been substantial research on the psychological consequences of preterm birth in childhood and adolescence. Accumulating evidence in preterm-born children has converged on the identification of a so-called “preterm behavioural phenotype”, characterised by increases in anxiety, inattention, and social impairments, coupled with executive function deficits (Johnson and Marlow, 2011). This profile appears to extend into adolescence, manifesting in an increased prevalence of diagnosed ADHD, ASD, and affective disorders (Johnson and Wolke, 2013). Preterm adolescents are at a 3-to-4-fold increased risk of being diagnosed with any psychiatric disorder compared to their term-born peers, representing a prevalence of approximately 25% (Burnett et al., 2011; Johnson and Wolke, 2013). Sub-clinically, dimensional measures capture increased liability for experiencing a wide range of symptoms including social (Healy et al., 2013) and emotional difficulties (Indredavik et al., 2005) in adolescence, which may impact on daily function even in the absence of a formal diagnosis.

In adulthood, population linkage and meta-analytic studies have found that the risk of psychiatric hospitalisation is significantly related to the degree of prematurity (Lindström et al., 2009; Nosarti et al., 2012), and preterm-born young adults are substantially more likely to be diagnosed with a psychiatric disorder (Burnett et al., 2011; Mathiasen et al., 2011; Nosarti et al., 2012) or be prescribed psychotropic medication (Robinson et al., 2020) than their term-born counterparts. Comparatively few studies have assessed psychopathology dimensionally in preterm adults; however, a meta-analysis of 6 studies investigating self-reported mental health problems in adults born preterm at very low birth weight found significant increases in internalising problems and socially avoidant behaviour compared to term-born adults (Pyhälä et al., 2017). In a recent study assessing psychiatric symptoms dimensionally in the UCLH cohort, we found preterm-born adults aged 30 to have elevated total psychopathology as well as increased positive, negative, and cognitive symptoms compared to term-born controls (Kroll et al., 2018).

Despite the many studies retrospectively examining a history of pre- and perinatal events in schizophrenia, there is very little research linking preterm birth specifically to psychotic disorders and symptoms. While preterm birth is indeed associated with an increased risk of being diagnosed with non-affective psychosis in adult life (Nosarti et al., 2012), this risk does not appear to be specific to psychotic disorder at the population level. Thus, it is possible that preterm birth confers a transdiagnostic biological vulnerability to psychopathology in adulthood, preceded by a more specific behavioural profile in childhood and adolescence. Different aspects of this profile in conjunction with intervening environmental factors may precipitate different trajectories in the expression of psychopathology during the transition to adulthood, leading to increased diagnostic heterogeneity and comorbidities

amongst preterm-born adults. Potential risk factors for and precursors of psychosis arising as a result of preterm birth in adulthood will now be discussed.

3. Adult sequelae of preterm birth and psychosis risk

3.1. Neurodevelopment

Preterm birth is a leading cause of brain injury, mostly due to perinatal hypoxia-ischemia, which can result in damage in particular to the periventricular white matter and basal ganglia (Back, 2015; Logitharajah et al., 2009; Volpe, 2009). However, even in the absence of severe or obvious brain injury, preterm birth can result in subtle changes in neural architecture that are evident throughout development and into adulthood (Nagy et al., 2009; Nosarti et al., 2002; Nosarti et al., 2014), and which have been related to a range of neurocognitive difficulties (Hadaya and Nosarti, 2020; Kanel et al., 2020).

There are several overlapping brain alterations associated with preterm birth and with psychotic disorder. One of the most commonly observed abnormalities following preterm birth is ventricular enlargement (often following peri/intraventricular haemorrhage, P/IVH), with a large proportion of preterm infants showing increased ventricle size at term-equivalent age (i.e., the age at which they would have been born had they not been premature) (Hart et al., 2008). Ventricular enlargement has also been observed in preterm adolescents and adults (Allin et al., 2011; Cooke and Abernethy, 1999; Hedderich et al., 2020; Nosarti et al., 2002; Stewart et al., 1999). Neurodevelopment of regions adjacent to the lateral ventricles are preferentially disrupted following P/IVH; consequently post-haemorrhagic ventricular enlargement is associated with reduced deep grey matter volumes (Brouwer et al., 2016) and periventricular white matter damage (Larroque et al., 2003) at term-equivalent age. Evidence from the UCLH study suggests that these alterations are likely to have long-lasting effects on brain structure and function. Thus, very preterm adults exhibit an association between ventricle size and impaired microstructural integrity of widespread white matter tracts (Allin et al., 2011), and ventricular enlargement resulting from perinatal brain injury is related to abnormal frontal (Kalpakidou et al., 2014) and frontoparietal (Froudast-Walsh et al., 2015) neural activation during working memory processing.

Increased ventricle size is also one of the most replicated neuroimaging findings in chronic schizophrenia (Olabi et al., 2011; van Erp et al., 2016), with additional evidence for ventricular enlargement at the stage of the prodrome (Chung et al., 2017) and first episode of psychosis (Steen et al., 2006; Vita et al., 2006), and even in male neonates at high genetic risk for schizophrenia (Gilmore et al., 2010). It appears to worsen over the course of the illness (Kempton et al., 2010) but at least some of this is related to the effects of antipsychotics (Murray et al., 2016). Numerous studies have found associations between ventricular abnormalities and a history of obstetric complications in patients with schizophrenia (Costas-Carrera et al., 2020), with a strong likelihood that complications during delivery interact with genetic risk for psychosis in contributing to these abnormalities (Cannon et al., 1989; Falkai et al., 2003). Ventricular enlargement following preterm birth may therefore represent a marker of increased underlying vulnerability to psychosis.

Similarly, white matter abnormalities are common in both preterm and psychosis populations. The most frequent form of brain injury following preterm birth is periventricular leukomalacia (PVL), defined as either focal (necrotic) or diffuse damage to the periventricular white matter. Diffuse PVL is thought to impact on premyelinating oligodendrocytes, which can subsequently result in an impairment of axonal myelination (Iida et al., 1995; Volpe, 2009). Myelination of the brain's connective white matter tracts is known to extend well into adulthood (Miller et al., 2012) and underpins the efficiency of neuronal signal conduction, providing a crucial basis for brain connectivity. Healthy cognitive functioning is dependent on effective communication between

Table 1

Adult outcome studies of the University College London Hospital (UCLH) study in very preterm (VPT) and full term (FT) born individuals.

First author (year)	N	Age	Type	Task(s)	Findings
Allin et al. (2006b)	VPT: 153 FT: 71	18	Neurological assessment	Neurological Evaluation Scale	• VPT > FT neurological signs; associated with reduced neuropsychological function
Allin et al. (2006a)	VPT: 108 FT: 67	18	Personality assessment	Eysenck Personality Questionnaire-Revised	• VPT < FT extraversion scores
Nosarti et al. (2007)	VPT: 61 FT: 64	22	Cognitive assessment	WASI; Hayling Sentence Completion Test; Controlled Oral Word Association Test; Animal and Object test; Trail-Making Test; Test of Attentional Performance	• VPT > FT neuroticism and lie scores • VPT < FT executive function involving response inhibition and mental flexibility
Walshe et al. (2008)	VPT: 169 FT: 101	18	Psychopathology assessment	Clinical Interview Schedule – Revised	• VPT > FT risk for psychiatric disorder • VPT individuals with family history of psychiatric disorder were particularly vulnerable
Kontis et al. (2009)	VPT: 111 FT: 45	19	Diffusion MRI, cognitive assessments	WASI; California Verbal Learning Test	• VPT > FT MD in genu of the corpus callosum; associated with lower IQ • Differential correlation between verbal learning and callosal FA and MD between groups
Lawrence et al. (2009)	VPT: 26 FT: 21	20	Task-based fMRI	Go/No-Go with attentional oddball condition	• No group difference in task performance • VPT > FT BOLD signal in medial and right lateral posterior regions during response inhibition • VPT < FT BOLD signal in fronto-parietal-cerebellar network during oddball trials
Narberhaus et al. (2009)	VPT: 21 FT: 22	20	Task-based fMRI; structural T1	Visual paired associates task	• No group difference in task performance. • VPT > FT BOLD signal in left caudate, right cuneus, and left superior parietal lobule during encoding • VPT < FT BOLD signal in right inferior frontal gyrus during encoding • VPT > FT BOLD signal in right cerebellum and anterior cingulate during recognition • Reduced grey matter in bilateral hippocampus in VPT compared to controls
Nosarti et al. (2009)	VPT: 28 FT: 26	20	Task-based fMRI; structural T1	Verbal fluency task	• No group difference in task performance • VPT < FT BOLD signal in anterior cingulate, right caudate, and left inferior frontal gyrus during easy trials; in left middle frontal gyrus during hard trials • VPT > FT BOLD signal in anterior cingulate gyrus during hard trials • fMRI results partly explained by altered grey matter distribution (putamen, uncus, middle temporal gyrus) in VPT compared to controls
Lawrence et al. (2010)	VPT: 22 FT: 22	20	Task-based fMRI; structural T1	Verbal paired associates task	• No group difference in task performance. • VPT > FT BOLD signal in left parahippocampal and precentral gyri during encoding • VPT > FT BOLD signal in precentral gyrus during recall • VPT < FT grey matter volume in bilateral hippocampi • VPT > FT grey matter volume in left parahippocampal gyrus; was associated with parahippocampal activation in VPT during encoding
Allin et al. (2011)	VPT: 80 FT: 41	19	Diffusion MRI, cognitive assessments	WASI; Controlled Oral Word Association Test; Hayling Sentence Completion Test; California Verbal Learning Test; Wechsler Memory Scale immediate and delayed picture recall	• VPT < FT performance in all cognitive domains except Wechsler Memory Scale • VPT > FT lateral ventricular volume • VPT < FT total grey and white matter volumes; FA in corpus callosum, superior longitudinal fasciculi, and left superior corona radiata; associated with worse IQ and memory performance • VPT > FT FA in inferior fronto-occipital fasciculi, uncinate fasciculi, superior longitudinal fasciculi and anterior corona radiata
Kalpakidou et al. (2014)	VPT: 32 FT: 17	20	Task-based fMRI	Verbal fluency task, n-back task	• No group difference in task performance • VPT > FT BOLD signal with increasing task difficulty in frontal, temporal, and parietal cortices, caudate, insula, and thalamus during verbal fluency • Increased BOLD signal in VPT with history of PVH and ventricular dilatation compared to VPT with uncomplicated PVH during n-back task
Lawrence et al. (2014)	VPT: 20 FT: 20	20	Task-based fMRI, structural T1	Cued motor task	• No group difference in task performance • VPT > FT BOLD signal in right cerebellum, lingual, parahippocampal, and middle temporal gyri • Increased cerebellar activation associated with decreased grey matter volume in premotor and middle temporal cortices
Nosarti et al. (2014)	VPT: 68 FT: 43	19	Structural T1, cognitive assessments	Hayling Sentence Completion Test, Controlled Oral Word Association Test, Visual Reproduction test of the Wechsler Memory Scale	• VPT < FT grey matter volume in frontal, temporal, insular, and occipital cortices, thalamus, caudate, and putamen • VPT > FT grey matter volume in medial frontal gyrus

(continued on next page)

Table 1 (continued)

First author (year)	N	Age	Type	Task(s)	Findings
White et al. (2014)	VPT: 29 FT: 23	28	Resting-state fMRI, cognitive assessments	WASI, Hayling Sentence Completion Test,	<ul style="list-style-type: none"> • VPT < FT white matter volume in frontal, temporal, and parietal, and callosal regions • VPT > FT white matter volume in parahippocampal and occipital cortices and cerebellum • White matter volume beneath inferior frontal gyrus associated with IQ; callosal white matter and temporal grey matter volume associated with executive function • VPT < FT executive function • VPT < FT functional connectivity of the striatal salience network with the posterior default-mode network • Association between functional connectivity and executive function scores moderated by perinatal variables in the VPT
Cole et al. (2015)	VPT: 65 FT: 36	15, 19	Structural T1, Psychopathology assessment	Peters' Delusional Inventory	<ul style="list-style-type: none"> • No group difference in hippocampal volumes • Hippocampal subregions deformations reflecting atrophy in VPT • Baseline hippocampal volume associated with delusional ideation t follow-up
Nam et al. (2015)	VPT: 160 FT: 88	15, 20	Structural T1, cognitive assessments	WASI; Wechsler Memory Scale Revised; California Verbal Learning Test; Controlled Oral Word Association Test; Hayling Sentence Completion Test	<ul style="list-style-type: none"> • VPT < FT on all tasks except verbal memory • VPT > FT cortical thickness in frontal, occipital, temporal, and insular cortices • VPT < FT cortical thickness in bilateral medial temporal and left insular cortices • More extensive cortical thinning in VPT from 15 to 20 • Cortical thinning in left temporal pole, right occipitotemporal gyrus, and superior parietal lobe associated with executive functioning
Froudust-Walsh et al. (2015)	VPT: 41 FT: 21	30	Task-based fMRI, diffusion MRI	n-back task	<ul style="list-style-type: none"> • No group difference in task performance • VPT-PBI < FT BOLD signal in fronto-parietal regions and increased BOLD signal in perisylvian cortex • VPT-PBI: smaller dorsal cingulum volume associated with increased BOLD signal in perisylvian cortex • Increased BOLD signal in perisylvian cortex associated with better task performance • VPT > FT rich-club index
Karolis et al. (2016)	VPT: 51 FT: 60	30	Diffusion MRI, cognitive assessments	WASI; Trail Making Test; Controlled Oral Word Association Test; Animal Naming test and the Object Naming test; Hayling Sentence Completion Test; Visual Paired Associate Learning task; Intra-/Extra-Dimensional Shift task	<ul style="list-style-type: none"> • Simulated lesion approach suggests altered role for basal ganglia and motor connections in VPT, associated with information flow, rule learning and verbal IQ. • VPT < FT cingulum and fornix volume, associated with memory performance
Caldinelli et al. (2017)	VPT: 84 FT: 48	19	Diffusion MRI, cognitive assessments	California Verbal Learning Test; Visual Reproduction Test of Wechsler Memory Scale-Revised; WASI	
Kroll et al. (2017)	VPT: 122 FT: 89		Cognitive assessments	WASI; Hayling Sentence Completion Test; Controlled Oral Word Association Test; CANTAB SOC; CANTAB IED; TMT-B; Continuous Performance Test; Global Role Functioning Index	<ul style="list-style-type: none"> • VPT < FT executive function and IQ • Executive function score more strongly correlated with real-life achievement measures in VPT • VPT-PBI < FT striatal dopamine synthesis capacity • VPT-PBI < FT hippocampal volume • VPT < FT memory task performance • VPT < FT BOLD signal in right middle frontal gyrus and posterior cingulate cortex • VPT > FT BOLD signal in left inferior frontal gyrus and bilateral lateral occipital cortex • VPT < FT hippocampus, fornix, and cingulum volumes • VPT > FT positive, negative, cognitive, and behavioural symptoms, associated with lower IQ in VPT
Froudust-Walsh et al. (2017)	VPT: 29 FT: 14	30	[18F]-DOPA PET, structural T1		
Tseng et al. (2017)	VPT: 49 FT: 50	30	Task-based fMRI, diffusion MRI, structural T1	Recognition memory task	
Kroll et al. (2018)	VPT: 152 FT: 96		Cognitive and psychopathology assessment	WASI, Comprehensive Assessment of At-Risk Mental States	
Tseng et al. (2019)	VPT: 64 FT: 36	30	Task-based fMRI, diffusion MRI	Verbal fluency task	<ul style="list-style-type: none"> • VPT < FT task performance in hard (but not easy) trials • VPT < FT hemodynamic response suppression in superior temporal gyrus, insula, thalamus, and sensorimotor cortex • VPT > FT arcuate fasciculus left-laterality • Linear association between IQ and gestational age for VPT participants born between 25 and 33 weeks of gestation • VPT < FT cortical gyrification in frontal, anterior temporal, and occipitoparietal lobes; was associated with lower IQ and higher psychopathology.
Kroll et al. (2019)	VPT: 258	8-31	Cognitive assessment	WASI	
Papini et al., 2020	VPT: 79 FT: 81	30	Structural T1, cognitive and psychopathology assessment	WASI; Comprehensive Assessment of At-Risk Mental States	

Abbreviations: VPT = very preterm birth; FT = full term; WASI = Wechsler Abbreviated Scale of Intelligence; fMRI = functional magnetic resonance imaging; MD = mean diffusivity; FA = fractional anisotropy; BOLD = blood oxygen level dependent; PVH = periventricular haemorrhage; PBI = perinatal brain injury.

disparate brain regions and, accordingly, structural dysconnectivity (e.g., detected with diffusion imaging techniques) is associated with impaired cognitive functioning in various populations, including preterm-born individuals (reviewed in Hadaya and Nosarti, 2020) and those

with psychosis (Kelly et al., 2019). Even in the absence of severe PVL observed with conventional MRI, premature infants typically exhibit altered patterns of white matter maturation (Anjari et al., 2007; Batalle et al., 2017; Kelly et al., 2016).

In very preterm adults enrolled in the UCLH study, we have observed abnormalities both in the microstructure (Allin et al., 2011; Froudist-Walsh et al., 2015; Tseng et al., 2019; Tseng et al., 2017) and volumes (Caldinelli et al., 2017; Nosarti et al., 2014; Tseng et al., 2017) of white matter structures compared to term-born controls. Overlapping observations have also been made in other adult cohorts, showing microstructural changes particularly in the corpus callosum and cingulum (Eikenes et al., 2011; Meng et al., 2016; Pascoe et al., 2019) but also extending to other core white matter tracts, which is further reflected in reduced global white matter volume in preterm individuals (Soria-Pastor et al., 2008). Several studies in preterm-born adults have shown impaired cognitive performance to be associated with reduced fractional anisotropy (FA) (Allin et al., 2011; Eikenes et al., 2011) or volume (Caldinelli et al., 2017) of specific white matter tracts, mirroring findings in younger cohorts (Skranes et al., 2007; Vollmer et al., 2017). Interestingly, however, several studies have shown that impaired structural white matter integrity may result in neural compensation at the functional level, allowing for comparable task performance to term-born controls (Froudist-Walsh et al., 2015; Salvan et al., 2017). This mechanism speaks in favour of adaptive plastic processes which are achieved in the preterm brain in order to compensate for the early insult. Using network analysis, we have found that despite a relative paucity of white matter resources, preterm adults display a stronger “rich-club” architecture compared to term-born controls, suggesting that in the face of anatomical constraints, global connectivity is prioritised over other, more peripheral, connections (Karolis et al., 2016). A simulated “lesion” approach further suggested that the basal ganglia in particular played an altered role in supporting global connectivity compared to term-born adults (Karolis et al., 2016). In addition, preterm adults from the same cohort showed compromised functional connectivity between striatal aspects of the salience network and the default mode network (White et al., 2014), suggesting that between-network connectivity is critically impaired in these individuals. Further evidence for an altered role played by the basal ganglia comes from a study showing that structural volumetric abnormalities in the striatum are associated with abnormal functional connectivity in a basal ganglia network in preterm-born adults (Bäuml et al., 2015).

These observations raise interesting possibilities with respect to psychosis risk. Schizophrenia has frequently been conceptualised as a “disconnection syndrome” (Friston and Frith, 1995), whereby aberrant structural brain connectivity leads to a disintegration of effective mental functioning. It therefore seems plausible that an impairment in white matter integrity rooted in neurodevelopment may constitute a significant risk factor for psychosis (Bullmore et al., 1997; Kochunov and Hong, 2014). In fact, altered structural connectivity has been detected in infant offspring of women with schizophrenia, suggesting that genetic high risk impacts brain connectivity early on in development (Ahn et al., 2019; Shi et al., 2012). Fronto-striatal connectivity in particular has been implicated in psychosis (Dandash et al., 2017; Robbins, 1990), in line with the notion that psychotic symptoms arise as a result of aberrant integration of top-down cortical and bottom-up subcortical signals, precipitated by aberrant striatal dopamine functioning (Howes and Kapur, 2009). If, in the preterm brain, overall connectivity indeed relies more heavily on basal ganglia connections than normally expected (Bäuml et al., 2015; Karolis et al., 2016), one might hypothesise that any disturbance of the basal ganglia occurring in early adulthood could disproportionately affect global connectivity, potentially mimicking striatal dysregulation typically observed in psychosis (Bullmore et al., 1997). Abnormal striatal dopamine functioning appears to be a key mechanism underlying positive psychotic symptoms (Howes and Murray, 2014). Preterm adults without brain injury were shown to have normal striatal dopamine synthesis capacity, and preterm adults with perinatal brain injury showed reduced dopamine synthesis capacity (Froudist-Walsh et al., 2017). This latter contrasts with the increased dopamine synthesis capacity typically observed in psychosis patients (Howes and Murray, 2014); however, another risk factor associated

with schizophrenia, notably heavy cannabis use, has also been associated with decreased striatal dopamine (Bloomfield et al., 2014). One possibility is that this may be associated with supersensitivity of the dopamine D2 receptor (Murray et al., 2014), and that disruption of normal dopamine signalling either presynaptically or postsynaptically may lead to psychosis (Seeman and Seeman, 2014).

It has been suggested that glial cell abnormalities are critically involved in white matter pathology and subsequent symptomatology observed in psychosis and schizophrenia (Dietz et al., 2020). There is evidence for impaired glial progenitor cell differentiation in schizophrenia, resulting in delayed maturation of oligodendrocytes and therefore disrupted myelination in early development (Kerns et al., 2010; Windrem et al., 2017). Impaired progenitor cell differentiation may be precipitated by untimely microglial activation during late fetal development, e.g. as a result of maternal infection, and indeed increased risk of schizophrenia is associated with maternal infection in mid- to late pregnancy (Brown et al., 2004), when oligodendrocyte maturation is most sensitive to microglial activation (Chew et al., 2013). In terms of timing, preterm birth is of particular relevance here. Maternal-fetal inflammatory response and concomitant glial activation is indeed strongly implicated in prematurity (Mallard et al., 2019; Supramaniam et al., 2013) and is known to be associated with subsequent neurodevelopmental disorders such as ASD (Bokobza et al., 2019). Recent multimodal research has leveraged advances in imaging genomics to shed further light on glial cell involvement in altered brain development following preterm birth. Work here has demonstrated that the neurodevelopmental effects of prematurity are temporally and spatially coincident with developmental processes involving cortical glial cell populations (Ball et al., 2020), and that the microglial inflammatory response is implicated in structural white matter changes resulting from brain injury following preterm birth (Krishnan et al., 2017a). Thus, it is possible that neuroinflammation related to preterm birth and subsequent glial pathology could contribute to brain alterations characteristic of later psychotic illness.

On a macrostructural level, there is also evidence for volumetric grey matter abnormalities in preterm adults, with potential relevance for psychosis risk. Alterations of the grey matter are being increasingly recognised as important contributing factors to neurodevelopmental disorder and other psychopathologies following preterm birth (Fleiss et al., 2020). Young adults of the UCLH study showed reduced grey matter volume (GMV) in widespread regions including frontal, temporal, insular, subcortical, and occipital areas (Nosarti et al., 2014). Less extensive increases in GMV were found in medial and anterior frontal regions. Similar findings were also observed when the preterm individuals were adolescents (Nosarti et al., 2008), suggesting that volumetric differences are not a mere result of developmental delay, with individuals “catching up” by adulthood, but rather constitute permanent structural alterations. Studies in other cohorts confirm this, with reduced regional and global grey matter volumes being observed in both adult (Bäuml et al., 2015; Meng et al., 2016; Pascoe et al., 2019; Shang et al., 2019) and younger (de Kieviet et al., 2012) preterm samples. Perinatal brain injury was furthermore shown to exacerbate the observed structural changes (Nosarti et al., 2014). Abnormal GMV also partially accounted for altered brain activation during a verbal executive function task, once more suggesting processes of functional plasticity compensating for structural deficits (Nosarti et al., 2009).

Meta-analyses of structural brain changes in individuals at high clinical risk of psychosis as well as those experiencing a first episode of psychosis (FEP) provide evidence for reduced GMV in frontal, temporal and insular cortices (Fusar-Poli et al., 2012b; Radua et al., 2012). Subcortical and insular GMV reductions are also seen in those at high familial risk of psychosis (Cooper et al., 2014). The reoccurrence of abnormalities of the insula may be of particular interest here, as this is a major hub of localisation of the transient bursting of spontaneous neuronal events that are critical for brain maturation in preterm infants (aged between 32 and 36 postmenstrual weeks) (Arichi et al., 2017) and as development of insular connections is preferentially affected following preterm

birth, with alterations modulated by genetic factors (Krishnan et al., 2017b). Furthermore, impaired integrity of the anterior insula appears to represent a transdiagnostically shared neural substrate of mental illness across psychiatric disorders (Goodkind et al., 2015; McTeague et al., 2017). Thus, evidence again points towards an interaction of genetic liability for psychiatric disorder and perinatal factors including preterm birth in contributing to neurodevelopmental alterations that further increase the risk of experiencing psychopathology such as psychosis.

Reduced volumes of the hippocampus and parahippocampal gyrus have also been associated with clinical (Fusar-Poli et al., 2012b) and genetic (Boos et al., 2007; Fusar-Poli et al., 2014) high risk for psychosis. Schizophrenic patients who have suffered obstetric complications including prematurity were found to be especially likely to show decreased volume of the hippocampus (Stefanis et al., 1999). Reduced hippocampal volume is apparent in preterm-born infants by term-equivalent age (Ball et al., 2013), though findings at later ages are more mixed (Aanes et al., 2015; Fraello et al., 2011; Nosarti and Froudish-Walsh, 2016; Omizzolo et al., 2013). Of note, the hippocampus is known to follow a dynamic and highly heterogeneous maturational trajectory, with both gain and loss of regional volume observed throughout development (Gogtay et al., 2006). In adulthood, very preterm born UCLH study participants showed hippocampal shape changes consistent with atrophy, despite no overall volume difference compared to term-born adults (Cole et al., 2015). Intriguingly, this longitudinal study found that larger hippocampal volume in adolescence was associated with increased delusional ideation in early adulthood. Though initially counterintuitive, this finding is consistent with observations that individuals with an At Risk Mental State (ARMS) for psychosis show increased hippocampal volume before transitioning to psychosis, contrasting with reduced hippocampal volume in first episode psychosis patients (Buehlmann et al., 2010).

Finally, cortical gyrification (i.e., the folding of the cortical surface), which predominantly occurs in fetal life, is delayed in preterm infants (Dubois et al., 2019; Engelhardt et al., 2015). Recent work demonstrated that altered gyrification is also evident in preterm adults, and crucially mediates the effect of prematurity on general IQ reduction (Hedderich et al., 2019). These findings were extended on by work from the UCLH study showing that abnormal gyrification in preterm adults was related not only to lower IQ but also increased psychopathology (Papini et al., 2020). Strikingly, the pattern of abnormal cortical folding overlapped considerably with that observed in adolescents with a diagnosis of schizophrenia (Palaniyappan and Liddle, 2012) with alterations involving the inferior frontal, insular, and superior temporal cortices.

Taken together, neurobiological abnormalities following preterm birth are widespread and heterogeneous, and are likely to confer a general vulnerability to psychiatric disorder. However, within this heterogeneity, it is possible that certain neurodevelopmental trajectories are indicative of clinical risk for psychosis more specifically. Moreover, recent evidence supports the notion that genetic vulnerability to psychiatric illness (as measured by polygenic risk scores) interacts with the environmental stress caused by preterm birth to promote neuroanatomical abnormalities of the lentiform nucleus (Cullen et al., 2019) (which together with the caudate forms the striatum); this in turn may further compound the risk of experiencing psychopathology. Therefore, where prematurity coincides with genetic risk for psychosis and results in brain injury, the pre-existing vulnerability is likely to be exacerbated. Ventricular enlargement resulting from perinatal brain injury may be a particular marker of vulnerability to psychosis. In addition, brain tissue abnormalities, especially where they affect fronto-insular-temporal or hippocampal cortex, as well as fronto-striatal connectivity, likely underlie an increased risk for psychosis in preterm individuals. Importantly, many of the brain alterations observed in preterm or psychosis samples also mediate a range of cognitive deficits, which will be discussed in more detail in the following section.

3.2. Cognitive function

Cognitive impairment in psychosis spans multiple domains including executive functioning (Reichenberg and Harvey, 2007), language-related abilities (Condray, 2005), and social cognition (covered in more detail in Section 3.4) (Sheffield et al., 2018). Executive dysfunction in particular is a hallmark of schizophrenia, with deficits thought to be underpinned by neural abnormalities notably of the prefrontal and anterior cingulate cortices (Minzenberg et al., 2009). Importantly, cognitive deficits are already evident in childhood in individuals who go on to develop schizophrenic psychosis (Fusar-Poli et al., 2012a; Jones et al., 1994). It has consequently been suggested that cognitive impairment lies, at least in part, on the causal pathway linking genetic or developmental risk factors with the development of psychosis (Reichenberg, 2005), and is therefore an early indicator of psychosis risk.

Cognitive development in children and adolescents born preterm has also been studied extensively (Johnson, 2007). A recent meta-analysis of cognitive outcomes concluded that very preterm born children exhibit medium to large deficits in general intelligence, executive functioning, and processing speed (Brydges et al., 2018). Many of these deficits are associated with early regionally specific neuroanatomical changes (Batalle et al., 2018). For example, thalamocortical (Ball et al., 2015) and callosal (Pannek et al., 2020) connectivity assessed at term-equivalent age are predictive of cognitive abilities in toddlers, whereas neonatal microstructural integrity of the arcuate fasciculus predicted language ability at the age of 2 (Salvan et al., 2017). Neonatal volumes of insula and putamen are associated with maths skills aged 5 and 7 (Ullman et al., 2015), and 8-year olds show smaller cortical volumes that are associated with general IQ (Peterson et al., 2000). Several studies have investigated which cognitive deficits persist into adulthood (Breeman et al., 2015; De Jong et al., 2012; Eryigit Madzwamuse et al., 2015; Løhaugen et al., 2010); the UCLH study in particular has shed light on the neural correlates of cognition in preterm adults (Allin et al., 2011; Kalpakidou et al., 2014; Kontis et al., 2009; Lawrence et al., 2010; Lawrence et al., 2009; Narberhaus et al., 2009; Nosarti et al., 2007; Nosarti et al., 2006; Nosarti et al., 2009).

Preterm born adults tend to score lower on average than term-born controls on IQ tests (Breeman et al., 2015; Kroll et al., 2019; Løhaugen et al., 2010). However, even accounting for these differences in IQ, preterm adults exhibit further cognitive deficits, particularly in executive functioning. In the first broad assessment of executive function in very preterm young adults, our group reported impairments in tasks involving response inhibition and mental flexibility (Nosarti et al., 2007). Impaired executive functioning was furthermore associated with poorer real-life achievements in these adults (Kroll et al., 2017). When investigating the neural correlates of executive functioning in the UCLH cohort, we also found that in spite of good performance on a response inhibition task, preterm adolescents and adults compared to controls displayed altered task-related haemodynamic responses, which may indicate alternative processing strategies in these individuals (Lawrence et al., 2009; Nosarti et al., 2006). This is underlined by findings from an independent cohort that preterm adults show a haemodynamic response characteristic of predominantly reactive- rather than proactive cognitive control, suggesting alternative neural strategies despite similar task performance (Olsen et al., 2018). Similar observations were made with respect to verbal fluency (Kalpakidou et al., 2014; Nosarti et al., 2009) and verbal and visual associative learning (Lawrence et al., 2010; Narberhaus et al., 2009) tasks, during which preterm adults showed altered brain activation in the absence of performance differences. These findings in adults are in line with a considerable body of work in preterm children demonstrating engagement of alternative neural circuits, especially in the context of language processing (Barde et al., 2012; Barnes-Davis et al., 2018; Lubsen et al., 2011; Ment et al., 2006). Overall, while cognitive performance in preterm-born adults compared to term-born controls depends on the specific task domain (and difficulty) under study, performance does appear to

be associated with neuroanatomical alterations associated with preterm birth. For example, deficits in global executive functioning in preterm adults were found to be mediated by reduced temporal grey matter and callosal white matter volumes (Nosarti et al., 2014). Microstructural changes of the corpus callosum in preterm adults are also associated with lower IQ, verbal learning, and memory performance (Allin et al., 2011; Kontis et al., 2009).

Taken together, these findings suggest that neurodevelopmental abnormalities associated with preterm birth necessitate a functional reorganisation of executive processes, but nevertheless can result in persisting cognitive deficits. Some of these deficits and their associated neural changes overlap with those seen in psychosis: for example, impaired inhibitory control is associated with similar patterns of increased midline and attenuated fronto-parieto-cerebellar activation in psychosis (Minzenberg et al., 2009; Vercammen et al., 2012), and abnormal microstructural integrity of the corpus callosum is related to poor executive function in patients with schizophrenia (Ohoshi et al., 2019).

It is possible that executive function deficits following preterm birth are mediated by attentional difficulties, with inattention constituting the core behavioural difficulty in preterm individuals (Anderson et al., 2011; Elgen et al., 2002). This notion provides a compelling basis for a potential link between the cognitive profile of prematurely born individuals and elevated psychosis risk. Attentional impairments are not only pervasive in patients with psychotic disorder (Hoonakker et al., 2017; Luck and Gold, 2008), but may also constitute a neurodevelopmental marker of vulnerability to psychosis prior to illness onset (Seidman et al., 2016). Children with ADHD are at higher risk of developing schizophrenia in adulthood (Dalsgaard et al., 2014) and the severity of childhood ADHD symptoms retrospectively assessed in first-episode schizophrenia patients is associated with obstetric complications, delay of milestone attainment, and earlier onset of psychotic symptoms (Peralta et al., 2011). Intriguingly, much of the altered neural activation observed in preterm adults during executive task performance occurs within a fronto-parietal network thought to underpin attention allocation (Lawrence et al., 2009; Nosarti et al., 2006). Corresponding with this, patients with psychosis exhibit altered activation and connectivity of the attentional fronto-parietal network not just during executive task processing (Godwin et al., 2017; Roiser et al., 2013), but even at rest (Chang et al., 2014; Tu et al., 2013). Attentional impairment is suggested to serve as a particularly useful endophenotypic marker of familial risk for psychosis (Cornblatt and Malhotra, 2001), predicting over half of individuals at high-risk for psychosis who develop schizophrenia (Erlenmeyer-Kimling et al., 2000). However, even in the absence of genetic risk for psychosis, it is possible that neurodevelopmental disruptions to networks underpinning attentional processes could have wide-reaching cognitive consequences increasing vulnerability to psychosis. More generally, it has been suggested that early neurodevelopmental insults might deplete cognitive reserves, resulting in a cascade of cognitive impairments that manifest increasingly throughout development as environmental demands grow, and culminate in psychosis (Mollon and Reichenberg, 2018).

In summary, there is overlap both in the cognitive domains and associated neural correlates implicated in psychosis and those affected by prematurity, notably executive functioning and attention. While not all studies show differences in cognitive performance between preterm and term-born adults, there is substantial evidence that cognitive abilities are associated with neural abnormalities in those born preterm, both during development (Ball et al., 2015; Pannek et al., 2020; Peterson et al., 2000; Salvan et al., 2017; Ullman et al., 2015) and in adulthood (Allin et al., 2011; Lawrence et al., 2014; Nam et al., 2015; Nosarti et al., 2014; Olsen et al., 2018). Given these findings, which suggest that alterations in neural systems underpinning cognitive functioning persist well into adulthood of preterm individuals, it is likely that these disruptions constitute significant vulnerability factors that could further interact with genetic or environmental risk for psychotic disorder.

3.3. Motor functioning

Even in the absence of obvious disability, neurological impairments are known to be more common in preterm-born individuals than in their term-born peers (Fawke, 2007). Delays in motor development are a key characteristic of preterm infants, with evidence that motor impairments can persist into adulthood (Allin et al., 2006b; de Kievit et al., 2009).

Young adults of the UCLH study underwent comprehensive neurological assessment aged 18 (Allin et al., 2006b), with preterm-born individuals exhibiting increased motor confusion, alongside impaired sensory integration, compared to term-born controls. These integrative neurological abnormalities were furthermore associated with reduced general intelligence. In a further study, adults from the same cohort performed a movement generation task while undergoing functional imaging (Lawrence et al., 2014). Although many preterm and term-born participants performed near ceiling at this simple task and behavioural differences between groups were not detected, preterm individuals showed increased activation in a cerebellar-cortical network relative to controls. Similarly to several cognitive studies in this cohort, these findings imply recruitment of additional neural resources in order to perform the motor task at comparable levels to term-born subjects. This hyperactivation was correlated with structural grey matter deficits in right premotor cortex (Lawrence et al., 2014), lending further support to the notion of a neural compensatory strategy.

Research in other preterm cohorts also confirm that motor impairments following prematurity are not outgrown by adulthood. Extremely low birth weight survivors showed impaired motor coordination compared to controls from the age of 8 to 36, suggesting that the impairment is stable throughout development (Poole et al., 2015). Both fine and gross motor skills remained impaired from age 14 to 23 in preterm individuals born at very low birth weight (VLBW) (Husby et al., 2013), and these impairments were associated with microstructural abnormalities of inter-hemispheric (corpus callosum) and motor (corticospinal tract) pathways (Hollund et al., 2018). Motor coordination problems in adults born preterm have also been shown to be associated with reduced cortical surface area (Sripada et al., 2015). Crucially, poorer motor skills are associated with increased levels of psychiatric symptoms and lower quality of life ratings in preterm VLBW adults (Husby et al., 2016), leading to suggestions that manifestations of motor impairments may become more evident as the challenges related to the transition into adulthood increase.

Psychosis is known to be associated with an excess of neurological soft signs including impairments in motor coordination, sequencing, and sensory integration (Dazzan and Murray, 2002). Given the preponderance of motor deficits in first-degree relatives of individuals with schizophrenia, developmental motor symptoms – especially impaired coordination – are thought to represent an endophenotype of schizophrenia indicating disease risk (Burton et al., 2016). Motor deficits in schizophrenia are typically associated with negative and cognitive symptoms (Bombin et al., 2005), but in individuals at high risk for psychosis, motor dysfunction was also highly related to premorbid positive symptomatology and was furthermore indicative of transition to psychosis (Masucci et al., 2018). Indeed, gross motor skills have been shown to have unusually high sensitivity (75%) in predicting schizophrenia-related psychoses in offspring of patients with schizophrenia (Erlenmeyer-Kimling et al., 2000).

Motor neurological soft signs in psychosis are associated with structural alterations in a cerebello-thalamo-prefrontal network (Mouchet-Mages et al., 2011) which is also implicated in “cognitive dysmetria” (i.e., disruption in the fluid coordination of mental activity) in schizophrenia (Andreasen et al., 1999; Andreasen et al., 1996). Cerebellar and thalamocortical connectivity are known to be affected by prematurity (Ball et al., 2013; Herzmans et al., 2019), likely playing a role in the emergence of motor dysfunction in preterm infants (Hoon Jr et al., 2009; Messerschmidt et al., 2008). Furthermore structural alterations of the basal ganglia, which are at particular risk of neonatal brain injury

following preterm birth (Logitharajah et al., 2009) are associated with motor abnormalities in first episode psychosis patients (Cuesta et al., 2020). These findings suggest that preterm birth may cause disruption to the neural circuitry crucially involved in early neurological signs associated with psychosis. Early motor difficulties could lead to impaired self-other distinction and development of the embodied self, which are implicated in the genesis of psychotic symptoms by virtue of a failure to distinguish between internally and externally generated sensation (Poletti et al., 2019). Recent evidence of impaired body representation and deficits in sensorimotor representation of self and other generated action in preterm children (Butti et al., 2020; Montirosso et al., 2019) provides a possible mechanistic link between abnormal motor development following preterm birth and vulnerability to psychosis. This is further underlined by evidence that neuromotor abnormalities are significantly associated with obstetric complications in high risk (Marcus et al., 1993) and psychotic (Peralta and Cuesta, 2011) individuals.

3.4. Social functioning

Social difficulties and deficits in social cognition (referring to the mental operations underlying social behaviour) are a key characteristic of the preterm behavioural phenotype (Johnson and Marlow, 2011). Preterm-born children and adolescents are at increased risk of developing autism-spectrum disorders (ASD), whereby the symptomatic presentation is more strongly characterised by social communication problems than repetitive or stereotyped behaviour (Indredavik et al., 2005). Both alterations in brain development (Fischi-Gómez et al., 2015; Healy et al., 2013) and exposure to socio-environmental risk factors (Montagna and Nosarti, 2016) are implicated in adverse childhood social outcomes following preterm birth, and general neurocognitive impairments in functions such as attention and memory are likely to contribute to social cognitive deficits in these individuals (Dean et al., 2021). Socio-emotional problems following preterm birth can already be observed in early childhood, and these problems have been associated with structural and functional brain alterations. For example, disrupted orbitofrontal white matter integrity at term-equivalent age is predictive of socio-emotional difficulties at age 5 (Rogers et al., 2012), and in school-aged children born preterm poorer performance on social tasks is associated with hypoactivation of relevant frontoparietal circuits (Mossad et al., 2017; Urbain et al., 2019).

In contrast to childhood and adolescence, comparatively little research has focused on social cognition in adults born preterm, but evidence suggests that social difficulties persist into adulthood, with those born preterm reporting poorer social life and fewer social interactions (Kajantie et al., 2008; Lund et al., 2012; Saigal, 2014). Personality assessments in preterm adults also showed that they are characterised by a distinct socially withdrawn personality type (Eryigit-Madzwamuse et al., 2015), lower extraversion and higher neuroticism (Allin et al., 2006a).

Psychotic disorders, too, are characterised by profound problems with social interactions and social cognitive deficits. These difficulties are likely rooted in early development, with children who later develop schizophrenia showing greater social maladjustment than healthy controls (Done et al., 1994). In fact, the magnitude of social cognitive deficits in individuals at high clinical risk for psychosis substantially exceeds deficits in other cognitive domains (Fusar-Poli et al., 2012a). Similarly to other cognitive deficits, attention is suggested to play an important role in the development of social difficulties in psychosis (Cornblatt and Malhotra, 2001), whereby attentional problems may cause an inefficiency to process information from the (social) environment, resulting in a disruption of social competence. This is underscored by observations that attention deficits tend to be more highly correlated with social compared to psychotic symptoms (Green, 1996).

Good social functioning likely acts as a protective factor against psychopathology (McLaughlin et al., 2020; Selten and Cantor-Graae, 2005),

thus social difficulties arising as a result of preterm birth may transdiagnostically increase the risk for developing psychiatric disorder in later life. With particular relevance for psychosis, social stress, disadvantage, or isolation (encapsulated in the concept of “social defeat”) has furthermore been suggested to cause sensitisation and/or overactivity of the mesolimbic dopamine system, thus precipitating the emergence of psychotic symptoms more specifically (Gevonden et al., 2014; Selten and Cantor-Graae, 2005). Conversely, the dysfunction of striatal dopamine which we found in adults with perinatal brain injury from the UCHL cohort (Froudish-Walsh et al., 2017) may underpin vulnerability to psychosocial stress (Pyhälä et al., 2009).

In summary, psychosocial stress associated with poor interpersonal skills following preterm birth is highly likely to increase general vulnerability to mental health problems, although the specificity of this for psychosis is less clear. However, social impairments following preterm birth may also be a marker of disrupted development of neural systems not only underpinning social but also general cognitive functioning (such as attentional processes) (Montagna and Nosarti, 2016). Key regions of the social brain are also relevant for cognitive processes implicated in psychosis development, such as temporoparietal junction (Gromann et al., 2013) and medial prefrontal cortex (Ilzarbe et al., 2019). Thus, abnormalities in these regions associated with prematurity may manifest socially during earlier development, but contribute to elevated psychosis risk in the transition to adulthood.

4. Summary and outlook

We have considered the implications of the neurodevelopmental, cognitive, motor, and social sequelae of preterm birth for developing vulnerability to psychosis, with an emphasis on outcomes observed in adulthood. There is remarkably little research explicitly investigating the occurrence of psychotic symptoms following preterm birth. This may be a consequence of the difficulties caused by the long interval between preterm birth and onset of psychosis, but it is also a reflection of a lack of specificity in the link between the two. Indeed research indicates that preterm birth results in a transdiagnostically increased risk for psychiatric disorder in adulthood at the population level (Nosarti et al., 2012; Walshe et al., 2008). However, at the individual level, it is nevertheless important to consider the mechanisms by which adverse outcomes of preterm birth may increase vulnerability specifically to psychosis. Outcomes of preterm birth are highly heterogeneous, placing those exposed onto one of a wide array of possible trajectories. Similarly, psychotic disorders are highly heterogeneous both in presentation and in origin. The aim of this review was to tease out the pathways that could link prematurity to psychosis risk within this diverseness. Key potential mechanisms and markers identified here are depicted in Fig. 1.

Certain aspects of the developmental preterm behavioural phenotype are particularly relevant for potential psychosis risk. Specifically, deficits in attention, social difficulties, and motor impairments, all of which are increased following preterm birth, are known to be predictive of psychosis. Each of these factors has separately been identified as endophenotypes signalling familial risk for psychosis (Burton et al., 2016; Cornblatt and Malhotra, 2001; Tikka et al., 2020). As such, they could be considered simple epiphenomena of underlying genetic vulnerability; however, it is more likely that they lie on the causal pathway towards developing psychotic symptoms and therefore pose risk even in people with relatively low genetic vulnerability. Attentional deficits likely induce greater social and cognitive impairment engendering abnormal information processing; social difficulties increase the likelihood of experiencing psychosocial stress and isolation resulting in social defeat; and motor difficulties could lead to impaired self-other distinction and development of the embodied self; all of which represent outcomes known to be strongly associated with psychotic experiences. Each of these factors warrant more detailed investigations in adult preterm cohorts in conjunction with assessments of psychosis-proneness.

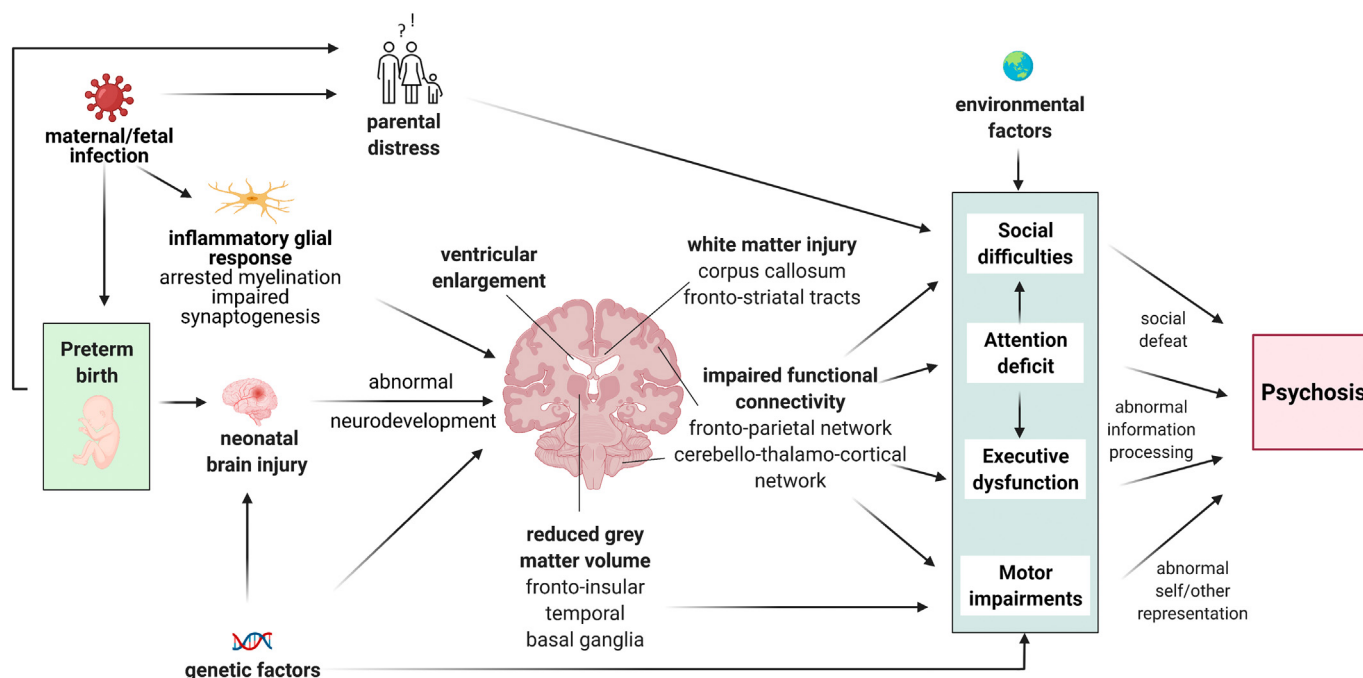


Fig. 1. Potential mechanisms underlying increased vulnerability to psychosis following preterm birth.

The behavioural vulnerability factors described here are underpinned by neural abnormalities that show overlapping structure in preterm and psychosis patient samples. Neural changes observed in psychosis have long been considered to be at least partly neurodevelopmental in nature (Murray and Lewis, 1987), and many of these alterations could be caused by insults to the brain and/or subsequent altered neurodevelopment as a result of preterm birth, including those resulting from neuroinflammatory glial response. Of course, individuals subject to preterm birth suffer very different impacts on the neonatal brain. Those candidate impacts most likely to increase risk of psychosis include white matter injury resulting in impaired microstructural integrity of fronto-striatal and interhemispheric tracts (Allin et al., 2011; Dandash et al., 2017; Karolis et al., 2016; Ohoshi et al., 2019), reduced grey matter volume in basal-ganglia, fronto-insular, and temporal regions (Cuesta et al., 2020; Fusar-Poli et al., 2012b; Logitharajah et al., 2009; Nosarti et al., 2014), and functional dysconnectivity in frontoparietal and cerebello-cortical circuits (Ball et al., 2013; Mouchet-Mages et al., 2011; Narberhaus et al., 2009; Roiser et al., 2013).

Brain alterations resulting from preterm birth may manifest in symptoms such as inattention or autism early on, but then change in the transition to adulthood as the demands of the surrounding world increase, ultimately leading to psychosis. Equally, individuals could appear behaviourally unaffected for the most part (as seen in the frequently normal cognitive task performance in preterm and term-born adults), but the neural compensatory changes necessary for this intact behaviour could signal vulnerability that renders the system less resilient to later stressors and risk factors. Importantly, substantial evidence suggests that there is at least an additive effect between genetic risk for psychosis and obstetric complications (Cannon et al., 1989; Cullen et al., 2019; Falkai et al., 2003), whereby neonatal brain injury as a result of preterm birth likely increases an already existing risk. In addition, social factors of the caregiving environment such as parenting and the wider community may play an important role. Preterm birth is known to cause significant parental stress and overprotectiveness, which can negatively impact cognitive and behavioural development (Kleine et al., 2020; Treyvaud, 2014), thus representing a further risk factor for increased psychopathology.

In addition, it is important to note that causes of preterm birth itself are heterogeneous – for example, preterm deliveries may be medically

indicated due to pre-eclampsia or fetal growth restriction, or occur spontaneously due to maternal infection, inflammation or vascular disease (Goldenberg et al., 2008) – and these different aetiologies could themselves constitute independent risk factors for subsequent development of the offspring. For example, preterm birth resulting from chronic maternal stress and mediated by fetal infectious-inflammatory processes (Wadhwa et al., 2001) likely poses a greater risk for subsequent psychosis-proneness (due to the established link between inflammation and psychosis, as discussed above) compared to indicated preterm birth due to pre-eclampsia (Davies et al., 2020). Although neonatal morbidity (Bastek et al., 2010) and mortality (Delorme et al., 2016) are known to depend on the subtype of preterm birth, the impact of different causes of preterm birth on long-term outcomes is an area which remains largely unexplored (Crump, 2020). However, the possibility of a genetic confounding of the association between prematurity and psychopathology must be considered, given that women with mental illness are at increased risk of preterm birth (Baer et al., 2016), especially spontaneous preterm birth (Sanchez et al., 2013; Venkatesh et al., 2019). That said, a recent study found little evidence for an association between maternal polygenic risk for schizophrenia and preterm delivery (Leppert et al., 2019), although psychosocial and lifestyle factors associated with psychiatric disorder could underlie the increased risk of giving birth prematurely (Behrman and Butler, 2007). Taken together, it must be acknowledged that an association between preterm birth and psychosis risk could in some cases be at least partly attributed to common underlying risk factors for both, including genetic susceptibility.

Moreover, prematurely born infants are subject to a wide range of different postnatal experiences associated with varying degrees of neonatal illness (and treatment thereof) in neonatal intensive care, such as exposure to pain, need for mechanical ventilation, surgery, or anaesthesia. While it is difficult to separate out potential effects of intensive care strategies from effects of morbidity on later outcomes (Marlow, 2014), many of the factors characterising early hospital course are important risk factors for poor neurodevelopmental outcomes (Kocok et al., 2016; Smith et al., 2011; Xiong et al., 2012). Gaining a better understanding the long-term consequences of neonatal intensive care remains challenging and will be important in order to elucidate potential links between prematurity and psychiatric outcomes, including psychosis.

It is important to remember that a range of factors can increase risk of psychosis and that the pathways between these different factors and psychotic symptoms may be quite different. For example, already it is clear that those individuals who develop psychosis following heavy cannabis use show relatively little in the way of neurodevelopmental or social difficulties in childhood. Future research can further improve our understanding of psychosis by taking into account this heterogeneity. Risk related to preterm birth should be studied firstly by more explicitly assessing the prevalence of psychotic symptoms dimensionally in large developmental and adult preterm cohorts. Here, a better understanding of the long-term outcomes following varying subtypes of preterm birth with different underlying causes will substantially improve further risk stratification. In addition, testing whether symptoms of psychosis are more strongly related to brain structure and function in preterm compared to term-born individuals will shed light on specific pathways to psychosis related to neurodevelopmental disruption. Finally, it will be crucial to investigate the predictive validity of developmental symptoms in conjunction with neural abnormalities for transition to psychosis specifically in preterm cohorts. Overall, this will improve clinicians' ability to anticipate the type of psychopathology preterm-born individuals are most likely to suffer from long-term, and thereby provide more tailored care on an individual level.

Role of the funding source

LDV is funded by the Medical Research Council (Grant Ref: MR/S026460/1).

CRediT authorship contribution statement

Lucy D. Vanes: Conceptualization, Writing – original draft. **Robin M. Murray:** Conceptualization, Writing – review & editing. **Chiara Nosarti:** Conceptualization, Writing – review & editing.

Declaration of competing interest

The authors have no financial relationships or conflicts of interest relevant to this article to disclose.

Acknowledgments

We thank the study participants of the UCLH study for their continuing help. We also thank the National Institute for Health Research (NIHR) Biomedical Research Centre at South London and Maudsley NHS Foundation Trust. Fig. 1 was created with BioRender.com.

References

- Aanes, S., Bjulund, K.J., Skranes, J., Løhaugen, G.C., 2015. Memory function and hippocampal volumes in preterm born very-low-birth-weight (VLBW) young adults. *Neuroimage* 105, 76–83.
- Ahn, S.J., Cornea, E., Murphy, V., Styner, M., Jarskog, L.F., Gilmore, J.H., 2019. White matter development in infants at risk for schizophrenia. *Schizophr. Res.* 210, 107–114.
- Allin, M., Rooney, M., Cuddy, M., Wyatt, J., Walshe, M., Rifkin, L., Murray, R., 2006a. Personality in young adults who are born preterm. *Pediatrics* 117 (2), 309–316.
- Allin, M., Rooney, M., Griffiths, T., Cuddy, M., Wyatt, J., Rifkin, L., Murray, R., 2006b. Neurological abnormalities in young adults born preterm. *J. Neurol. Neurosurg. Psychiatr.* 77 (4), 495–499.
- Allin, M.P., Kontis, D., Walshe, M., Wyatt, J., Barker, G.J., Kanaan, R.A., McGuire, P., Rifkin, L., Murray, R.M., Nosarti, C., 2011. White matter and cognition in adults who were born preterm. *PLoS one* 6 (10), e24525.
- Anderson, P.J., De Luca, C.R., Hutchinson, E., Spencer-Smith, M.M., Roberts, G., Doyle, L.W., V.I.C.S. Group, 2011. Attention problems in a representative sample of extremely preterm/extremely low birth weight children. *Dev. Neuropsychol.* 36 (1), 57–73.
- Andreasen, N.C., O'Leary, D.S., Cizadlo, T., Arndt, S., Reza, K., Ponto, L., Watkins, G.L., Hichwa, R.D., 1996. Schizophrenia and cognitive dysmetria: a positron-emission tomography study of dysfunctional prefrontal-thalamic-cerebellar circuitry. *Proc. Natl. Acad. Sci.* 93 (18), 9985–9990.
- Andreasen, N.C., Nopoulos, P., O'Leary, D.S., Miller, D.D., Wassink, T., Flaum, M., 1999. Defining the phenotype of schizophrenia: cognitive dysmetria and its neural mechanisms. *Biol. Psychiatr.* 46 (7), 908–920.
- Anjari, M., Srinivasan, L., Allsop, J.M., Hajnal, J.V., Rutherford, M.A., Edwards, A.D., Counsell, S.J., 2007. Diffusion tensor imaging with tract-based spatial statistics reveals local white matter abnormalities in preterm infants. *Neuroimage* 35 (3), 1021–1027.
- Arichi, T., Whitehead, K., Barone, G., Pressler, R., Padormo, F., Edwards, A.D., Fabrizi, L., 2017. Localization of spontaneous bursting neuronal activity in the preterm human brain with simultaneous EEG-fMRI. *Elife* 6, e27814.
- Back, S.A., 2015. Brain injury in the preterm infant: new horizons for pathogenesis and prevention. *Pediatr. Neurol.* 53 (3), 185–192.
- Baer, R.J., Chambers, C.D., Bandoli, G., Jelliffe-Pawlowski, L.L., 2016. Risk of preterm birth by subtype among Medi-Cal participants with mental illness. *Am. J. Obstet. Gynecol.* 215 (4), 519.e511–519.e519.
- Ball, G., Boardman, J.P., Aljabar, P., Pandit, A., Arichi, T., Merchant, N., Rueckert, D., Edwards, A.D., Counsell, S.J., 2013. The influence of preterm birth on the developing thalamocortical connectome. *Cortex* 49 (6), 1711–1721.
- Ball, G., Pazderova, L., Chew, A., Tumor, N., Merchant, N., Arichi, T., Allsop, J.M., Cowan, F.M., Edwards, A.D., Counsell, S.J., 2015. Thalamocortical connectivity predicts cognition in children born preterm. *Cereb. Cort.* 25 (11), 4310–4318.
- Ball, G., Aljabar, P., Arichi, T., Tumor, N., Cox, D., Merchant, N., Nongena, P., Hajnal, J.V., Edwards, A.D., Counsell, S.J., 2016. Machine-learning to characterise neonatal functional connectivity in the preterm brain. *Neuroimage* 124, 267–275.
- Ball, G., Seidlitz, J., O'Muircheartaigh, J., Dimitrova, R., Fenchel, D., Makropoulos, A., Christiaens, D., Schuh, A., Passerat-Palmbach, J., Hutter, J., 2020. Cortical morphology at birth reflects spatiotemporal patterns of gene expression in the fetal human brain. *PLoS Biol.* 18 (11), e3000976.
- Barde, L.H., Yeatman, J.D., Lee, E.S., Glover, G., Feldman, H.M., 2012. Differences in neural activation between preterm and full term born adolescents on a sentence comprehension task: implications for educational accommodations. *Dev. Cogn. Neurosci.* 2, S114–S128.
- Barnes-Davis, M.E., Merhar, S.L., Holland, S.K., Kadis, D.S., 2018. Extremely preterm children exhibit increased interhemispheric connectivity for language: findings from fMRI-constrained MEG analysis. *Dev. Sci.* 21 (6), e12669.
- Bastek, J.A., Srinivas, S.K., Sammel, M.D., Elovitz, M.A., 2010. Do neonatal outcomes differ depending on the cause of preterm birth? A comparison between spontaneous birth and iatrogenic delivery for preeclampsia. *Am. J. Perinatol.* 27 (02), 163–169.
- Batalle, D., Hughes, E.J., Zhang, H., Tournier, J.-D., Tumor, N., Aljabar, P., Wali, L., Alexander, D.C., Hajnal, J.V., Nosarti, C., 2017. Early development of structural networks and the impact of prematurity on brain connectivity. *Neuroimage* 149, 379–392.
- Batalle, D., Edwards, A.D., O'Muircheartaigh, J., 2018. Not just a small adult brain: understanding later neurodevelopment through imaging the neonatal brain. *J. Child Psychol. Psychiatr.* 59 (4), 350–371.
- Bäumli, J.G., Daamen, M., Meng, C., Neitzel, J., Scheef, L., Jaekel, J., Busch, B., Baumann, N., Bartmann, P., Wolke, D., 2015. Correspondence between aberrant intrinsic network connectivity and gray-matter volume in the ventral brain of preterm born adults. *Cereb. Cort.* 25 (11), 4135–4145.
- Behrman, R.E., Butler, A.S., 2007. *Preterm Birth: Causes, Consequences, and Prevention*. Bloomfield, M.A., Morgan, C.J., Egerton, A., Kapur, S., Curran, H.V., Howes, O.D., 2014. Dopaminergic function in cannabis users and its relationship to cannabis-induced psychotic symptoms. *Biol. Psychiatr.* 75 (6), 470–478.
- Bokobza, C., Van Steenwinckel, J., Mani, S., Mezger, V., Fleiss, B., Gressens, P., 2019. Neuroinflammation in preterm babies and autism spectrum disorders. *Pediatr. Res.* 85 (2), 155–165.
- Bombin, I., Arango, C., Buchanan, R.W., 2005. Significance and meaning of neurological signs in schizophrenia: two decades later. *Schizophr. Bull.* 31 (4), 962–977.
- Boos, H.B., Aleman, A., Cahn, W., Pol, H.H., Kahn, R.S., 2007. Brain volumes in relatives of patients with schizophrenia: a meta-analysis. *Arch. Gen. Psychiatr.* 64 (3), 297–304.
- Breeman, L.D., Jaekel, J., Baumann, N., Bartmann, P., Wolke, D., 2015. Preterm cognitive function into adulthood. *Pediatrics* 136 (3), 415–423.
- Brouwer, M.J., De Vries, L.S., Kersbergen, K.J., van der Aa, N.E., Brouwer, A.J., Viergever, M.A., Išgum, I., Han, K.S., Groenendaal, F., Benders, M.J., 2016. Effects of posthemorrhagic ventricular dilatation in the preterm infant on brain volumes and white matter diffusion variables at term-equivalent age. *J. Pediatr.* 168, 41–49.e41.
- Brown, A.S., Hooton, J., Schaefer, C.A., Zhang, H., Petkova, E., Babulas, V., Perrin, M., Gorman, J.M., Susser, E.S., 2004. Elevated maternal interleukin-8 levels and risk of schizophrenia in adult offspring. *Am. J. Psychiatr.* 161 (5), 889–895.
- Brydges, C.R., Landes, J.K., Reid, C.L., Campbell, C., French, N., Anderson, M., 2018. Cognitive outcomes in children and adolescents born very preterm: a meta-analysis. *Dev. Med. Child Neurol.* 60 (5), 452–468.
- Buehlmann, E., Berger, G.E., Aston, J., Gschwandtner, U., Pflueger, M.O., Borgwardt, S.J., Radue, E.-W., Riecher-Rössler, A., 2010. Hippocampus abnormalities in at risk mental states for psychosis? A cross-sectional high resolution region of interest magnetic resonance imaging study. *J. Psychiatr. Res.* 44 (7), 447–453.
- Bullmore, E., Frangou, S., Murray, R., 1997. The dysplastic net hypothesis: an integration of developmental and dysconnectivity theories of schizophrenia. *Schizophr. Res.* 28 (2–3), 143–156.
- Burnett, A., Anderson, P., Cheong, J., Doyle, L., Davey, C., Wood, S., 2011. Prevalence of psychiatric diagnoses in preterm and full-term children, adolescents and young adults: a meta-analysis. *Psychol. Med.* 41 (12), 2463.
- Burton, B.K., Hjorthøj, C., Jepsen, J.R., Thorup, A., Nordentoft, M., Plessen, K.J., 2016. Do motor deficits during development represent an endophenotype for schizophrenia? A meta-analysis. *J. Child Psychol. Psychiatr.* 57 (4), 446–456.
- Butti, N., Montiroso, R., Giusti, L., Borgatti, R., Urgesi, C., 2020. Premature birth affects visual body representation and body schema in preterm children. *Brain Cogn.* 145, 105612.
- Caldinelli, C., Froudish-Walsh, S., Karolis, V., Tseng, C.-E., Allin, M.P., Walshe, M., Cuddy, M., Murray, R.M., Nosarti, C., 2017. White matter alterations to cingulum and fornix following very preterm birth and their relationship with cognitive functions. *Neuroimage* 150, 373–382.
- Cannon, T.D., Mednick, S.A., Parnas, J., 1989. Genetic and perinatal determinants of structural brain deficits in schizophrenia. *Arch. Gen. Psychiatr.* 46 (10), 883–889.
- Chang, X., Shen, H., Wang, L., Liu, Z., Xin, W., Hu, D., Miao, D., 2014. Altered default mode and fronto-parietal network subsystems in patients with schizophrenia and their unaffected siblings. *Brain Res.* 1562, 87–99.

- Chew, L.-J., Fusar-Poli, P., Schmitz, T., 2013. Oligodendroglial alterations and the role of microglia in white matter injury: relevance to schizophrenia. *Dev. Neurosci.* 35 (2–3), 102–129.
- Chung, Y., Haut, K.M., He, G., van Erp, T.G., McEwen, S., Addington, J., Bearden, C.E., Cadenhead, K., Cornblatt, B., Mathalon, D.H., 2017. Ventricular enlargement and progressive reduction of cortical gray matter are linked in prodromal youth who develop psychosis. *Schizophr. Res.* 189, 169–174.
- Cole, J.H., Filippetti, M.L., Allin, M.P., Walshe, M., Nam, K.W., Gutman, B.A., Murray, R.M., Rifkin, L., Thompson, P.M., Nosarti, C., 2015. Subregional hippocampal morphology and psychiatric outcome in adolescents who were born very preterm and at term. *PLoS One* 10 (6), e0130094.
- Condray, R., 2005. Language disorder in schizophrenia as a developmental learning disorder. *Schizophr. Res.* 73 (1), 5–20.
- Cooke, R., Abernethy, L., 1999. Cranial magnetic resonance imaging and school performance in very low birth weight infants in adolescence. *Arch. Dis. Child.-Fetal Neonat.* Ed. 81 (2), F116–F121.
- Cooper, D., Barker, V., Radua, J., Fusar-Poli, P., Lawrie, S.M., 2014. Multimodal voxel-based meta-analysis of structural and functional magnetic resonance imaging studies in those at elevated genetic risk of developing schizophrenia. *Psychiat. Res. Neuroimaging* 221 (1), 69–77.
- Cornblatt, B.A., Malhotra, A.K., 2001. Impaired attention as an endophenotype for molecular genetic studies of schizophrenia. *Am. J. Med. Genet.* 105 (1), 11–15.
- Costas-Carrera, A., Garcia-Rizo, C., Bitanirhw, B., Penadés, R., 2020. Obstetric complications and brain imaging in schizophrenia: a systematic review. *Biological Psychiatry: Cognitive Neuroscience and Neuroimaging*.
- Crump, C., 2020. An overview of adult health outcomes after preterm birth. *Early Human Dev.* 150, 105187.
- Cuesta, M.J., Lecumberri, P., Moreno-Izco, L., López-Ilundain, J.M., Ribeiro, M., Cabada, T., Lorente-Omeñaca, R., De Erausquin, G., García-Martí, G., Sanjuan, J., 2020. Motor abnormalities and basal ganglia in first-episode psychosis (FEP). *Psychol. Med.* 1–12.
- Cullen, H., Krishnan, M.L., Selzam, S., Ball, G., Visconti, A., Saxena, A., Counsell, S.J., Hajnal, J., Breen, G., Plomin, R., 2019. Polygenic risk for neuropsychiatric disease and vulnerability to abnormal deep grey matter development. *Sci. Rep.* 9 (1), 1–8.
- Dalsgaard, S., Mortensen, P., Frydenberg, M., Maibing, C., Nordentoft, M., Thomsen, P., 2014. Association between Attention-Deficit Hyperactivity Disorder in childhood and schizophrenia later in adulthood. *Eur. Psychiat.* 29 (4), 259–263.
- Dandash, O., Pantelis, C., Fornito, A., 2017. Dopamine, fronto-striato-thalamic circuits and risk for psychosis. *Schizophr. Res.* 180, 48–57.
- Davies, C., Segre, G., Estradé, A., Radua, J., De Micheli, A., Provenzano, U., Oliver, D., de Pablo, G.S., Ramella-Cravaro, V., Boszoi, M., 2020. Prenatal and perinatal risk and protective factors for psychosis: a systematic review and meta-analysis. *Lancet Psychiat.* 7 (5), 399–410.
- Dazzan, P., Murray, R.M., 2002. Neurological soft signs in first-episode psychosis: a systematic review. *Br. J. Psychiat.* 181 (543), s50–s57.
- De Jong, M., Verhoeven, M., van Baar, A.L., 2012. School outcome, cognitive functioning, and behaviour problems in moderate and late preterm children and adults: a review. *Seminars in Fetal and Neonatal Medicine*. Elsevier, pp. 163–169.
- Dean, B., Ginnell, L., Boardman, J.P., Fletcher-Watson, S., 2021. Social cognition following preterm birth: a systematic review. *Neurosci. Biobehav. Rev.* 124, 151–167.
- Delorme, P., Goffinet, F., Ancel, P.-Y., Foix-L'Hélias, L., Langer, B., Lebeaux, C., Marchand, L.M., Zeitlin, J., Ego, A., Arnaud, C., 2016. Cause of preterm birth as a prognostic factor for mortality. *Obstet. Gynecol.* 127 (1), 40–48.
- Dietz, A.G., Goldman, S.A., Nedergaard, M., 2020. Glial cells in schizophrenia: a unified hypothesis. *Lancet Psychiat.* 7 (3), 272–281.
- Done, D.J., Crow, T.J., Johnstone, E.C., Sacker, A., 1994. Childhood antecedents of schizophrenia and affective illness: social adjustment at ages 7 and 11. *BMJ* 309 (6956), 699–703.
- Dubois, J., Lefèvre, J., Angley, H., Leroy, F., Fischer, C., Lebenberg, J., Dehaene-Lambertz, G., Borradori-Tolsa, C., Lazeyras, F., Hertz-Pannier, L., 2019. The dynamics of cortical folding waves and prematurity-related deviations revealed by spatial and spectral analysis of gyrification. *Neuroimage* 185, 934–946.
- Eikenes, L., Løhaugen, G.C., Brubakk, A.-M., Skranes, J., Håberg, A.K., 2011. Young adults born preterm with very low birth weight demonstrate widespread white matter alterations on brain DTI. *Neuroimage* 54 (3), 1774–1785.
- Elgen, I., Sommerfelt, K., Markestad, T., 2002. Population based, controlled study of behavioural problems and psychiatric disorders in low birthweight children at 11 years of age. *Arch. Dis. Child.-Fetal Neonat.* Ed. 87 (2), F128–F132.
- Engelhardt, E., Inder, T.E., Alexopoulos, D., Dierker, D.L., Hill, J., Van Essen, D., Neil, J.J., 2015. Regional impairments of cortical folding in premature infants. *Ann. Neurol.* 77 (1), 154–162.
- Erlenmeyer-Kimling, L., Rock, D., Roberts, S.A., Janal, M., Kestenbaum, C., Cornblatt, B., Adamo, U.H., Gottesman, I.I., 2000. Attention, memory, and motor skills as childhood predictors of schizophrenia-related psychoses: the New York High-Risk Project. *Am. J. Psychiat.* 157 (9), 1416–1422.
- van Erp, T.G., Hibar, D.P., Rasmussen, J.M., Glahn, D.C., Pearlson, G.D., Andreassen, O.A., Agartz, I., Westlye, L.T., Haukvik, U.K., Dale, A.M., 2016. Subcortical brain volume abnormalities in 2028 individuals with schizophrenia and 2540 healthy controls via the ENIGMA consortium. *Mol. Psychiat.* 21 (4), 547–553.
- Eryigit Madzwamuse, S., Baumann, N., Jaekel, J., Bartmann, P., Wolke, D., 2015. Neurocognitive performance of very preterm or very low birth weight adults at 26 years. *J. Child Psychol. Psychiat.* 56 (8), 857–864.
- Eryigit Madzwamuse, S., Strauss, V., Baumann, N., Bartmann, P., Wolke, D., 2015. Personality of adults who were born very preterm. *Arch. Dis. Child.-Fetal Neonat.* Ed. 100 (6), F524–F529.
- Falkai, P., Schneider-Axmann, T., Honer, W.G., Vogele, K., Schönell, H., Pfeiffer, U., Scherk, H., Block, W., Träber, F., Schild, H.H., 2003. Influence of genetic loading, obstetric complications and premorbid adjustment on brain morphology in schizophrenia. *Eur. Arch. Psychiat. Clin. Neurosci.* 253 (2), 92–99.
- Fawke, J., 2007. Neurological outcomes following preterm birth. *Seminars in Fetal and Neonatal Medicine*. Elsevier, pp. 374–382.
- Fischi-Gómez, E., Vasung, L., Meskaldji, D.-E., Lazeyras, F., Borradori-Tolsa, C., Hagmann, P., Barisnikov, K., Thiran, J.-P., Hüppi, P.S., 2015. Structural brain connectivity in school-age preterm infants provides evidence for impaired networks relevant for higher order cognitive skills and social cognition. *Cerebr. Cort.* 25 (9), 2793–2805.
- Fleiss, B., Gressens, P., Stolp, H.B., 2020. Cortical gray matter injury in encephalopathy of prematurity: link to neurodevelopmental disorders. *Front. Neurol.* 11, 575.
- Fraello, D., Maller-Kesselman, J., Vohr, B., Katz, K.H., Kesler, S., Schneider, K., Reiss, A., Ment, L., Spann, M.N., 2011. Consequence of preterm birth in early adolescence: the role of language on auditory short-term memory. *J. Child Neurol.* 26 (6), 738–742.
- Friston, K.J., Frith, C.D., 1995. Schizophrenia: a disconnection syndrome. *Clin. Neurosci.* 3 (2), 89–97.
- Froudust-Walsh, S., Karolis, V., Caldinelli, C., Brittain, P.J., Kroll, J., Rodríguez-Toscano, E., Tesse, M., Colquhoun, M., Howes, O., Dell'Acqua, F., 2015. Very early brain damage leads to remodeling of the working memory system in adulthood: a combined fMRI/tractography study. *J. Neurosci.* 35 (48), 15787–15799.
- Froudust-Walsh, S., Bloomfield, M.A., Veronesi, M., Kroll, J., Karolis, V.R., Jauhar, S., Bonoldi, I., McGuire, P.K., Kapur, S., Murray, R.M., 2017. The effect of perinatal brain injury on dopaminergic function and hippocampal volume in adult life. *Elife* 6, e29088.
- Fusar-Poli, P., Deste, G., Smieskova, R., Barlati, S., Yung, A.R., Howes, O., Stieglitz, R.-D., Vita, A., McGuire, P., Borgwardt, S., 2012a. Cognitive functioning in prodromal psychosis: a meta-analysis. *Arch. Gen. Psychiat.* 69 (6), 562–571.
- Fusar-Poli, P., Radua, J., McGuire, P., Borgwardt, S., 2012b. Neuroanatomical maps of psychosis onset: voxel-wise meta-analysis of antipsychotic-naïve VBM studies. *Schizophr. Bull.* 38 (6), 1297–1307.
- Fusar-Poli, P., Smieskova, R., Serafini, G., Politi, P., Borgwardt, S., 2014. Neuroanatomical markers of genetic liability to psychosis and first episode psychosis: a voxelwise meta-analytical comparison. *World J. Biol. Psychiat.* 15 (3), 219–228.
- Gevonden, M., Booij, J., van den Brink, W., Heijtel, D., van Os, J., Seltén, J.-P., 2014. Increased release of dopamine in the striata of young adults with hearing impairment and its relevance for the social defeat hypothesis of schizophrenia. *JAMA Psychiat.* 71 (12), 1364–1372.
- Gilmore, J.H., Kang, C., Evans, D.D., Wolfe, H.M., Smith, J.K., Lieberman, J.A., Lin, W., Hamer, R.M., Styner, M., Gerig, G., 2010. Prenatal and neonatal brain structure and white matter maturation in children at high risk for schizophrenia. *Am. J. Psychiat.* 167 (9), 1083–1091.
- Godwin, D., Ji, A., Kandala, S., Mamah, D., 2017. Functional connectivity of cognitive brain networks in schizophrenia during a working memory task. *Front. Psychiatry* 8, 294.
- Gogtay, N., Nugent III, T.F., Herman, D.H., Odonez, A., Greenstein, D., Hayashi, K.M., Clasen, L., Toga, A.W., Giedd, J.N., Rapoport, J.L., 2006. Dynamic mapping of normal human hippocampal development. *Hippocampus* 16 (8), 664–672.
- Goldenberg, R.L., Culhane, J.F., Iams, J.D., Romero, R., 2008. Epidemiology and causes of preterm birth. *Lancet* 371 (9606), 75–84.
- Goodkind, M., Eickhoff, S.B., Oathes, D.J., Jiang, Y., Chang, A., Jones-Hagata, L.B., Ortega, B.N., Zaiko, Y.V., Roach, E.L., Korgaonkar, M.S., 2015. Identification of a common neurobiological substrate for mental illness. *JAMA Psychiat.* 72 (4), 305–315.
- Green, M.F., 1996. What are the functional consequences of neurocognitive deficits in schizophrenia? *Am. J. Psychiat.* 153 (3), 321–330.
- Gromann, P.M., Heslenfeld, D.J., Fett, A.-K., Joyce, D.W., Shergill, S.S., Krabbendam, L., 2013. Trust versus paranoia: abnormal response to social reward in psychotic illness. *Brain* 136 (6), 1968–1975.
- Hadaya, L., Nosarti, C., 2020. The neurobiological correlates of cognitive outcomes in adolescence and adulthood following very preterm birth. *Seminars in Fetal and Neonatal Medicine*. Elsevier, p. 101117.
- Hart, A.R., Whitby, E.W., Griffiths, P.D., Smith, M.F., 2008. Magnetic resonance imaging and developmental outcome following preterm birth: review of current evidence. *Dev. Med. Child Neurol.* 50 (9), 655–663.
- Healy, E., Reichenberg, A., Nam, K.W., Allin, M.P., Walshe, M., Rifkin, L., Murray, R.M., Nosarti, C., 2013. Preterm birth and adolescent social functioning—alterations in emotion-processing brain areas. *J. Pediatr.* 163 (6), 1596–1604.
- Hedderich, D.M., Bäuml, J.G., Berndt, M.T., Menegaux, A., Scheef, L., Daamen, M., Zimmer, C., Bartmann, P., Boecker, H., Wolke, D., 2019. Aberrant gyrification contributes to the link between gestational age and adult IQ after premature birth. *Brain* 142 (5), 1255–1269.
- Hedderich, D.M., Boeckh-Behrens, T., Bäuml, J.G., Menegaux, A., Daamen, M., Zimmer, C., Bartmann, P., Scheef, L., Boecker, H., Wolke, D., Sorg, C., Spiro, J.E., 2020. Sequelae of premature birth in young adults. *Clin. Neuroradiol.* 1–9.
- Herzmann, C.S., Snyder, A.Z., Kenley, J.K., Rogers, C.E., Shimony, J.S., Smyser, C.D., 2019. Cerebellar functional connectivity in term- and very preterm-born infants. *Cerebr. Cort.* 29 (3), 1174–1184.
- Holland, I.M.H., Olsen, A., Skranes, J., Brubakk, A.-M., Håberg, A.K., Eikenes, L., Evensen, K.A.I., 2018. White matter alterations and their associations with motor function in young adults born preterm with very low birth weight. *NeuroImage Clin.* 17, 241–250.
- Hoon Jr., A.H., Stashinko, E.E., Nagae, L.M., Lin, D.D., Keller, J., Bastian, A., Campbell, M.L., Levey, E., Mori, S., Johnston, M.V., 2009. Sensory and motor deficits in children with cerebral palsy born preterm correlate with diffusion tensor imaging abnormalities in thalamocortical pathways. *Dev. Med. Child Neurol.* 51 (9), 697–704.
- Hoonakker, M., Doignon-Camus, N., Bonnefond, A., 2017. Sustaining attention to simple visual tasks: a central deficit in schizophrenia? A systematic review. *Ann. New York Acad. Sci.* 1408 (1), 32–45.
- Howes, O.D., Kapur, S., 2009. The dopamine hypothesis of schizophrenia: version III—the final common pathway. *Schizophr. Bull.* 35 (3), 549–562.

- Howes, O.D., Murray, R.M., 2014. Schizophrenia: an integrated sociodevelopmental-cognitive model. *Lancet* 383 (9929), 1677–1687.
- Husby, I.M., Skranes, J., Olsen, A., Brubakk, A.-M., Evensen, K.A.I., 2013. Motor skills at 23 years of age in young adults born preterm with very low birth weight. *Early Human Dev.* 89 (9), 747–754.
- Husby, I.M., Stray, K.M.-T., Olsen, A., Lydersen, S., Indredavik, M.S., Brubakk, A.-M., Skranes, J., Evensen, K.A.I., 2016. Long-term follow-up of mental health, health-related quality of life and associations with motor skills in young adults born preterm with very low birth weight. *Health Qual. Life Outcomes* 14 (1), 1–14.
- Iida, K., Takashima, S., Ueda, K., 1995. Immunohistochemical study of myelination and oligodendrocyte in infants with periventricular leukomalacia. *Pediatr. Neurol.* 13 (4), 296–304.
- Ilzarbe, D., de la Serna, E., Baeza, I., Rosa, M., Puig, O., Calvo, A., Masias, M., Borrás, R., Pariente, J.C., Castro-Fornieles, J., 2019. The relationship between performance in a theory of mind task and intrinsic functional connectivity in youth with early onset psychosis. *Dev. Cogn. Neurosci.* 40, 100726.
- Indredavik, M.S., Vik, T., Heyerdahl, S., Kulseng, S., Brubakk, A.-M., 2005. Psychiatric symptoms in low birth weight adolescents, assessed by screening questionnaires. *Eur. Child Adolesc. Psychiatr.* 14 (4), 226–236.
- Johnson, S., 2007. Cognitive and behavioural outcomes following very preterm birth. *Seminars in Fetal and Neonatal Medicine*. Elsevier, pp. 363–373.
- Johnson, S., Marlow, N., 2011. Preterm birth and childhood psychiatric disorders. *Pediatr. Res.* 69 (8), 11–18.
- Johnson, S., Wolke, D., 2013. Behavioural outcomes and psychopathology during adolescence. *Early Human Dev.* 89 (4), 199–207.
- Jones, P., Murray, R., Rodgers, B., Marmot, M., 1994. Child developmental risk factors for adult schizophrenia in the British 1946 birth cohort. *Lancet* 344 (8934), 1398–1402.
- Kajantie, E., Hovi, P., Räikkönen, K., Pesonen, A.-K., Heinonen, K., Järvenpää, A.-L., Eriksson, J.G., Strang-Karlsson, S., Andersson, S., 2008. Young adults with very low birth weight: leaving the parental home and sexual relationships—Helsinki Study of Very Low Birth Weight Adults. *Pediatrics* 122 (1), e62–e72.
- Kalpakidou, A.K., Allin, M.P., Walshe, M., Giampietro, V., McGuire, P.K., Rifkin, L., Murray, R.M., Nosarti, C., 2014. Functional neuroanatomy of executive function after neonatal brain injury in adults who were born very preterm. *PLoS One* 9 (12), e113975.
- Kanel, D., Counsell, S.J., Nosarti, C., 2020. Advances in functional and diffusion neuroimaging research into the long-term consequences of very preterm birth. *Work* 33, 34.
- Karolis, V.R., Froudish-Walsh, S., Brittain, P.J., Kroll, J., Ball, G., Edwards, A.D., Dell'Acqua, F., Williams, S.C., Murray, R.M., Nosarti, C., 2016. Reinforcement of the brain's rich-club architecture following early neurodevelopmental disruption caused by very preterm birth. *Cerebr. Cort.* 26 (3), 1322–1335.
- Kelly, C.E., Cheong, J.L., Fam, L.G., Leemans, A., Seal, M.L., Doyle, L.W., Anderson, P.J., Spittle, A.J., Thompson, D.K., 2016. Moderate and late preterm infants exhibit widespread brain white matter microstructure alterations at term-equivalent age relative to term-born controls. *Brain Imaging Behav.* 10 (1), 41–49.
- Kelly, S., Guimond, S., Lyall, A., Stone, W.S., Shenton, M.E., Keshavan, M., Seidman, L.J., 2019. Neuro correlates of cognitive deficits across developmental phases of schizophrenia. *Neurobiol. Dis.* 131, 104353.
- Kempton, M.J., Stahl, D., Williams, S.C., Delisi, L.E., 2010. Progressive lateral ventricular enlargement in schizophrenia: a meta-analysis of longitudinal MRI studies. *Schizophr. Res.* 120 (1–3), 54–62.
- Kerns, D., Vong, G.S., Barley, K., Dracheva, S., Katsel, P., Casaccia, P., Haroutunian, V., Byne, W., 2010. Gene expression abnormalities and oligodendrocyte deficits in the internal capsule in schizophrenia. *Schizophr. Res.* 120 (1–3), 150–158.
- de Kieviet, J.F., Piek, J.P., Aarnoudse-Moens, C.S., Oosterlaan, J., 2009. Motor development in very preterm and very low-birth-weight children from birth to adolescence: a meta-analysis. *JAMA* 302 (20), 2235–2242.
- de Kieviet, J.F., Zoetebier, L., Van Elburg, R.M., Vermeulen, R.J., Oosterlaan, J., 2012. Brain development of very preterm and very low-birthweight children in childhood and adolescence: a meta-analysis. *Dev. Med. Child Neurol.* 54 (4), 313–323.
- Kleine, I., Falconer, S., Roth, S., Counsell, S., Redshaw, M., Kennea, N., Edwards, A., Nosarti, C., 2020. Early postnatal maternal trait anxiety is associated with the behavioural outcomes of children born preterm < 33 weeks. *J. Psychiatr. Res.* 131, 160–168.
- Kocok, M., Wilcox, R., Crank, C., Patra, K., 2016. Evaluation of the relationship between opioid exposure in extremely low birth weight infants in the neonatal intensive care unit and neurodevelopmental outcome at 2 years. *Early Human Dev.* 92, 29–32.
- Kochunov, P., Hong, L.E., 2014. Neurodevelopmental and neurodegenerative models of schizophrenia: white matter at the center stage. *Schizophr. Bull.* 40 (4), 721–728.
- Kontis, D., Catani, M., Cuddy, M., Walshe, M., Nosarti, C., Jones, D., Wyatt, J., Rifkin, L., Murray, R., Allin, M., 2009. Diffusion tensor MRI of the corpus callosum and cognitive function in adults born preterm. *Neuroreport* 20 (4), 424–428.
- Kostović, I., Jovanov-Milošević, N., 2006. The development of cerebral connections during the first 20–45 weeks' gestation. *Seminars in Fetal and Neonatal Medicine*. Elsevier, pp. 415–422.
- Kostović, I., Judoš, M., 2010. The development of the subplate and thalamocortical connections in the human foetal brain. *Acta Paediatr.* 99 (8), 1119–1127.
- Krishnan, M.L., Van Steenwinckel, J., Schang, A.-L., Yan, J., Arnadottir, J., Le Charpentier, T., Csaba, Z., Dournaud, P., Cipriani, S., Auvynet, C., 2017a. Integrative genomics of microglia implicates *DLG4* (*PSD95*) in the white matter development of preterm infants. *Nat. Commun.* 8 (1), 1–11.
- Krishnan, M.L., Wang, Z., Aljabar, P., Ball, G., Mirza, G., Saxena, A., Counsell, S.J., Hajnal, J.V., Montana, G., Edwards, A.D., 2017b. Machine learning shows association between genetic variability in *PPARG* and cerebral connectivity in preterm infants. *Proc. Natl. Acad. Sci.* 114 (52), 13744–13749.
- Kroll, J., Karolis, V., Brittain, P.J., Tseng, C.-E.J., Froudish-Walsh, S., Murray, R.M., Nosarti, C., 2017. Real-life impact of executive function impairments in adults who were born very preterm. *J. Intl. Neuropsychol. Soc.* 23 (5), 381.
- Kroll, J., Froudish-Walsh, S., Brittain, P.J., Tseng, C.-E., Karolis, V., Murray, R., Nosarti, C., 2018. A dimensional approach to assessing psychiatric risk in adults born very preterm. *Psychol. Med.* 48 (10), 1738–1744.
- Kroll, J., Karolis, V., Brittain, P.J., Tseng, C.-E.J., Froudish-Walsh, S., Murray, R.M., Nosarti, C., 2019. Systematic assessment of perinatal and socio-demographic factors associated with IQ from childhood to adult life following very preterm birth. *Intelligence* 77, 101401.
- Larroque, B., Marret, S., Ancel, P.-Y., Arnaud, C., Marpeau, L., Supernant, K., Pierrat, V., Rozé, J.-C., Matis, J., Cambon, G., 2003. White matter damage and intraventricular hemorrhage in very preterm infants: the EPIPAGE study. *J. Pediatr.* 143 (4), 477–483.
- Lawrence, E., Froudish-Walsh, S., Neilan, R., Nam, K., Giampietro, V., McGuire, P., Murray, R., Nosarti, C., 2014. Motor fMRI and cortical grey matter volume in adults born very preterm. *Dev. Cogn. Neurosci.* 10, 1–9.
- Lawrence, E.J., Rubia, K., Murray, R.M., McGuire, P.K., Walshe, M., Allin, M., Giampietro, V., Rifkin, L., Williams, S.C., Nosarti, C., 2009. The neural basis of response inhibition and attention allocation as mediated by gestational age. *Human Brain Map.* 30 (3), 1038–1050.
- Lawrence, E.J., McGuire, P.K., Allin, M., Walshe, M., Giampietro, V., Murray, R.M., Rifkin, L., Nosarti, C., 2010. The very preterm brain in young adulthood: the neural correlates of verbal paired associate learning. *J. Pediatr.* 156 (6), 889–895.
- Leppert, B., Havdahl, A., Riglin, L., Jones, H.J., Zheng, J., Smith, G.D., Tilling, K., Thapar, A., Reichborn-Kjennerud, T., Stergiakouli, E., 2019. Association of maternal neurodevelopmental risk alleles with early-life exposures. *JAMA Psychiatr.* 76 (8), 834–842.
- Lewis, S.W., Murray, R.M., 1987. Obstetric complications, neurodevelopmental deviance, and risk of schizophrenia. *J. Psychiatr.* 21 (4), 413–421.
- Lindström, K., Lindblad, F., Hjern, A., 2009. Psychiatric morbidity in adolescents and young adults born preterm: a Swedish national cohort study. *Pediatrics* 123 (1), e47–e53.
- Logitharajah, P., Rutherford, M.A., Cowan, F.M., 2009. Hypoxic-ischemic encephalopathy in preterm infants: antecedent factors, brain imaging, and outcome. *Pediatr. Res.* 66 (2), 222–229.
- Løhaugen, G.C., Gramstad, A., Evensen, K.A.I., Martinussen, M., Lindqvist, S., Indredavik, M., Vik, T., Brubakk, A.M., Skranes, J., 2010. Cognitive profile in young adults born preterm at very low birthweight. *Dev. Med. Child Neurol.* 52 (12), 1133–1138.
- Lubsen, J., Vohr, B., Myers, E., Hampson, M., Lacadie, C., Schneider, K.C., Katz, K.H., Constable, R.T., Ment, L.R., 2011. Microstructural and functional connectivity in the developing preterm brain. *Seminars in Perinatology*. Elsevier, pp. 34–43.
- Luck, S.J., Gold, J.M., 2008. The construct of attention in schizophrenia. *Biol. Psychiatr.* 64 (1), 34–39.
- Lund, L.K., Vik, T., Lydersen, S., Løhaugen, G.C., Skranes, J., Brubakk, A.-M., Indredavik, M.S., 2012. Mental health, quality of life and social relations in young adults born with low birth weight. *Health Qual. Life Outcomes* 10 (1), 1–10.
- Mallard, C., Tremblay, M.-E., Vexler, Z.S., 2019. Microglia and neonatal brain injury. *Neuroscience* 405, 68–76.
- Manley, B.J., Doyle, L.W., Davies, M.W., Davis, P.G., 2015. Fifty years in neonatology. *J. Paediatr. Child Health* 51 (1), 118–121.
- Marcus, J., Hans, S.L., Auerbach, J.G., Auerbach, A.G., 1993. Children at risk for schizophrenia: the Jerusalem Infant Development Study: II. Neurobehavioral deficits at school age. *Arch. Gen. Psychiatr.* 50 (10), 797–809.
- Marlow, N., 2014. Anesthesia and long-term outcomes after neonatal intensive care. *Pediatr. Anesth.* 24 (1), 60–67.
- Masucci, M.D., Lister, A., Corcoran, C.M., Brucato, G., Girgis, R.R., 2018. Motor dysfunction as a risk factor for conversion to psychosis independent of medication use in a psychosis-risk cohort. *J. Nerv. Ment. Dis.* 206 (5), 356.
- Mathiasen, R., Hansen, B.M., Forman, J.L., Kessing, L.V., Greisen, G., 2011. The risk of psychiatric disorders in individuals born prematurely in Denmark from 1974 to 1996. *Acta Paediatr.* 100 (5), 691–699.
- McIntosh, A.M., Owens, D.C., Moorhead, W.J., Whalley, H.C., Stanfield, A.C., Hall, J., Johnstone, E.C., Lawrie, S.M., 2011. Longitudinal volume reductions in people at high genetic risk of schizophrenia as they develop psychosis. *Biol. Psychiatr.* 69 (10), 953–958.
- McLaughlin, K.A., Colich, N.L., Rodman, A.M., Weissman, D.G., 2020. Mechanisms linking childhood trauma exposure and psychopathology: a transdiagnostic model of risk and resilience. *BMC Med.* 18, 1–11.
- McTeague, L.M., Huemer, J., Carreon, D.M., Jiang, Y., Eickhoff, S.B., Etkin, A., 2017. Identification of common neural circuit disruptions in cognitive control across psychiatric disorders. *Am. J. Psychiatr.* 174 (7), 676–685.
- Meng, C., Bäuml, J., Daamen, M., Jaekel, J., Neitzel, J., Scheef, L., Busch, B., Baumann, N., Boecker, H., Zimmer, C., 2016. Extensive and interrelated subcortical white and gray matter alterations in preterm-born adults. *Brain Struct. Funct.* 221 (4), 2109–2121.
- Ment, L.R., Peterson, B.S., Vohr, B., Allan, W., Schneider, K.C., Lacadie, C., Katz, K.H., Maller-Kesselman, J., Pugh, K., Duncan, C.C., 2006. Cortical recruitment patterns in children born prematurely compared with control subjects during a passive listening functional magnetic resonance imaging task. *J. Pediatr.* 149 (4), 490–498.e492.
- Messerschmidt, A., Fuiko, R., Prayer, D., Brugger, P.C., Boltshauser, E., Zoder, G., Sterniste, W., Weber, M., Birnbacher, R., 2008. Disrupted cerebellar development in preterm infants is associated with impaired neurodevelopmental outcome. *Eur. J. Pediatr.* 167 (10), 1141–1147.
- Miller, D.J., Duka, T., Stimpson, C.D., Schapiro, S.J., Baze, W.B., McArthur, M.J., Fobbs, A.J., Sousa, A.M., Šestan, N., Wildman, D.E., 2012. Prolonged myelination in human neocortical evolution. *Proc. Natl. Acad. Sci.* 109 (41), 16480–16485.
- Minzenberg, M.J., Laird, A.R., Thelen, S., Carter, C.S., Glahn, D.C., 2009. Meta-analysis of 41 functional neuroimaging studies of executive function in schizophrenia. *Arch. Gen. Psychiatr.* 66 (8), 811–822.
- Mollon, J., Reichenberg, A., 2018. Cognitive development prior to onset of psychosis. *Psychol. Med.* 48 (3), 392.

- Montagna, A., Nosarti, C., 2016. Socio-emotional development following very preterm birth: pathways to psychopathology. *Front. Psychol.* 7, 80.
- Montirosso, R., Piazza, C., Giusti, L., Provenzi, L., Ferrari, P.F., Reni, G., Borgatti, R., 2019. Exploring the EEG mu rhythm associated with observation and execution of a goal-directed action in 14-month-old preterm infants. *Sci. Rep.* 9 (1), 1–12.
- Mossad, S.I., Smith, M.L., Pang, E.W., Taylor, M.J., 2017. Neural correlates of “Theory of Mind” in very preterm born children. *Human Brain Map.* 38 (11), 5577–5589.
- Mouchet-Mages, S., Rodrigo, S., Cacia, A., Mouaffak, F., Olie, J., Meder, J., Oppenheim, C., Krebs, M., 2011. Correlations of cerebello-thalamo-prefrontal structure and neurological soft signs in patients with first-episode psychosis. *Acta Psychiatr. Scand.* 123 (6), 451–458.
- Murray, R.M., Lewis, S.W., 1987. Is schizophrenia a neurodevelopmental disorder? *Br. Med. J. (Clin. Res. Ed.)* 295 (6606), 681.
- Murray, R.M., Mehta, M., Di Forti, M., 2014. Different dopaminergic abnormalities underlie cannabis dependence and cannabis-induced psychosis. *Biol. Psychiat.* 75 (6), 430–431.
- Murray, R.M., Quattrone, D., Natesan, S., van Os, J., Nordentoft, M., Howes, O., Di Forti, M., Taylor, D., 2016. Should psychiatrists be more cautious about the long-term prophylactic use of antipsychotics? *Br. J. Psychiat.* 209 (5), 361–365.
- Murray, R.M., Bhavsar, V., Tripoli, G., Howes, O., 2017. 30 years on: how the neurodevelopmental hypothesis of schizophrenia morphed into the developmental risk factor model of psychosis. *Schizophr. Bull.* 43 (6), 1190–1196.
- Nagy, Z., Ashburner, J., Andersson, J., Jbabdi, S., Draganski, B., Skare, S., Böhm, B., Smedler, A.-C., Forssberg, H., Lagercrantz, H., 2009. Structural correlates of preterm birth in the adolescent brain. *Pediatrics* 124 (5), e964–e972.
- Nam, K.W., Castellanos, N., Simmons, A., Froudust-Walsh, S., Allin, M.P., Walshe, M., Murray, R.M., Evans, A., Muehlboeck, J.-S., Nosarti, C., 2015. Alterations in cortical thickness development in preterm-born individuals: Implications for high-order cognitive functions. *NeuroImage* 115, 64–75.
- Narberhaus, A., Lawrence, E., Allin, M.P., Walshe, M., McGuire, P., Rifkin, L., Murray, R., Nosarti, C., 2009. Neural substrates of visual paired associates in young adults with a history of very preterm birth: alterations in fronto-parieto-occipital networks and caudate nucleus. *Neuroimage* 47 (4), 1884–1893.
- Nath, M., Wong, T.P., Srivastava, L.K., 2020. Neurodevelopmental insights into circuit dysconnectivity in schizophrenia. *Progr. Neuro-Psychopharmacol. Biol. Psychiat.* 110047.
- Nosarti, C., Froudust-Walsh, S., 2016. Alterations in development of hippocampal and cortical memory mechanisms following very preterm birth. *Dev. Med. Child Neurol.* 58, 35–45.
- Nosarti, C., Al-Asady, M.H., Frangou, S., Stewart, A.L., Rifkin, L., Murray, R.M., 2002. Adolescents who were born very preterm have decreased brain volumes. *Brain* 125 (7), 1616–1623.
- Nosarti, C., Rubia, K., Smith, A.B., Fearson, S., Williams, S.C., Rifkin, L., Murray, R.M., 2006. Altered functional neuroanatomy of response inhibition in adolescent males who were born very preterm. *Dev. Med. Child Neurol.* 48 (4), 265–271.
- Nosarti, C., Giouroukou, E., Micali, N., Rifkin, L., Morris, R.G., Murray, R.M., 2007. Impaired executive functioning in young adults born very preterm. *J. Intl. Neuropsychol. Soc. JINS* 13 (4), 571.
- Nosarti, C., Giouroukou, E., Healy, E., Rifkin, L., Walshe, M., Reichenberg, A., Chitnis, X., Williams, S.C., Murray, R.M., 2008. Grey and white matter distribution in very preterm adolescents mediates neurodevelopmental outcome. *Brain* 131 (1), 205–217.
- Nosarti, C., Shergill, S.S., Allin, M.P., Walshe, M., Rifkin, L., Murray, R.M., McGuire, P.K., 2009. Neural substrates of letter fluency processing in young adults who were born very preterm: alterations in frontal and striatal regions. *Neuroimage* 47 (4), 1904–1913.
- Nosarti, C., Reichenberg, A., Murray, R.M., Cnattingius, S., Lambe, M.P., Yin, L., MacCabe, J., Rifkin, L., Hultman, C.M., 2012. Preterm birth and psychiatric disorders in young adult life. *Arch. Gen. Psychiat.* 69 (6), 610–617.
- Nosarti, C., Nam, K.W., Walshe, M., Murray, R.M., Cuddy, M., Rifkin, L., Allin, M.P., 2014. Preterm birth and structural brain alterations in early adulthood. *NeuroImage Clin.* 6, 180–191.
- Ohoshi, Y., Takahashi, S., Yamada, S., Ishida, T., Tsuda, K., Tsuji, T., Terada, M., Shinosaki, K., Uka, S., 2019. Microstructural abnormalities in callosal fibers and their relationship with cognitive function in schizophrenia: a tract-specific analysis study. *Brain Behav.* 9 (8), e01357.
- Olabi, B., Ellison-Wright, I., McIntosh, A.M., Wood, S.J., Bullmore, E., Lawrie, S.M., 2011. Are there progressive brain changes in schizophrenia? A meta-analysis of structural magnetic resonance imaging studies. *Biol. Psychiat.* 70 (1), 88–96.
- Olsen, A., Dennis, E.L., Evensen, K.A.L., Hollund, I.M.H., Løhaugen, G.C., Thompson, P.M., Brubakk, A.-M., Eikenes, L., Häberg, A.K., 2018. Preterm birth leads to hyper-reactive cognitive control processing and poor white matter organization in adulthood. *Neuroimage* 167, 419–428.
- Omizzolo, C., Thompson, D.K., Scratch, S.E., Stargatt, R., Lee, K.J., Cheong, J., Roberts, G., Doyle, L.W., Anderson, P.J., 2013. Hippocampal volume and memory and learning outcomes at 7 years in children born very preterm. *J. Intl. Neuropsychol. Soc. JINS* 19 (10), 1065.
- Palaniyappan, L., Liddle, P.F., 2012. Aberrant cortical gyrification in schizophrenia: a surface-based morphometry study. *J. Psychiat. Neurosci. JPN* 37 (6), 399.
- Pannek, K., George, J.M., Boyd, R.N., Colditz, P.B., Rose, S.E., Frapp, J., 2020. Brain microstructure and morphology of very preterm-born infants at term equivalent age: associations with motor and cognitive outcomes at 1 and 2 years. *NeuroImage* 221, 117163.
- Papini, C., Palaniyappan, L., Kroll, J., Froudust-Walsh, S., Murray, R.M., Nosarti, C., 2020. Altered cortical gyrification in adults who were born very preterm and its associations with cognition and mental health. *Biol. Psychiat. Cogn. Neurosci. Neuroimaging.* 5 (7), 640–650.
- Pascoe, M.J., Melzer, T.R., Horwood, L.J., Woodward, L.J., Darlow, B.A., 2019. Altered grey matter volume, perfusion and white matter integrity in very low birthweight adults. *NeuroImage Clin.* 22, 101780.
- Peralta, V., Cuesta, M.J., 2011. Neuromotor abnormalities in neuroleptic-naïve psychotic patients: antecedents, clinical correlates, and prediction of treatment response. *Compr. Psychiat.* 52 (2), 139–145.
- Peralta, V., de Jalón, E.G., Campos, M.S., Zandio, M., Sanchez-Torres, A., Cuesta, M.J., 2011. The meaning of childhood attention-deficit hyperactivity symptoms in patients with a first-episode of schizophrenia-spectrum psychosis. *Schizophr. Res.* 126 (1–3), 28–35.
- Peterson, B.S., Vohr, B., Staib, L.H., Cannistraci, C.J., Dolberg, A., Schneider, K.C., Katz, K.H., Westerveld, M., Sparrow, S., Anderson, A.W., 2000. Regional brain volume abnormalities and long-term cognitive outcome in preterm infants. *JAMA* 284 (15), 1939–1947.
- Poletti, M., Raballo, A., 2020. Developmental psychotic risk: toward a neurodevelopmentally informed staging of vulnerability to psychosis. *Harv. Rev. Psychiat.* 28 (4), 271–278.
- Poletti, M., Tortorella, A., Raballo, A., 2019. Impaired corollary discharge in psychosis and at-risk states: Integrating neurodevelopmental, phenomenological, and clinical perspectives. *Biol. Psychiat. Cogn. Neurosci. Neuroimaging* 4 (9), 832–841.
- Poole, K.L., Schmidt, L.A., Missiuna, C., Saigal, S., Boyle, M.H., Van Lieshout, R.J., 2015. Motor coordination difficulties in extremely low birth weight survivors across four decades. *J. Dev. Behav. Pediatr.* 36 (7), 521–528.
- Pyhälä, R., Räikkönen, K., Feldt, K., Andersson, S., Hovi, P., Eriksson, J.G., Järvenpää, A.-L., Kajantie, E., 2009. Blood pressure responses to psychosocial stress in young adults with very low birth weight: Helsinki study of very low birth weight adults. *Pediatrics* 123 (2), 731–734.
- Pyhälä, R., Wolford, E., Kautiainen, H., Andersson, S., Bartmann, P., Baumann, N., Brubakk, A.-M., Evensen, K.A.L., Hovi, P., Kajantie, E., 2017. Self-reported mental health problems among adults born preterm: a meta-analysis. *Pediatrics* 139 (4).
- Radua, J., Borgwardt, S., Crescini, A., Mataix-Cols, D., Meyer-Lindenberg, A., McGuire, P., Fusar-Poli, P., 2012. Multimodal meta-analysis of structural and functional brain changes in first episode psychosis and the effects of antipsychotic medication. *Neurosci. Biobehav. Rev.* 36 (10), 2325–2333.
- Reichenberg, A., 2005. Cognitive impairment as a risk factor for psychosis. *Dial. Clin. Neurosci.* 7 (1), 31.
- Reichenberg, A., Harvey, P.D., 2007. Neuropsychological impairments in schizophrenia: integration of performance-based and brain imaging findings. *Psychol. Bull.* 133 (5), 833.
- Robbins, T.W., 1990. The case for frontostriatal dysfunction in schizophrenia. *Schizophr. Bull.* 16 (3), 391.
- Robinson, R., Lahti-Pulkkinen, M., Schnitzlein, D., Voit, F., Girchenko, P., Wolke, D., Lemola, S., Kajantie, E., Heinonen, K., 2020. Mental health outcomes of adults born very preterm or with very low birth weight: a systematic review. *Seminars in Fetal and Neonatal Medicine.* Elsevier, p. 101113.
- Rogers, C.E., Anderson, P.J., Thompson, D.K., Kidokoro, H., Wallendorf, M., Treyvaud, K., Roberts, G., Doyle, L.W., Neil, J.J., Inder, T.E., 2012. Regional cerebral development at term relates to school-age social-emotional development in very preterm children. *J. Am. Acad. Child Adolesc. Psychiat.* 51 (2), 181–191.
- Roiser, J.P., Wigton, R., Kilner, J.M., Mendez, M.A., Hon, N., Friston, K.J., Joyce, E.M., 2013. Dysconnectivity in the frontoparietal attention network in schizophrenia. *Front. Psychiat.* 4.
- Rosanoff, A.J., Handy, L.M., Plesslet, I.R., Brush, S., 1934. The etiology of so-called schizophrenic psychoses: with special reference to their occurrence in twins. *Am. J. Psychiat.* 91 (2), 247–286.
- Saigal, S., 2014. Functional outcomes of very premature infants into adulthood. *Seminars in Fetal and Neonatal Medicine.* Elsevier, pp. 125–130.
- Salvan, P., Tournier, J.D., Batalle, D., Falconer, S., Chew, A., Kennea, N., Aljabar, P., Dehaene-Lambertz, G., Arichi, T., Edwards, A.D., 2017. Language ability in preterm children is associated with arcuate fasciculi microstructure at term. *Human Brain Map.* 38 (8), 3836–3847.
- Sanchez, S.E., Puente, G.C., Atencio, G., Qiu, C., Yanez, D., Gelaye, B., Williams, M.A., 2013. Risk of spontaneous preterm birth in relation to maternal depressive, anxiety and stress symptoms. *J. Reprod. Med.* 58, 25.
- Seeman, M.V., Seeman, P., 2014. Is schizophrenia a dopamine supersensitivity psychotic reaction? *Prog. Neuro-Psychopharmacol. Biol. Psychiat.* 48, 155–160.
- Seidman, L.J., Shapiro, D.I., Stone, W.S., Woodberry, K.A., Ronzio, A., Cornblatt, B.A., Addington, J., Bearden, C.E., Cadenhead, K.S., Cannon, T.D., 2016. Association of neurocognition with transition to psychosis: baseline functioning in the second phase of the North American Prodrome Longitudinal Study. *JAMA Psychiat.* 73 (12), 1239–1248.
- Selten, J.-P., Cantor-Graae, E., 2005. Social defeat: risk factor for schizophrenia? *Br. J. Psychiat.* 187 (2), 101–102.
- Shang, J., Fisher, P., Bäuml, J.G., Daamen, M., Baumann, N., Zimmer, C., Bartmann, P., Boecker, H., Wolke, D., Sorg, C., 2019. A machine learning investigation of volumetric and functional MRI abnormalities in adults born preterm. *Human Brain Map.* 40 (14), 4239–4252.
- Sheffield, J.M., Karcher, N.R., Barch, D.M., 2018. Cognitive deficits in psychotic disorders: a lifespan perspective. *Neuropsychol. Rev.* 28 (4), 509–533.
- Shi, F., Yap, P.-T., Gao, W., Lin, W., Gilmore, J.H., Shen, D., 2012. Altered structural connectivity in neonates at genetic risk for schizophrenia: a combined study using morphological and white matter networks. *Neuroimage* 62 (3), 1622–1633.
- Skranes, J., Vangberg, T., Kulseng, S., Indredavik, M., Evensen, K., Martinussen, M., Dale, A., Haraldseth, O., Brubakk, A.-M., 2007. Clinical findings and white matter abnormalities seen on diffusion tensor imaging in adolescents with very low birth weight. *Brain* 130 (3), 654–666.

- Smith, G.C., Gutovich, J., Smyser, C., Pineda, R., Newnham, C., Tjoeng, T.H., Vavasseur, C., Wallendorf, M., Neil, J., Inder, T., 2011. Neonatal intensive care unit stress is associated with brain development in preterm infants. *Ann. Neurol.* 70 (4), 541–549.
- Soria-Pastor, S., Gimenez, M., Narberhaus, A., Falcon, C., Botet, F., Bargallo, N., Mercader, J.M., Junque, C., 2008. Patterns of cerebral white matter damage and cognitive impairment in adolescents born very preterm. *Int. J. Dev. Neurosci.* 26 (7), 647–654.
- Sripada, K., Løhaugen, G.C., Eikenes, L., Bjørlykke, K.M., Håberg, A.K., Skranes, J., Rimol, L.M., 2015. Visual-motor deficits relate to altered gray and white matter in young adults born preterm with very low birth weight. *Neuroimage* 109, 493–504.
- Steen, R.G., Mull, C., McClure, R., Hamer, R.M., Lieberman, J.A., 2006. Brain volume in first-episode schizophrenia: systematic review and meta-analysis of magnetic resonance imaging studies. *Br. J. Psychiat.* 188 (6), 510–518.
- Stefanis, N., Frangou, S., Yakeley, J., Sharma, T., O'Connell, P., Morgan, K., Sigmundsson, T., Taylor, M., Murray, R., 1999. Hippocampal volume reduction in schizophrenia: effects of genetic risk and pregnancy and birth complications. *Biol. Psychiat.* 46 (5), 697–702.
- Stewart, A., Rifkin, L., Amess, P., Kirkbride, V., Townsend, J., Miller, D., Lewis, S., Kingsley, D., Moseley, I., Foster, O., 1999. Brain structure and neurocognitive and behavioural function in adolescents who were born very preterm. *Lancet* 353 (9165), 1653–1657.
- Supramaniam, V., Vontell, R., Srinivasan, L., Wyatt-Ashmead, J., Hagberg, H., Rutherford, M., 2013. Microglia activation in the extremely preterm human brain. *Pediatr. Res.* 73 (3), 301–309.
- Taylor, H.G., 2017. Outcomes of preterm birth: a lifespan perspective. *Dev. Med. Child Neurol.* 59 (5), 454.
- Tikka, D.L., Singh, A.R., Tikka, S.K., 2020. Social cognitive endophenotypes in schizophrenia: a study comparing first episode schizophrenia patients and individuals at clinical-and familial-'at-risk' for psychosis. *Schizophr. Res.* 215, 157–166.
- Treyvaud, K., 2014. Parent and family outcomes following very preterm or very low birth weight birth: a review. *Seminars in Fetal and Neonatal Medicine*. Elsevier, pp. 131–135.
- Tseng, C.E.J., Froudast-Walsh, S., Brittain, P.J., Karolis, V., Caldinelli, C., Kroll, J., Counsell, S.J., Williams, S.C., Murray, R.M., Nosarti, C., 2017. A multimodal imaging study of recognition memory in very preterm born adults. *Human Brain Map.* 38 (2), 644–655.
- Tseng, C.-E.J., Froudast-Walsh, S., Kroll, J., Karolis, V., Brittain, P.J., Palamin, N., Clifton, H., Counsell, S.J., Williams, S.C., Murray, R.M., 2019. Verbal fluency is affected by altered brain lateralization in adults who were born very preterm. *Eneuro* 6 (2).
- Tu, P.-C., Lee, Y.-C., Chen, Y.-S., Li, C.-T., Su, T.-P., 2013. Schizophrenia and the brain's control network: aberrant within-and between-network connectivity of the frontoparietal network in schizophrenia. *Schizophr. Res.* 147 (2-3), 339–347.
- Ullman, H., Spencer-Smith, M., Thompson, D.K., Doyle, L.W., Inder, T.E., Anderson, P.J., Klingberg, T., 2015. Neonatal MRI is associated with future cognition and academic achievement in preterm children. *Brain* 138 (11), 3251–3262.
- Urbain, C., Sato, J., Hammill, C., Duerden, E.G., Taylor, M.J., 2019. Converging function, structure, and behavioural features of emotion regulation in very preterm children. *Human Brain Map.* 40 (11), 3385–3397.
- Venkatesh, K.K., Ferguson, K.K., Smith, N.A., Cantonwine, D.E., McElrath, T.F., 2019. Association of antenatal depression with clinical subtypes of preterm birth. *Am. J. Perinatol.* 36 (06), 567–573.
- Vercammen, A., Morris, R., Green, M.J., Lenroot, R., Kulkarni, J., Carr, V.J., Weickert, C.S., Weickert, T.W., 2012. Reduced neural activity of the prefrontal cognitive control circuitry during response inhibition to negative words in people with schizophrenia. *J. Psychiat. Neurosci.* JPN 37 (6), 379.
- Vita, A., De Peri, L., Silenzi, C., Dieci, M., 2006. Brain morphology in first-episode schizophrenia: a meta-analysis of quantitative magnetic resonance imaging studies. *Schizophr. Res.* 82 (1), 75–88.
- Vollmer, B., Lundequist, A., Mårtensson, G., Nagy, Z., Lagercrantz, H., Smedler, A.-C., Forssberg, H., 2017. Correlation between white matter microstructure and executive functions suggests early developmental influence on long fibre tracts in preterm born adolescents. *PloS One* 12 (6), e0178893.
- Volpe, J.J., 2009. Brain injury in premature infants: a complex amalgam of destructive and developmental disturbances. *Lancet Neurol.* 8 (1), 110–124.
- Wadhwa, P.D., Culhane, J.F., Rauh, V., Barve, S.S., Hogan, V., Sandman, C.A., Hobel, C.J., Chic-DeMet, A., Dunkel-Schetter, C., Garite, T.J., 2001. Stress, infection and preterm birth: a biobehavioural perspective. *Paediatr. Perinat. Epidemiol.* 15, 17–29.
- Walker, E., Bollini, A.M., 2002. Pubertal neurodevelopment and the emergence of psychotic symptoms. *Schizophr. Res.* 54 (1-2), 17–23.
- Walshe, M., Rifkin, L., Rooney, M., Healy, E., Nosarti, C., Wyatt, J., Stahl, D., Murray, R., Allin, M., 2008. Psychiatric disorder in young adults born very preterm: role of family history. *Eur. Psychiat.* 23 (7), 527–531.
- Weinberger, D.R., 1987. Implications of normal brain development for the pathogenesis of schizophrenia. *Arch. Gen. Psychiat.* 44 (7), 660–669.
- White, T.P., Symington, I., Castellanos, N.P., Brittain, P.J., Walsh, S.F., Nam, K.-W., Sato, J.R., Allin, M.P., Shergill, S.S., Murray, R.M., 2014. Dysconnectivity of neurocognitive networks at rest in very-preterm born adults. *NeuroImage Clin.* 4, 352–365.
- Windrem, M.S., Osipovitch, M., Liu, Z., Bates, J., Chandler-Militello, D., Zou, L., Munir, J., Schanz, S., McCoy, K., Miller, R.H., 2017. Human iPSC glial mouse chimeras reveal glial contributions to schizophrenia. *Cell Stem Cell* 21 (2), 195–208.e196.
- Xiong, T., Gonzalez, F., Mu, D.-Z., 2012. An overview of risk factors for poor neurodevelopmental outcome associated with prematurity. *World J. Pediatr.* 8 (4), 293–300.