



www.sciencedirect.com
www.rbmonline.com



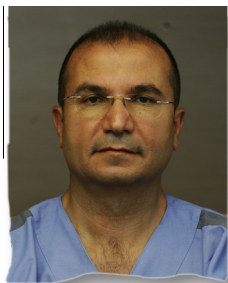
ARTICLE

ICSI pregnancy outcomes following hysteroscopic placement of Essure devices for hydrosalpinx in laparoscopic contraindicated patients

Kemal Ozgur ^a, Hasan Bulut ^a, Murat Berkkanoglu ^a, Kevin Coetzee ^{a,b,*}, Gamze Kaya ^a

^a Antalya IVF, Halide Edip Cd. No:7, Kanal Mh., Antalya 07080, Turkey; ^b Vitale, Halide Edip Cd. No:7, Kanal Mah., Antalya 07080, Turkey

* Corresponding author. E-mail address: kevincoetzee61@yahoo.co.nz (K Coetzee). URL: <http://www.antalyatupbebek.com.tr> (K. Coetzee)



Kemal Ozgur, MD completed his residency training in obstetrics and gynecology in 1993 at Akdeniz University, Turkey, after which he completed a 3-year fellowship in reproductive endocrinology and infertility at Tygerberg Hospital, South Africa and the Jones Institute, Norfolk, USA. He returned to Akdeniz University in 1997 and established the IVF unit at the university. Two years later, Dr Ozgur founded Antalya IVF, the largest IVF centre in southern Turkey. His major areas of interest are assisted reproduction, andrology and hysteroscopic surgery. He has published extensively in these fields, with over 30 articles published in renowned international journals.

Abstract This study investigated the use of hysteroscopic Essure device placement for the treatment of hydrosalpinx-related infertility in patients with laparoscopic contraindications and compared their pregnancy outcomes following assisted conception treatment with those of patients having had laparoscopic tubal ligation. A total of 102 infertile patients were diagnosed with unilateral or bilateral hydrosalpinges: 26 patients had laparoscopic contraindications and were treated hysteroscopically and 76 patients were treated laparoscopically. In total, 66 intracytoplasmic sperm injection (ICSI) and 39 frozen embryo transfer (FET) procedures were performed. In the hysteroscopy group, 13 ICSI and eight FET in 16 patients resulted in 10 pregnancies (pregnancy rates 47.6% per transfer and 62.5% per patient), and in the laparoscopy group, 53 ICSI and 31 FET embryo transfers in 54 patients resulted in 36 pregnancies (pregnancy rates 42.9% per transfer and 66.7% per patient). Live birth rates per assisted reproduction procedure were 23.8% (5/21) in the hysteroscopy group and 32.1% (27/84) for the laparoscopy group. The hysteroscopic placement of Essure devices to isolate hydrosalpinx prior to assisted conception treatment produced pregnancy outcomes comparable to those produced following laparoscopic tubal ligation. The live birth rates indicate that a larger, more comparative, prospectively randomized study is required.

RBMO Online

© 2014, Reproductive Healthcare Ltd. Published by Elsevier Ltd. All rights reserved.

KEYWORDS: Essure, hydrosalpinx, hysteroscopy, ICSI, laparoscopy, live birth

<http://dx.doi.org/10.1016/j.rbmo.2014.03.005>

1472-6483/© 2014, Reproductive Healthcare Ltd. Published by Elsevier Ltd. All rights reserved.

Please cite this article in press as: Ozgur, K et al. ICSI pregnancy outcomes following hysteroscopic placement of Essure devices for hydrosalpinx in laparoscopic contraindicated patients. Reproductive BioMedicine Online (2014), <http://dx.doi.org/10.1016/j.rbmo.2014.03.005>

Introduction

Tubal factor infertility was one of the original motivations for the development of IVF and currently still accounts for up to 35% of female infertility. A significant subgroup of tubal factor infertility is hydrosalpinx-associated tubal factor. Women diagnosed with tubal hydrosalpinges, especially if bilateral and visible by ultrasound, have the worst possible prognosis for pregnancy from assisted conception treatment (Camus et al., 1999; Strandell et al., 1999, 2001) compared with patients with other tubal factors. The pathophysiology of hydrosalpinx has been linked to the continuous tubo-uterine reflux of hydrosalpinx fluid. Some of the adverse effects that have been attributed to the presence of hydrosalpinx fluid in the uterine cavity are; embryo cytotoxicity, altered embryo–endometrium receptivity, the dilution of the nutritional components of normal intrauterine fluid and altered tubo-uterine flow dynamics (Strandell and Lindhard, 2002).

Investigations to eliminate the effects of hydrosalpinx on female fecundity, based on the suggested pathophysiological effects of hydrosalpinx, have focused on interventions that disrupt the tubo-uterine communication from affected tubes. Several retrospective and prospective studies have been completed and provide substantiated evidence that interventions such as laparoscopic salpingectomy significantly improve implantation, ongoing pregnancy and live birth rates (Johnson et al., 2010; Strandell et al., 1999, 2001). Laparoscopic surgery, such as salpingectomy or tubal ligation, however, has to be performed under general anaesthesia in a hospital situation (Johnson et al., 2010). The operational mode of these procedures make them invasive, subject to relatively high levels of risk and complication and are often contraindicated for infertile women, because of the existence of severe intra-abdominal adhesions and pathophysiologies.

The Essure system (Conceptus, San Carlos, CA, USA), approved in November 2002 by the US Food and Drug Federation for tubal sterilization (Hurskainen et al., 2010; Shah et al., 2011), has recently been introduced to the management of hydrosalpinx (Hitkari et al., 2007; Kerin and Cattanach, 2007) to improve patient fecundity in assisted conception programmes. The transfer of its application to assisted conception was prompted by its proven effectiveness in tubal sterilization, its transcervical application and the reduced risk associated with hysteroscopic procedures. The proximal occlusion of a hydrosalpinx by the hysteroscopic placement of an Essure device also provides women for whom laparoscopic surgery is contraindicated with a feasible therapeutic alternative. The Essure insert is a spring-like device consisting of a stainless steel inner coil and a nickel titanium elastic outer coil and polyethylene fibres. The device is inserted into a Fallopian tube using a standard hysteroscope. Following insertion, the polyethylene fibres elicit a benign fibrotic tissue ingrowth which blocks the Fallopian tube over time, isolating the hydrosalpinx (Hurskainen et al., 2010; Shah et al., 2011; Ubeda et al., 2004).

In this study centre, laparoscopic tubal surgery has, as in other programmes, been the routine means for treating hydrosalpinx prior to assisted conception treatment, but often meant patients with severe intra-abdominal adhesions

and pathologies were left untreated, because of their determinately high risk for complications. This study retrospectively examined the assisted conception pregnancy outcomes following the introductory use of hysteroscopic Essure device placement for the treatment of hydrosalpinx in patients with laparoscopic contraindications. In the second arm of this dual-cohort study, the pregnancy outcomes of patients diagnosed with hydrosalpinx only and treated laparoscopically were also analysed as a comparative measure to treatment success.

Materials and methods

This retrospective study examined the clinical data from patients who presented to Antalya IVF for assisted reproduction treatment during the period 2009–2012, specifically patients who were diagnosed with hydrosalpinx-related tubal infertility. The presence of hydrosalpinges were confirmed with a midcycle diagnostic transvaginal ultrasound examination. A hysterosalpingography (HSG) was performed if a definitive diagnosis could not be made by ultrasound. In total, 102 patients had a confirmed diagnosis, 56 of whom indicated in their fertility history that they had previous assisted conception procedures elsewhere. All patients received counselling on the implications and risks of the procedures and informed consent was obtained before the therapeutic tubal procedure was scheduled to be performed. No institutional approval for this retrospective review was sought, as all procedures and medical devices were approved by the Turkish Health Ministry and were used in accordance with patient prognosis.

In addition to hydrosalpinx diagnosis, 26 patients had contraindications of varying type and severity for laparoscopic surgery. The contraindications for laparoscopy were mostly due to intra-abdominal adhesions of various aetiologies (pelvic endometriosis, frozen pelvis due to pelvic inflammatory disease, laparoscopic surgery). In one patient, the contraindication for laparoscopic surgery was morbid obesity. All patients who had contraindications were scheduled for hysteroscopic procedure for the placement of an Essure device (HE group), while all other patients ($n = 76$) were scheduled to have laparoscopic tubal ligation (TL group) procedures.

All procedures performed in the study, including oocyte retrieval, were performed under propofol-based general anaesthesia as ambulatory procedures. All patients had their therapeutic procedures scheduled for the early proliferative phase of their menstrual cycles to ensure the absence of bleeding and a thin endometrium. All hysteroscopy patients were given 1 misoprostol pill (200 g, Cytotec; Searle, UK) to administer vaginally 2 h before their procedures. The Essure device (ESS305, Conceptus) was delivered by hysteroscope (26252BB BIOH; Karl Storz), without cervical dilatation through a 5% mannitol solution-distended uterus, using a dedicated delivery system. The device was inserted through the utero-tubal ostia and released intramurally in a proximal position with no more than four coils left protruding into the uterus. In three patients, the procedure to place the Essure device was unsuccessful: in the first patient, the tubal ostium of the affected Fallopian tube could not be visually located; in the second patient, access to the uterine cavity

was severely restricted due to an extremely retroflexed uterus held in position by adhesions associated with frozen pelvis syndrome; and in the third patient, the ostium was visualized but the microinsert could not be inserted beyond 4–5 mm into the tubal lumen due to a severe kink in the tubal lumen caused by hydrosalpinx-related distortions. Uni- or bilateral laparoscopic tubal ligation was performed using a method described as bipolar coagulation and proximal tubal cut, leaving the cut tube in place. Two hours post-operatively, all patients were assessed before being discharged. All Essure patients were scheduled to have a follow-up assessment 3 months after the procedure to assess their satisfaction with the procedure and to check insert placement.

The first 10 patients of the HE group had a HSG procedure performed 3 months after their hysteroscopy procedure to confirm insert placement and tubal occlusion. In all 10 patients, the devices were found to be correctly placed and complete tubal occlusion had occurred. Thereafter, HSG procedures were only performed in patients where placements were considered difficult, and all other patients were only assessed for correct placement using transvaginal ultrasound. From this study centre's experience and evidence from published studies that show that when correct placement was achieved >95% of patients have complete tubal occlusion (Gerritse et al., 2009; Shah et al., 2011; Ubada et al., 2004), the decision was made to spare the patients the added risk and cost of HSG.

All IVF treatments (intracytoplasmic sperm injection (ICSI) and frozen embryo transfer (FET)) for both laparoscopic and hysteroscopic patients were scheduled to start after a stand-down period of at least 2 months from the date of hydrosalpinx treatment (Berkkanoglu and Ozgur, 2007). All patients at Antalya IVF undergo ICSI cycles. Ovarian stimulation was performed using a gonadotrophin-releasing hormone (GnRH) antagonist protocol with a combination of recombinant FSH (Gonal-F; Merck Serono) and human menopausal gonadotrophin (Menopur; Ferring Pharmaceuticals). Response to ovarian stimulation was monitored by serial transvaginal ultrasound follicular measurements. GnRH antagonist (Cetrotide, 0.25 mg; Merck Serono) was started once leading follicles reached 14 mm in diameter and ovulation was induced by human chorionic gonadotrophin (HCG; 250 µg/0.05 ml; Ovidrel; Merck Serono) trigger when at least three follicles reached 17 mm in diameter. Transvaginal ultrasound-guided oocyte retrieval was performed 36 h after ovulation induction. Retrieved oocytes were denuded and all mature oocytes were fertilized by ICSI. A maximum of two embryos were transferred on day 3 or day 5. Freezing and thawing of embryos were performed using Vitrolife freeze- and thaw-kits (Vitrolife, Sweden) according to the manufacturer's recommendations. Briefly, embryos were frozen by transferring them through an equilibration and freezing solution step, loading them into straws (IMV, France) and freezing them using a controlled-rate freezer (Planer, UK), and embryos were thawed by warming and transferring them through rehydration and equilibration solution steps. Finally, rinsed embryos were placed in culture media droplets covered with light mineral oil and incubated until transfer.

Frozen embryo transfer cycles were performed in a hormone replacement cycle using oestradiol (2 mg b.d.;

Estrofem, Novo Nordisk) and progesterone (8% b.f.; Crinone, Merck Serono). Oestradiol tablets were started before day 4 of the cycle and endometrial thickness was evaluated on cycle days 9 and 11, with a thickness <6 mm required. Progesterone was started on cycle day 15 (embryo day 0). A maximum of two frozen-thawed day-3 or day-5 embryos were transferred. The same luteal phase supplementation protocol of oestradiol and progesterone was continued for at least 9 weeks of gestation if pregnant.

Pregnancy was defined as a positive day-14 β-HCG. Live birth was defined as the delivery of at least one live fetus after 20 weeks of gestation. The delivery of a singleton or twin pregnancy was counted as one live birth.

Results

Intra-operative complications led to the failure to successfully place Essure devices by hysteroscopy in three patients, who were excluded from analysis. Correct placement and total occlusion of the affected tube was confirmed by HSG in 10 patients. Thereafter, only correct placement was confirmed by transvaginal ultrasound. No significant post-operative complications occurred in either group. Of the 99 patients, 26 who underwent hysteroscopic ($n = 7$) or laparoscopic ($n = 19$) tubal procedures for hydrosalpinx did not proceed to an assisted conception treatment. Three patients from the TL group had an incomplete cycle because there was no transferable embryos and for that reason were not included in the analysis of pregnancy outcome. During the study period, the overall pregnancy rate for ICSI procedures reaching embryo transfer was 47.4% (2299/4848).

Of the 23 infertile women included in the HE group, 17 had primary infertility. Women in this group were aged 23–40 (31.5 ± 5.8 years) and were diagnosed with unilateral ($n = 16$) or bilateral ($n = 7$) hydrosalpinges (Table 1). Of the 76 infertile women in the TL group, 38 had primary infertility. Women in this group were aged 18–46 (32.9 ± 5.4 years) and were diagnosed with unilateral ($n = 49$) or bilateral ($n = 27$) hydrosalpinges (Table 1). The duration of infertility for patients in both groups was 5.6 years. Patients from both groups had ICSI and FET treatments prior to having tubal surgery at Antalya IVF: 14 patients in the HE group and 42 in the TL group. None of the assisted conception treatments performed prior to tubal surgery resulted in clinical pregnancy.

In the HE group, 16 patients underwent 21 embryo transfer cycles (13 ICSI and eight FET), which resulted in 10 pregnancies in 10 patients, and the pregnancy rates were 47.6% per transfer and 62.5% per patient (Table 1). In the TL group, 54 patients underwent 84 embryo transfer cycles (53 ICSI and 31 FET), which resulted in 36 pregnancies in 30 patients, and the pregnancy rates were 42.9% per transfer and 66.7% per patient (Table 1). The proportion of ICSI to FET were similar in the two groups: 61.9% ICSI in the HE group and 63.1% ICSI in the TL group.

In the HE group, five of the 10 pregnancies (50.0%) progressed normally to live deliveries after 20 weeks of gestation, giving a live birth rate per transfer of 23.8% (Table 1) per treatment cycle. The outcomes for the five pregnancies lost in the HE group were: two cycles had empty fetal sacs, one cycle miscarried at 8 weeks, one at

Table 1 Demographic characteristics and IVF outcomes of patients treated with laparoscopic tubal ligation and hysteroscopic placement of an Essure device.

	HE (n = 23)	TL (n = 76)
Age (years)	31.5 ± 5.7 (23–40)	32.9 ± 5.4 (18–46)
Duration of infertility (years)	5.6 ± 4.5 (2–20)	5.6 ± 4.6 (0.33–17)
Primary diagnosis		
Unilateral hydrosalpinx	16	49
Bilateral hydrosalpinx	7	27
Secondary diagnosis		
DOR ¹	10	13
Anovulation	0	7
Unexplained	2	11
Male	4	16
Previous assisted reproduction treatment		
Procedures ^a	14	42
Pregnancies	0	2 ^b
Post-procedure assisted reproduction treatment		
Patients	16	54
Transfers ^a	21	84
Pregnancies ^c	10	36
Patients with a pregnancy	10 (62.5)	30 (55.6)
Live births	5	27
Pregnancies/transfer	47.6	42.9
Pregnancies/patient	62.5	66.7
Live births/pregnancy	50.0	75.0
Live births/transfer	23.8	32.1

Values are mean ± SD (range), n or n (%).

¹DOR = decreased ovarian reserve (<10 antral follicle count).

^aBoth intracytoplasmic sperm injection and frozen embryo transfer.

^bEctopic pregnancies.

^cPositive day-14 β-human chorionic gonadotrophin.

21 weeks and one at 27 weeks of gestation. In the TL group, 27 of the 36 pregnancies (75.0%) progressed normally to live deliveries, resulting in a live birth rate per transfer of 32.1% (Table 1). Of the nine pregnancies lost in TL group, eight were first-trimester losses (5–14 weeks) and one was a second-trimester loss (25 weeks).

Discussion

Sufficient evidence exists that shows the significant effect of exposure of the uterine cavity to hydrosalpinx fluid has on female fecundity and the significant improvement that can be gained from the occlusion of the hydrosalpinges through the use of appropriate therapeutic interventions, and this evidence strongly supported by this study, where no clinical pregnancies were achieved in 56 assisted conception cycles completed by patients prior to having therapeutic procedures for hydrosalpinx. The two pregnancies that did occur were both nonviable ectopic pregnancies. This is in stark contrast to the pregnancy outcomes achieved from the 105 assisted conception treatments in 99 women following laparoscopic or hysteroscopic procedures to isolate the

diagnosed hydrosalpinges. In total, 46 pregnancies were obtained (per treatment pregnancy rate 43.8%, 46/105). The rate compared favourably with the 47.9% pregnancy rate achieved for all ICSI-only cycles performed during the same time period.

Although laparoscopic procedures have historical proven efficacy, the cumulative risks for patients intending to undergo IVF treatment have always been a concern. Hysteroscopic procedures, generally regarded as simpler and safer, have been used for more than a century. It was, however, only after the approval of the Essure system and numerous tubal sterilization studies showing hysteroscopic placement of an Essure device to be a safe, minimally invasive, short in duration and effective tubal sterilization procedure that proximal tubal occlusion using an Essure device became a possible alternative for hydrosalpinx isolation in assisted conception programmes (Shah et al., 2011). An effective transcervical alternative is certainly a more appropriate adjunct treatment in an assisted conception programme, especially as many infertile women have contraindications for laparoscopic surgery (Shah et al., 2011).

The transcervical hysteroscopic placement of an Essure device has consistently been reported to be a minimally

invasive and relatively simple treatment method (Hitkari et al., 2007; Hurskainen et al., 2010; Kerin and Cattanach, 2007). This study centre's experience with the Essure system confirms this status, because the insertion of the devices during the study period occurred without any significant intra-operative and post-operative complications and have been generally well tolerated by patients. Procedures are currently being performed using an office hysteroscopy set up under general anaesthesia in an ambulatory setting, but the experience gained from performing the 26 procedures has shown that the procedure can easily be performed using mild sedation and/or local anaesthetic in cases where there are no anatomical complications and the tubal ostia are clearly visible.

Contraception studies, including long-term follow-up studies, have shown the Essure system to be a highly effective method for tubal occlusion (Galen and Khan, 2010; Hurskainen et al., 2010; Rios Castillo et al., 2011). The success rate of tubal occlusion has been shown to approach 100% if the device is positioned correctly and an appropriate length of time is allowed for complete occlusion to occur (Hurskainen et al., 2010; Rios Castillo et al., 2011). There was only one concern with regards to using an Essure device for tubal occlusion in an assisted conception situation, about the possible effect of the coils protruding into the uterus on implantation and ongoing pregnancy (Kerin and Cattanach, 2007). Therefore, most investigators using the system in conjunction with assisted reproductive treatment have tried to limit the number of coils protruding into the uterus (Galen and Khan, 2010; Kerin and Cattanach, 2007) by inserting the devices as deeply possible without reducing the device's effectiveness. In studies where the number of coils were limited to no more than four, it was found to hold no threat to implantation or ongoing pregnancy (Hitkari et al., 2007; Kerin and Cattanach, 2007; Mijatovic et al., 2010). A study by Velasco Sanchez et al. (2011) assessed the safety of Essure devices in pregnancy by examining the pregnancy outcomes of 10 unintended pregnancies resulting from 4500 sterilization procedures; no incidents of preterm premature membrane rupture or preterm delivery of ongoing pregnancies were found. Based on the published evidence and methodologies, the current study therefore limited the number of coils to no more than four in the surgical application of the Essure devices in this patient group.

In the few studies that have investigated the use of the Essure system in infertile women with hydrosalpinges prior to assisted conception treatment, all report successful pregnancies, ongoing pregnancies and deliveries (Galen and Khan, 2010; Mijatovic et al., 2010; Nichols and West, 2010; Rabanal et al., 2010). In one study similar to the present one (Mijatovic et al., 2010), 10 women had uni- or bilateral hysteroscopic placement of an Essure device to isolate hydrosalpinges prior to assisted conception treatment because of laparoscopy contraindications and an ongoing pregnancy rate of 40% was reported. The results from the current study also show that a correctly placed Essure device is able to eliminate the negative effect of hydrosalpinge fluid on conception, with pregnancy outcomes achieved that are comparable not only to those obtained after laparoscopic tubal ligation but also to the overall ICSI pregnancy rate for patients treated during the study period.

Of the 23 women that had hysteroscopic placement of an Essure device, 16 patients went onto have 13 ICSI and eight FET treatment cycles, with a resultant pregnancy rate of 47.6% per transfer and 62.5% per patient. In the TL group, very similar pregnancy rates were achieved (42.9% per treatment and 66.7% per patient). As a proportion of the total number of patients treated, more patients achieved a pregnancy in the HE group. However, and most likely because of infertility aetiology or the small size of the HE group and not because of the use of the Essure system, lower live birth rates per pregnancy (50.0% versus 75.0%) and per treatment (23.8% versus 32.1%) were achieved. Pregnancy losses in the HE group occurred in both the first and the second trimesters of pregnancy.

In conclusion, this study confirms that the hysteroscopic placement of an Essure device can be successfully used as a method to treat hydrosalpinx in patients with intra-abdominal conditions that preclude the use of laparoscopy. Not only does this work report a highly comparable pregnancy rate but also it also confirms that ongoing pregnancy and delivery may not be compromised by using the Essure system. Although the transcervical approach of the Essure system certainly presents an attractive alternative to the invasive and restrictive laparoscopic approach to tubal occlusion, the question of whether the Essure system could be used universally for the treatment of hydrosalpinx in assisted conception programme can only be fully answered by a prospective randomized study.

References

- Berkkanoglu, M., Ozgur, K., 2007. The optimum time interval of an ICSI/ET cycle with laparoscopic tubal occlusion for hydrosalpinges. *Fertil. Steril.* 88, S332.
- Camus, E., Poncelet, C., Goffinet, F., Wainer, B., Merlet, F., Nisand, I., Phillipe, H.J., 1999. Pregnancy rates after in-vitro fertilization in cases of tubal fertility with and without hydrosalpinx: a meta-analysis of published comparative studies. *Hum. Reprod.* 14, 1243–1249.
- Galen, D.I., Khan, N.M., 2010. Use of Essure micro-insert for the treatment of hydrosalpinx prior to in vitro fertilization: a multicenter IDE/IRB off-label study. *Fertil. Steril.* 94, S55.
- Gerritse, M.B.E., Veersema, S., Timmermans, A., Brölmann, H.A.M., 2009. Incorrect position of Essure microinserts 3 months after successful bilateral placement. *Fertil. Steril.* 91, e1–e5.
- Hitkari, J.A., Singh, S.S., Shapiro, H.M., Leylan, N., 2007. Essure treatment of hydrosalpinges. *Fertil. Steril.* 88, 1663–1666.
- Hurskainen, R., Hovi, S.-L., Gissler, M., Grahn, R., Kukkonen-Harjula, K., Nord-Saari, M., Makela, M., 2010. Hysteroscopic tubal sterilization: a systematic review of the Essure system. *Fertil. Steril.* 94, 16–19.
- Johnson, N., van Voorst, S., Sowter, M.C., Strandell, A., Mol, B.W., 2010. Surgical treatment for tubal disease in women due to undergo in vitro fertilization. *Cochrane Database Syst. Rev.* 20, CD002125.
- Kerin, J.F., Cattanach, S., 2007. Successful pregnancy outcome with the use of in vitro fertilization after Essure hysteroscopic sterilization. *Fertil. Steril.* 87, 1212–1214.
- Mijatovic, V., Veersema, S., Emanuel, M.H., Schats, R., Hompes, P.G.A., 2010. Essure hysteroscopic tubal occlusion device for the treatment of hydrosalpinx prior to in vitro fertilization-embryo transfer in patients with contraindication for laparoscopy. *Fertil. Steril.* 93, 1338–1342.

- Nichols, J.E., West, J.R., 2010. Success of Essure® micro-inserts in the treatment of hydrosalpinx prior to in vitro fertilization (IVF)/frozen embryo transfer (FET) and pregnancy outcomes. *Fertil. Steril.* 94, S245.
- Rabanal, A., Prieto, B., Matorras, R., Urquijo, E., Diez, S., Brouard, I., Martinez-Astorquiza, T., 2010. Hysteroscopic treatment of hydrosalpinx prior to in vitro fertilization – embryo transfer (IVF-ET). *Hum. Reprod.* 25, i64–i65.
- Rios Castillo, J., Velasco Sanchez, E., Povedano Canizares, B., de Andres Cara, M., Lorent Gonzalez, J., Arjona Berral, J.E., 2011. Longterm efficacy of female sterilization with Essure device. *Hum. Reprod.* 26, i247.
- Shah, V., Panay, N., Williamson, R., Hemingway, A., 2011. Hysterosalpingogram: an essential examination following Essure hysteroscopic sterilisation. *Br. J. Radiol.* 84, 805–812.
- Strandell, A., Lindhard, A., 2002. Why does hydrosalpinx reduce fertility? *Hum. Reprod.* 17, 1141–1145.
- Strandell, A., Lindhard, A., Waldenstrom, U., Thornburn, J., Janson, P.O., Hamberger, L., 1999. Hydrosalpinx and IVF outcome: a prospective, randomized multicentre trial in Scandinavia on salpingectomy prior to IVF. *Hum. Reprod.* 14, 2762–2769.
- Strandell, A., Lindhard, A., Waldenstrom, U., Thornburn, J., 2001. Hydrosalpinx and IVF outcome: cumulative results after salpingectomy in a randomized controlled trial. *Hum. Reprod.* 16, 2403–2410.
- Ubeda, A., Labastida, R., Dexeus, S., 2004. Essure®: a new device for hysteroscopic tubal sterilization in an outpatient setting. *Fertil. Steril.* 82, 196–199.
- Velasco Sanchez, E., Rios Castillo, J., Arjona Berral, J.E., Povedano Canizares, B., Lorent Gonzalez, J., de Andres Cara, M., 2011. Pregnancy outcomes and perinatal results of unintended pregnancies following EssureR sterilization: descriptive study of 10 cases. *Hum. Reprod.* 26, i247.

Declaration: The authors report no financial or commercial conflicts of interest.

Received 25 September 2013; refereed 27 February 2014; accepted 6 March 2014.