



A minority of patients with functional seizures have abnormalities on neuroimaging

Wesley T. Kerr^{a,b,*}, John K. Lee^a, Amir H. Karimi^a, Hiroyuki Tatekawa^c, L. Brian Hickman^{a,d}, Michael Connerney^a, Siddhika S. Sreenivasan^a, Ishita Dubey^a, Corinne H. Allas^a, Jena M. Smith^a, Ivanka Savic^{a,e}, Daniel H.S. Silverman^f, Lubomir M. Hadjiiski^g, Nicholas J. Beimer^{h,i}, William C. Stacey^{h,j}, Mark S. Cohen^{a,b,c,k}, Jerome Engel Jr^{a,b,l,m}, Jamie D. Feusner^{b,e,n,o,p}, Noriko Salamon^{a,c}, John M. Stern^a

^a Department of Neurology, David Geffen School of Medicine at UCLA, Los Angeles, CA, USA

^b Department of Psychiatry and Biobehavioral Sciences, University of California Los Angeles, Los Angeles, CA, USA

^c Department of Radiology, David Geffen School of Medicine at UCLA, Los Angeles, CA, USA

^d Department of Internal Medicine, University of California at Irvine, Irvine, CA, USA

^e Department of Women's and Children's Health, Karolinska Institute and Neurology Clinic, Karolinska University Hospital, Karolinska Universitetssjukhuset, Stockholm, Sweden

^f Department of Molecular and Medical Pharmacology, University of California Los Angeles, Los Angeles, CA, USA

^g Department of Radiology, Michigan Medicine, University of Michigan, Ann Arbor, MI, USA

^h Department of Neurology, Michigan Medicine, University of Michigan, Ann Arbor, MI, USA

ⁱ Department of Psychiatry, Michigan Medicine, University of Michigan, Ann Arbor, MI, USA

^j Department of Biomedical Engineering, University of Michigan, Ann Arbor, MI, USA

^k Departments of Bioengineering, Psychology and Biomedical Physics, David Geffen School of Medicine at UCLA, Los Angeles, CA, USA

^l Department of Neurobiology, David Geffen School of Medicine at UCLA, Los Angeles, CA, USA

^m Brain Research Institute, University of California Los Angeles, Los Angeles, CA, USA

ⁿ Centre for Addiction and Mental Health, Toronto, Canada

^o Department of Psychiatry, University of Toronto, Toronto, Canada

^p Department of Clinical Neuroscience, Karolinska Institute, Stockholm, Sweden

ARTICLE INFO

Keywords:

Decision analysis
Clinical diagnostics
Psychogenic non-epileptic seizures
Conversion disorder
Dissociative seizures

ABSTRACT

Objective: Functional seizures often are managed incorrectly as a diagnosis of exclusion. However, a significant minority of patients with functional seizures may have abnormalities on neuroimaging that typically are associated with epilepsy, leading to diagnostic confusion. We evaluated the rate of epilepsy-associated findings on MRI, FDG-PET, and CT in patients with functional seizures.

Methods: We studied radiologists' reports from neuroimages at our comprehensive epilepsy center from a consecutive series of patients diagnosed with functional seizures without comorbid epilepsy from 2006 to 2019. We summarized the MRI, FDG-PET, and CT results as follows: within normal limits, incidental findings, unrelated findings, non-specific abnormalities, post-operative study, epilepsy risk factors (ERF), borderline epilepsy-associated findings (EAF), and definitive EAF.

Results: Of the 256 MRIs, 23% demonstrated ERF (5%), borderline EAF (8%), or definitive EAF (10%). The most common EAF was hippocampal sclerosis, with the majority of borderline EAF comprising hippocampal atrophy without T2 hyperintensity or vice versa. Of the 87 FDG-PETs, 26% demonstrated borderline EAF (17%) or definitive EAF (8%). Epilepsy-associated findings primarily included focal hypometabolism, especially of the temporal lobes, with borderline findings including subtle or questionable hypometabolism. Of the 51 CTs, only 2% had definitive EAF.

Abbreviations: ASM, antiseizure medication; ES, Epileptic Seizures; FS, Functional Seizures; MRI, Magnetic Resonance Imaging; PET, fluorodeoxyglucose-positron emission tomography; CT, X-ray computed tomography; SPECT, single positron emission spectroscopy; EEG, electroencephalography; vEEG, video-electroencephalography; ERF, Epilepsy risk factors; EAF, Epilepsy-associated finding; UCLA, University of California, Los Angeles; T, Tesla.

* Corresponding author at: 710 Westwood Plaza, Suite 1-240, Box 951769, Los Angeles, CA 90095, USA.

E-mail address: WesleyTK@ucla.edu (W.T. Kerr).

<https://doi.org/10.1016/j.jns.2021.117548>

Received 28 May 2021; Received in revised form 12 June 2021; Accepted 16 June 2021

Available online 18 June 2021

0022-510X/© 2021 The Authors. Published by Elsevier B.V. This is an open access article under the CC BY license (<http://creativecommons.org/licenses/by/4.0/>).

Significance: This large case series provides further evidence that, while uncommon, EAF are seen in patients with functional seizures. A significant portion of these abnormal findings are borderline. The moderately high rate of these abnormalities may represent framing bias from the indication of the study being “seizures,” the relative subtlety of EAF, or effects of antiseizure medications.

1. Introduction

Functional seizures (FS) are paroxysmal events where patients lose conscious control of their movements, awareness, or sensations [1]. Alternate terms for FS include dissociative seizures and psychogenic nonepileptic seizures [2–4]. While these seizures may appear behaviorally similar to epileptic seizures (ES), they are not caused by abnormal epileptic neural activity and are not treated with antiseizure medications (ASMs) [5,6]. Instead, the term, functional seizures, represents an abnormality of the function of the nervous system that is not typically associated with a definitive structural abnormality [2].

Consequently, clinicians may presume that neuroimaging of patients with FS would be normal, and abnormal neuroimaging should cast doubt on the diagnosis. However, multiple retrospective studies have demonstrated radiologically apparent abnormalities in 30% of magnetic resonance images (MRIs) from patients with FS without comorbid ES [7–14]. While the majority of these abnormalities were nonspecific, two previous studies found that 5–10% of them had definitive epilepsy-associated findings (EAF) including hippocampal sclerosis [7,10]. This rate of nonspecific abnormalities is markedly higher than healthy controls, who typically have nonspecific findings on 2–18% of MRIs, with the rate of EAF being too low to quantify reliably [15–24]. In the years following most of these prior studies, the development of epilepsy-specific scanning protocols and widespread adoption of 3 Tesla scanners have led to higher image quality and sensitivity for subtle abnormalities [8,25]. In patients with temporal lobe epilepsy with hippocampal sclerosis, 86% of 1.5 Tesla MRIs using standard protocols failed to illustrate this key finding [26,27]. Therefore, the rate of neuroimaging abnormalities in FS should be re-addressed.

In addition to these findings that were detectable using visual analysis by a specialized neuroradiologist, quantitative neuroimaging has demonstrated significant morphometric, connectivity and metabolic changes in patients with FS as compared to seizure-naïve controls and patients with epilepsy [28–39]. Quantitative morphometry has demonstrated changes in the left amygdala, right hippocampus, left insula, left lateral orbital cortex, and bilateral medial orbital cortices [30,40]. In addition to these morphometric changes, there are alterations in the connectivity of the limbic network, executive control network, and motor control networks in multiple areas as measured using functional MRI, diffusion tractography, single positron emission spectroscopy (SPECT), and high-density electroencephalography (EEG) [41–44]. Each of these findings suggest that there are observable changes in the structure of the brain in functional seizures, in addition to changes in the function.

We hypothesized that the rate of radiologically apparent findings in patients with FS was related to the use of higher quality imaging protocols. As nonspecific or equivocal findings are a common challenge in clinical practice, we also hypothesized that the frequency of borderline as compared to definitive EAF would be elevated (e.g. temporal T2 hyperintensity without atrophy versus hippocampal sclerosis), and we would observe more sequelae of history that are epilepsy risk factors (ERF) but are associated less strongly with epilepsy (e.g. prior intracerebral hemorrhage). Because our protocol includes the acquisition of interictal fluorodeoxyglucose-positron emission tomography (PET) on the first day of video-EEG (vEEG) monitoring, we uniquely evaluate the hypothesis that the frequency of ERF and EAF on PET may be similar to MRI, and they may correlate within the same patient. Lastly, we hypothesized that ERF or EAF may be associated with key clinical factors and these associations may provide further interpretation on the impact

or consequence of abnormal imaging on clinical care.

2. Material and methods

Our patient population includes all patients with functional seizures admitted to the UCLA adult vEEG monitoring unit between January 2006 and December 2019. Diagnosis met the International League Against Epilepsy criteria for “documented” [1], and was formed using expert clinical opinion based on the available clinical history, physical exam, ictal vEEG, and structural MRI. We excluded patients with mixed functional and epileptic seizures, because EAF on neuroimaging could be attributed to the comorbid epilepsy. While all patients were adults at the time of vEEG, some were younger than 18 at the time of the imaging. Age was reported at time of imaging and was calculated at the days between their birthdate and the date of imaging. Comorbidities and confounding factors were obtained from retrospective chart review as well as, after May 2015, direct prospective interview, as described elsewhere [45].

Neuroimaging was obtained as part of the clinical care of these patients. MRI was acquired if prior imaging was not obtained, was more than several years prior to presentation, or of insufficient quality for evaluation of epilepsy. Similarly, X-ray computed tomography (CT) was obtained if the patient had contraindications to MRI and imaging was needed. If MRI or CT scans were collected as part of care in our health system separate from vEEG evaluation, these results were included. Our protocol for PET scanning at the time of vEEG, is to obtain the PET on the morning after admission prior to reduction of antiseizure medications. Therefore, due to diagnostic uncertainty, PET scans sometimes were obtained in patients who eventually were diagnosed with functional seizures.

Radiologists' reports of neuroimaging were obtained through chart review. We included neuroimages acquired at the University of California, Los Angeles (UCLA) that were deemed of sufficient quality for a radiologist to review. We excluded neuroimages obtained at outside facilities, irrespective of if they were re-reviewed internally. When multiple images were available, we included the most recent image before or during admission to vEEG and excluded images obtained after vEEG admission. We included all indications for MRI imaging including but not limited to seizure. While the majority of these images were read by fellowship trained neuroradiologists, this was not required. Additionally, we did not include further information obtained by re-review by neurologists, epileptologists, fellowship-trained neuroradiologists, or neuroradiologists specializing in epilepsy unless an addendum was made to the original radiology report.

For the MRIs, images were obtained on a diversity of scanners throughout the health system. We recorded the strength of the magnetic field, model of the scanner, and if a specialized epilepsy-protocol was used. The epilepsy-specific protocol has been developed and used to improve sensitivity for detection of subtle abnormalities like hippocampal sclerosis and focal cortical dysplasia by having 1 mm isotropic volumetric pixels (voxels) and additional sequences perpendicular to the axis of the hippocampus.

The CT images were obtained on a diversity of scanners throughout the health system and had a variety of acquisition protocols. For the PETs, these data were obtained on a single scanner that was maintained throughout the period of the study. The PET scans were acquired on a combined PET-CT scanner but the resolution of the simultaneously acquired CT was limited to only what was necessary for attenuation correction; therefore we did not include interpretations of the CT

obtained during PET scanning.

The findings and impression from the radiology report were sorted into the following categories: within normal limits (WNL), incidental findings alone, findings unrelated to seizures, nonspecific findings, post-operative imaging, epilepsy risk factors (ERF), borderline epilepsy-associated factors (EAF), and definitive EAF (see Supplemental Table 1 for detailed list of which findings were included in each category). This categorization was based on our interpretation of prior literature and has not been published or validated elsewhere. When analyzing the associations between clinical factors and imaging findings, we excluded post-operative imaging and compared EAF or ERF to all other findings.

For MRI, definitive EAF included but was not limited to hippocampal sclerosis, tuberous sclerosis complex, focal cortical dysplasia, and encephalomalacia [46–56]. Borderline EAF included but was not limited to hippocampal atrophy without T2 hyperintensity, hippocampal T2 hyperintensity without atrophy, subtle or questionable findings for focal cortical dysplasia [57–62]. ERF included cortically based infarcts or T2 hyperintensities, cavernous malformations, old supratentorial intracerebral hemorrhages, and cortically adjacent masses [63–67]. Each of these represent sequelae of risk factors for epilepsy, but they are not associated as strongly with epileptic seizures as the EAF. Nonspecific findings included, but were not limited to, subcortical white matter T2 hyperintensities, meningiomas without mass effect, and lobar or diffuse cortical volume loss [57,64,68–77]. Findings unrelated to epilepsy included empty sella, Chiari 1 malformation, and T2 hyperintensities consistent with multiple sclerosis [74,78–81]. Incidental findings included, but were not limited to, pineal cysts without mass effect or edema [73,82–84]. All post-operative images were reported separately irrespective of concomitant findings. For CT, these similar definitions were used but hypodensities were seen as compared to T2 hyperintensities [69,73,85,86].

For PET, definitive EAF included focal hypometabolism in a particular lobe or area of cortex, whereas mild or subtle hypometabolism in a similar region was categorized as a borderline EAF [87–91].

We compared the correspondence between borderline or definitive EAF on MRI and PET using Cohen's kappa statistics. The association between the imaging findings and age, cardiovascular disease, prior antiseizure medications, current antiseizure medications, and delay to diagnosis was evaluated using Student's *t*-tests, log-normal *t*-tests for delay to vEEG [92], and Fisher exact tests. Patients with missing data were excluded from the relevant pairwise comparisons (complete case analysis). All intervals reflect 95% confidence intervals of chance, with all frequency-based intervals calculated using binomial exact statistics.

All patients consented for the use of their records in research, and the UCLA Institutional Review Board approved this study. This work is consistent with Declaration of Helsinki. De-identified raw data and code for this study is available at <https://SeizureDisorderCenterResearchGroup.org/>.

3. Results

The demographics for the patients with neuroimaging are listed in Table 1. During the study period, roughly 1600 unique patients were admitted for vEEG, of which 445 were diagnosed with functional seizures without comorbid epilepsy. MRI from UCLA was available in 58% (256/445) of patients, whereas FDG-PET was available in 20% (87/445), and CT was available in 11% (51/445). There were no systematic differences in age or sex in the availability of imaging at UCLA. Of patients who had an MRI, 32% (82/256) also had an FDG-PET and 19% (49/256) also had a CT. Of patients who had an FDG-PET, 94% (82/87) also had an MRI and 8% (7/87) also had a CT. Overall, 23% (56/256) of MRIs were obtained with epilepsy protocol and 45% (68/150) had a magnet strength of 3 Tesla as compared to 1.5 Tesla. The magnet strength was not specified in the radiologist's report or electronic health record in the remaining 106 MRIs.

The rates of each type of finding on MRI, PET, CT are summarized in

Table 1

Demographic table of the age and gender of patients based on what imaging was available. All reflects all patients with functional seizures. Columns reflect patients with each imaging modality available, and rows reflect proportion of patients with the column's imaging modality available that also have the row's imaging modality available. Confidence intervals (CI) are binomial exact. Abbreviations: interquartile range (IQR), magnetic resonance imaging (MRI), positron emission tomography (PET), computed tomography (CT).

	Statistic	Available Imaging			
		All	MRI	PET	CT
Age	Median	34	32	32	33
	IQR	23–45	22–44	22–44	24–43
Female	Prevalence (%)	75	77	71	78
	95% CI	70–79	71–83	62–81	66–89
Duration	Median (years)	3	4	8	5
Seizure Disorder	IQR	1–10	1.4–11	2.5–18	1.6–18
Also Available					
MRI	Frequency (%)	58	100	94	94
	95% CI	53–63	–	88–99	86–100
PET	Frequency (%)	20	32	100	14
	95% CI	15–24	26–38	–	5–24
CT	Frequency (%)	11	19	8	100
	95% CI	8–15	14–24	2–14	–

Fig. 1 and listed in Supplemental Table 2. The rates of ERF, borderline EAF, or definitive EAF were 23% (95% CI 18–30%) for MRI, 26% (95% CI 16–35%) for PET, and 2% (95% CI 0–7%) for CT. Cohen's kappa for the association between ERF or EAF on MRI compared to PET was 15% (95% CI -10% to 41%).

Female sex was associated with a decreased rate of ERF or EAF on MRI (odds ratio 0.31, 95% CI 0.16–0.60, Fisher exact $p = 0.0005$). Patients with ERF or EAF on MRI were taking more ASMs (mean 2.0 versus 1.3 ASMs, 95% CI of difference 0.3–1.1, $p = 0.0004$) but there was no difference in the number of past ASMs ($p = 0.4$). Patients with ERF or EAF on MRI also were older (mean 38 versus 32 years, 95% CI of difference 2–11 years, $p = 0.003$). No other clinical factors were significantly associated with the rate of ERF or EAF on MRI, PET, or CT including age, BMI, number of current ASMs, number of past ASMs, or time from seizure onset to vEEG monitoring (Supplemental Table 3). When specified, there was no association the likelihood of ERF or EAF and if the scan was epilepsy protocol, the magnetic field was 3 Tesla, or the scanner model (Supplemental Table 3).

4. Discussion

While the majority of patients with functional seizures have normal or nonspecific findings on neuroimaging, a substantial minority have findings that have been associated with epilepsy. Therefore, we caution clinicians against anchoring on visually appealing images: epilepsy-associated findings on neuroimaging do not rule out functional seizures. These abnormal findings were associated with more current ASMs, but not past ASMs or delay to vEEG monitoring in our dataset. The interpretation of the observed abnormal findings is an emerging field of research. We discuss two potential hypotheses: cognitive biases of radiologists in a challenging clinical scenario and subtle structural correlates of functional seizures or common comorbidities.

First, we consider contribution of framing bias. This cognitive bias is present when the result of a study is influenced by how the study is presented or how the question is asked [93]. Many neuroimaging findings associated with medication resistant epilepsy are subtle and are appreciated better with specialized imaging protocols [8,20,94,95]. Even though 45% of our MRIs were obtained at 3 T and 23% were obtained with epilepsy protocol, the radiologists were challenged to evaluate uniformly for subtle, clinically relevant findings in a non-ideal setting. Unfortunately, this non-ideal setting is similar to typical clinical practice. All clinicians, radiologists included, need to integrate the

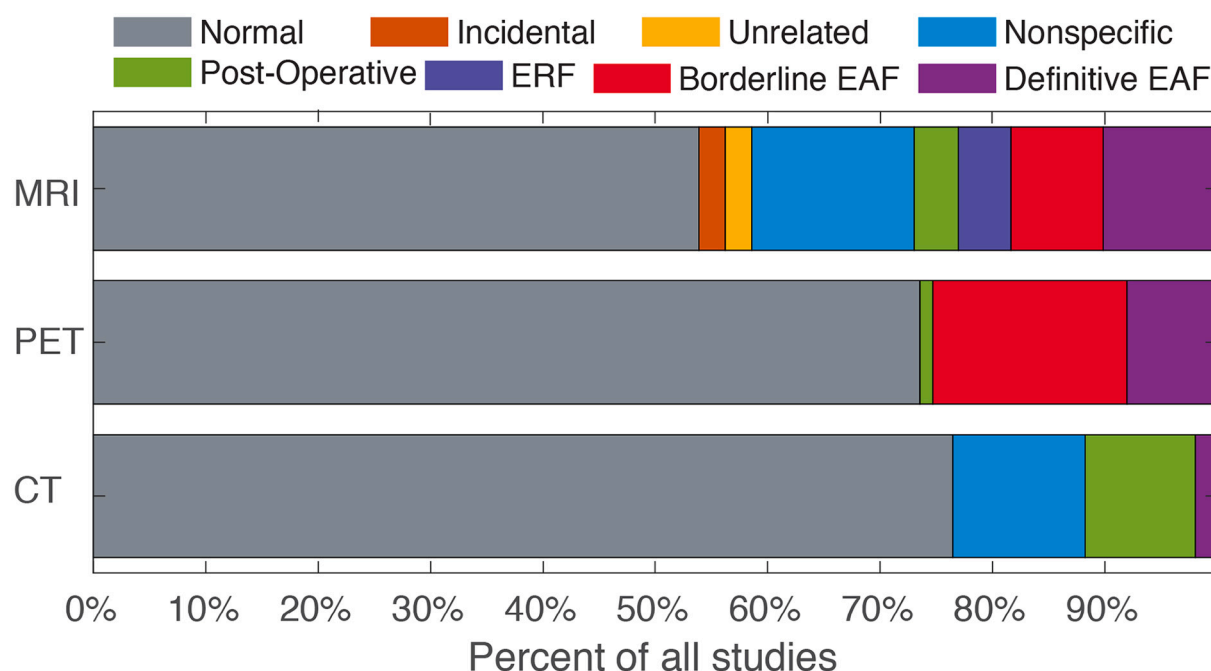


Fig. 1. The rate of each type of neuroimaging finding by imaging modality. Abbreviations: epilepsy risk factor (ERF), epilepsy associated finding (EAF).

clinical history with radiological findings to provide an interpretation that impacts diagnosis and management. Video-EEG monitoring in a patient with epilepsy typically occurs as an element of the presurgical evaluation for medication-resistant epilepsy where, if a surgically intervenable lesion is identified, surgery or neuromodulation could improve patient's seizure frequency, quality of life, and cost of care substantially [96]. Outside of this clinical context, the pre-test probability for EAF is negligible [15–20]. Whereas, in a similar clinical context of 804 patients with epilepsy, 37% of 3 T MRIs were normal, 20% had incidental findings, 20% had EAF, and 4% had ERF [25]. While this dataset of patients with epilepsy had an elevated rate of post-surgical findings (17%) compared to ours, these frequencies of EAF and ERF in patients with epilepsy roughly matches the frequency of findings in our patients.

Therefore, by providing a history of seizures, the non-radiologist raises the pre-test probability that an EAF will be present. This history of seizure potentially leads to an increased detection of abnormalities (higher sensitivity), but this may come at a cost of decreased specificity due to borderline findings being noted as significant. The cost of false positives incurred by this high sensitivity may be low when neuroimaging findings were clinically correlated with clinical history; scalp video-EEG; and potentially intracranial video-EEG and other neurodiagnostic modalities (e.g. magnetoencephalography, neuropsychiatric testing). In contrast, the cost of false negatives from low specificity may be high because the rates of seizure freedom after surgery are higher in lesional (MRI-positive and PET-positive) epilepsy as compared to non-lesional (MRI-negative or PET-negative) epilepsy [97–100]. This bias for high sensitivity may be reflected by the high frequency of borderline EAF. In the PET reports, borderline findings were noted twice as often as clear findings (17% versus 8%). The detection of surgically intervenable lesions is increased by coregistration of PET with MRI [87,88]. However, there was a lack of association between EAF on MRI and PET in our data. This highlights that it was appropriate for radiologists to denote these findings as borderline because, when viewed within the context of a single other neuroimaging modality, the costs of false positives were mitigated.

However, not all of our findings support a framing bias because we did not observe an increased rate of EAF in 3 T or epilepsy-protocol MRIs. The increase in resolution of these modalities may offset the

additional framing bias of acquiring specialized imaging. Alternatively, there may be a ceiling effect where patient history was more important than acquisition protocol.

However, this rate of neuroimaging abnormalities in functional seizures cannot be explained entirely by cognitive errors of radiologists. There is increasing quantitative evidence for structural and metabolic abnormalities in patients with functional seizures [38,40]. In specific, the emerging biopsychosocial model of functional neurological disorders includes changes in functional connectivity between areas involved in emotional processing (limbic network), motor control, and volitional or conscious processing of emotions [41]. This limbic network includes the amygdala, hippocampus, and cingulate gyrus that, coincidentally, are the most common localization for medication-resistant epilepsy in adults. In a subset of these patients with higher quality MRI, we quantitatively demonstrated significant atrophy in amygdala and hippocampus in patients with functional seizures as compared to seizure-naïve controls and, notably, did not observe a significant difference in the amygdalar volume between functional seizures and temporal lobe epilepsy without hippocampal sclerosis [40]. While the degree of structural findings we see in functional seizures has not been reported in other functional neurological disorders, quantitative left hippocampal volume was inversely correlated with lifetime adverse events in patients with functional movement disorder [101].

Alternatively, these findings may represent structural correlates of common comorbidities of functional seizures. While radiologists qualitatively control for age when interpreting volumes, temporal lobe atrophy increases with age and older patients more frequently had ERF or EAF on MRI [102]. Temporal lobe atrophy also has been reported in depression, PTSD, and survivors of sexual abuse [103–107], all of which are common in patients with functional seizures [108,109]. Migraines also were a common comorbidity of functional seizures; one study demonstrated borderline or definitive mesial temporal sclerosis in 19% (13/73, 95% CI 10–29%) of migraineurs without epilepsy [110]. This markedly elevated rate is different from other studies of incidental hippocampal sclerosis in patients without seizures or migraines [19,20]. One explanation is that the degree of atrophy in functional seizures is less than in patients with temporal lobe epilepsy [40], therefore the findings in functional seizures may be described by radiologists as subtle, mild, or equivocal. Additionally, the increased rate of many EAF

and ERF with age may be nonspecific (e.g. post-infarct or post-traumatic encephalomalacia or gliosis, intracranial neoplasms or masses [111,112]).

This understanding of the subtle neuroanatomical changes associated with functional seizures illustrates the importance of nuance and level of evidence for neuroimaging findings. A substantial portion of the reported EAF were borderline and, especially for MRI, many nonspecific findings were reported. Therefore, we suggest that these borderline and nonspecific findings be viewed in the context of other clinical information like history, electrophysiology, and seizure observations. One objective method to integrate history and neurodiagnostic evidence is the clinical diagnostic support tool named Differential Diagnosis of Epilepsy versus Functional Seizures (DDESVSFS) [113]. Janocko and colleagues commented that, of the 30% of patients with functional seizures who had abnormal imaging, the majority of findings were nonspecific. In comparison, 50% of patients with epilepsy had abnormal imaging. In other studies, 60% of patients with functional seizures with comorbid epilepsy had abnormal imaging [10,43]. However, they and others who made similar observations did not quantify the level of certainty or frequency of neuroimaging findings more strongly associated with epilepsy. Therefore, some degree of structural abnormalities may reflect the underlying neural network changes seen in functional seizures, but the heterogeneity of findings and the level of prior evidence make this explanation a conjecture. Further direct and controlled comparisons between imaging and clinical findings in epilepsy, functional seizures, other functional neurological disorders, and appropriate psychiatric and medical comorbidities are necessary to characterize the unique imaging correlates of disease.

A direct comparison to patients with epilepsy would need to include temporal lobe epilepsy with and without hippocampal sclerosis, as well as non-temporal lobe epilepsies. Additionally, to evaluate the influence of framing bias, intra-observer consistency and inter-observer variation, each neuroimage would need to be re-adjudicated by multiple radiologists in a research context. These comparisons across patient groups would be most valuable if imaging results were viewed in the context of clinical history (e.g. DDESVSFS [114] and Functional Seizures Likelihood Score [45]) and EEG [114], which would require more discussion. While we did not compare directly the rate of neuroimaging findings in functional seizures to a similar population of patients with epilepsy at our center or re-adjudicate the radiologists' impression, the current work provides further details regarding the types of neuroimaging findings observed in patients with functional seizures in clinical practice.

We hypothesized that abnormal neuroimaging may delay referral to vEEG monitoring or prompt more trials of ASMs. The increased rate of ASM treatment and polytherapy in patients with ERF or EAF supported this hypothesis, but this did not translate to a difference in diagnostic delay. This supports that abnormal MRI likely influenced clinical management by increasing clinician's suspicion for epilepsy. The International League Against Epilepsy recommends referral for vEEG monitoring when patients with seizures are not seizure free after two appropriately chosen and tolerated ASMs. However, the average patient with functional seizures and ERF or EAF on MRI was currently taking 2 ASMs and had tried 1.5 ASMs in the past, suggesting a delay in referral [5,92]. This type of hesitancy for referral also is seen in patients with epilepsy [115]. We did not observe a diagnostic delay from abnormal imaging, likely due to a ceiling effect because the average delay to vEEG monitoring was 9–10 years in our patients both with and without abnormal MRI. The curious increase in the rate of abnormal MRI in men also was observed in a recent Indian dataset, but the interpretation remains unclear [11].

An alternative explanation for the increased rate of ERF or EAF in patients taking ASMs is that the ASMs could have an effect on neuroimaging findings. While the cerebellar effect of sodium channel blockers is established, we did not frequently observe cerebellar atrophy in patients with functional seizures. Outside the cerebellum, most studies of the effect of ASMs on neuroimaging focus on differences observed on

functional MRI [116]. One study demonstrated decreased amygdalar volume in adolescents with bipolar disorder and a 6-week exposure to valproate [117]. However, other MRI studies of patients with bipolar disorder on long term valproate did not observe similar differences [118,119]. Therefore, while we could not definitively determine that increased ASM use was a cause or an effect of ERF or EAF in this cross-sectional study, prior literature suggests that these neuroimaging findings would be unlikely to be caused by ASMs alone.

An important limitation in our approach is that neuroimages were obtained as part of clinical care and as such were not available for all patients and were not acquired on the same scanners with the same protocols. While we expect the quality of neuroimaging at our comprehensive epilepsy center to be higher than a non-specialized center, this limited data quality matches what is often available clinically. Additionally, when compared to the aforementioned studies of MRI findings in patients without seizures [15,18–24], a higher proportion of our images were obtained on 3 Tesla scanners, and many were obtained with the specialized epilepsy-protocol. While we did not observe increased rates of EAF or ERF with these higher quality images in patients with functional seizures, our elevated rate of incidental and nonspecific findings may be attributed to these differences in quality. Future studies that directly compare patients with functional seizures to seizure-naïve controls and patients with epilepsy would improve the interpretation of neuroimaging findings in patients with functional seizures.

Additionally, our rate of image availability was low and matched prior similar studies [7,120,121]. While we did not observe associations between confounding factors and imaging availability, there likely was a bias to obtain neuroimaging in patients with a higher pretest probability of epilepsy or who had demonstrated abnormalities on outside imaging. Therefore, these numbers may represent an overestimate of the rate of neuroimaging findings in patients with functional seizures. Additionally, while our center has pediatric vEEG monitoring, we excluded this population from this work, so our results may not generalize to pediatric or adolescent patients with functional seizures.

5. Conclusions

Neuroimaging findings associated with epilepsy do not rule out functional seizures. While the majority of patients had normal neuroimaging, a substantial proportion had findings that are strongly associated with epilepsy [48]. These findings likely represent a framing bias of radiologists evaluating neuroimages of patients with a history of seizures or represent subtle structural or metabolic correlates of the underlying network alterations in functional seizures. In the future, these imaging correlates of disease can be clarified by direct comparisons between patients with functional seizures, epilepsy, other functional neurological disorders, and psychiatric disorders.

Conflicts & ethical publication

Drs. Engel, Stern, Lee, Hickman, Connerney, Silverman, Beimer, Stacey, Salamon, and Kerr have clinical responsibilities that include the diagnosis and treatment of patients with epilepsy and non-epileptic seizures. The remaining authors have no declared conflicts of interest. We confirm that we have read the Journal's position on issues involved in ethical publication and affirm that this report is consistent with those guidelines.

Acknowledgements

The authors thank Kirk Shattuck and Marc Nuwer for organization support, access to the data, and technical support. This work was supported by the National Institutes of Health (R25 NS065723, T32 GM08042, T90 DA022768, R90 DA022768, R90 DA023422, T32 GM008185, R01 NS033310, & P20 NS080181) and the William M. Keck

Foundation.

Appendix A. Supplementary data

Supplementary data to this article can be found online at <https://doi.org/10.1016/j.jns.2021.117548>.

References

- [1] W.C. LaFrance Jr., G.A. Baker, R. Duncan, L.H. Goldstein, M. Reuber, Minimum requirements for the diagnosis of psychogenic nonepileptic seizures: a staged approach: a report from the international league against epilepsy nonepileptic seizures task force, *Epilepsia* 54 (2013) 2005–2018.
- [2] A.A. Asadi-Pooya, F. Brigo, B. Mildon, T.R. Nicholson, Terminology for psychogenic nonepileptic seizures: making the case for “functional seizures”, *Epilepsy Behav.* 104 (2020) 106895.
- [3] W.T. Kerr, J.M. Stern, We need a functioning name for PNES: consider dissociative seizures, *Epilepsy Behav.* 105 (2020) 107002.
- [4] M. Beghi, F. Peroni, C.M. Cornaggia, Reply to: we need a functioning name for PNES: considering dissociative seizures, *Epilepsy Behav.* 109 (2020) 107084.
- [5] W.T. Kerr, E.A. Janio, J.M. Le, J.M. Hori, A.B. Patel, N.L. Gallardo, J. Baurijian, A. M. Chau, S.R. D'Ambrosio, A.Y. Cho, J. Engel Jr., M.S. Cohen, J.M. Stern, Diagnostic delay in psychogenic seizures and the association with anti-seizure medication trials, *Seizure* 40 (2016) 123–126.
- [6] R. Alessi, K.D. Valente, Psychogenic nonepileptic seizures: should we use response to AEDS as a red flag for the diagnosis? *Seizure* 23 (2014) 906–908.
- [7] A.A. Asadi-Pooya, M. Homayoun, Structural brain abnormalities in patients with psychogenic nonepileptic seizures, *Neurol. Sci.* 41 (2020) 555–559.
- [8] B. Mesraoua, M. Koepp, B. Schuknecht, D. Deleu, H.J. Al Hail, G. Melikyan, L. Elsheikh, A.A. Asadi-Pooya, Unexpected brain imaging findings in patients with seizures, *Epilepsy Behav.* 111 (2020) 107241.
- [9] R.D. Bolen, E.H. Koontz, P.B. Pritchard 3rd., Prevalence and distribution of MRI abnormalities in patients with psychogenic nonepileptic events, *Epilepsy Behav.* 59 (2016) 73–76.
- [10] M. Reuber, G. Fernandez, C. Helmstaedter, A. Qurishi, C.E. Elger, Evidence of brain abnormality in patients with psychogenic nonepileptic seizures, *Epilepsy Behav.* 3 (2002) 249–254.
- [11] R. Aghoram, P.P. Nair, Imaging in psychogenic nonepileptic seizures: An observational study, *Indian J. Psychol. Med.* 41 (2019) 494–496.
- [12] Y. Patidar, M. Gupta, G.A. Khwaja, D. Chowdhury, A. Batra, A. Dasgupta, Clinical profile of psychogenic non-epileptic seizures in adults: a study of 63 cases, *Ann. Indian Acad. Neurol.* 16 (2013) 157–162.
- [13] S.G. Jones, T.J. OB, S.J. Adams, R. Mocellin, C.J. Kilpatrick, R. Yerra, J.H. Lloyd, D. Velakoulis, Clinical characteristics and outcome in patients with psychogenic nonepileptic seizures, *Psychosom. Med.* 72 (2010) 487–497.
- [14] O. Devinsky, S. Mesad, K. Alper, Nondominant hemisphere lesions and conversion nonepileptic seizures, *J. Neuropsychiatr. Clin. Neurosci.* 13 (2001) 367–373.
- [15] Z. Morris, W.N. Whiteley, W.T. Longstreth Jr., F. Weber, Y.C. Lee, Y. Tsushima, H. Alphas, S.C. Ladd, C. Warlow, J.M. Wardlaw, Salman R. Al-Shahi, Incidental findings on brain magnetic resonance imaging: systematic review and meta-analysis, *BMJ* 339 (2009) b3016.
- [16] G.I. Ogbale, A.O. Adeleke, M.O. Owolabi, R.B. Olatunji, B.P. Yusuf, Incidental cranial CT findings in head injury patients in a Nigerian tertiary hospital, *J. Emerg. Trauma. Shock* 8 (2015) 77–82.
- [17] G.L. Katzman, A.P. Dagher, N.J. Patronas, Incidental findings on brain magnetic resonance imaging from 1000 asymptomatic volunteers, *JAMA* 282 (1999) 36–39.
- [18] M.W. Vernooij, M.A. Ikram, H.L. Tanghe, A.J. Vincent, A. Hofman, G.P. Krestin, W.J. Niessen, M.M. Breteler, A. van der Lugt, Incidental findings on brain MRI in the general population, *N. Engl. J. Med.* 357 (2007) 1821–1828.
- [19] K.R. Moore, C.E. Swallow, J.S. Tsuruda, Incidental detection of hippocampal sclerosis on MR images: is it significant? *AJNR Am. J. Neuroradiol.* 20 (1999) 1609–1612.
- [20] K. Menzler, J. Iwinska-Zelder, K. Shiratori, R.K. Jaeger, W.H. Oertel, H.M. Hamer, F. Rosenow, S. Knake, Evaluation of MRI criteria (1.5 T) for the diagnosis of hippocampal sclerosis in healthy subjects, *Epilepsy Res.* 89 (2010) 349–354.
- [21] R. Koncz, A. Mohan, L. Dawes, A. Thalamuthu, M. Wright, D. Ames, T. Lee, J. Trollor, W. Wen, P. Sachdev, Incidental findings on cerebral MRI in twins: the older Australian twins study, *Brain Imag. Behav.* 12 (2018) 860–869.
- [22] A.K. Haberg, T.A. Hammer, K.A. Kvistad, J. Rydland, T.B. Muller, L. Eikenes, M. Garseth, L.J. Stovner, Incidental intracranial findings and their clinical impact: the HUNT MRI study in a general population of 1006 participants between 50–66 years, *PLoS One* 11 (2016), e0151080.
- [23] V. Koppelmans, S.B. Schagen, M.M. Poels, W. Boogerd, C. Seynaeve, A. van der Lugt, M.M. Breteler, Incidental findings on brain magnetic resonance imaging in long-term survivors of breast cancer treated with adjuvant chemotherapy, *Eur. J. Cancer* 47 (2011) 2531–2536.
- [24] A. Cieszanowski, E. Maj, P. Kulisiewicz, I.P. Grudzinski, K. Jakoniuk-Glodala, I. Chlipala-Nitek, B. Kaczynski, O. Rowinski, Non-contrast-enhanced whole-body magnetic resonance imaging in the general population: the incidence of abnormal findings in patients 50 years old and younger compared to older subjects, *PLoS One* 9 (2014), e107840.
- [25] G.P. Winston, C. Micallef, B.E. Kendell, P.A. Bartlett, E.J. Williams, J.L. Burdett, J. S. Duncan, The value of repeat neuroimaging for epilepsy at a tertiary referral Centre: 16 years of experience, *Epilepsy Res.* 105 (2013) 349–355.
- [26] M.C. McBride, K.S. Bronstein, B. Bennett, G. Erba, W. Pilcher, M.J. Berg, Failure of standard magnetic resonance imaging in patients with refractory temporal lobe epilepsy, *Arch. Neurol.* 55 (1998) 346–348.
- [27] J. Von Oertzen, H. Urbach, S. Jungbluth, M. Kurthen, M. Reuber, G. Fernandez, C. E. Elger, Standard magnetic resonance imaging is inadequate for patients with refractory focal epilepsy, *J. Neurol. Neurosurg. Psychiatry* 73 (2002) 643–647.
- [28] S.J. van der Kruis, N.M. Bodde, M.J. Vaessen, R.H. Lazeron, K. Vonck, P. Boon, P. A. Hofman, W.H. Backes, A.P. Aldenkamp, J.F. Jansen, Functional connectivity of dissociation in patients with psychogenic non-epileptic seizures, *J. Neurol. Neurosurg. Psychiatry* 83 (2012) 239–247.
- [29] A. Labate, A. Cerasa, M. Mula, L. Mumoli, M.C. Gioia, U. Aguglia, A. Quattrone, A. Gambardella, Neuroanatomic correlates of psychogenic nonepileptic seizures: a cortical thickness and VBM study, *Epilepsia* 53 (2012) 377–385.
- [30] A.J. Ristic, M. Dakovic, M. Kerr, M. Kovacevic, A. Parojcic, D. Sokic, Cortical thickness, surface area and folding in patients with psychogenic nonepileptic seizures, *Epilepsy Res.* 112 (2015) 84–91.
- [31] S. Lee, J.B. Allendorfer, T.E. Gaston, J.C. Griffis, K.A. Hernando, R.C. Knowlton, J. P. Szaflarski, L.W. Ver Hoef, White matter diffusion abnormalities in patients with psychogenic non-epileptic seizures, *Brain Res.* 2015 (2016) 169–176.
- [32] R. Li, Y. Li, D. An, Q. Gong, D. Zhou, H. Chen, Altered regional activity and inter-regional functional connectivity in psychogenic non-epileptic seizures, *Sci. Rep.* 5 (2015) 11635.
- [33] S. Amiri, M.M. Mirbagheri, A.A. Asadi-Pooya, F. Badragheh, H. Ajam Zibadi, M. Arbabi, Brain functional connectivity in individuals with psychogenic nonepileptic seizures (PNES): An application of graph theory, *Epilepsy Behav.* 114 (2021) 107565.
- [34] K.A. Hernando, J.P. Szaflarski, L.W. Ver Hoef, S. Lee, J.B. Allendorfer, Uncinate fasciculus connectivity in patients with psychogenic nonepileptic seizures: a preliminary diffusion tensor tractography study, *Epilepsy Behav.* 45 (2015) 68–73.
- [35] J.R. Ding, D. An, W. Liao, J. Li, G.R. Wu, Q. Xu, Z. Long, Q. Gong, D. Zhou, O. Sporns, H. Chen, Altered functional and structural connectivity networks in psychogenic non-epileptic seizures, *PLoS One* 8 (2013), e63850.
- [36] J. Ding, D. An, W. Liao, G. Wu, Q. Xu, D. Zhou, H. Chen, Abnormal functional connectivity density in psychogenic non-epileptic seizures, *Epilepsy Res.* 108 (2014) 1184–1194.
- [37] S.J. van der Kruis, S.R. Jagannathan, N.M. Bodde, R.M. Besseling, R.H. Lazeron, K.E. Vonck, P.A. Boon, P.J. Cluitmans, P.A. Hofman, W.H. Backes, A. P. Aldenkamp, J.F. Jansen, Resting-state networks and dissociation in psychogenic non-epileptic seizures, *J. Psychiatr. Res.* 54 (2014) 126–133.
- [38] W.T. Kerr, S.T. Nguyen, A.Y. Cho, E.P. Lau, D.H. Silverman, P.K. Douglas, N. M. Reddy, A. Anderson, J. Bramen, N. Salamon, J.M. Stern, M.S. Cohen, Computer-aided diagnosis and localization of lateralized temporal lobe epilepsy using Interictal FDG-PET, *Front. Neurol.* 4 (2013) 31.
- [39] M. Arthuis, J.A. Micoulaud-Franchi, F. Bartolomei, A. McGonigal, E. Guedj, Resting cortical PET metabolic changes in psychogenic non-epileptic seizures (PNES), *J. Neurol. Neurosurg. Psychiatry* 86 (2015) 1106–1112.
- [40] H. Tatekawa, W.T. Kerr, I. Savic, J. Engel Jr., N. Salamon, Reduced left amygdala volume in patients with dissociative seizures (psychogenic nonepileptic seizures), *Seizure* 75 (2020) 43–48.
- [41] S. Pick, L.H. Goldstein, D.L. Perez, T.R. Nicholson, Emotional processing in functional neurological disorder: a review, biopsychosocial model and research agenda, *J. Neurol. Neurosurg. Psychiatry* 90 (2019) 704–711.
- [42] A.A. Asadi-Pooya, Neurobiological origin of psychogenic nonepileptic seizures: a review of imaging studies, *Epilepsy Behav.* 52 (2015) 256–259.
- [43] M. McSweeney, M. Reuber, L. Levita, Neuroimaging studies in patients with psychogenic non-epileptic seizures: a systematic meta-review, *Neuroimage Clin.* 16 (2017) 210–221.
- [44] W.T. Kerr, A. Anderson, E.P. Lau, A.Y. Cho, H. Xia, J. Bramen, P.K. Douglas, E. S. Braun, J.M. Stern, M.S. Cohen, Automated diagnosis of epilepsy using EEG power spectrum, *Epilepsia* 53 (2012) e189–e192.
- [45] W.T. Kerr, E.A. Janio, A.M. Chau, C.T. Braesch, J.M. Le, J.M. Hori, A.B. Patel, N. L. Gallardo, C.H. Allas, A.H. Karimi, I. Dubey, S.S. Sreenivasan, J. Baurijian, E. S. Hwang, E.C. Davis, S.R. D'Ambrosio, A. Al Banna, R. Mazumder, T. Wu, Z. A. DeCant, M.G. Gibbs, E. Chang, X. Zhang, A.Y. Cho, N.J. Beimer, J. Engel Jr., M. S. Cohen, J.M. Stern, Objective score from initial interview identifies patients with probable dissociative seizures, *Epilepsy Behav.* 2020 (2020) 107525.
- [46] R.S. Fisher, J.H. Cross, J.A. French, N. Higurashi, E. Hirsch, F.E. Jansen, L. Lagae, S.L. Moshe, J. Peltola, E. Roulet Perez, I.E. Scheffer, S.M. Zuberi, Operational classification of seizure types by the international league against epilepsy: position paper of the ILAE Commission for Classification and Terminology, *Epilepsia* 58 (2017) 522–530.
- [47] M.K. Sidhu, J.S. Duncan, J.W. Sander, Neuroimaging in epilepsy, *Curr. Opin. Neurol.* 31 (2018) 371–378.
- [48] A. Bernasconi, F. Cendes, W.H. Theodore, R.S. Gill, M.J. Koepp, R.E. Hogan, G. D. Jackson, P. Federico, A. Labate, A.E. Vaudano, I. Blumcke, P. Ryvlin, N. Bernasconi, Recommendations for the use of structural magnetic resonance imaging in the care of patients with epilepsy: a consensus report from the international league against epilepsy neuroimaging Task Force, *Epilepsia* 60 (2019) 1054–1068.
- [49] R. Dhamija, B.D. Moseley, G.D. Cascino, E.C. Wirrell, A population-based study of long-term outcome of epilepsy in childhood with a focal or hemispheric lesion on neuroimaging, *Epilepsia* 52 (2011) 1522–1526.

- [50] M.A. Dirik, B. Sanlidag, Magnetic resonance imaging findings in newly diagnosed epileptic children, *Pak. J. Med. Sci.* 34 (2018) 424–428.
- [51] E. Aronica, A. Muhlebaier, Neuropathology of epilepsy, *Handb. Clin. Neurol.* 145 (2017) 193–216.
- [52] R. Guerrini, F. Sicca, L. Parmeggiani, Epilepsy and malformations of the cerebral cortex, *Epileptic Disord* 5 (Suppl. 2) (2003) S9–26.
- [53] I.M. Najm, H.B. Sarnat, I. Blumcke, Review: the international consensus classification of focal cortical dysplasia - a critical update 2018, *Neuropathol. Appl. Neurobiol.* 44 (2018) 18–31.
- [54] R.J. Slegers, I. Blumcke, Low-grade developmental and epilepsy associated brain tumors: a critical update 2020, *Acta Neuropathol. Commun.* 8 (2020) 27.
- [55] H.J. Faulkner, D.R. Sandeman, S. Love, M.J. Likeman, D.A. Nunez, S.D. Lhatoo, Epilepsy surgery for refractory epilepsy due to encephalocele: a case report and review of the literature, *Epileptic Disord* 12 (2010) 160–166.
- [56] I. Ollivier, H. Cebula, J. Todeschi, M.D.N. Santin, F. Severac, M.P. Valenti-Hirsch, E. Hirsch, F. Proust, Predictive factors of epilepsy in arteriovenous malformation, *Neurochirurgie* 66 (2020) 144–149.
- [57] A. Labate, A. Gambardella, U. Aguglia, F. Condino, P. Ventura, P. Lanza, A. Quattrone, Temporal lobe abnormalities on brain MRI in healthy volunteers: a prospective case-control study, *Neurology* 74 (2010) 553–557.
- [58] J.L. Leach, R. Awwad, H.M. Greiner, J.J. Vannest, L. Miles, F.T. Mangano, Mesial temporal lobe morphology in intractable pediatric epilepsy: so-called hippocampal malrotation, associated findings, and relevance to presurgical assessment, *J. Neurosurg. Pediatr.* 17 (2016) 683–693.
- [59] M. Maeda, H. Tsukahara, H. Terada, S. Nakaji, H. Nakamura, H. Oba, O. Igarashi, K. Arasaki, T. Machida, K. Takeda, J.I. Takanashi, Reversible splenial lesion with restricted diffusion in a wide spectrum of diseases and conditions, *J. Neuroradiol.* 33 (2006) 229–236.
- [60] N.S. Yeghiazaryan, G. Morana, A. Rossi, P. Veggiotti, G. Savino, L. Giordano, C. Minetti, P. Striano, Temporal lobe epilepsy and hippocampal malrotation: is there a causal association? *Epilepsy Behav.* 18 (2010) 502–504.
- [61] A.A. Cohen-Gadol, J.W. Britton, C.R. Jack Jr., J.A. Friedman, W.R. Marsh, Transient postictal magnetic resonance imaging abnormality of the corpus callosum in a patient with epilepsy. Case report and review of the literature, *J. Neurosurg.* 97 (2002) 714–717.
- [62] N.Y. Lorenzo, J.E. Parisi, G.D. Cascino, C.R. Jack Jr., W.R. Marsh, K.A. Hirschorn, Intractable frontal lobe epilepsy: pathological and MRI features, *Epilepsy Res.* 20 (1995) 171–178.
- [63] M. Giulioni, G. Marucci, M. Martinoni, A.F. Marliani, F. Toni, F. Bartiromo, L. Volpi, P. Riguzzi, F. Bisulli, I. Naldi, R. Michelucci, A. Baruzzi, P. Tinuper, G. Rubboli, Epilepsy associated tumors: review article, *World J. Clin. Cases.* 2 (2014) 623–641.
- [64] A. Mehta, B.E. Zusman, R. Choxi, L.A. Shutter, A. Yassin, A. Antony, P. D. Thirumala, Seizures after intracerebral hemorrhage: incidence, risk factors, and impact on mortality and morbidity, *World Neurosurg.* 112 (2018) e385–e392.
- [65] F. Angeleri, J. Majkowski, G. Cacchio, A. Sobieszek, S. D'Acunto, R. Gesuita, A. Bachleda, G. Polonara, L. Krollicki, M. Signorino, U. Salvolini, Posttraumatic epilepsy risk factors: one-year prospective study after head injury, *Epilepsia* 40 (1999) 1222–1230.
- [66] F. Rosenow, M.A. Alonso-Vanegas, C. Baumgartner, I. Blumcke, M. Carreno, E. R. Gizewski, H.M. Hamer, S. Knake, P. Kahane, H.O. Luders, G.W. Mathern, K. Menzler, J. Miller, T. Otsuki, C. Ozkara, A. Pitkanen, S.N. Roper, A. C. Sakamoto, U. Sure, M.C. Walker, B.J. Steinhoff, CoTSotl Surgical Task Force, Cavernoma-related epilepsy: review and recommendations for management-report of the Surgical Task Force of the ILAE commission on therapeutic strategies, *Epilepsia* 54 (2013) 2025–2035.
- [67] C.F. Bladin, A.V. Alexandrov, A. Bellavance, N. Bornstein, B. Chambers, R. Cote, L. Lebrun, A. Pirisi, J.W. Norris, Seizures after stroke: a prospective multicenter study, *Arch. Neurol.* 57 (2000) 1617–1622.
- [68] R.A. Bronen, G. Cheung, MRI of the temporal lobe: normal variations, with special reference toward epilepsy, *Magn. Reson. Imaging* 9 (1991) 501–507.
- [69] T.C. Chen, Y.Y. Chen, P.Y. Cheng, C.H. Lai, The incidence rate of post-stroke epilepsy: a 5-year follow-up study in Taiwan, *Epilepsy Res.* 102 (2012) 188–194.
- [70] E. Ferlazzo, S. Gasparini, E. Beghi, C. Sueri, E. Russo, A. Leo, A. Labate, A. Gambardella, V. Belcastro, P. Striano, M. Paciaroni, L.R. Pisani, U. Aguglia, Epilepsy Study Group of the Italian Neurological S, Epilepsy in cerebrovascular diseases: review of experimental and clinical data with meta-analysis of risk factors, *Epilepsia* 57 (2016) 1205–1214.
- [71] J.W. Lazor, J.M. Stein, J.E. Schmitt, K.A. Davis, S.A. Nabavizadeh, Epilepsy lesion localization is not predicted by developmental venous anomaly location or its FDG-PET metabolic activity, *J. Neuroimaging* 30 (2020) 544–550.
- [72] P. Gelisse, D. Corda, C. Raybaud, C. Dravet, M. Bureau, P. Genton, Abnormal neuroimaging in patients with benign epilepsy with centrotemporal spikes, *Epilepsia* 44 (2003) 372–378.
- [73] W. Reith, Differential diagnosis of intracerebral and spinal cysts, *Radiologe* 58 (2018) 111–112.
- [74] J.A. Hidalgo, C.A. Tork, M. Varacallo, Arnold Chiari Malformation, in: StatPearls. Treasure Island (FL), 2021.
- [75] J.Y. Choi, D.W. Rha, E.S. Park, The effects of the severity of periventricular leukomalacia on the neuropsychological outcomes of preterm children, *J. Child Neurol.* 31 (2016) 603–612.
- [76] P. Sparks, T. Lawrence, S. Hinze, Neuroimaging in the diagnosis of chronic traumatic encephalopathy: a systematic review, *Clin. J. Sport Med.* 30 (Suppl. 1) (2020) S1–S10.
- [77] J.A. Bertelson, B. Ajtai, Neuroimaging of dementia, *Neurol. Clin.* 32 (2014) 59–93.
- [78] Z. Mahamud, J. Burman, J. Zelano, Risk of epilepsy after a single seizure in multiple sclerosis, *Eur. J. Neurol.* 25 (2018) 854–860.
- [79] G. Rubin, Z.H. Rappaport, Epilepsy in chronic subdural haematoma, *Acta Neurochir.* 123 (1993) 39–42.
- [80] M.J. Thurtell, Idiopathic intracranial hypertension, *Continuum (Minneapolis)* 25 (2019) 1289–1309.
- [81] A. Brenner, D.A. Kozyrev, S.I. Shiran, E. Azoulay, L.T. Pratt, R. Precel, L. Ben-Sira, O. Eyal, S. Constantini, J. Roth, Y. Leventhal, Incidental findings on brain magnetic resonance imaging (MRI) in pediatric endocrine patients, *Endocr. Pract.* 26 (2020) 1105–1114.
- [82] E.J. Nevins, K. Das, M. Bhojak, R.S. Pinto, M.N. Hoque, M.D. Jenkinson, E. Chavredakis, Incidental pineal cysts: is surveillance necessary? *World Neurosurg.* 90 (2016) 96–102.
- [83] F. D'Antonio, A. Khalil, C. Garel, G. Pilu, G. Rizzo, T. Lerman-Sagie, A. Bhide, B. Thilaganathan, L. Manzoli, A.T. Papageorgiou, Systematic review and meta-analysis of isolated posterior fossa malformations on prenatal ultrasound imaging (part 1): nomenclature, diagnostic accuracy and associated anomalies, *Ultrasound Obstet. Gynecol.* 47 (2016) 690–697.
- [84] E. Boltshauser, F. Martin, S. Altermatt, Outcome in children with space-occupying posterior fossa arachnoid cysts, *Neuropediatrics* 33 (2002) 118–121.
- [85] I. Unterberger, R. Bauer, G. Walser, G. Bauer, Corpus callosum and epilepsies, *Seizure* 37 (2016) 55–60.
- [86] B.V. Manyam, What is and what is not 'Fahr's' disease, *Parkinsonism Relat. Disord.* 11 (2005) 73–80.
- [87] K.K. Lee, N. Salamon, [18F] Fluorodeoxyglucose-positron-emission tomography and mr imaging coregistration for presurgical evaluation of medically refractory epilepsy, *AJNR Am. J. Neuroradiol.* 30 (2009) 1811–1816.
- [88] N. Salamon, J. Kung, S.J. Shaw, J. Koo, S. Koh, J.Y. Wu, J.T. Lerner, R. Sankar, W. D. Shields, J. Engel Jr., I. Fried, H. Miyata, W.H. Yong, H.V. Vinters, G. W. Mathern, FDG-PET/MRI coregistration improves detection of cortical dysplasia in patients with epilepsy, *Neurology* 71 (2008) 1594–1601.
- [89] E. Lotan, K.P. Friedman, T. Davidson, T.M. Shepherd, Brain 18F-FDG-PET: utility in the diagnosis of dementia and epilepsy, *Isr. Med. Assoc. J.* 22 (2020) 178–184.
- [90] Z. Jaisani, R.S. Miletich, M. Ramanathan, A.L. Weinstock, Clinical FDG-PET findings in patients with temporal lobe epilepsy: concordance with EEG and MRI, *J. Neuroimaging* 30 (2020) 119–125.
- [91] F. Cendes, W.H. Theodore, B.H. Brinkmann, V. Sulc, G.D. Cascino, Neuroimaging of epilepsy, *Handb. Clin. Neurol.* 136 (2016) 985–1014.
- [92] W.T. Kerr, X. Zhang, C.E. Hill, E.A. Janio, A.M. Chau, C.T. Braesch, J.M. Le, J. M. Hori, A.B. Patel, C.H. Allas, A.H. Karimi, I. Dubey, S.S. Sreenivasan, N. L. Gallardo, J. Bauirjan, E.S. Hwang, E.C. Davis, S.R. D'Ambrosio, M. Al Banna, A. Y. Cho, S.R. Dewar, J. Engel Jr., J.D. Feusner, J.M. Stern, Factors associated with delay to video-EEG in dissociative seizures, *Seizure* 86 (2021) 155–160.
- [93] J.N. Itri, R.R. Tappouni, R.O. McEachern, A.J. Pesch, S.H. Patel, Fundamentals of diagnostic error in imaging, *Radiographics* 38 (2018) 1845–1865.
- [94] A.C. Coan, B. Kubota, F.P. Bergo, B.M. Campos, F. Cendes, 3T MRI quantification of hippocampal volume and signal in mesial temporal lobe epilepsy improves detection of hippocampal sclerosis, *AJNR Am. J. Neuroradiol.* 35 (2014) 77–83.
- [95] J.M. Mettenberg, B.F. Branstetter, C.A. Wiley, P. Lee, R.M. Richardson, Improved detection of subtle mesial temporal sclerosis: validation of a commercially available software for automated segmentation of hippocampal volume, *AJNR Am. J. Neuroradiol.* 40 (2019) 440–445.
- [96] S.R. Sheikh, M.W. Kattan, M. Steinmetz, M.E. Singer, B.L. Udeh, L. Jehi, Cost-effectiveness of surgery for drug-resistant temporal lobe epilepsy in the US, *Neurology* 95 (2020) e1404–e1416.
- [97] J.N. Gelinas, A.W. Battison, S. Smith, M.B. Connolly, P. Steinbok, Electrooculography and seizure outcomes in children with lesional epilepsy, *Childs Nerv. Syst.* 27 (2011) 381–390.
- [98] I.G. Dorward, J.B. Titus, D.D. Limbrick, J.M. Johnston, M.E. Bertrand, M. D. Smyth, Extratemporal, nonlesional epilepsy in children: postsurgical clinical and neurocognitive outcomes, *J. Neurosurg. Pediatr.* 7 (2011) 179–188.
- [99] M.L. Bell, S. Rao, E.L. So, M. Trenerry, N. Kazemi, S.M. Stead, G. Cascino, R. Marsh, F.B. Meyer, R.E. Watson, C. Giannini, G.A. Worrell, Epilepsy surgery outcomes in temporal lobe epilepsy with a normal MRI, *Epilepsia* 50 (2009) 2053–2060.
- [100] A.A. Cohen-Gadol, B.G. Wilhelm, F. Collignon, J.B. White, J.W. Britton, D. M. Cambier, T.J. Christianson, W.R. Marsh, F.B. Meyer, G.D. Cascino, Long-term outcome of epilepsy surgery among 399 patients with nonlesional seizure foci including mesial temporal lobe sclerosis, *J. Neurosurg.* 104 (2006) 513–524.
- [101] D.L. Perez, N. Marin, A. Barsky, V. Costumero-Ramos, S.J. Makaretz, S.S. Young, J. Sepulcre, W.C. LaFrance Jr., M.S. Keshavan, B.C. Dickerson, Cingulo-insular structural alterations associated with psychogenic symptoms, childhood abuse and PTSD in functional neurological disorders, *J. Neurol. Neurosurg. Psychiatry* 88 (2017) 491–497.
- [102] J.B. Pereira, L. Cavallin, G. Spulber, C. Aguilar, P. Mecocci, B. Vellas, M. Tsolaki, I. Kloszewska, H. Soininen, C. Spenger, D. Aarsland, S. Lovestone, A. Simmons, L. O. Wahlund, E. Westman, AddNeuroMed c, for the Alzheimer's disease neuroimaging I. influence of age, disease onset and ApoE4 on visual medial temporal lobe atrophy cut-offs, *J. Intern. Med.* 275 (2014) 317–330.
- [103] B. Johnstone, D. Velakoulis, C.Y. Yuan, A. Ang, C. Steward, P. Desmond, T. J. O'Brien, Early childhood trauma and hippocampal volumes in patients with epileptic and psychogenic seizures, *Epilepsy Behav.* 64 (2016) 180–185.
- [104] H.P. Blumberg, J. Kaufman, A. Martin, R. Whiteman, J.H. Zhang, J.C. Gore, D. S. Charney, J.H. Krystal, B.S. Peterson, Amygdala and hippocampal volumes in

- adolescents and adults with bipolar disorder, *Arch. Gen. Psychiatry* 60 (2003) 1201–1208.
- [105] V. Dhikav, K.S. Anand, Is hippocampal atrophy a future drug target? *Med. Hypotheses* 68 (2007) 1300–1306.
- [106] L.L. Altshuler, O.A. Abulseoud, L. Foland-Ross, G. Bartzokis, S. Chang, J. Mintz, G. Hellemann, H.V. Vinters, Amygdala astrocyte reduction in subjects with major depressive disorder but not bipolar disorder, *Bipolar Disord.* 12 (2010) 541–549.
- [107] J.E. Hardee, J.C. Thompson, A. Puce, The left amygdala knows fear: laterality in the amygdala response to fearful eyes, *Soc. Cogn. Affect. Neurosci.* 3 (2008) 47–54.
- [108] W.T. Kerr, E.A. Janio, C.T. Braesch, J.M. Le, J.M. Hori, A.B. Patel, N.L. Gallardo, J. Baurirjan, S.R. D'Ambrosio, A.M. Chau, E.S. Hwang, E.C. Davis, A. Buchard, D. Torres-Barba, M. Al Banna, S.E. Barritt, A.Y. Cho, J. Engel Jr., M.S. Cohen, J. M. Stern, Identifying psychogenic seizures through comorbidities and medication history, *Epilepsia* 58 (2017) 1852–1860.
- [109] W.T. Kerr, E.A. Janio, C.T. Braesch, J.M. Le, J.M. Hori, A.B. Patel, N.L. Gallardo, J. Baurirjan, A.M. Chau, E.S. Hwang, E.C. Davis, A. Buchard, D. Torres-Barba, S. D'Ambrosio, M. Al Banna, A.Y. Cho, J. Engel Jr., M.S. Cohen, J.M. Stern, An objective score to identify psychogenic seizures based on age of onset and history, *Epilepsy Behav.* 80 (2018) 75–83.
- [110] M.H. Bagheri, R. Jalli, A. Hoseyni Moghadam, New MRI finding in migraines: mesial temporal sclerosis, *J. Biomed. Phys. Eng.* 10 (2020) 459–466.
- [111] C. Arnold Fiebelkorn, P. Vemuri, A.A. Rabinstein, M.M. Mielke, S.A. Przybelski, K. Kantarci, D.T. Jones, R.D. Brown Jr., D.S. Knopman, R.C. Petersen, C. R. Jack Jr., J. Graff-Radford, Frequency of acute and subacute infarcts in a population-based study, *Mayo Clin. Proc.* 93 (2018) 300–306.
- [112] J.L. Fisher, J.A. Schwartzbaum, M. Wrensch, J.L. Wiemels, Epidemiology of brain tumors, *Neurol. Clin.* 25 (2007) 867–890 (vii).
- [113] N.J. Janocko, J. Jing, Z. Fan, D.L. Teagarden, H.K. Villarreal, M.L. Morton, O. Groover, D.W. Loring, D.L. Drane, M.B. Westover, I. Karakis, DDESVSFS: a simple, rapid and comprehensive screening tool for the differential diagnosis of epileptic seizures VS functional seizures, *Epilepsy Res.* 171 (2021) 106563.
- [114] M. Reuber, G. Fernandez, J. Bauer, D.D. Singh, C.E. Elger, Interictal EEG abnormalities in patients with psychogenic nonepileptic seizures, *Epilepsia* 43 (2002) 1013–1020.
- [115] W.T. Kerr, X. Zhang, C.E. Hill, E.A. Janio, A.M. Chau, C.T. Braesch, J.M. Le, J. M. Hori, A.B. Patel, C.H. Allas, A.H. Karimi, I. Dubey, S.S. Sreenivasan, N. L. Gallardo, J. Baurirjan, E.S. Hwang, E.C. Davis, S.R. D'Ambrosio, M. Al Banna, A. Y. Cho, S.R. Dewar, J. Engel Jr., J.D. Feusner, J.M. Stern, Epilepsy, dissociative seizures, and mixed: associations with time to video-EEG, *Seizure* 86 (2021) 116–122.
- [116] G.C. Beltramini, F. Cendes, C.L. Yasuda, The effects of antiepileptic drugs on cognitive functional magnetic resonance imaging, *Quant. Imag. Med. Surg.* 5 (2015) 238–246.
- [117] F. Cazala, R. Suchting, C.P. Zeni, I.E. Bauer, B. Mwangi, M.J. Wu, I.C. Passos, D. E. Spiker, G.B. Zunta-Soares, J.C. Soares, Effects of valproate on brain volumes in pediatric bipolar disorder: a preliminary study, *Psychiatry Res. Neuroimaging* 278 (2018) 65–68.
- [118] L. Li, E. Ji, X. Han, F. Tang, Y. Bai, D. Peng, Y. Fang, S. Zhang, Z. Zhang, H. Yang, Cortical thickness and subcortical volumes alterations in euthymic bipolar I patients treated with different mood stabilizers, *Brain Imag. Behav.* 13 (2019) 1255–1264.
- [119] C. Germana, M.J. Kempton, A. Sarnicola, T. Christodoulou, M. Haldane, M. Hadjulis, P. Girardi, R. Tatarelli, S. Frangou, The effects of lithium and anticonvulsants on brain structure in bipolar disorder, *Acta Psychiatr. Scand.* 122 (2010) 481–487.
- [120] D. Wei, M. Garlinghouse, W. Li, N. Swingle, K.K. Samson, O. Taraschenko, Utilization of brain imaging in evaluating patients with psychogenic nonepileptic spells, *Epilepsy Behav.* 85 (2018) 177–182.
- [121] U. Seneviratne, Z.M. Low, Z.X. Low, A. Hehir, S. Paramaswaran, M. Foong, H. Ma, T.G. Phan, Medical health care utilization cost of patients presenting with psychogenic nonepileptic seizures, *Epilepsia* 60 (2019) 349–357.