



POSTER PRESENTATION

Open Access

Classification of human coronary atherosclerotic plaques with T1, T2 and Ultrashort TE MRI

Mihaly Karolyi^{2*}, Harald Seifarth², Gary Liew², Christopher Schlett², Pal Maurovich-Horvat², Guangping Dai¹, Shuning Huang¹, Craig J Goergen¹, Udo Hoffmann², David E Sosnovik^{1,2}

From 15th Annual SCMR Scientific Sessions
Orlando, FL, USA. 2-5 February 2012

Summary

Multicontrast MRI with T1, T2 and Ultrashort TE (UTE) sequences is used to image atherosclerotic plaque in human coronary arteries. MRI classification of the plaques is compared with their histological classification and found to correlate extremely well. The addition of UTE MRI adds significant value to the imaging of human coronary artery plaque by MRI.

Background

The differentiation of atherosclerotic plaque components in the carotid arteries with MRI has been successfully demonstrated. The detection of plaque calcification by MRI, however has been challenging. In addition, few studies have evaluated the ability of MRI to characterize atherosclerotic plaques in human coronary arteries (1). Here we use a combination of T1, T2 and ultrashort TE (UTE) MRI to evaluate atherosclerotic plaques in fixed post-mortem human coronary arteries. We hypothesized that the addition of UTE to T1 and T2 weighted MRI would allow both calcified and lipid rich plaques to be accurately detected and distinguished from one another.

Methods

Twenty eight plaques from human donor hearts with proven coronary artery disease were imaged on 9.4T horizontal bore MRI scanner (Biospec, Bruker). The specimens were imaged with a T1W 3D FLASH sequence (250 μ m isotropic resolution, TR/TE 30/2.5ms), a T2W Rare sequence (slice thickness 0.4 mm, in plane resolution 0.156mm, TR/TE 3000/40ms), and an UTE sequence (200-300 μ m resolution, TE of 20 μ s). Plaques showing selective hypointensity on T2W MRI were

classified as lipid rich. Areas of hypointensity on the T1W images but not the UTE images were classified as calcified. After MRI, the plaques were sectioned for histological characterization with a pentachrome stain, which was used as the gold standard readout. The histological sections were digitized and co-registered with the MR images for analysis.

Results

Plaque classification by MRI was performed by 4 readers who were blinded to the histological plaque classification. The sensitivity and specificity of MRI for the detection of plaque calcification were 100.0% and 90.0% respectively. The sensitivity and specificity of MRI for the detection of lipid rich necrotic cores were 90.0%, 75.0%, respectively. Good inter-observer agreement was found for plaque classification by MRI ($\kappa = 0.7829$, $p < 0.0001$). More importantly, MRI categorization of coronary artery plaques agreed well with the histological classification (weighted $\kappa = 0.6945$, $p < 0.0001$). An example of a lipid-rich necrotic plaque with calcification is shown in Figure 1. A fibrocalcific coronary artery plaque is shown in Figure 2.

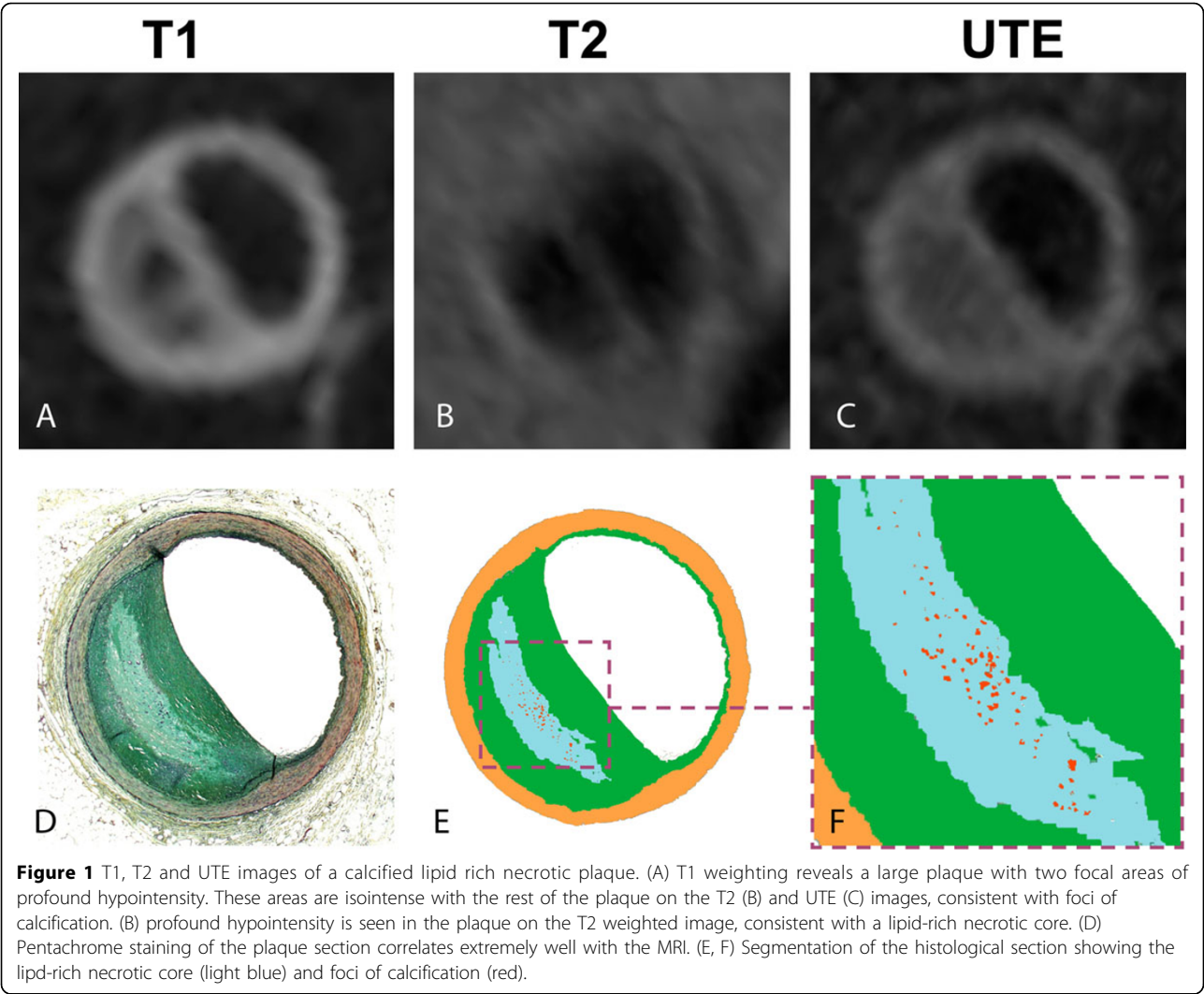
Conclusions

MRI with T1, T2 and UTE contrast is able to accurately classify atherosclerotic plaques in human coronary arteries. This underscores the need to develop techniques to image the coronary artery wall in patients in vivo.

Funding

R01 HL093038 and NCRR P41RR14075

²Massachusetts General Hospital, Harvard Medical School, Boston, MA, USA
Full list of author information is available at the end of the article



Author details

¹Massachusetts General Hospital, Charlestown, MA, USA. ²Massachusetts General Hospital, Harvard Medical School, Boston, MA, USA.

Published: 1 February 2012

Reference

1. Itskovich, et al: MRM. 2004.

doi:10.1186/1532-429X-14-S1-P135

Cite this article as: Karolyi et al.: Classification of human coronary atherosclerotic plaques with T1, T2 and Ultrashort TE MRI. *Journal of Cardiovascular Magnetic Resonance* 2012 **14**(Suppl 1):P135.

**Submit your next manuscript to BioMed Central
and take full advantage of:**

- Convenient online submission
- Thorough peer review
- No space constraints or color figure charges
- Immediate publication on acceptance
- Inclusion in PubMed, CAS, Scopus and Google Scholar
- Research which is freely available for redistribution

Submit your manuscript at
www.biomedcentral.com/submit

