

POSTER PRESENTATION

Open Access

Pressure gradient measurement in the coronary artery using phase contrast (PC)-MRI: initial patient results towards noninvasive quantification of fractional flow reserve

Zixin Deng^{1,2*}, Sang Eun Lee⁵, Zhaoyang Fan¹, Christopher T Nguyen¹, Qi Yang¹, Xiaoming Bi³, Byoung Wook Choi⁴, Daniel S Berman¹, Hyuk-Jae Chang⁵, Debiao Li^{1,2}

From 19th Annual SCMR Scientific Sessions
Los Angeles, CA, USA. 27-30 January 2016

Background

Fractional flow reserve (FFR) is an invasive procedure evaluating the functional significance of an intermediate coronary stenosis in patients with coronary artery disease (CAD) [1]. Quantification of pressure gradient (ΔP) across a particular stenosis is the key to the determination of FFR. Noninvasive ΔP measurement (ΔP_{MR}) using phase-contrast (PC)-MRI in conjunction with Navier-Stokes (NS) equations has been attempted in various vessels [2-4]. Our previous work has shown the feasibility of deriving ΔP_{MR} at various vessel diameters in a phantom (*fig. 1a*) and excellent correlation between ΔP_{MR} and ΔP measured via a pressure-transducer (*fig. 1b*). This study aimed to investigate the feasibility of deriving ΔP_{MR} in healthy and diseased coronary arteries.

Methods

Coronary PC-MRI acquisitions were ECG triggered (mid-diastole) and navigator gated (end-expiration) [5]. Fat-suppression pre-pulses were applied prior to the acquisitions to avoid chemical shift effects and increase vessel contrast [6]. Contiguous slices (4-9) were consecutively collected across the proximal coronary segment (healthy controls) or stenotic lesion (patients). Imaging parameters were: VENC=35-65 cm/s in all 3 directions, FA=15°, cardiac phase=2(~70 ms/phase), in-plane resolution = 0.5-0.6 × 0.5-0.6 mm², slice thickness=3.2 mm and TA=2-4 min/slice at 3T. Eddy-current correction was done offline followed by NS calculations [7].

Protocol was performed on 11 healthy controls and 6 patients (one with known invasive FFR). Patient inclusion criteria: known/suspected CAD, ≥1 coronary lesion (proximal stenosis ≥30%) detected by CTA and/or invasive coronary angiography (ICA).

Results

A significant ($p<0.001$) increase in ΔP_{MR} was seen in the patient group (6.40 ± 4.43 mmHg) vs. healthy controls (0.62 ± 0.49 mmHg) (*figure 2a*). CTA/ICA reports in 5/6 patients showed a range of stenoses of 30-50% (proximal left anterior descending coronary artery (*pLAD*)), but not significant enough to perform invasive FFR. ICA/FFR was performed in 1/6 patients (diffused, 50% lumen narrowing at *pLAD*, *fig 2b-c*) with FFR=0.56, suggesting a functionally significant lesion. The same patient showed a ΔP_{MR} of ~14 mmHg, likewise suggesting a functionally significant lesion (relatively high pressure drop).

Conclusions

Preliminary results suggest that noninvasive quantification of ΔP_{MR} in both healthy and diseased coronary arteries is feasible. The patient with low FFR (high pressure drop), corroborating the ΔP_{MR} results, showed the feasibility of ΔP_{MR} in differentiating between a functionally significant and a non-significant lesion within the patient group. More patient studies with invasive FFR comparison are underway to further validate the approach. In addition, technical improvements in terms of spatial, temporal resolutions and reduction of noise are also being developed to further improve accuracy.

¹Cedars Sinai Medical Center, Los Angeles, CA, USA
Full list of author information is available at the end of the article

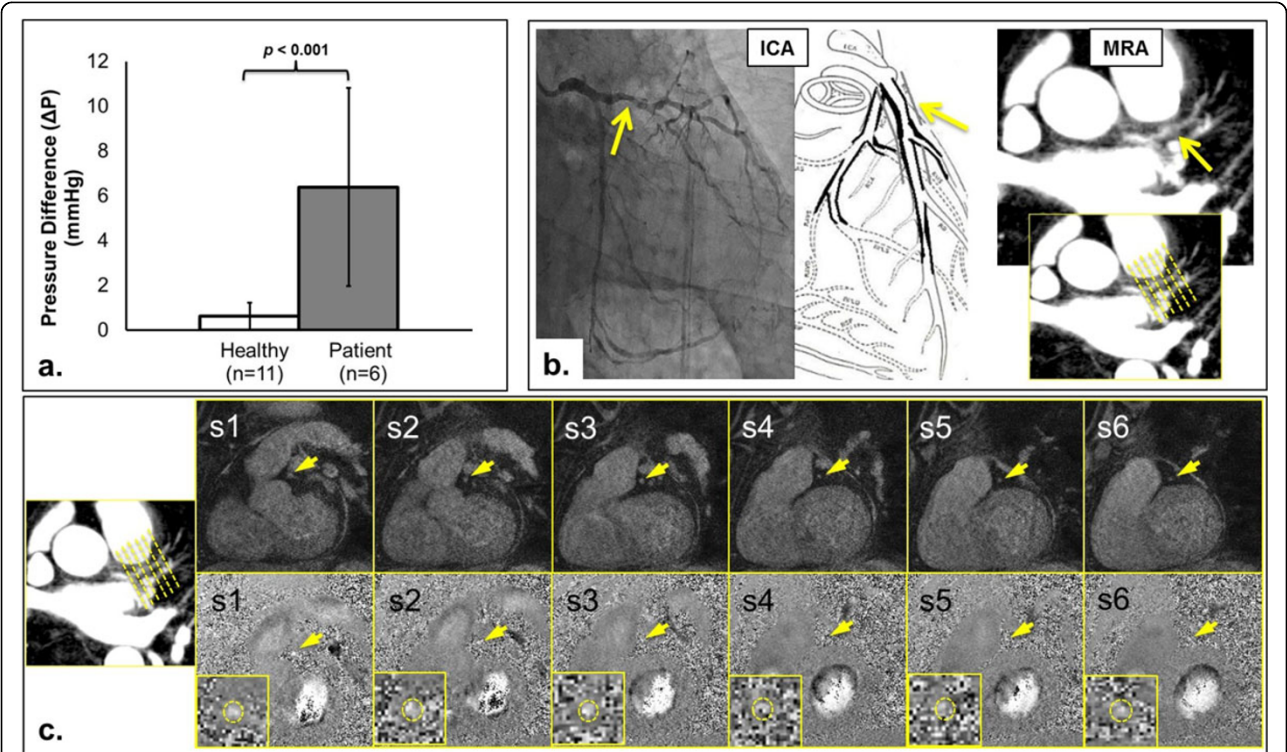
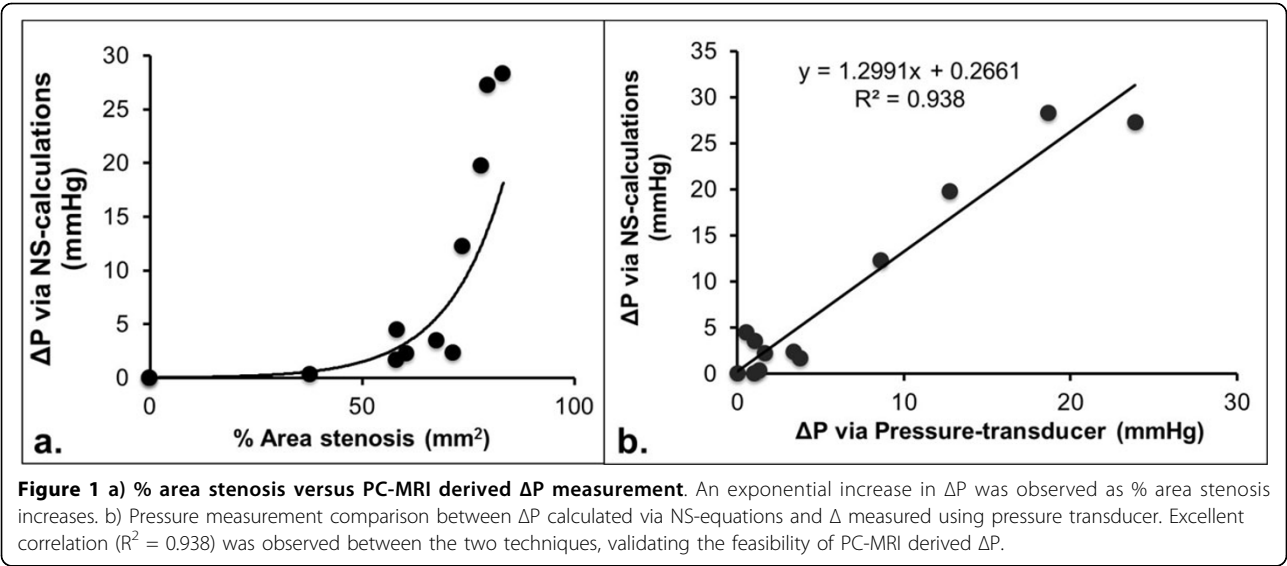


Figure 2 a) The mean \pm std ΔP value for health controls and patients were 0.6249 ± 0.4884 mmHg and 6.3960 ± 4.4302 mmHg, respectively. The high standard deviation in the patient group is due to the range of the stenotic level among the patient group. **b)** Patient example (Patient A). Invasive coronary angiography (ICA) and magnetic resonance angiography (MRA). **c)** Patient A, six cross-sectional slices obtained from PC-MRI over the stenotic lesion at the proximal left anterior descending artery. Top row: flow compensated, bottom row: phase contrast (in the z-direction).

Authors' details

¹Cedars Sinai Medical Center, Los Angeles, CA, USA. ²Bioengineering, University of California, Los Angeles, Los Angeles, CA, USA. ³R&D, Siemens Healthcare, Los Angeles, CA, USA. ⁴Radiology, Severance Hospital, Yonsei University College of Medicine, Seoul, Korea (the Republic of). ⁵Cardiology, Severance Cardiovascular Hospital, Yonsei University College of Medicine, Seoul, Korea (the Republic of).

Published: 27 January 2016

References

1. Pijls, *et al*: *NEJM* 1996.
2. Bock, *et al*: *MRM* 2011.
3. Lum, *et al*: *RY* 2007.
4. Bley, *et al*: *RY* 2011.
5. Deng, *et al*: *ISMRM* 2014.
6. Middione, *et al*: *MRM* 2013.
7. Yang, *et al*: *MRM* 1996.

doi:10.1186/1532-429X-18-S1-P218

Cite this article as: Deng *et al.*: Pressure gradient measurement in the coronary artery using phase contrast (PC)-MRI: initial patient results towards noninvasive quantification of fractional flow reserve. *Journal of Cardiovascular Magnetic Resonance* 2016 **18**(Suppl 1):P218.

Submit your next manuscript to BioMed Central and take full advantage of:

- Convenient online submission
- Thorough peer review
- No space constraints or color figure charges
- Immediate publication on acceptance
- Inclusion in PubMed, CAS, Scopus and Google Scholar
- Research which is freely available for redistribution

Submit your manuscript at
www.biomedcentral.com/submit

