Morsy *et al. BMC Oral Health* (2023) 23:612
https://doi.org/10.1186/s12903-023-03276-5

BMC Oral Health

RESEARCH Open Access

Omega-3 nanoemulgel in prevention of radiation-induced oral mucositis and its associated effect on microbiome: a randomized clinical trial

Basma M. Morsy[1*], Shahira El Domiaty[1], Mohamed A. M. Meheissen[2], Lamia A. Heikal[3], Marwa A. Meheissen[4] and Nourhan M. Aly[5]

Abstract

Background Oral mucositis (OM) is recognized as one of the most frequent debilitating sequelae encountered by head and neck cancer (HNC) patients treated by radiotherapy. This results in severe mucosal tissue inflammation and oral ulcerations that interfere with patient's nutrition, quality of life (QoL) and survival. Omega-3 (ω-3) polyunsaturated fatty acids (PUFAs) have recently gained special interest in dealing with oral diseases owing to its anti-inflammatory, anti-oxidant and wound healing properties. Thus, this study aims to assess topical Omega-3 nanoemulgel efficacy in prevention of radiation-induced oral mucositis and regulation of oral microbial dysbiosis.

Materials and methods Thirty-four head and neck cancer patients planned to receive radiotherapy were randomly allocated into two groups: Group I: conventional preventive treatment and Group II: topical Omega-3 nanoemulgel. Patients were evaluated at baseline, three and six weeks after treatment using the World Health Organization (WHO) grading system for oral mucositis severity, Visual Analogue Scale (VAS) for perceived pain severity, and MD-Anderson Symptom Inventory for Head and Neck cancer (MDASI-HN) for QoL. Oral swabs were collected to assess oral microbiome changes.

Results VAS scores and WHO mucositis grades were significantly lower after six weeks of treatment with topical Omega-3 nanoemulgel when compared to the conventional treatment. The total MDASI score was significantly higher in the control group after three weeks of treatment, and the head and neck subscale differed significantly at both three and six weeks. A significant reduction in Firmicutes/Bacteroidetes ratio was observed after six weeks in the test group indicating less microbial dysbiosis.

Conclusions Topical Omega-3 nanoemulgel demonstrated a beneficial effect in prevention of radiation-induced oral mucositis with a possibility of regulating oral microbial dysbiosis.

Keywords Oral mucositis, Prevention, Omega-3, Nanoemulgel, Microbiome

*Correspondence:
Basma M. Morsy
basma.mohamed.dent@alexu.edu.eg

Full list of author information is available at the end of the article

© The Author(s) 2023. **Open Access** This article is licensed under a Creative Commons Attribution 4.0 International License, which permits use, sharing, adaptation, distribution and reproduction in any medium or format, as long as you give appropriate credit to the original author(s) and the source, provide a link to the Creative Commons licence, and indicate if changes were made. The images or other third party material in this article are included in the article's Creative Commons licence, unless indicated otherwise in a credit line to the material. If material is not included in the article's Creative Commons licence and your intended use is not permitted by statutory regulation or exceeds the permitted use, you will need to obtain permission directly from the copyright holder. To view a copy of this licence, visit http://creativecommons.org/licenses/by/4.0/. The Creative Commons Public Domain Dedication waiver (http://creativecommons.org/publicdomain/zero/1.0/) applies to the data made available in this article, unless otherwise stated in a credit line to the data.

Background

Oral mucositis (OM) is considered one of the most common debilitating complications that develops in head and neck cancer (HNC) patients receiving radiotherapy [1].

Radiation-induced oral mucositis (RIOM) is described as an injury to normal tissues occurring in the form of oral mucosal inflammation and/or ulceration, encountered in more than 80% of head and neck cancer patients undergoing radiation therapy [2–4].

OM- related complaints frequently include mild to severe pain as well as oral erosions and ulcerations that are prone to secondary infections, which interfere with the oral intake of solid food and liquids and may subsequently result in dehydration and/or malnutrition. It can also lead to a reduction in the treatment dose or breaking the treatment course, prolonging hospitalization and consequently affecting patients' quality of life (QoL) and overall survival [1, 3, 5].

The major steps in OM development and resolution are generally characterized by five continuous overlapping phases [1, 6]. This usually involves generation of reactive oxygen species (ROS), activation of transcription factors like nuclear factor kappa B (NF-κB) and upregulation of some pro-inflammatory cytokines including tumor necrosis factor alpha (TNF-α), interleukin-1 beta (IL-1β) and interleukin6 (IL-6) [6–8]. This further strengthens tissue injury resulting in development of painful ulcerations that are prone to secondary infection, which is considered the most significant stage in mucositis [7]. After 4–12 weeks of anti-cancer treatment completion, spontaneous healing of the oral tissues takes place, following submucosal signaling that promotes proliferation, differentiation and renewal of epithelial cells [9].

Along with the current cascade involved in the pathogenesis of OM, recent studies have discussed an emerging role for oral microbial community alterations in OM development and progression. This is possibly explained by an alteration in oral microbial diversity or an increase in pathogenic bacterial abundance during radiation, which is known as "dysbiosis"[10]. A recent review has reported a notably higher bacterial load in OM epithelial ulcerations, which postulated a potential correlation between certain microbial communities and OM severity [11]. More intriguingly, the oral microbiome profile can be used to anticipate and subsequently prevent the onset of severe RIOM [10]. However, the exact role of oral microbiome in OM pathogenesis remains unclear [1, 3, 12]. Thus, in spite of using different antimicrobial agents that target bacteria associated with severe forms of OM, none of the conducted clinical trials have achieved tangible promising outcomes [11, 13].

To date, standard treatment for OM usually focuses on pain control and rehydration [14]. However, multiple preventive methods have been tested in previous clinical studies, with possible potential in mitigating OM. These interventions include: anti-inflammatory medications, herbal medicine, growth factors, cytokines and photobiomodulation therapy [15, 16]. Several studies also recommend patients' dietary modifications such as decreasing sugar intake, in addition to using calcium phosphate rinses and benzydamine mouthwash, to prevent RIOM development [17, 18]. In spite of the continuously evolving treatment and preventive approaches, definitive cost-effective treatment or preventive therapies for oral mucositis are still lacking [1, 3, 19].

Omega-3 (ω-3) polyunsaturated fatty acids (PUFAs) are classified as essential fatty acids that have long been recognized in normal growth, health, and disease risk reduction [20, 21]. They comprise a group of fatty acids, among which eicosapentaenoic acid (EPA, C20:5) and docosahexaenoic acid (DHA, C22:6) are the two vital bioactive forms in humans [20, 22]. Although EPA and DHA can be synthesized from the precursor Alpha-linolenic acid (ALA), this requires complex chemical reactions making their conversion less efficient in humans. Thus, consumption of food such as fish, fish oils or nutritional supplements rich in these two principal fatty acids is recommended [22].

Supported by both animal and human studies, mounting evidence has shown that ω-3 PUFAs, mainly EPA and DHA, have beneficial therapeutic roles in various human diseases such as diabetes, cardiovascular diseases and autoimmune conditions [21, 23].Moreover, growing research indicates that dietary intake of ω-3 PUFAs in cancer patients exhibits anti-neoplastic roles, enhances the efficacy of radiation and lowers cancer incidence and mortality rates [24]. Additionally, multiple studies have highlighted the effect of Omega-3 supplements' consumption in maintaining body weight/composition and improving (QoL) of cancer patients [25, 26]. This is possibly attributed to their anti-inflammatory and anti-oxidant effects, and also their role in maintaining epithelial integrity and promoting whole-body wound healing [27, 28].

Several hypotheses have been postulated to explain the anti-inflammatory effect of Omega-3. It majorly focused on their capability in inhibiting nuclear factor kappa B (NF-κB) protein expression [27]. This comes along with downregulation of multiple pro-inflammatory cytokines including (TNFα), (IL-1β) and (IL-6) [27, 29]. Omega-3 also possess the ability to produce certain metabolites known as specialized pro-resolving mediators (SPMs) that include: resolvins D (RvD) and E (RvE) series and protectins that act as potent anti-inflammatory agents [30]. Furthermore, DHA was noted to induce upregulation of detoxification and antioxidant genes, reducing oxidative stress [27, 31].

Moreover, recent studies suggest the potential role of ω-3 in managing chemotherapy- or radiotherapy-related intestinal microbial dysbiosis, by upregulating beneficial bacteria with anti-inflammatory impact, that in turn modulates systemic inflammatory and immune responses of the host. In addition to its ability to decrease proportions of pathogenic microorganisms, which may collectively influence OM in terms of development, severity or healing [11, 27, 29]. However, the effect of ω-3 on oral microbiome is still not fully covered.

Compared to systemic supplements, animal studies have demonstrated a better effect of locally delivered ω-3 PUFAs in terms of decreasing inflammation, enhancing re-epithelialization and wound healing [28, 32, 33].

Both human and animal studies demonstrated the effect of ω-3 PUFAs on different oral diseases such as gingivitis, periodontal diseases and recurrent aphthous stomatitis (RAS) [34–39]. A recent clinical trial suggested that ω-3 PUFAs may exert a therapeutic potential against chemotherapy-induced mucositis [40]. To the best of our knowledge however, the effect of ω-3 PUFAs has not been investigated on (RIOM) yet. Thus, the purpose of this study was to evaluate the effect of topical Omega-3 nanoemulgel in prevention of radiation-induced oral mucositis and its associated pain, improvement of patients' (QoL), as well as testing its effect on oral microbiome.

Materials and methods

Study design

A two-arm parallel randomized, controlled clinical trial was conducted on thirty-four head and neck cancer patients of both genders who were planned to receive radiotherapy from February to September 2022. Patients were selected from the outpatient clinic of Department of Clinical Oncology, Faculty of Medicine, Alexandria University. Prior to the study, patients were given a detailed explanation of the study and signed an informed consent according to the guidelines of the Ethical Committee of the Faculty of Dentistry, Alexandria University. The study was completed according to the principles of the modified Helsinki's code for human clinical studies (2013) and CONSORT 2010 guidelines for reporting randomized clinical trials. It was also approved by the Research Ethics committee of the Faculty of Dentistry, Alexandria University (IRB NO: 00010556-IORG0008839- 0290-09/2021) in September 2021, and has been registered at ClinicalTrials.gov on 28/01/2022, registration number: (NCT05214495), [41]. Detailed trial protocol can be accessed and provided when requested.

Participants

Participants were eligible if they had head and neck cancer proven malignancy and were planned to receive radiotherapy (50 Gy or above) using machine (Elekta unity linear accelerator, Sweden) [42] either as postoperative (adjuvant) or definitive therapy, aged above 18 from both sexes [43], and had good to moderate oral hygiene levels (simplified oral hygiene index scores ≤ 3) [44]. Patients were excluded if they were planned to receive concomitant chemotherapy or were diagnosed with any current oral viral/fungal infections. Patients under anticoagulants such as warfarin, heparin, or aspirin, suffering from any uncontrolled systemic diseases (such as diabetes, cardiovascular, liver disorder, renal dysfunction) or having interfering physical or intellectual disabilities that can affect the procedure were also excluded [2].

Before enrollment in the study, thorough medical and dental history was taken from all patients. All participants received phase one therapy that included: scaling and root planning (SRP), obturation of caries, removal of all septic foci detected intraorally and basic oral hygiene instructions' demonstration [45]. Also, a brief introduction about the study and its objectives was given to all patients in their native language and a written informed consent was signed by them, that stated all possible outcomes, side effects of the treatment, as well as their right to withdraw at any time from the study.

Sample size estimation

Sample size was estimated assuming 5% alpha error and 80% study power. Bakr et al. [2] reported no signs of oral mucositis (grade 0) after 6 weeks of topical oral vitamin oral D application in 60% of patients compared to 13.3% with conventional treatment. Topical omega-3 oral gel is assumed to have a similar effect as vitamin D [35, 46]. Based on comparison of proportions, sample size was calculated to be 16 patients per group, increased to 18 to make up for loss to follow-up. The total sample size required = number of groups × number per group = 2 × 18 = 36 patients. Sample size was calculated using G*Power (Version 3.1.9.4) [47].

Randomization, blinding and allocation concealment

Randomization was performed using a computer-generated random allocation software [48]. Participants were allocated in blocks of four to one of the two study groups, using permuted block technique. Allocation numbers were sealed in opaque envelopes, and an assistant, who was not involved in the study, performed the treatment allocation. Blinding of participants and the main operator was challenging since several therapeutic agents with different regimens and doses were applied in the control group compared to the test group that only received topical Omega-3 nanoemulgel. Accordingly, a single placebo gel for the control group was not feasible. However, the outcome assessor and statistician were blinded to the allocation of groups. Outcome assessment was performed by a trained oral medicine specialist after

calibration using 20 intraoral photographs of different grades of mucositis. Intra-examiner reliability was calculated, and Kappa statistic ranged from 0.83 to 0.94 indicating excellent reliability [49].

Preparation of Omega-3 nanoemulgel

Fish oil (Omega-3 fatty acids 70.4%; EPA 34.9% and DHA 24.2%) was supplied from Safe pharmaceutical company, Alexandria, Egypt. To enhance fish oil ingredients' absorption and tissue-penetration, Omega-3 nanoemulgel was formulated [50]. Fish oil nano emulsion was developed using direct emulsification method. Briefly, the aqueous phase containing Tween 80 (El Gomhouria Co. Alexandria, Egypt) was added to the oily phase (Fish oil and Span 80 (sigma Aldrich, UK)) [51, 52]. The ratio of water: oil was 6:4 and the ratio of the used surfactant was 7:3 for Tween 80 and Span 80 respectively. The mixture was pre-emulsified for 5 min at 20,000 rpm using T25-digital Ultra-Turrax homogenizer (IKA Works, Inc., Wilmington, NC). The formed coarse emulsion was then ultrasonicated using Branson Digital Sonifier S-450D (Emerson Electric Co., St. Louis, MO at 60% ultrasonic amplitude for 5 min [53]. Nanoemulgel was prepared by mixing the nanoemulsion (NE) with Carbopol gel (1% w/w) in 2: 1 ratio. For preparation of gel, Carbopol 940 (Alamreya Pharmaceuticals, Alexandria, Egypt) was dispersed in water then neutralized using triethanolamine using pH meter (Mettler Toledo, Switzerland) [54]. Drops of Apple oil were added at the end as a flavouring agent. The final concentration of Fish oil in the preparation was 35% w/w.

Invitro characterization of the prepared formulation

1. **Particle Size Distribution Analysis** Size of the emulsion droplets and polydispersity index (PDI) was measured using a Zetasizer Nano ZS90 (Malvern Pananalytical, Malvern, UK). Samples were diluted 1:10 using distilled water. Dynamic Light Scattering was performed using laser wavelength 633 nm and 90° scattering angle at 25 °C.
2. **Viscosity measurement**: The viscosity of the prepared (NE) hydrogel was measured using Brookfield RV head multipoint viscometer at a speed of 1 rpm and spindle CP-40 at room temperature.
3. **Spreadability**: The spreadability of prepared nanoemulgel was determined by measuring the spreading diameter of nanoemulgel between the two glass plates after 1 min. The spreadability was calculated using the formula $S = m \cdot l / t$, where S is spreadability, m is mass added, l diameter of the spreaded gel and t is the time taken.
4. **Stability Test**: The stability of the prepared (NE) systems was assessed by applying centrifugation stress; 1 mL of the system was added to 100 mL distilled water and centrifuged for 30 min (5000× rpm), and phase separation was inspected visually using ultra cooling centrifuge (Sigma laborzentrifugen GmbH, Osterode, Germany) [51].
5. **Characterization Results**: Characterization results for Omega-3 nanoemulgel are listed in Table 1.

Table 1 Characterization results for Omega-3 nanoemulgel

Characteristics of NE	
Droplet size of NE (nm)	146.7 ± 11.45
PDI	0.14
Stability	Stable with no phase separation
Characteristics of FO nano emulgel	
Viscosity	18,260 cp.
Spreadability	0.79 g.cm.S^{-1}
pH	6.8

Intervention

The assigned thirty-four patients were randomly allocated to the following groups:

The control group (n=17) received conventional preventive treatment that was started one day before radiotherapy and applied twice daily for six weeks [2, 55]. This included topical antifungal agent: Miconazole 2% (Miconaz oral gel)[1] that was applied with a standardized spoon twice daily, anti-inflammatory mouthwash, 5gm sodium bicarbonate mouthwash (Alkamisr sachets)[2] where patients were asked to rinse twice daily using a standardized cup. Topical anesthetics agent containing 1.5 g Benzocaine: (BBC oral spray)[3], topical analgesic gel containing 2.0 g Lidocaine HCl (Oracure gel)[4] and systemic analgesics were provided when needed.

The test group (n=17) were given topical Omega-3 nanoemulgel formulated and characterized with the aid of the Pharmaceutics Department, Faculty of Pharmacy, Alexandria University, as previously mentioned, where 1 g (containing 350 mg of fish oil) was self-applied by patients twice daily, every 12 h, starting one day before radiotherapy and ongoing for six weeks, to ensure a daily dose of (700 mg of fish oil/day) [56–58]. To ensure compliance, participants of both groups were given self-check reminder sheets with assigned doses, that were checked at both follow up visits. Also, patients developing grade (3–4) OM from both groups were re-assessed by an oncology specialist. Systemic analgesics, parenteral nutrition or complete hospitalization was done if needed.

[1] Manufactured by Medical Union Pharmaceuticals, 6th District-Nasr City-Cairo-A.R.E.

[2] Manufactured by: Misr Co. For Pharm. Ind. S.A.E. - Egypt.

[3] Manufactured by Amoun Pharmaceutical Company El Obour city – Cairo – Egypt.

[4] Manufactured by Amoun Pharmaceutical Company El Obour city – Cairo – Egypt.

Outcome measures

As patients were planned to receive a typical radiation cycle of (5–7) weeks, and as OM clinical signs usually appear by the second or third week of treatment [59], all patients were evaluated clinically at baseline, three and six weeks after the intervention [2, 8] through the following:

- Oral mucositis severity, measured using the WHO grading system [60], according to the patient's functional and symptomatic clinical features [61] listed in Table 2.
- Pain and discomfort were reported by each patient using the Visual Analog Scale (VAS) [62, 63] where patients were asked to rate the level of pain they were experiencing on a scale from 0 (no pain at all) to 10 (severe intolerable pain).
- Symptom burden and QoL were assessed by the translated Arabic version of M. D. Anderson Symptom Inventory–Head and Neck (MDASI-HN) questionnaire [64, 65]. It assesses the severity of symptoms experienced by head and neck cancer patients that interfere with their daily functioning. The MDASI-HN is composed of 28 items measured on 3 subscales: 13 core symptom items (as: fatigue, nausea and dry mouth), 6 interference items (as activity and life enjoyment), and 9 head and neck cancer specific items (as difficulty in swallowing/chewing and mouth or throat sores). Each item is scored on a Likert scale from 0 to 10 with higher scores indicating a worse condition. The score of each domain is the average score of its items, and the total score is the average of the 28 items. The questionnaire was originally developed and validated in English [64], and further translated and validated in Arabic [65]. The scores were used as quantitative variables.

Microbiological assessment

Sample collection, preservation, and transport

Oral samples were collected from all patients using sterile cotton tipped swabs which were used to remove saliva and shedded cells by gently scrapping the oral mucosa. Swabs were then put into 3 ml sterile phosphate buffered saline (PBS) and were immediately delivered and stored at −20 °C, at Alexandria University Diagnostic Microbiology Laboratory.

DNA extraction

DNA was extracted from samples using QIAamp® DNA Mini Kit (QIAGEN, Hilden, Germany) according to the manufacturers' instructions. DNA extracts were stored at −80 °C until PCR testing. Eight microliters of DNA extract were used for each PCR reaction.

Table 2 WHO grading system for Oral mucositis severity

Grade	Description
Grade 0	None
Grade I	Mild mucositis: oral soreness and/or erythema
Grade II	moderate mucositis: oral erythema, ulcers, and solid diet can be tolerated
Grade III	severe mucositis: oral ulcers, but solid diet cannot be tolerated
Grade IV	life-threatening: oral alimentation is impossible

Table 3 Primers' sequences used in the current study

GENE	SEQUENCE	bp
Total bacteria	CGCTAGTAATCGTGGATCAGAATG TGTGACGGGCGGTGTGTA	69
Phylum		
Bacteroidetes	GTTTAATTCGATGATACGCGAG TTAASCCGACACCTCACGG	122
Firmicutes	GGAGYATGTGGTTTAATTCGAAGCA AGCTGACGACAACCATGCAC	126

Real-time PCR (SYBR green)

The real-time PCR protocol was done as previously described [66]. Selected phyla; (Bacteroidetes [67], Firmicutes [68]) were targeted using specific PCR primers. In addition to a broad-range primer which targets conserved 16SrRNA sequence of total bacteria [69], the amplification of which acted as the denominator against which other bacteria amplification was estimated. Primers (Metabion International AG, Germany) that were used in the study are listed in Table 3. Amplification was carried out in real-time PCR cycler, the Rotor-Gene Q (QIAGEN, Germany) by the aid of 2x MAXIMA SYBR Green qPCR Master mix (2x), No-ROX (Thermo Fisher Scientific). It was performed in 20 µL reaction volume that contains 10 pmol/µL of each primer. The reaction consisted of initial denaturation at 95 °C for 10 min, followed by 40 cycles of denaturation at 95 °C for 30 s, annealing at 60 °C for 30 s, and extension at 72 °C for 30 s. Melting curve analysis was done to check the specificity of the amplified products. Specific bacterial DNA quantification was expressed as relative quantitation/fold difference that was calculated automatically using the Rotor-Gene software [70].

Statistical analysis

Data were analyzed using IBM SPSS for Windows (Version 23.0) and significance was inferred at p value < 0.05. Descriptive statistics were calculated as means, standard deviation (SD), median, interquartile range (IQR), frequencies and percentages. Comparisons between the two study groups were done using independent samples t-test for quantitative normally distributed variables, and Mann-Whitney test for non-normally distributed and ordinal. Fisher exact and chi-square tests were used for comparing qualitative nominal variables. Comparisons

between different timepoints within the same group were done using Wilcoxon signed rank (two time points only), and Friedman test (3 timepoints) followed by multiple pairwise comparisons using Bonferroni adjusted significance level. Intention-to-treat analysis was used in analyzing all subjects included in the current study.

Results

Figure 1 shows that out of the total 42 head and neck cancer patients assessed for eligibility, only 34 were included in the current study. Table 4 represents the patients' demographic data and baseline characteristics. There were 9 (52.9%) males in the test group compared to 13 (76.5%) in the control group. The mean (SD) age was 55.76 (11.67) and 58.35 (11.67) in the test and control groups, respectively. The most common cancer site was the oral cavity in both groups. No statistically significant differences between groups were detected regarding their demographic data and baseline characteristics. The only complaint received was a transient bitter taste associated with topical Omega-3, and no other adverse side-effects were observed in both groups.

Table 5 shows that there were no significant differences in the perceived pain intensity between the two groups at baseline (p=0.56) and three weeks (p=0.09), while at six weeks, the control group showed significantly higher perceived pain than the test group (mean (SD)=2.75 (2.21) and 1.40 (1.55) in the control and test groups, respectively, p=0.049). The mean difference in pain intensity after six weeks (from baseline) was higher in the control group (mean (SD)=2.63 (2.28)) than the test group (mean (SD)=1.33 (1.63)), (p=0.09) as represented in Fig. 2.

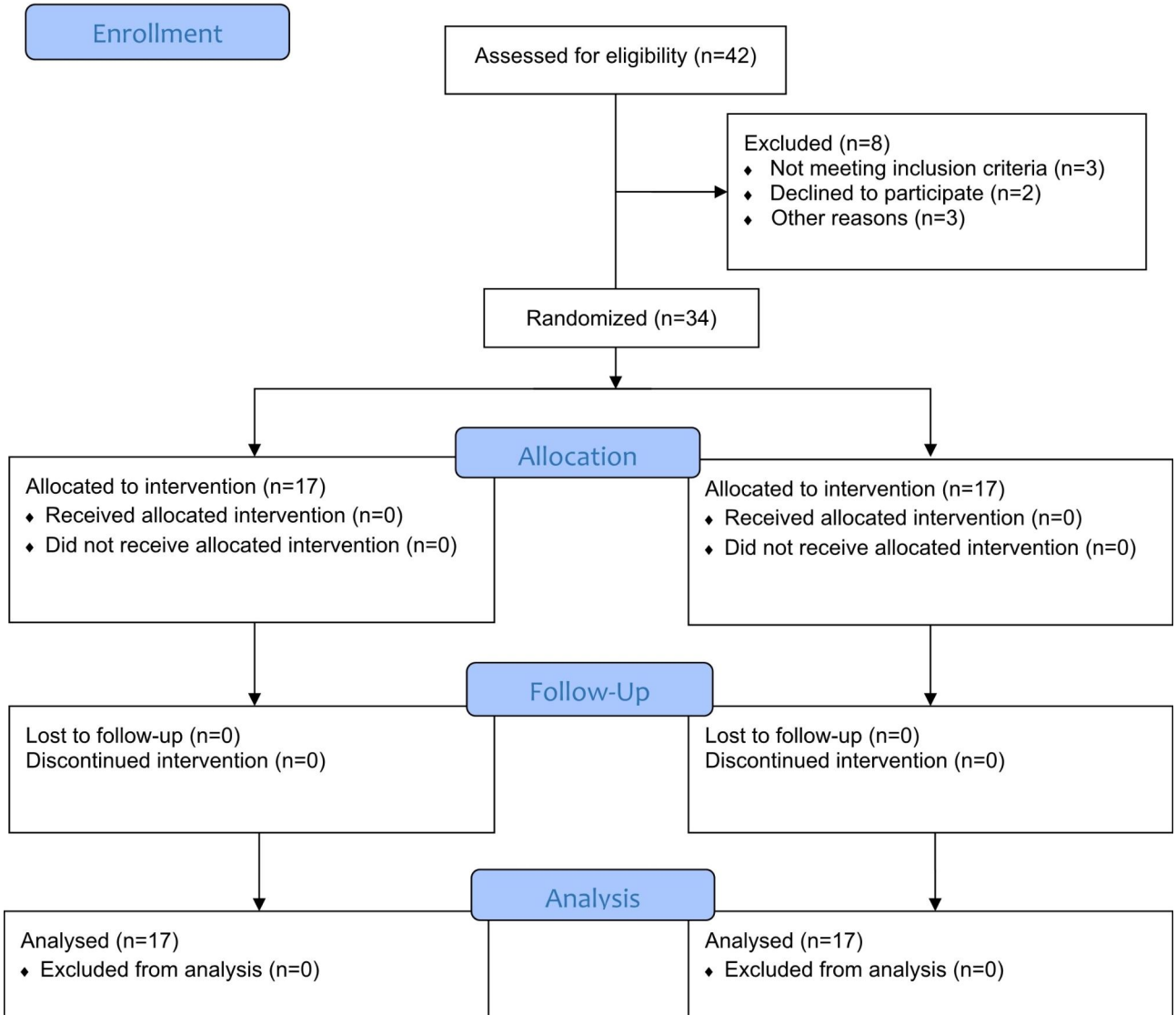

Fig. 1 Consort flow chart

Table 4 Baseline characteristics

		Test (n = 17)	Control (n = 17)	P value
Age a	**Mean (SD)**	55.76 (11.67)	58.35 (11.67)	0.52[a]
Gender: n (%)	**Males**	9 (52.9%)	13 (76.5%)	0.28[b]
	Females	8 (47.1%)	4 (23.5%)	
Diagnosis: n (%)	**Laryngeal**	5 (29.4%)	6 (35.3%)	0.81[c]
	Oral Cavity	9 (52.9%)	9 (52.9%)	
	Sinonasal	3 (17.7%)	2 (11.8%)	
Radiation therapy: n (%)	**Adjuvant**	14 (82.3%)	10 (58.8%)	0.26[b]
	Definitive	3 (17.7%)	7 (41.2%)	
Total radiation dose (GY)	**Mean (SD)**	64.20 (3.78)	65.18 (4.55)	0.52[a]
	Median (IQR)	64.0 (60.0, 66.0)	65.5 (60.0, 70.0)	
	Min – Max	60.0–70.0	60.0–70.0	
Number of radiation fractions	**Mean (SD)**	31.87 (2.17)	32.18 (2.65)	0.72[a]
	Median (IQR)	32.0 (30.0, 33.0)	32.0 (30.0, 35.0)	
	Min – Max	28.0–35.0	28.0–35.0	

[a]: Independent samples t-test

[b]: Fisher exact test

[c]: Chi-square test (with Monte Carlo corrected p value)

Table 5 Comparison of pain intensity using VAS in the two study groups at different timepoints

		Test (n = 17)	Control (n = 17)	MWU P value
Baseline	**Mean (SD)**	0.06 (0.24)	0.18 (0.39)	0.56
	Median (IQR)	0.00 (0.00, 0.00)	0.00 (0.00, 0.00)	
3 weeks	**Mean (SD)**	1.79 (2.42)	3.06 (2.46)	0.09
	Median (IQR)	1.00 (0.00, 3.25)	3.00 (1.00, 5.00)	
6 weeks	**Mean (SD)**	1.40 (1.55)	2.75 (2.21)	**0.049***
	Median (IQR)	1.00 (0.00, 2.00)	2.00 (1.00, 4.75)	
Friedman test p value		0.06	**< 0.001***	
Baseline vs. 3 weeks		0.17	**< 0.001***	
Baseline vs. 6 weeks		0.07	**0.002***	
3 weeks vs. 6 weeks		1.00	1.00	

MWU: Mann-Whiney U test was used

*statistically significant at p value < 0.05

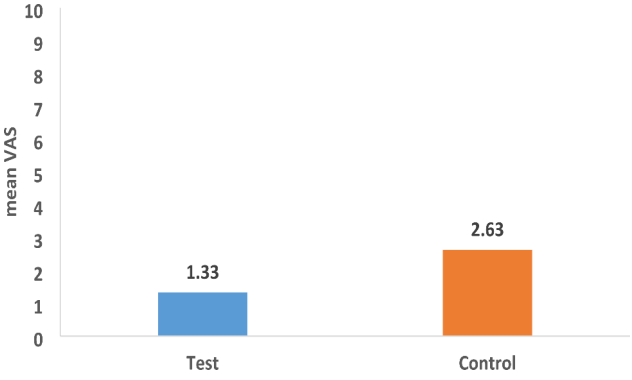

Fig. 2 Difference in mean VAS score after 6 weeks (from baseline)

Table 6 Comparison of WHO oral mucositis grade between the two study groups at different timepoints

		Test (n = 17)	Control (n = 17)	P value
Baseline	**Grade 0**	17 (100%)	17 (100%)	1.00
	Grade 1–2	0 (0%)	0 (0%)	
	Grade 3–4	0 (0%)	0 (0%)	
3 weeks	**Grade 0**	10 (58.8%)	3 (17.6%)	**0.01***
	Grade 1–2	4 (23.5%)	7 (41.2%)	
	Grade 3–4	3 (17.7%)	7 (41.2%)	
6 weeks	**Grade 0**	11 (64.7%)	2 (11.8%)	**0.02***
	Grade 1–2	4 (23.5%)	11 (64.7%)	
	Grade 3–4	2 (11.8%)	4 (23.5%)	
Friedman's test		0.08	**< 0.001***	
Baseline vs. 3 weeks		0.13	**< 0.001***	
Baseline vs. 6 weeks		0.36	**0.002***	
3 weeks vs. 6 weeks		1.00	1.00	

*statistically significant at p value < 0.05

Table 6 shows that all the included patients presented with grade 0 mucositis at baseline. After three weeks of therapy, 10 patients (58.8%) in the test group compared to only 3 patients (17.6%) in the control group showed grade 0 mucositis, while severe mucositis (grade 3–4) was reported in only three patients (17.7%) in the test group compared to 7 (41.2%) in the control group with a significant difference between both groups (p = 0.01). At the six weeks follow-up, the same 10 patients (58.8%) presented with grade 0 mucositis in the test group, compared to only 2 patients (11.8%) in the control group with a significant difference between both groups (p = 0.02)

highlighting the preventive activity of Omega-3 nanoemulgel. Moderate mucositis (grade 1–2) was reported in 11 patients (64.7%) in the control group compared to 5 patients (29.4%) in the test group, and severe mucositis (grade 3–4) was reported in 2 (11.8%), and 4 (23.5%) in the test and control groups, respectively. As for the intragroup comparisons, there were no significant differences between the mucositis scores across timepoints in the test group (p=0.08), however, significant differences were detected between baseline and both three and six weeks follow-ups in the control group (p<0.001 and 0.002, respectively).

Table 7 Comparison of MDASI scores between the two study groups at different timepoints

		Test (n=17)	Control (n=17)	P value
		Mean (SD)		
Core	**Baseline**	0.6 (0.40)	0.43 (0.31)	0.10
	3 weeks	2.09 (1.85)	2.44 (1.31)	0.28
	6 weeks	1.94 (0.75)	2.40 (1.26)	0.28
	Friedman test	**<0.001***	**<0.001***	
	Baseline vs. 3 weeks	**0.003***	**<0.001***	
	Baseline vs. 6 weeks	**<0.001***	**<0.001***	
	3 weeks vs. 6 weeks	1.00	1.00	
Interference	**Baseline**	1.23 (0.81)	1.24 (1.01)	0.92
	3 weeks	2.56 (1.59)	3.28 (1.15)	**0.04***
	6 weeks	2.70 (0.72)	3.07 (1.47)	0.50
	Friedman test	**0.003***	**<0.001***	
	Baseline vs. 3 weeks	**0.02***	**<0.001***	
	Baseline vs. 6 weeks	**0.003***	**<0.001***	
	3 weeks vs. 6 weeks	1.00	1.00	
Head and neck	**Baseline**	1.02 (0.74)	1.31 (0.91)	0.38
	3 weeks	2.38 (1.14)	3.39 (1.52)	**0.04***
	6 weeks	2.38 (0.86)	3.63 (1.39)	**0.02***
	Friedman test	**0.001***	**<0.001***	
	Baseline vs. 3 weeks	**0.01***	**<0.001***	
	Baseline vs. 6 weeks	**0.002***	**<0.001***	
	3 weeks vs. 6 weeks	1.00	1.00	
Total score	**Baseline**	0.95 (0.50)	0.99 (0.58)	0.79
	3 weeks	2.34 (1.43)	3.04 (1.23)	**0.04***
	6 weeks	2.34 (0.66)	3.04 (1.30)	0.16
	Friedman test	**0.004***	**<0.001***	
	Baseline vs. 3 weeks	**0.02***	**<0.001***	
	Baseline vs. 6 weeks	**0.007***	**<0.001***	
	3 weeks vs. 6 weeks	1.00	1.00	

*statistically significant at p value<0.05

Table 7 shows that the total MDASI scores did not differ significantly between the two study groups at baseline and six weeks (p=0.79 and 0.16, respectively). At three weeks, the total MDASI score was significantly higher in the control than the test group (mean (SD)=3.04 (1.23) and 2.34 (1.43), in the control and test groups, respectively). As for the Head and Neck subscale, scores were significantly higher in the control group at three and six weeks (p=0.04 and 0.02, respectively), while in the interference subscale the significant difference between both groups was only detected at the three weeks follow-up (p=0.04).

Table 8 represents the oral microbiome results at baseline and after six weeks of therapy. No significant differences between groups were reported at baseline (p>0.05). The Bacteroidetes phylum was significantly higher in the test group at six weeks (mean (SD)=62 (13) $\times 10^{-2}$ and 38 (28) $\times 10^{-2}$ in the test and control groups, respectively, p=0.04). Moreover, the difference from baseline in both the Bacteroidetes and Firmicutes phyla differed significantly between both groups (p=0.002 and 0.02, respectively). Intragroup comparisons also showed a significant change in the Bacteroidetes phylum in both groups (p=0.04), and also a significant increase in the Firmicutes phylum in the control group only (p=0.01). Meanwhile, the Firmicutes to Bacteroidetes ratio was significantly higher in the control group at the six weeks follow-up (mean (SD)=6.96 (11.24) compared to 1.32 (0.30), p=0.01), and the difference from baseline also differed significantly between both groups (p=0.002). The intragroup comparison of Firmicutes to Bacteroidetes ratio differed between baseline and the 6-week follow-up in the control group only (p=0.01).

Discussion

RIOM is one of the most frequently encountered complications in HNC [71], that is usually associated with significant pain and discomfort, affecting the patient's QoL [9]. Omega-3 PUFAs have been reported to have vital roles in inflammation reduction and tissue homeostasis recovery in many oral diseases including oral mucositis [72]. Results of the present study demonstrated a significant difference in VAS pain scores between the test and control groups after six weeks. This comes together with a significant reduction in oral mucositis incidence and severity in the test group in both times of assessments. After six weeks, around (59%) of the test group were clinically free from oral mucositis compared to only two patients in the control group. These results highlighted the efficacy of topical Omega-3 nanoemulgel in preventing oral mucositis, mitigating its severity and associated pain. This could be possibly attributed to the previously

Table 8 Microbiome results in the two study groups

		Test	Control	P value 1
		Mean (SD)		
Bacteroidetes	**Baseline**	55 (19) $\times 10^{-2}$	46 (24) $\times 10^{-2}$	0.32
	Six weeks	62 (13) $\times 10^{-2}$	38 (28) $\times 10^{-2}$	**0.04***
	Difference.	7 (17) $\times 10^{-2}$	-8 (9) $\times 10^{-2}$	**0.002***
	P value 2	**0.04***	**0.04***	
Firmicutes	**Baseline**	84 (7) $\times 10^{-2}$	81 (11) $\times 10^{-2}$	0.67
	Six weeks	88 (9) $\times 10^{-2}$	94 (5) $\times 10^{-2}$	0.06
	Difference	4 (6) $\times 10^{-2}$	13 (7) $\times 10^{-2}$	**0.02***
	P value 2	0.07	**0.01***	
Firmicutes: Bacteroidetes ratio	**Baseline**	1.73 (0.74)	4.10 (6.85)	0.61
	Six weeks	1.32 (0.30)	6.96 (11.24)	**0.01***
	Difference	-0.41 (0.71)	2.86 (4.46)	**0.002***
	P value 2	0.11	**0.01***	

P value 1: Test compared to control (Mann-Whitney U test)

P value 2: Baseline compared to follow-up (Wilcoxon signed rank test)

*statistically significant at p value <0.05

illustrated potent anti-inflammatory, antioxidant roles and early wound epithelialization ability. No adverse side-effects were observed in both groups, however, the only complaint received was a slight fishy taste associated with topical Omega-3.

Our results are aligned with Hashemipour et al. [40] who reported a significant decrease in oral mucositis severity and duration in patients receiving systemic Omega-3 supplements. Furthermore, our results are also consistent with El Khouli et al. [39] who reported a significant reduction in RAS outbreak and pain level after using ω-3 supplements [39]. Despite the difference in the etiopathogenesis between RAS and RIOM, the study highlights the influence of omega-3 intake on mucosal recovery [72].This can be related to the ability of EPA and DHA, on a cellular level, to maintain epithelial integrity and cell barrier function by preventing disruption in tight junction structure and decreasing cell necrosis [73]. In addition, our results of topical protective action of Omega-3 nanoemulgel are comparable with Basha et al. [28] who demonstrated a significant enhancement in oral mucosal wound healing in rats treated topically by omega-3 compared to its systemic administration.

Although clinician-reported instruments such as the WHO grading system can provide an adequate estimate of the severity of oral mucositis and its associated symptoms, patient reported outcome tools have been increasingly used to measure symptom burden and QoL [64]. In our study, the MDASI-HN was chosen to assess patients' symptom severity during the study period. MDASI-HN is a brief, validated, comprehensive, self-administered questionnaire that directly assesses HNC symptoms and is closely associated with the severity of RIOM [74, 75].

Our study demonstrated a significant difference in MDASI-HN scores in the head and neck subscale between groups at three and six weeks, while the total scores differed significantly only after three weeks. Patients receiving topical omega-3 nanoemulgel experienced clinically meaningful reduction in mouth sores and reported easier food chewing and swallowing, together with an overall improvement in their daily functioning and QoL compared to the control group. These results are consistent with Barker et al [76] who reported a significant worsening in most of MDASI-HN scores, where difficulty in swallowing, oral dryness and mouth sores were the most clinically deteriorating symptoms experienced by patients, after six weeks of receiving (chemo) radiotherapy in the head and neck region. However, in contrast to our findings, Lopez et al [77] reported no significant differences in any of the MDASI-HN items after six weeks of oral glutamine administration compared to placebo, and this could be related to the non-significant difference in clinically reported outcomes between the two studied groups.

In addition to the known mechanisms of RIOM development and progression, recently, there have been a surge of interest in microbiome dysbiosis and its possible association with oral mucositis [78–81]. ω-3 is currently identified as a major potential hotspot in managing gastrointestinal and oral bacterial dysbiosis [82, 83]. In our study, we mainly focused on dominant bacterial phyla [22]: Bacteroidetes and Firmicutes where Firmicutes/Bacteroidetes ratio could serve as a marker for bacterial dysbiosis [84]. After six weeks, our results have outlined a significant increase in Firmicutes and Firmicutes/Bacteroidetes ratio in the control group compared to the test group. These results are consistent with the Pilchardus Study (2016)which reported a significant decrease in the Firmicutes phylum in both experimental groups, together with a decrease in Firmicutes/Bacteroidetes ratio in the

Omega-3 group [85]. This was also aligned with Yu et al. who reported a reduction in the Firmicutes phylum in mice fed by ω-3 rich fish oil for 15 days [86]. Additionally, Fu et al. illustrated the inherent ability of ω-3 supplementations in altering the abundance and diversity of gut microbes, specifically influencing Firmicutes/Bacteroidetes ratio in many diseases such as Obesity and inflammatory bowel disease [83].

The study has several strengths, to the best of our knowledge, this is the first clinical trial to test the efficacy of topical Omega-3 nanoemulgel in preventing RIOM. We depended on clinical examination to assess the oral mucositis severity and complemented our assessment by measuring patient-reported outcomes to comprehensively capture the efficacy of topical omega-3 in prevention of RIOM and its associated symptoms. We also collected oral swabs to assess the role of Omega-3 in regulation of oral microbial dysbiosis. Our study, thus, fills a knowledge gap by providing evidence about the effect of topical Omega-3 nanoemulgel in prevention of RIOM.

However, the study had some limitations including the short-term follow up, so further clinical trials with larger sample size and longer follow-ups that can assess OM after several radiation therapy-cycles are still needed. Also, the current study included a heterogenous group of head and neck tumours that required different radiation doses for treatment, thus, more clinical trials are needed with standardization of the type of head and neck cancer to ensure a more homogenous sample of patients. Also, trials comparing the efficacy of topical and systemic Omega-3 supplements on mucositis prevention are needed to further study the role of Omega-3 on modulation of oral microbiota, including more phyla and species. More studies are encouraged to determine and adjust the exact dosage of Omega-3 nanoemulgel in different oral diseases.

Conclusions

The current study demonstrated a beneficial effect of topical use of ω-3 nanoemulgel in RIOM prevention, decreasing the associated pain intensity and improving the overall QoL of HNC patients. Moreover, in addition to its potent anti-inflammatory and antioxidant properties, our study suggests a potential role of Omega-3 in influencing oral microbial dysbiosis that could directly or indirectly help in RIOM amelioration.

List of abbreviations

OM	Oral mucositis
HNC	Head and neck cancer
ω-3	Omega-3
PUFAs	Polyunsaturated fatty acids
WHO	World Health Organization
VAS	Visual Analogue Scale
MDASI-HN	MD-Anderson Symptom Inventory for Head and Neck cancer
RIOM	Radiation-induced oral mucositis
QoL	Quality of life
ROS	Reactive oxygen species
NF-κB	Nuclear factor kappa B
TNF-α	Tumor necrosis factor alpha,
IL-1β	Interleukin-1 beta
IL-6	Interleukin6
EPA	Eicosapentaenoic acid
DHA	Docosahexaenoic acid
SPMs	Pro-resolving mediators
RAS	Recurrent aphthous stomatitis
NE	Nanoemulsion

Acknowledgements

The authors would like to show grateful recognition to Dr Hossam Elsabagh and Dr Farida Reyad (Oral Medicine, Periodontology, Oral Diagnosis, and Oral Radiology Department, Alexandria University) for their contribution in the professional writing. The authors are indebted to Dr Mahmoud Khodir (Oral and Maxillofacial Surgery Department, Alexandria University) for their contribution in the patients' dental care. The authors received no financial support.

Author contributions

BMM contributed to research idea, study design, dataacquisition, and interpretation, drafted and critically revised the manuscript.SD contributed to study design, data interpretation, and critically revised the manuscript. MAMM contributed to study design, patients' selection, data analysis and critically revised the manuscript. LAH made the Omega-3 gel formulation and characterization and critically revised the manuscript. MAM contributed to the microbiological part of the study and critically revised the manuscript. NMA made the statistical work and critically revised the manuscript. All authors reviewed the manuscript.

Funding

The authors did not receive any funding for this study.
Open access funding provided by The Science, Technology & Innovation Funding Authority (STDF) in cooperation with The Egyptian Knowledge Bank (EKB).

Data Availability

All data included in this study are available from the corresponding author upon request.

Declarations

Ethics approval and consent to participate

Ethical approval for the study was obtained from the Research Ethics Committee at the Faculty of Dentistry, Alexandria University (IRB 00010556)-(IORG 0008839). A detailed informed consent was provided by each patient.

Consent for publication

Not applicable.

Competing interest

The authors declare they have no conflict of interest.

Author details

[1]Oral Medicine, Periodontology, Oral Diagnosis, and Oral Radiology Department, Faculty of Dentistry, Alexandria University, Champolion St, 21527 Alexandria Governorate, Egypt
[2]Clinical Oncology and Nuclear Medicine Department, Faculty of Medicine, Alexandria University, Alexandria Governorate, Egypt
[3]Department of Pharmaceutics, Faculty of Pharmacy, Alexandria University, Alexandria Governorate, Egypt
[4]Medical Microbiology and Immunology Department, Faculty of Medicine, Alexandria University, Alexandria Governorate, Egypt
[5]Pediatric Dentistry and Dental Public Health Department, Faculty of Dentistry, Alexandria University, Alexandria Governorate, Egypt

Received: 16 February 2023 / Accepted: 31 July 2023
Published online: 30 August 2023

References

1. Zhu XX, Yang XJ, Chao YL, Zheng HM, Sheng HF, Liu HY, et al. The potential effect of oral microbiota in the prediction of Mucositis during Radiotherapy for nasopharyngeal carcinoma. EBioMedicine. 2017;18:23–31.
2. Bakr IS, Zaki AM, El-Moslemany RM, Elsaka RO. Vitamin D oral gel for prevention of radiation-induced oral mucositis: a randomized clinical trial. Oral Dis. 2020;:odi13650.
3. Reyes-Gibby CC, Wang J, Zhang L, Peterson CB, Do K, Jenq RR, et al. Oral microbiome and onset of oral mucositis in patients with squamous cell carcinoma of the head and neck. Cancer. 2020;126:5124–36.
4. Maria OM, Eliopoulos N, Muanza T. Radiation-Induced Oral Mucositis. Front Oncol. 2017;7 MAY:1.
5. Huang CJ, Huang MY, Fang PT, Chen F, Wang YT, Chen CH, et al. Randomized double-blind, placebo-controlled trial evaluating oral glutamine on radiation-induced oral mucositis and dermatitis in head and neck cancer patients. Am J Clin Nutr. 2019;109:615–25.
6. Mallick S, Benson R, Rath GK. Radiation induced oral mucositis: a review of current literature on prevention and management. Eur Arch Otorhinolaryngol. 2016;273:2285–93.
7. Kusiak A, Alicjajereczek-Fossa B, Cichońska D, Alterio D. Oncological-therapy related oral mucositis as an interdisciplinary problem—literature review. Int J Environ Res Public Health. 2020;17.
8. Elsabagh HH, Moussa E, Mahmoud SA, Elsaka RO, Abdelrahman H. Efficacy of melatonin in prevention of radiation-induced oral mucositis: a randomized clinical trial. Oral Dis. 2020;26:566–72.
9. Gugnacki P, Sierko E. Is there an interplay between oral Microbiome, Head and Neck Carcinoma and Radiation-Induced oral mucositis? Cancers (Basel). 2021;13:5902.
10. Ingrosso G, Saldi S, Marani S, Wong AYW, Bertelli M, Aristei C, et al. Breakdown of symbiosis in radiation-induced oral mucositis. J Fungi. 2021;7:1–14.
11. Al-Qadami G, Van Sebille Y, Bowen J, Wardill H. Oral-gut Microbiome Axis in the pathogenesis of Cancer Treatment-Induced oral mucositis. Front Oral Heal. 2022;3 March.
12. Vesty A, Gear K, Biswas K, Wagner Mackenzie B, Taylor MW, Douglas RG. Oral microbial influences on oral mucositis during radiotherapy treatment of head and neck cancer. Support Care Cancer. 2020;28:2683–91.
13. Saunders DP, Epstein JB, Elad S, Allemano J, Bossi P, Van De Wetering MD, et al. Systematic review of antimicrobials, mucosal coating agents, anesthetics, and analgesics for the management of oral mucositis in cancer patients. Support Care Cancer. 2013;21:3191–207.
14. Elad S, Cheng KKF, Lalla RV, Yarom N, Hong C, Logan RM, et al. MASCC/ISOO clinical practice guidelines for the management of mucositis secondary to cancer therapy. Cancer. 2020;126:4423–31.
15. Colella G, Boschetti CE, Vitagliano R, Colella C, Jiao L, King-Smith N, et al. Interventions for the Prevention of oral mucositis in patients receiving Cancer Treatment: evidence from Randomised controlled trials. Curr Oncol. 2023;30:967–80.
16. Reyad FA, Elsayed NM, El Chazli Y. Photobiomodulation for chemotherapy-induced oral mucositis in leukemic children: a randomized controlled clinical trial. Oral Dis. 2022;January:1–9.
17. Lalla RV. Evidence-based management of oral mucositis. J Oncol Pract. 2020;16:111–2.
18. Brown TJ, Gupta A. Management of cancer therapy-associated oral mucositis. J Oncol Pract. 2020;16:103–9.
19. Oshvandi K, Vafaei SY, Kamallan SR, Khazaei S, Ranjbar H, Mohammadi F. Effectiveness of zinc chloride mouthwashes on oral mucositis and weight of patients with cancer undergoing chemotherapy. BMC Oral Health. 2021;21.
20. Shahidi F, Ambigaipalan P. Omega-3 polyunsaturated fatty acids and their health benefits. Annu Rev Food Sci Technol. 2018;9:345–81.
21. Li X, Bi X, Wang S, Zhang Z, Li F, Zhao AZ. Therapeutic potential of ω-3 polyunsaturated fatty acids in human autoimmune diseases. Frontiers in Immunology. 2019;10 SEP:2241.
22. Costantini L, Molinari R, Farinon B, Merendino N. Impact of omega-3 fatty acids on the gut microbiota. Int J Mol Sci. 2017;18.
23. Kris-Etherton PM, Harris WS, Appel LJ. Omega-3 fatty acids and cardiovascular disease: new recommendations from the American Heart Association. Arterioscler Thromb Vasc Biol. 2003;23:151–2.
24. Wei L, Wu Z, Chen YQ. Multi-targeted therapy of cancer by omega-3 fatty acids-an update. Cancer Lett. 2022;526:193–204.
25. de Aguiar Pastore Silva J, Emilia de Souza Fabre M, Waitzberg DL. Omega-3 supplements for patients in chemotherapy and/or radiotherapy: a systematic review. Clin Nutr. 2015;34:359–66.
26. de Castro GS, Andrade MF, Pinto FCS, Faiad JZ, Seelaender M. Omega-3 fatty acid supplementation and its impact on systemic inflammation and body weight in patients with Cancer Cachexia—A systematic review and Meta-analysis. Front Nutr. 2022;8:1–11.
27. Zhang Y, Zhang B, Dong L, Chang P. Potential of Omega-3 polyunsaturated fatty acids in managing chemotherapy- or Radiotherapy-Related intestinal microbial dysbiosis. Adv Nutr. 2019;10:133–47.
28. Basha S, ElRefai SM, Moussa M. Assessment of the topical and systemic Effects of Omega-3 on oral mucosal wound healing in albino rats: a histopathological and biochemical study. Madridge J Case Reports Stud. 2018;2:26–31.
29. Rousseau G. Microbiota, a New Playground for the Omega-3 polyunsaturated fatty acids in Cardiovascular Diseases. Mar Drugs. 2021;19:54.
30. Giacobbe J, Benoiton B, Zunszain P, Pariante CM, Borsini A. The anti-inflammatory role of Omega-3 polyunsaturated fatty acids metabolites in Pre-Clinical Models of Psychiatric, neurodegenerative, and neurological Disorders. Front Psychiatry. 2020;11 February.
31. Serafini MM, Catanzaro M, Fagiani F, Simoni E, Caporaso R, Dacrema M, et al. Modulation of Keap1/Nrf2/ARE signaling pathway by Curcuma- and garlic-derived hybrids. Front Pharmacol. 2020;10:1597.
32. Hashemipour MA, Ghasemi AR, Dogaheh MA, Torabi M. Effects of locally and systemically Applied n-3 fatty acid on oral ulcer recovery process in rats. Wounds a Compend Clin Res Pract; 2012.
33. Huhmann R, Mueller RS. A cream containing omega-3-fatty acids, humectants and emollients as an aid in the treatment of equine Culicoides hypersensitivity. Vet Dermatol. 2019;30.
34. Maybodi FR, Fakhari M, Tavakoli F. Effects of omega-3 supplementation as an adjunct to non-surgical periodontal therapy on periodontal parameters in periodontitis patients: a randomized clinical trial. BMC Oral Health. 2022;22:1–7.
35. Azuma MM, Cardoso C, de Silva BM, Oliveira CC, Jacinto PHC, de Andrada R. AC, The use of omega-3 fatty acids in the treatment of oral diseases. Oral Dis. 2020;:odi13667.
36. Xia D-N, Tan Y-Q, Yang J-Y, Zhou G. Omega-3 polyunsaturated fatty acids: a promising approach for the management of oral lichen planus. Inflamm Res. 2020;69:989–99.
37. Miller LM, Piccinin FB, van der Velden U, Gomes SC. The impact of Omega-3 supplements on non-surgical Periodontal Therapy: a systematic review. Nutrients. 2022;14:1–14.
38. Raizada MK, Sable DM. Clinical Assessment of Efficacy of Omega 3 in oral Submucous Fibrosis Patients - A Randomized Controlled Trial. Asian Pac J Cancer Prev. 2022;23:1185–92.
39. El Khouli AM, El-Gendy EA. Efficacy of omega-3 in treatment of recurrent aphthous stomatitis and improvement of quality of life: a randomized, double-blind, placebo-controlled study. Oral Surg Oral Med Oral Pathol Oral Radiol. 2014;117:191–6.
40. Hashemipour MA, Barzegari S, Kakoie SAR. Effects of Omega-3 fatty acids against chemotherapy-induced Mucositis: a double-blind Randomized Clinical Trial. Wounds a Compend Clin Res Pract. 2017.
41. Association WM. World Medical Association Declaration of Helsinki: ethical principles for Medical Research Involving human subjects. JAMA. 2013;310:2191–4.
42. Musha A, Shimada H, Shirai K, Saitoh J-I, Yokoo S, Chikamatsu K et al. Prediction of Acute Radiation Mucositis using an oral mucosal dose surface model in Carbon Ion Radiotherapy for Head and Neck Tumors the OMDS-model was useful for predicting the location and severity of ARM. Maximum point doses in the model correlated well with grade 2–3 ARM. 2015. https://doi.org/10.1371/journal.pone.0141734.
43. Gussgard AM, Hope AJ, Jokstad A, Tenenbaum H, Wood R. Assessment of cancer therapy-induced oral mucositis using a patient-reported oral mucositis experience questionnaire. PLoS ONE. 2014;9.
44. GREENE JC. VJR. THE SIMPLIFIED ORAL HYGIENE INDEX. J Am Dent Assoc. 1939;68:7–13.
45. Mark AM. Oral care during cancer treatment. J Am Dent Assoc. 2019;150:82.
46. Hadian Z, Moghadamnia AA, Kazemi S, Shirzad A. Effect of Omega-3 on recurrent Aphthous Stomatitis and Improvement Quality of Life. 2021. https://doi.org/10.1155/2021/6617575.

47. Faul F, Erdfelder E, Lang AGBA. G*Power 3: a flexible statistical power analysis program for the social, behavioral, and biomedical sciences. Behav Res Methods. 2007;39:175–91.
48. No Title.
49. McHugh ML. Interrater reliability: the kappa statistic. Biochem Med. 2012;22.
50. Donthi MR, Munnangi SR, Krishna KV, Saha RN, Singhvi G, Dubey SK. Nanoemulgel: a Novel Nano Carrier as a Tool for Topical Drug Delivery. Pharmaceutics. 2023;15:1–28.
51. Alyami MH, Alyami HS, Alshehri AA, Alsharif WK, Shaikh IA, Algahtani TS. Tamoxifen citrate containing topical Nanoemulgel prepared by Ultrasonication technique: Formulation Design and in Vitro evaluation. Gels. 2022;8.
52. Pereira GG, Rawling T, Pozzoli M, Pazderka C, Chen Y, Dunstan CR et al. Nanoemulsion-enabled oral delivery of novel anticancer ω-3 fatty acid derivatives. Nanomaterials. 2018;8.
53. Ochoa AA, Hernández-Becerra JA, Cavazos-Garduño A, Vernon-Carter EJ, GarcÍa HS. Preparation and characterization of curcumin nanoemulsions obtained by thin-film hydration emulsification and ultrasonication methods. Rev Mex Ing Quim. 2016;15.
54. Choi SW, Pangeni R, Park JW. Nanoemulsion-based hydrogel for topical delivery of highly skin-permeable growth factor combinations: Preparation and in vitro evaluation. J Nanosci Nanotechnol. 2017;17.
55. McGuire DB, Correa ME, Johnson J, Wienandts P. The role of basic oral care and good clinical practice principles in the management of oral mucositis. Support Care Cancer. 2006;14:541–7.
56. Henneicke-von Zepelin HH, Mrowietz U, Färber L, Bruck-Borchers K, Schober C, Huber J, Lutz G, Kohnen R, Christophers E, Welzel D. Highly purified omega-3-polyunsaturated fatty acids for topical treatment of psoriasis. Results of a double-blind, placebo-controlled multicentre study. Br J Dermatol. 1993;129:713–7.
57. Ramesh G, Das UN. Effect of evening primrose and fish oils on two stage skin carcinogenesis in mice. Prostaglandins Leukot Essent Fatty Acids. 1998;59:155–61.
58. Huang T-H, Wang P-W, Yang S-C, Chou W-L, Fang J-Y. Cosmetic and therapeutic applications of Fish Oil's fatty acids on the skin. Mar Drugs. 2018;16:256.
59. Sroussi HY, Epstein JB, Bensadoun RJ, Saunders DP, Lalla RV, Migliorati CA, et al. Common oral complications of head and neck cancer radiation therapy: mucositis, infections, saliva change, fibrosis, sensory dysfunctions, dental caries, periodontal disease, and osteoradionecrosis. Cancer Med. 2017;6:2918–31.
60. WHO. Handbook for reporting results of cancer treatment. 1979;:15–22.
61. Lalla RV, Sonis ST, Peterson DE. Management of oral mucositis in patients who have Cancer. Dent Clin North Am. 2008;52.
62. Scott J, Huskisson EC. Graphic representation of pain. Pain. 1976;2:175–84.
63. McCormack HM, Horne DJ, Sheather S. Clinical applications of visual analogue scales: a critical review. Psychol Med. 1988;18:1007–19.
64. Rosenthal DI, Mendoza TR, Chambers MS, Burkett VS, Garden AS, Hessell AC, Lewin JS, Ang KK, Kies MS, Gning I, Wang XS, Cleeland CS. The M. D. Anderson symptom inventory-head and neck module, a patient-reported outcome instrument, accurately predicts the severity of radiation-induced mucositis. Int J Radiat Oncol Biol Phys. 2008;72:1355–61.
65. Nejmi M, Wang XS, Mendoza TR, Gning I, Cleeland CS. Validation and application of the Arabic Version of the M. D. Anderson Symptom Inventory in moroccan patients with Cancer. J Pain Symptom Manage. 2010;40:75–86.
66. Ahmed SAS, Elhefnawy AM, Azouz HG, Roshdy YS, Ashry MH, Ibrahim AE et al. Study of the gut Microbiome Profile in Children with Autism Spectrum Disorder: a single Tertiary Hospital Experience. J Mol Neurosci. 2020;70.
67. Yu M, Kim J, Ahn JH, Moon Y. Nononcogenic restoration of the intestinal barrier by E. coli-delivered human EGF. JCI Insight. 2019;4.
68. Yang YW, Chen MK, Yang BY, Huang XJ, Zhang XR, He LQ et al. Use of 16S rRNA gene-targeted group-specific primers for real-time PCR analysis of predominant bacteria in mouse feces. Appl Environ Microbiol. 2015;81.
69. Zhou X, Liu X, Li J, Aprecio RM, Zhang W, Li Y. Real-time PCR quantification of six periodontal pathogens in saliva samples from healthy young adults. Clin Oral Investig. 2015;19.
70. Mohieldeen K, Hamoda SAF, Ahmed SM, Najeeb A, Ellakany WI. Gut microbiome in cirrhotic hepatitis C virus patients with and without hepatocellular carcinoma. Egypt Liver J. 2021;11.
71. Liu S, Zhao Q, Zheng Z, Liu Z, Meng L, Dong L et al. Status of treatment and Prophylaxis for Radiation-Induced oral mucositis in patients with Head and Neck Cancer. Front Oncol. 2021;11.
72. Lessa RC, Alves F, de Fortunati A, Lu E. J. Oral mucositis in cancer and potential use of omega-3 free fatty acids in its management: a review. Biomedicines. 2021;9.
73. Xiao K, Liu C, Qin Q, Zhang Y, Wang X, Zhang J, et al. EPA and DHA attenuate deoxynivalenol-induced intestinal porcine epithelial cell injury and protect barrier function integrity by inhibiting necroptosis signaling pathway. FASEB J. 2020;34:2483–96.
74. Vidyasagar N, Manur Gururajachar J. Predicting toxicity for head and neck cancer patients undergoing radiation therapy: an independent and external validation of MDASI-HN based nomogram. Rep Pract Oncol Radiother. 2020;25.
75. Viganò A, De Felice F, Iacovelli NA, Alterio D, Facchinetti N, Oneta O et al. M. D. Anderson symptom inventory head neck (MDASI-HN) questionnaire: italian language psychometric validation in head and neck cancer patients treated with radiotherapy ± systemic therapy – a study of the Italian Association of Radiotherapy and Clinical Oncology (AIRO). Oral Oncol. 2021;115.
76. Barker CL, Price GJ, Lee LW, McPartlin A, Baseline MD. Anderson Symptom Inventory score is strongly Associated with patient-reported Acute and late toxicity following (Chemo) Radiotherapy for Head and Neck cancers. Clin Oncol. 2022;34:683–9.
77. Lopez-Vaquero D, Gutierrez-Bayard L, Rodriguez-Ruiz J-A, Saldaña-Valderas M, Infante-Cossio P. Double-blind randomized study of oral glutamine on the management of radio/chemotherapy-induced mucositis and dermatitis in head and neck cancer. Mol Clin Oncol. 2017;6.
78. Laheij AMGA, Raber-Durlacher JE, Koppelmans RGA, Huysmans MCDNJM, Potting C, van Leeuwen SJM et al. Microbial changes in relation to oral mucositis in autologous hematopoietic stem cell transplantation recipients. Sci Rep. 2019;9.
79. Xia C, Jiang C, Li W, Wei J, Hong H, Li J et al. A phase II randomized clinical trial and mechanistic studies using Improved Probiotics to prevent oral Mucositis Induced by Concurrent Radiotherapy and Chemotherapy in Nasopharyngeal Carcinoma. Front Immunol. 2021;12.
80. Jiang R, Liu Y, Zhang H, Chen Y, Liu T, Zeng J et al. Distinctive microbiota of delayed healing of oral mucositis after radiotherapy of nasopharyngeal carcinoma. Front Cell Infect Microbiol. 2022;12.
81. Ye Y, Carlsson G, Agholme MB, Wilson JAL, Roos A, Henriques-Normark B et al. Oral bacterial community dynamics in paediatric patients with malignancies in relation to chemotherapy-related oral mucositis: a prospective study. Clin Microbiol Infect. 2013;19.
82. Kumar M, Pal N, Sharma P, Kumawat M, Sarma DK, Nabi B et al. Omega-3 fatty acids and their Interaction with the gut microbiome in the Prevention and Amelioration of Type-2 diabetes. Nutrients. 2022;14.
83. Fu Y, Wang Y, Gao H, Li D, Jiang R, Ge L et al. Associations among Dietary Omega-3 Polyunsaturated Fatty Acids, the Gut Microbiota, and Intestinal Immunity. Mediators Inflamm. 2021;2021.
84. Olivia Maurine Jasirwan C, Muradi A, Hasan I, Simadibrata M, Rinaldi I. Correlation of gut Firmicutes/Bacteroidetes ratio with fibrosis and steatosis stratified by body mass index in patients with non-alcoholic fatty liver disease. Biosci Microbiota, Food Heal. 2020;40.
85. Balfegò M, Canivell S, Hanzu FA, Sala-Vila A, Martínez-Medina M, Murillo S et al. Effects of sardine-enriched diet on metabolic control, inflammation and gut microbiota in drug-naïve patients with type 2 diabetes: a pilot randomized trial. Lipids Health Dis. 2016;15.
86. Yu HN, Zhu J, Pan W, sheng, Shen SR, Shan WG, Das UN. Effects of Fish Oil with a high content of n-3 polyunsaturated fatty acids on mouse gut microbiota. Arch Med Res. 2014;45.

Publisher's Note

Springer Nature remains neutral with regard to jurisdictional claims in published maps and institutional affiliations.