



Surgical Treatment for Spasticity: Selective Dorsal Rhizotomy – Technique and Literature Review

Tratamento cirúrgico para espasticidade: Rizotomia dorsal seletiva – Técnica e revisão da literatura

Marcos Paulo dos Santos Teixeira¹ Bernardo Assumpção de Monaco² Jessie Medeiros de Navarro³
Emmanuel Alejandro Vazquez⁴ Arthur José Maia Lopes⁵ Thais Cristina de Souza Melo⁶
Manoel Jacobsen Teixeira⁷

¹Foundation of Beneficence, Hospital de Cirurgia, Aracaju, SE, Brazil

²Department of Neurosurgery, Hospital das Clínicas, Faculty of Medicine, Universidade de São Paulo, São Paulo, SP, Brazil

³Department of Neurophysiology, Hospital das Clínicas, Faculty of Medicine, Universidade de São Paulo, São Paulo, SP, Brazil

⁴Department of Neurosurgery, Hospital Aleman de Bueno Aires, Argentina; Hospital das Clínicas, Faculty of Medicine, University of São Paulo, São Paulo, SP, Brazil

⁵Neurosurgery Residency, Faculty of Medicine, University of São Paulo, São Paulo, SP, Brazil

⁶Medical School Graduation, Universidade Federal de Sergipe, Aracaju, SE, Brazil

⁷Neurosurgery Discipline, Hospital das Clínicas, Faculty of Medicine, University of São Paulo, São Paulo, SP, Brazil

Address for correspondence Marcos Paulo dos Santos Teixeira, MD, Fundação de Beneficência Hospital de Cirurgia, Av. General Djenal Tavares de Queiroz, 310, apto 502, Luzia, Aracaju, Sergipe, Brazil (e-mail: marcosp_med@hotmail.com).

Arq Bras Neurocir 2021;40(3):e238–e244.

Abstract

Spasticity is a motor disorder that leads to a resistance to passive joint movement. Cerebral palsy is the most important cause of spasticity and can be caused by several factors, including multiple gestations, alcoholism, infections, hemorrhages, drowning, and traumatic brain injuries, among others. There are many scales that help to measure and monitor the degree of impairment of these patients. The initial treatment should focus on the causal factor, such as tumors, inflammation, degenerative diseases, hydrocephalus, etc. Subsequently, the treatment of spastic musculature includes oral or intrathecal myorelaxants, spinal cord electrostimulation, neurotomies, Lissauer tract lesion, dentatotomy and selective dorsal rhizotomy. The latter is a safe technique, possible to be performed in most centers with neurosurgical support, and it is effective in the treatment of severe spasticity. In this article, the authors describe the surgical technique and conduct a review the literature.

Keywords

- ▶ spasticity
- ▶ rhizotomy
- ▶ cerebral palsy
- ▶ electrical stimulation
- ▶ surgery

Resumo

A espasticidade é um distúrbio motor que leva a um quadro de resistência ao movimento articular passivo. A paralisia cerebral é a mais importante causa de espasticidade e pode ser causada por diversos fatores, tais como gestações múltiplas, alcoolismo, infecções, hemorragias, afogamento, lesões cerebrais traumáticas, entre

received
October 27, 2017
accepted
December 4, 2017
published online
May 10, 2018

DOI <https://doi.org/10.1055/s-0038-1623514>.
ISSN 0103-5355.

© 2018. Sociedade Brasileira de Neurocirurgia. All rights reserved. This is an open access article published by Thieme under the terms of the Creative Commons Attribution-NonDerivative-NonCommercial-License, permitting copying and reproduction so long as the original work is given appropriate credit. Contents may not be used for commercial purposes, or adapted, remixed, transformed or built upon. (<https://creativecommons.org/licenses/by-nc-nd/4.0/>)
Thieme Revinter Publicações Ltda., Rua do Matoso 170, Rio de Janeiro, RJ, CEP 20270-135, Brazil

Palavras-chave

- espasticidade
- rizotomia
- paralisia cerebral
- monitorização intraoperatória
- cirurgia

outros. Existem muitas escalas que ajudam a mensurar e acompanhar o grau de acometimento desses pacientes. O tratamento inicial deve focar no fator causal, como tumores, inflamação, doenças degenerativas, hidrocefalia etc. Posteriormente, o tratamento da musculatura espástica inclui miorrelaxantes orais, intratecais, eletroestimulação medular, neurtomias, lesão do trato de Lissauer, dentatotomia e a rizotomia dorsal seletiva. Esta última é uma técnica segura, possível de ser realizada na maioria dos centros com suporte neurocirúrgico, e eficaz no tratamento da espasticidade grave. No presente, artigo, os autores descrevem a técnica cirúrgica e fazem uma revisão da literatura.

Introduction

Spasticity is a motor disorder characterized by increased muscle tone, leading to a frame of resistance to passive articular movement. In the clinical practice, spasticity is one of the positive signs of upper motor neuron syndrome, which may be accompanied by stiffness, hyperreflexia, primitive reflexes, hypertonia of antigravitary muscles, increased reflexogenic areas, bladder hyperreflexia and clasp knife spasticity. Negative signs can also accompany the clinic examination in these patients, such as paresis, incoordination, fatigue, reduction of tissue elasticity, among others. These signs, under extreme conditions, impair posture, ambulation and self-care. As a direct consequence, we can cite pain, fractures and decubitus ulcers. The worsening of these patients also worsens the quality of life of their respective caregivers. However, the degree of spasticity may help some patients in the maintenance of posture and gait.

Cerebral palsy (CP) is considered one of the most important causes of spasticity, especially in children in whom, when associated with other symptoms such as dystonia, ataxia or stiffness, it leads to a serious disability condition. Even with the advances in care in the neonatal period, an increase in the incidence of CP cases has been observed, which may be related to an increase in the survival of children with very low weight.^{1,2}

Etiologically, CP is associated with prenatal events (multiple pregnancies, maternal alcoholism, infections), perina-

tals (hemorrhages, infections, bradycardia, fetal anoxia) and postnatal (drowning, traumatic brain injury, among others).³

To objectively evaluate spasticity, we use quantitative and qualitative indicators that measure the degree and functional repercussion of patients.

The modified Ashworth scale is the most widely used to assess muscle tone. It is a qualitative scale that evaluates the degree of spasticity, measured according to the degree of resistance to passive movement of a segment moved rapidly by an examiner⁴ (► **Table 1**). The Penn scale, also widely used in the clinical practice, evaluates the occurrence of spasms (► **Table 1**).

The Tardieu scale measures the intensity of the muscular reaction to passive movement. The arc of motion should be measured by a goniometer. The angle of resistance is the measure relative to the position of minimum stretch for all joints. It is a good option to evaluate the gain after treatment (► **Table 2**).

Gait can be used to evaluate the improvement of spasticity, either in clinical observation or in the gait laboratory using dynamic electromyography (EMG).⁵

Other tests are also used, such as upper limb skill tests and dynamometry hold,⁶ measurement of functional independence, Barthel index (quantitative method that evaluates independence in daily activities), quantitative muscle strength and myometrial tests,⁷ and the Lyon Université scale, which evaluates automatisms.⁸ Initially, spasticity treatment should focus on the causal factor, be it tumor,

Table 1 Modified Ashworth Scale and Penn Scale

Modified Ashworth Scale		Penn Scale
Degree	Description	Description
0	Normal muscular tonus	Absence of spasms
1	Increase in tone at the beginning or end of the arc of motion	Only spasms precipitated by stimuli
1+	Increased tonus in less than half of the arc of motion, manifested by abrupt tension and followed by minimal resistance	
2	Increased tonus in more than half of the arc of motion, but the affected part is easily mobilized	Spontaneous, strong and irregular spasms, less than one per hour
3	Considerable increase in muscle tone with difficult passive movement	Spontaneous spasms, one or more per hour
4	Rigid parts in flexion or extension	Spontaneous spasms, more than ten per hour

Table 2 Tardieu Scale

Modified Tardieu Scale	
Degree	Description
0	No resistance in the course of passive movement
1	A slight resistance along the course of the passive movement, without precision of the specific angle
2	Clear stiffness at a specific angle, interrupting the stretch, followed by relaxation.
3	Fatigable Clin that lasts less than 10 seconds and appears at a specific angle, while the evaluator is maintaining pressure.
4	Non-fatigable Clin that lasts for more than 10 seconds and appears at a specific angle while the evaluator is maintaining pressure.

inflammation, multiple sclerosis, infectious disease, vascular disease, degenerative disease, hydrocephalus, etc. It is mandatory to prevent or eliminate factors that aggravate spasticity, such as pain, visceral dysfunctions, decubitus ulcers, urinary infections, constipation, heterotopic ossification, ingrown nail, psychological stress and sleep disorders.

Neurosurgical treatment of spasticity is diverse. Intrathecal infusion of myorelaxants, such as baclofen, tizanidine, midazolam, clonidine or morphine, is indicated in patients with preserved motor function and when oral medication is not tolerated or effective. Spinal cord stimulation is an option in mildest cases. Nerve neurotomies such as shutter, sciatic, posterior tibial, fibular or femoral – in the lower limbs – and musculocutaneous, radial or median in the upper limbs, are options for more localized spasticity.

Percutaneous radiofrequency rhizotomy is used in debilitated patients and in the treatment of spastic bladder. The longitudinal myelotomy (longitudinal section of the spinal cord gray matter) is reserved for paraplegics with total impairment of sexual and sphincter function. The lesion of the Lissauer tract and the posterior horn of the spinal cord, proposed by Sindou in 1969, is used in the treatment of spasticity and pain in the lower limbs.⁹ Dentatotomy is efficient in the treatment of spasticity evidenced by several casuistics.¹⁰ A selective dorsal rhizotomy (SDR) is a safe, economical and possible technique to be performed in most centers with neurosurgical support, especially pediatric. It is an excellent option in cases of ambulatory patients and quadripastic children.

Patient Selection

Up to the present moment, there are no completely efficient measures to repair the damage to motor areas that control movement. We have several therapeutic measures for the treatment of spasticity, which include: drug therapy, physical therapy, occupational therapy, applications of botulinum toxin, orthopedic surgery, SDR, in addition to the surgical procedures already explained. The choice for the use of these

therapies is extremely important for the patient, since victims of polytraumatism are usually young with long survival, and that children with CP have a mean survival of 20 years.¹¹

Selective dorsal rhizotomy is a definitive surgery in which the cauda equina is exposed through osteoplastic laminotomy followed by L2-S1 roots identification.

The results of dorsal rhizotomy have been known since the initial experiments of Sherrington (1894) in decerebrated cats. In 1889, Abbe and Bennett described the result of nerve root section with pain control.^{1,13} In 1913, Foerster achieved improvement in spasticity after dorsal rhizotomy was performed.¹⁴ Despite good results, dorsal rhizotomy was abandoned for about half a century, due to the comorbidities related to the procedure. Only in 1960s, Gros et al performed partial rhizotomies EMG to help identify dysfunctional nerves.¹⁵ Fasano et al described the criteria for evaluating abnormal motor responses after electrical nerve stimulation.¹⁶ The traditional surgery proposed by Peacock et al consists of a laminotomy from L1 to L5 with a laminectomy of S1-S2.¹⁷ In many services, the level of the approach is varied, including lumbar topographies or medullary cone (MC), aiming to maintain a balance between the preservation of strength and the elimination of spasticity.³

The use of electromyography (EMG) to define which dorsal roots were injured also became a reason for discussion due to the variability of the motor response,¹⁸ of the standardization of the technique used in each center,¹⁹ the use of drugs used in anesthetic induction that may interfere with the results of stimulation,²⁰ and the variability of segmental innervation of the musculature of the lower limbs.²¹ One study performed a histological analysis of the sectioned roots of children with CP submitted to SDR, and found that the altered roots in the EMG presented axonal degeneration or demyelination. The roots that appeared normal in the EMG presented minimal histological alterations limited to myelin sheath or demyelination without axonal degeneration, showing that this is a significant method to find the roots that should be sectioned.²²

Spastic patients present contractions sustained at a stimulation of 50 Hz, but did not present the same contralateral pattern.²¹ We have observed in daily practice that a stimulation of 5 Hz is enough to differentiate the motor and sensitive roots. Intraoperative EMG is essential in the identification of the hyperactive roots, contributing to a balance between the reduction of spasticity, bladder control and the preservation of sensitivity.

Studies have shown that SDR is accompanied by significant improvement in several parameters, for example, improvement in motor function,²³⁻²⁵ significant spasticity reduction,²⁶ strength gain,²⁷ increase in movement amplitude,^{28,29} and qualitative³⁰ and quantitative.^{31,32} improvements in the upper limbs motor function. Some services use strict criteria to indicate SDR, including the Reimer index, which, when > 50%, can postpone SDR for a period of 6 to 12 months.³ However, early dorsal rhizotomy would prevent a posterior approach in soft tissues and articular joints.³³

In the end of the 1980s, the main concern with intraoperative complications was the risk of bronchospasm and

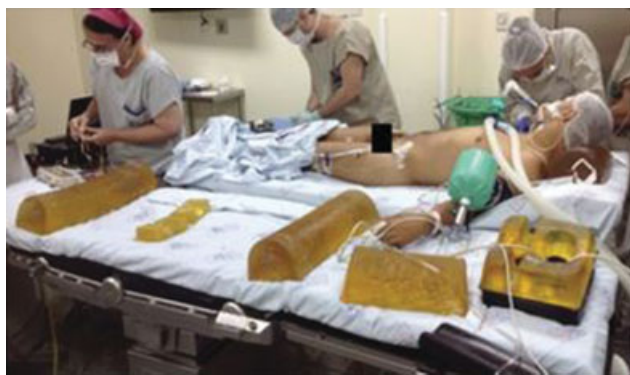

Fig. 1 Patient intubated on a side stretcher at the surgical table. Appropriate cushions are positioned to avoid decubitus ulcers after the patient is positioned in ventral decubitus.

aspiration pneumonia; However, with the development of new anesthetic techniques and new drugs, the risks were reduced.³⁴

Children with CP who evolve with spastic diplegia or tetraplegia, associated with an important spastic component in the lower limbs and minimal impairment in the upper limbs, are the main beneficiaries of this technique. Selective dorsal rhizotomy is not indicated for children under 2 years old because the CP cannot be safely diagnosed in this age group. Dystonia is not an absolute contraindication for surgery, but if there are lesions in basal nuclei with dystonic predominance, other procedures present better results, such as pallidotomy or deep cerebral stimulation. History of multiple orthopedic surgeries counterclaims the procedure due to fixed deformities and muscle weakness.²⁴

The main objective of SDR is the reduction of two levels in the Ashworth scale in the deprecated muscular target of the lower limbs. In 50% of the cases, there is also improvement in the upper limbs.³⁵

For a good postsurgical outcome, the patient should be duly selected. The clinical examination will define which segments are most affected by the disease and which would be the focus of the rhizotomy. A multidisciplinary team that includes physiatrist, orthopedist, neuropsychiatrician, psychologist and physical therapist is essential. Posture, sphincter control, amplitude of the articular movements,

whether there are bone or muscular deformities, presence of dystonia, dyskinesias, presence of spasms, gait observation, cognition and comorbidities should be evaluated.

Technique Description

The technique created by Park et al³⁶ in 1991 differs from the others by removing the lamina of one or two vertebrae, while traditional techniques use laminectomy from five to seven vertebrae.

The patient is sedated and intubated in dorsal decubitus on the lateral stretcher at the surgical table (► **Fig. 1**). Medications that do not alter the EMG activity, such as long-lasting neuromuscular blockers, should be avoided.

After orotracheal intubation, electrodes are introduced bilaterally in the long, large lateral, tibial anterior and medial gastrocnemius muscles (► **Fig. 2**).

Subsequently, the patient is transferred carefully to the ventral decubitus position to maintain soft structures at strategic points of the body to avoid decubitus ulcers. In this position, electrodes are introduced in the perichannel region and the wires are fixed with adhesive in the patient's lower limb (► **Fig. 3**).

We use continuous EMG and a trigger with 14 channels to stimulate the following L1-L2, L2-L3, L3-L4, L5-L5, L5-S1, S1-S2 and on-the-side segments. The interpretation of the EMG result is done by the neurophysiologist. Intraoperative EMG provides valuable information to the neurosurgeon that helps differentiate the sensory root of the motor, in addition, the mapping of the sphincter fibers is a safety factor for not adding deficits to the patient.³⁷ It is also necessary to have the utmost care with the sacral fibers of S2 to S4 to protect the bladder and sexual function.³⁸ The patient is kept in a slight position of Trendelenburg to reduce CSF losses. Radioscopy or ultrasonography (in case of children < 10 years old) is used to find the vertebral level to be approached (previously chosen through magnetic resonance imaging [MRI]) to find the MC end, and the incision is made after marking this level (► **Fig. 4**). Since laminectomy should be limited to this segment, it is important that the MC is found.

After making a horizontal incision, with the opening of the subcutaneous cell tissue, we dissected the dorsal musculature away from the thorny process until the slides of the L1 vertebra were exposed, in this example (► **Fig. 5**). After

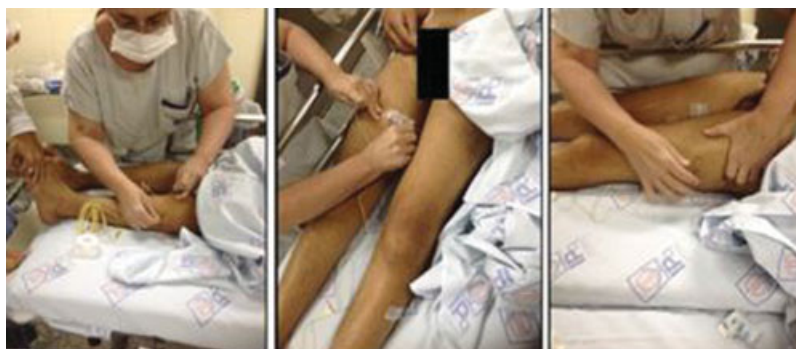

Fig. 2 Positioning of the EMG electrodes in the muscles of the lower limbs.

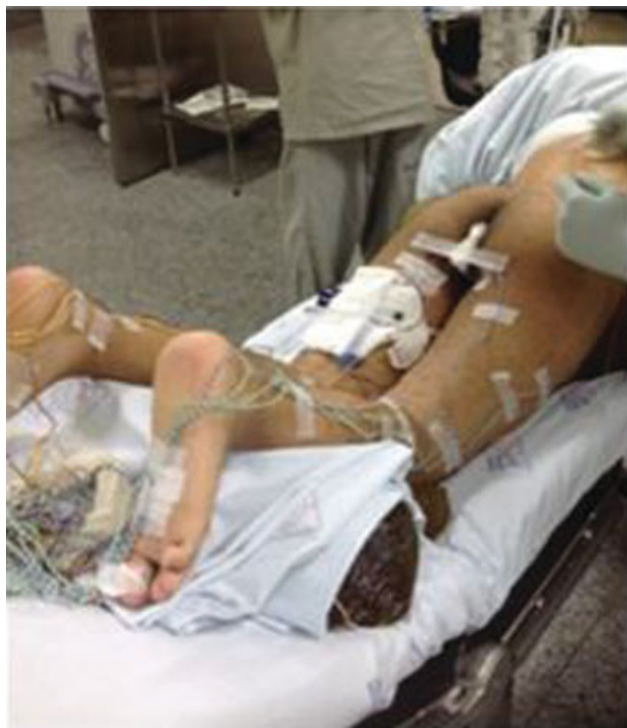

Fig. 3 Patient in ventral decubitus with electrodes positioned on the lower limbs and in the perichannel region.

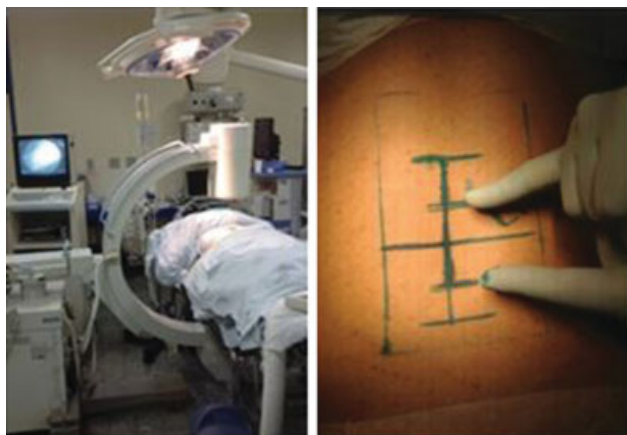

Fig. 4 Left: patient positioned in ventral decubitus at the moment radioscapy is performed to find the level of the spine that will be approached. Right: marking on the skin with the size of the incision.

exposure of the interlaminar space, the yellow ligament is removed with visualization of the dural sac. A linear incision is made to expose the medulla and visualize the MC and the cauda equina.

From this moment, saline solutions should be avoided because they alter the responses of the EMG. The edges of the dura mater are anchored with Vicryl or nylon 4.0 to keep the channel open. The first foramen of the anterior and posterior roots, lateral to the MC, is sought. The root is found, it is divided into four parts to initiate the stimulation to pulses of 0.1 thousandth of a second to a frequency of 0.5 Hz and then 50 Hz, and then identify if we are stimulating motor or sensory fibers. In spasticity, sensory fibers are hyperactive;

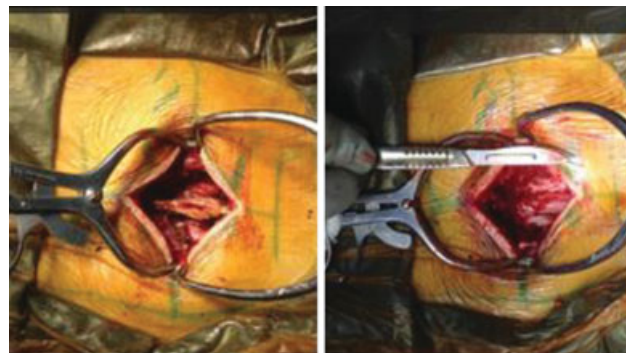

Fig. 5 Left: dorsal musculature distanced with visualization of the supraspinatus ligament and spinous process of L1. Right: after laminotomy, exposure of the dural sac to the level of the medullary cone.

In these cases, the most altered part for neurolysis is chosen, preserving those that are in better condition. By not choosing to cut the entire sensory root, it avoids the pain of deafferentation. In the Fig. 6a, we visualize the medullary dura mater at the open L1 level, exposing the MC and the cauda equina. We find the L1 sensory root and use a latex repair to separate the motor from the sensory part (►Fig. 6b). Half of the fibers in the L1 dorsal root are cut without stimulation (►Fig. 6c). In sequence, we stimulated L2 roots with EMG, isolating the sensory part and separating it into four parts. Again, we stimulate each segment to evaluate the degree of hyperactivity and recorded the electrical patterns of the related muscles. The most injured segments are sectioned.

The root that has already been cut is separated from the others with a tape or vascular shoelace, so as not to risk approaching them again (►Fig. 6d). After finding another root and separating again with repair (►Fig. 6d), we do a new stimulation and repeat the whole process (►Figs. 6e and 6f) until you approach the whole L2 S2 segment or, depending on the case, those in which the patient has more functional impairment.

The stimulation of nerve roots intraoperatively assesses the functional integrity of the nerve, since it is visually impossible for the surgeon to make this differentiation. As each root is stimulated, a motor response in the musculature of the corresponding segment is perceived, and the information of the action potential is received in the software that analyzes and records the stimuli corresponding to each root. In ►Fig. 7, we observe a graphic example of stimulation. The motor latency was 7 seconds and the sensory was 9 seconds. It shows that the L3 root is being stimulated and that the action potential has a late peak to the Yellow Line, which marks the division between motor and sensory, confirming it to be a sensory root. In the left column (in blue) the stimulations are separated into the four parts of the root. It is noted that parts 2 and 3 are more hyperactive. Therefore, these parts can be sectioned, preserving parts 1 and 4.

The advantages of this technique consist in the reduction of spinal deformity, especially in children, if compared with the extensive laminectomy in the traditional technique, improvement of spasticity in the hip, due to the section in the first lumbar dorsal root, reduced surgical access with lower muscular manipulation, and, consequently, less postoperative pain

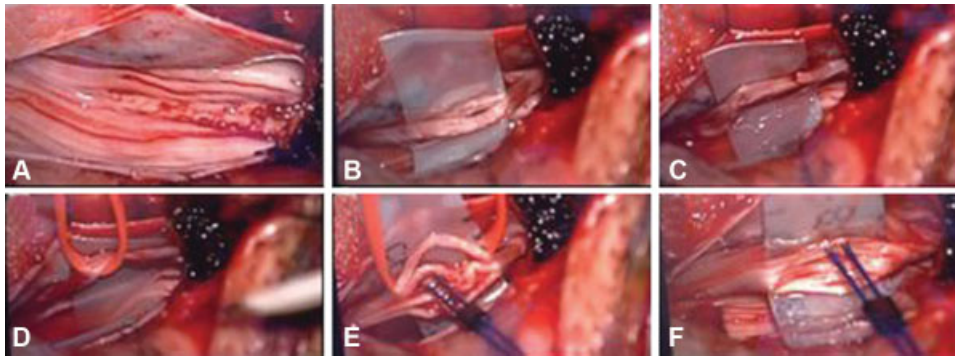


Fig. 6 Intraoperative images showing the open dura mater with visualization of the medullary cone and roots being stimulated during electromyography with bipolar configuration.

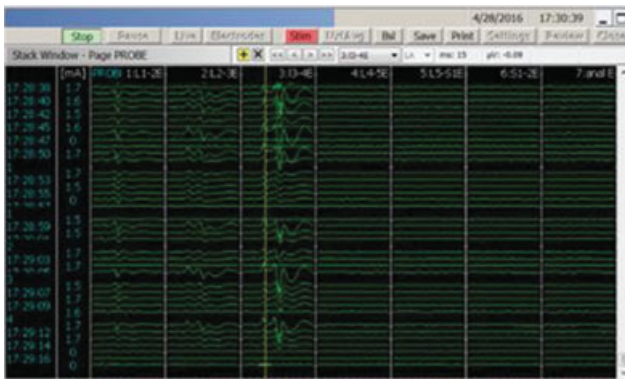


Fig. 7 Stimulation of the L3 segment. We visualize that the wave pulse is to the right of the yellow line and denotes the separation between a motor or sensory impulse. The left side (blue) shows the division of the four parts, evidencing that parts 2 and 3 of the L3 root are hyperactive and should be sectioned.

and early resumption of rehabilitation activities. However, the risks are shared with other procedures such as paraplegia, paralytic bladder, sexual impotence and sensitivity deficit.

A study that included 95 patients treated with SDR in childhood, and accompanied them for periods varying from 20 to 28 years, showed that 91% of the patients submitted to surgery reported that the surgical treatment positively impacted the quality of life. In 42% of the patients, there was improvement in ambulation, 88% would recommend the procedure for other patients and there were no late complications for these patients.³⁹

Daunter et al selected patients with CP who underwent SDR in infancy (before 10 years old) and compared them with an unoperated control group. They concluded that the SDR group presented less pain, fatigue and functional decline compared with the nonsurgical group.⁴⁰

The SDR technique by single-segment laminoplasty provides a less invasive approach, and the incidence of scoliosis after this approach is comparable with the natural history of children accompanied as outpatients.⁴¹

Conclusion

Selective dorsal rhizotomy is efficient in the treatment of severe spasticity. It is a surgery with low morbidity, and

electrophysiological stimulation has shown to be efficient in the choice of root segments that should be safely sectioned. However, for a successful treatment, the patient should be rigorously selected. In addition to the functional improvement of the spastic patients, there is an expressive improvement in the quality of life of the caregivers.

Conflicts of Interests

The authors declare that there are no conflicts of interests.

References

- 1 Rumeau-Rouquette C, Grandjean H, Cans C, du Mazaubrun C, Verrier A. Prevalence and time trends of disabilities in school-age children. *Int J Epidemiol* 1997;26(01):137–145
- 2 Kuban KCK, Leviton A. Cerebral palsy. *N Engl J Med* 1994;330(03): 188–195
- 3 Farmer JP, Sabbagh AJ. Selective dorsal rhizotomies in the treatment of spasticity related to cerebral palsy. *Childs Nerv Syst* 2007; 23(09):991–1002
- 4 Abolhasani H, Ansari NN, Naghdi S, Mansouri K, Ghotbi N, Hasson S. Comparing the validity of the Modified Modified Ashworth Scale (MMAS) and the Modified Tardieu Scale (MTS) in the assessment of wrist flexor spasticity in patients with stroke: protocol for a neurophysiological study. *BMJ Open* 2012;2(06):1136–1144
- 5 Lianza S, Koda LC. Avaliação da capacidade. In: Lianza S (editor). *Medicina de reabilitação*. 3a ed. Guanabara Koogan: Rio de Janeiro; 2001
- 6 Pierson SH. Outcome measures in spasticity management. *Muscle Nerve Suppl* 1997;6:S36–S60
- 7 Penta M, Thonnard JL, Tesio L. ABILHAND: a Rasch-built measure of manual ability. *Arch Phys Med Rehabil* 1998;79(09):1038–1042
- 8 Millet MF. Neurochirurgie dans le paraplegic spastiques. Resultats a moyen terme de la radicellotomie posterieure selective. In: Simon L (editor). *Actualites en reeducation fonctionnelle et readaptation*. Paris 1981:76–85
- 9 Sindou MP. History of the neurosurgical treatment for spasticity. *Oper Tech Neurosurg* 2004;7(03):96–99
- 10 Teixeira MJ, Fonoff ET. Surgical treatment of spasticity. *Rev Med (São Paulo)* 2004;83(1–2):17–27
- 11 Evans PM, Evans SJW, Alberman E. Cerebral palsy: why we must plan for survival. *Arch Dis Child* 1990;65(12):1329–1333
- 12 Abbe R. A Contribution to the Surgery of the Spine. *J Neurosurg* 1964;21(01):820–823 (reprint from *The Medical Record*)
- 13 Bennett WH. Acute spasmodic pain in the left lower extremity was completely relieved by sub-dural division of the posterior roots of certain spinal nerves, all other treatment having proved useless. *Med Chir Trans* 1889;72:329–348, 3

- 14 Foerster O. On the indications and results of the excision of posterior spinal nerve roots in men. *Surg Gynecol Obstet* 1913; 16:463–474
- 15 Gros C, Ouaknine G, Vlahovitch B, Frèrebeau P. [Selective posterior rhizotomy in the neurosurgical treatment of pyramidal hypertension]. *Neurochirurgie* 1967;13(04):505–518
- 16 Fasano VA, Barolat-Romana G, Ivaldi A, Sguazzi A. [Functional posterior radiculotomy, in the treatment of cerebral spasticity, peroperative electric stimulation of posterior roots and its use in the choice of the roots to be sectioned]. *Neurochirurgie* 1976;22(01):23–34
- 17 Peacock WJ, Arens LJ. Selective posterior rhizotomy for the relief of spasticity in cerebral palsy. *S Afr Med J* 1982;62(04):119–124
- 18 Warf BC, Nelson KR. The electromyographic responses to dorsal rootlet stimulation during partial dorsal rhizotomy are inconsistent. *Pediatr Neurosurg* 1996;25(01):13–19
- 19 Steinbok P, Kestle JR. Variation between centers in electrophysiologic techniques used in lumbosacral selective dorsal rhizotomy for spastic cerebral palsy. *Pediatr Neurosurg* 1996;25(05):233–239
- 20 Chabal C, Jacobson L, Little J. Effects of intrathecal fentanyl and lidocaine on somatosensory-evoked potentials, the H-reflex, and clinical responses. *Anesth Analg* 1988;67(06):509–513
- 21 Phillips LH II, Park TS. Electrophysiologic mapping of the segmental anatomy of the muscles of the lower extremity. *Muscle Nerve* 1991;14(12):1213–1218
- 22 Fukuhara T, Nakatsu D, Namba Y, Yamadori I. Histological evidence of intraoperative monitoring efficacy in selective dorsal rhizotomy. *Childs Nerv Syst* 2011;27(09):1453–1458
- 23 McLaughlin J, Bjornson K, Temkin N, et al. Selective dorsal rhizotomy: meta-analysis of three randomized controlled trials. *Dev Med Child Neurol* 2002;44(01):17–25
- 24 Engsberg JR, Ross SA, Collins DR, Park TS. Effect of selective dorsal rhizotomy in the treatment of children with cerebral palsy. *J Neurosurg* 2006;105(1, Suppl):8–15
- 25 Mittal S, Farmer JP, Al-Atassi B, et al. Long-term functional outcome after selective posterior rhizotomy. *J Neurosurg* 2002; 97(02):315–325
- 26 Abbott R, Johann-Murphy M, Shiminski-Maher T, et al. Selective dorsal rhizotomy: outcome and complications in treating spastic cerebral palsy. *Neurosurgery* 1993;33(05):851–857, discussion 857
- 27 Gul SM, Steinbok P, McLeod K. Long-term outcome after selective posterior rhizotomy in children with spastic cerebral palsy. *Pediatr Neurosurg* 1999;31(02):84–95
- 28 Steinbok P, Reiner AM, Beauchamp R, Armstrong RW, Cochrane DD, Kestle J. A randomized clinical trial to compare selective posterior rhizotomy plus physiotherapy with physiotherapy alone in children with spastic diplegic cerebral palsy. *Dev Med Child Neurol* 1997;39(03):178–184
- 29 Wright FV, Sheil EM, Drake JM, Wedge JH, Naumann S. Evaluation of selective dorsal rhizotomy for the reduction of spasticity in cerebral palsy: a randomized controlled trial. *Dev Med Child Neurol* 1998;40(04):239–247
- 30 Albright AL, Barry MJ, Fasick MP, Janosky J. Effects of continuous intrathecal baclofen infusion and selective posterior rhizotomy on upper extremity spasticity. *Pediatr Neurosurg* 1995;23(02): 82–85
- 31 Beck AJ, Gaskill SJ, Marlin AE. Improvement in upper extremity function and trunk control after selective posterior rhizotomy. *Am J Occup Ther* 1993;47(08):704–707
- 32 Buckon CE, Sienko Thomas S, Aiona MD, Piatt JH. Assessment of upper-extremity function in children with spastic diplegia before and after selective dorsal rhizotomy. *Dev Med Child Neurol* 1996; 38(11):967–975
- 33 Marbini A, Ferrari A, Cioni G, Bellanova MF, Fusco C, Gemignani F. Immunohistochemical study of muscle biopsy in children with cerebral palsy. *Brain Dev* 2002;24(02):63–66
- 34 Van de Wiele BM, Staudt LA, Rubinstien EH, Nuwer M, Peacock WJ. Perioperative complications in children undergoing selective posterior rhizotomy: a review of 105 cases. *Paediatr Anaesth* 1996;6(06):479–486
- 35 Vall JAÇ, Lima ALO, Martins AO. O impacto da rizotomia dorsal seletiva na qualidade de vida de crianças espásticas portadoras de paralisia cerebral. *Arq Bras Neurocir*. 2008;27(01):7–11
- 36 Park TS, Johnston JM. Surgical techniques of selective dorsal rhizotomy for spastic cerebral palsy. Technical note. *Neurosurg Focus* 2006;21(02):e7
- 37 Shalash AS, Ghany WAA. Intraoperative Electrophysiological Monitoring During Selective Dorsal Rhizotomy in Children with Spastic Cerebral Palsy. *Egypt J Neurol Psychiat Neurosurg* 2010;47(01):505–510
- 38 Huang JÇ, Deletis V, Vodusek DB, Abbott R. Preservation of pudendal afferents in sacral rhizotomies. *Neurosurgery* 1997; 41(02):411–415
- 39 Park TS, Liu JL, Edwards C, Walter DM, Dobbs MB. Functional Outcomes of Childhood Selective Dorsal Rhizotomy 20 to 28 Years Later. *Cureus* 2017;9(05):e1256
- 40 Daunter AK, Kratz AL, Hurvitz EA. Long-term impact of childhood selective dorsal rhizotomy on pain, fatigue, and function: a case-control study. *Dev Med Child Neurol* 2017;59(10):1089–1095
- 41 Funk JF, Haberl H. Monosegmental laminoplasty for selective dorsal rhizotomy—operative technique and influence on the development of scoliosis in ambulatory children with cerebral palsy. *Childs Nerv Syst* 2016;32(05):819–825