

Giant Cell Tumour of Tendon Sheath of Distal Phalanx of Thumb: A Case Report

Puja Chaurasia¹

¹Department of Surgery, Narayani Central Hospital Birgunj Pvt. Ltd., Birgunj, Parsa, Nepal.

ABSTRACT

Giant cell tumour of tendon sheath is an uncommon benign soft tissue tumour. Histopathological examination plays a crucial role in the definitive diagnosis of giant cell tumour although pre-operative imaging supports its suspicion. We report a case of a giant cell tumour of the tendon sheath in a 26-year-old man as a painless, firm, localized, slow-growing benign soft tissue tumour of the thumb; managed by complete excision. The patient continues to do well at 7 months post-surgery with no complaints and no signs of recurrence. Giant cell tumour of the phalanges is a locally aggressive entity; therefore delayed or missed diagnosis of giant cell tumour especially of the thumb distal phalanx can be extremely debilitating. Hence, high degree of suspicion and early en bloc resection is the key to its management.

Keywords: case reports; giant cell tumors; tendons; thumb.

INTRODUCTION

Giant cell tumour of tendon sheath (GCTTS) is a benign, slow-growing, locally aggressive soft tissue tumour of the hand region with an overall incidence of 1 in 50,000 individuals.^{1,2} Etiology of the entity includes trauma, inflammation, metabolic disease, and neoplasia.^{3,4} It occurs at any age with female predominance in the third to fifth decade of life.⁵ Histopathological examination of the tumour with clinical examination and various radiological armamentariums aid in the diagnosis.⁶

CASE REPORT

A 26-year-old male presented with complaints of swelling over the front of his right thumb. The lump was spontaneous, painless, and gradually progressive in size since he first noticed it 3 months back. He denied any history of trauma or prior occurrence of the lesion, fever, bruising, numbness, tingling, and purulent discharge. Clinical examination revealed a 3x2 cm firm, immobile, solitary mass attached to a tendon on the volar bulb of the right thumb of the dominant hand. The lump didn't extend into the subungual region and adjacent skin was normal. There were no signs of inflammation or discharge. The full range of motion of the distal interphalangeal joint could be obtained. There were no signs of neurosensory indifference. We thereafter made a differential diagnosis of either a giant cell tumour or a ganglionic cyst.

For investigation, a plain radiograph was obtained which showed a soft tissue swelling with normal bones; no fracture, dislocation, or destructive lesion (Figure 1).

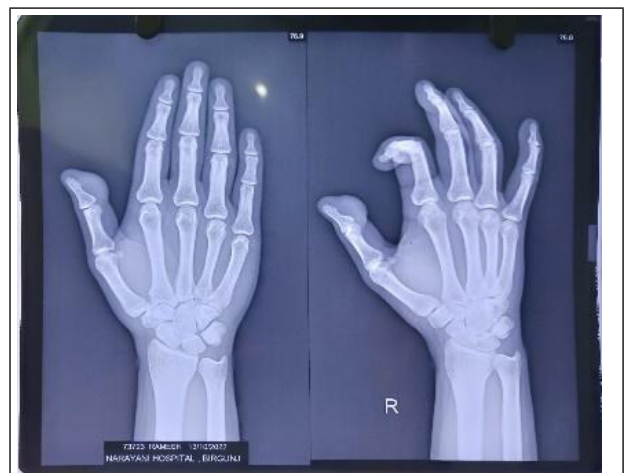

Figure 1. Posteroanterior X-ray of the right hand.

An ultrasound examination revealed a hypoechoic

Correspondence: Dr Puja Chaurasia, Department of Surgery, Narayani Central Hospital Birgunj Pvt. Ltd., Birgunj, Parsa, Nepal. E-mail: daffodilpuja@gmail.com, Phone: +977-9866389653.

complex solid-looking cystic lesion measuring about 21x16 mm at the ventral aspect of the right thumb with floating low-level echoes. No intralesional vascularity was observed. Adjacent vessels were normal.

The histopathological examination demonstrated features of giant cell tumour tendon sheath. Cut section examination revealed a greyish-white mass with cystic spaces. It showed tissue exhibiting the proliferation of cells. The cells were having round to oval and spindle nuclei. The cells were arranged in fascicles and storiform pattern focally. Numerous multinucleated giant cells were seen dispersed in the stroma. Areas of edema were also seen (Figure 2).

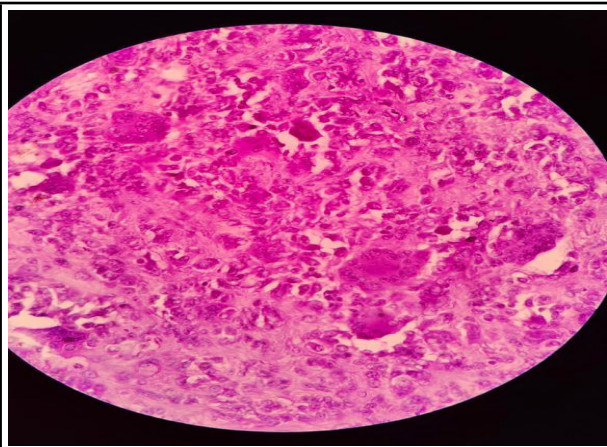


Figure 2. Hematoxylin and eosin staining of the resected specimen showed numerous multinucleated giant cells and mononuclear cells at 20x magnification.

Intra-operatively, a volar oblique incision was made on the right thumb under local anesthesia. The dissection was then carried into the subcutaneous tissue. A large mass measuring 3x2x0.5 cm grey-brown in color was completely removed (Figure 3).

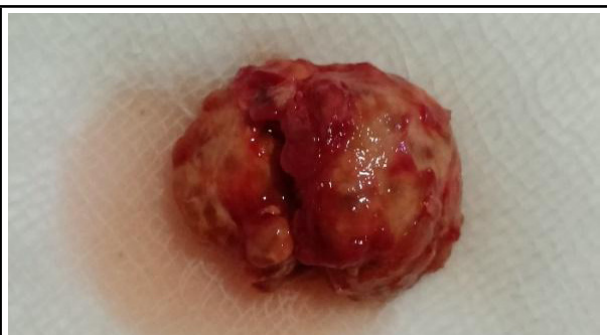

Figure 3. Tumour after complete resection.

The patient was discharged on the same day with a course of antibiotics and analgesics.

The patient was then evaluated 10 days later in the outpatient department. The patient had an uneventful post-operative course and he was advised for further

follow-up at 6 weeks and 6 months. However, he continues to do well at 7 months post-surgery with no complaints and no signs of recurrence (Figure 4).

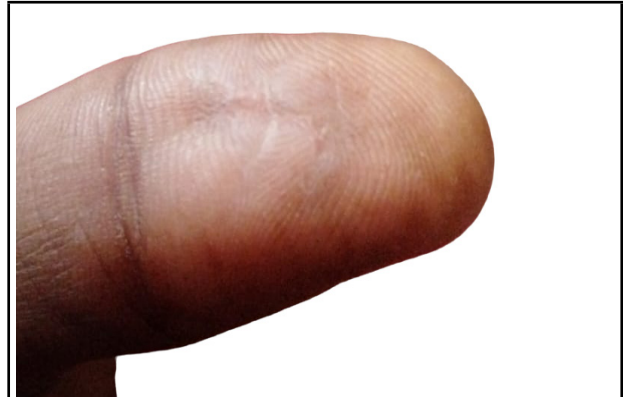

Figure 4. Post-operative image of the thumb at 7 months of GCTTS excision.

DISCUSSION

This case was intended to report an uncommon case of a giant cell tumour tendon sheath of the distal phalanx of the thumb. Giant cell tumours most commonly affect the first three fingers, with the index finger being the most frequently involved, whereas, in this patient, the thumb was the site of the lesion which is uncommon.⁶⁻⁸ These tumours are most commonly found in the region of the distal interphalangeal (DIP) joint, followed by the proximal phalanx, and usually in the dominant hand similar to our case.⁹

GCTTS manifests clinically as a firm, painless, gradually growing focal mass likely to impair the function of the involved tendon and joint.^{4,5} A plain radiograph commonly detects any soft tissue swelling and also determines whether a fracture, dislocation, or destructive lesion exists.^{5,6} In this case, there was no joint restriction, fracture, dislocation, or bony destruction which may be due to early presentation to the hospital. Sonography can be used to distinguish between solid and cystic lesions, and their relationship with the surrounding structures and to detect satellite lesions.⁶ MRI is the preferred imaging modality, particularly for evaluating extra-articular manifestations.^{5,10} In this specific case, a hypoechoic complex solid-looking cystic lesion was detected on ultrasonography, however, MRI was not performed due to the unaffordability of the patient.

In our case, GCTTS and ganglion cyst were the differential diagnoses we came up with based on the history, clinical and radiological examination. An ultrasound revealed that a ganglion cyst was more likely than a giant cell tumour. Complete surgical excision is the primary treatment for GCTTS.^{7,10} In this patient, the mass was excised in toto. Because of the

presence of a pseudo capsule, the tumour is frequently removed as a whole.⁵ However, after surgical excision, the tumour's characteristics were more suggestive of a giant cell tumour, indicating histopathological confirmation. A histopathological examination of the excised tissue was performed, which confirmed the diagnosis of GCTTS. Hence, histopathological examination is a must to confirm the diagnosis.^{7,10}

Recurrence is a major risk factor. Given the reported high recurrence rate of up to 45%, long-term follow-up after excision is advised.^{7,10} The recurrence was significantly higher at the thumb interphalangeal (IP) and distal digital interphalangeal (DIP) joints.¹ The reason may be the difficult excision of the tumour distally at the proximal interphalangeal (PIP) joint or the thumb IP and DIP joint due to the proximity of neurovascular structures to tumour margins.

The patient was then evaluated 10 days later in the outpatient department. The patient had an uneventful

post-operative course and continues to do well at 7 months post-surgery with no complaints and no signs of recurrence which was in line with a previous study.¹⁰

This report presents a case of giant cell tumour tendon sheath of distal phalanx thumb and its diagnosis and treatment in a resource constraint country. The report also emphasizes the significance of histopathological examination for the confirmation of diagnosis.

ACKNOWLEDGEMENTS

I would like to acknowledge Dr Anand Chaurasia, Department of Pathology, for providing the diagnostic histopathological findings.

Consent: JNMA [Case Report Consent Form](#) was signed by the patient and the original article is attached to the patient's chart.

Conflict of Interest: None.

REFERENCES

1. Al-Qattan MM. Giant cell tumours of tendon sheath: classification and recurrence rate. *J Hand Surg Br.* 2001 Feb;26(1):72-5. [[PubMed](#) | [Full Text](#) | [DOI](#)]
2. Pathade SC, Kurpad R, Tauheed M. Multiple giant cell tumours of tendon sheath: a rare occurrence. *J Clin Diagn Res.* 2014 Jan;8(1):170-1. [[PubMed](#) | [Full Text](#) | [DOI](#)]
3. Lowyck H, De Smet L. Recurrence rate of giant cell tumors of the tendon sheath. *European Journal of Plastic Surgery.* 2006 Jan;28(6):385-8. [[Full Text](#) | [DOI](#)]
4. Suresh SS, Zaki H. Giant cell tumor of tendon sheath: case series and review of literature. *J Hand Microsurg.* 2010 Dec;2(2):67-71. [[PubMed](#) | [Full Text](#) | [DOI](#)]
5. Adams EL, Yoder EM, Kasdan ML. Giant cell tumor of the tendon sheath: experience with 65 cases. *Eplasty.* 2012;12:e50. [[PubMed](#) | [Full Text](#)]
6. Collen J, Mount G, Pollock P, Shrout J, Malafronte P, Vangeertruyden P, et al. Giant cell tumor of the tendon sheath. *J Clin Rheumatol.* 2009 Mar;15(2):85-7. [[PubMed](#) | [Full Text](#) | [DOI](#)]
7. Darwish FM, Haddad WH. Giant cell tumour of tendon sheath: experience with 52 cases. *Singapore Med J.* 2008 Nov;49(11):879-82. [[PubMed](#) | [Full Text](#)]
8. Peh WC, Wong Y, Shek TW, Ip WY. Giant cell tumour of the tendon sheath of the hand: a pictorial essay. *Australas Radiol.* 2001 Aug;45(3):274-80. [[PubMed](#) | [Full Text](#) | [DOI](#)]
9. Monaghan H, Salter DM, Al-Nafussi A. Giant cell tumour of tendon sheath (localised nodular tenosynovitis): clinicopathological features of 71 cases. *J Clin Pathol.* 2001 May;54(5):404-7. [[PubMed](#) | [Full Text](#) | [DOI](#)]
10. Boeisa AN, Al Khalaf AA. Giant cell tumor of tendon sheath of the distal phalanx. *Cureus.* 2022 Sep 22;14(9):e29461. [[PubMed](#) | [Full Text](#) | [DOI](#)]

© The Author(s) 2023.

This work is licensed under a Creative Commons Attribution 4.0 International License. The images or other third party material in this article are included in the article's Creative Commons license, unless indicated otherwise in the credit line; if the material is not included under the Creative Commons license, users will need to obtain permission from the license holder to reproduce the material. To view a copy of this license, visit <https://creativecommons.org/licenses/by/4.0/>