

# Functional Outcome Of Percutaneous Spine Endoscopic Intervention In Lumbar Disc Herniation- A Retrospective Analysis

Anurag Agarwal, Shivani Rastogi, Deepak Malviya, Swagat Mahapatra<sup>1</sup>, Virendra Kumar, Manoj Tripathi, Kavya Sindhu

Departments of Anesthesiology, CCM and Pain Medicine and <sup>1</sup>Orthopedics, Dr. RMLIMS, Lucknow, Uttar Pradesh, India

## Abstract

**Introduction:** Low back pain is one of the most common musculoskeletal problems among developed and developing nations. The prolapsed intervertebral disc (PIVD) is the most common pathology associated with treatable low back pain. The management protocol for PIVD has evolved from conservative treatment to surgical and finally to minimally invasive pain and spine interventions. **Aims and Objectives:** The aim of study was to evaluate the functional efficacy and patient satisfaction in PIVD patients with minimally invasive percutaneous endoscopic disc decompression (PEDD). **Materials and Methods:** All data was obtained from pain medicine OT records of tertiary hospital regarding epidemiological data, VAS score for pain, ODI score for functional outcome and Modified Macnab's criteria for patient satisfaction (Pre-op, 1 week, 1 month, 3 months and 1 year) were tabulated and statistically analyzed using SPSS version 21. **Results:** There were 30 male and 26 female patients in our series with the mean age of the 42.09±10.57 years. The VAS score showed statistically significant improvement 3 months (P=0.034) and at 1 year (P=0.012) postoperative. The modified ODI score showed statistically significant improvement during 3 months (P= 0.015) and 1-year score (P=0.008). The modified MACNAB scores (P= 0.001) showed significant improvement in patient satisfaction. One patient had a recurrence and opted for conventional surgical management. Few patients had transient side effects (dysesthesia-7, mild weakness-1) which improved with conservative measures. **Conclusion:** We conclude that percutaneous endoscopic disc decompression for single-level lumbar disc herniation is a safe, effective and low-cost definitive treatment modality with minimal complications.

**Keywords:** Backache, disc prolapse, percutaneous treatment, spine endoscopy

Received: 16-06-2020

Revised: 18-07-2020

Accepted: 19-10-2020

Published: 31-08-2021

## INTRODUCTION

Low-back pain (LBP) is the most common musculoskeletal symptom identified among majority of countries including India. Back pain is the most common cause of activity limitation in people younger than 45 years, the second most frequent reason for visits to the family doctor, the fifth-ranking cause of admission to hospital, and the third-most common cause of surgical procedures.<sup>[1]</sup> Prolapsed intervertebral disc (PIVD) is one of the most common findings found in individuals undergoing magnetic resonance scans for LBP.<sup>[2]</sup> Other clinical features of disc herniation or prolapse include sciatica and radicular pain (leg pain due to irritation of a nerve root in the spine).<sup>[3]</sup> Treatment goals of patients

with PIVD are moderation of pain, increased function, and decreased health-care utilization. This can be achieved by nonpharmacological, medications, minimally invasive pain interventions, and conventional surgeries.<sup>[4]</sup> Surgical treatment of PIVD has evolved from traditional open spine surgery to minimally invasive spine interventions including percutaneous spine endoscopic procedures. Minimally invasive disc interventions were started by Lymen Smith in 1963 by injecting chymopapain intradiscally.<sup>[5]</sup> The

**Address for correspondence:** Dr. Swagat Mahapatra,  
Department of Orthopedics, Dr. RMLIMS, Lucknow, Uttar Pradesh, India.  
E-mail: drswagat@gmail.com

This is an open access journal, and articles are distributed under the terms of the Creative Commons Attribution-NonCommercial-ShareAlike 4.0 License, which allows others to remix, tweak, and build upon the work non-commercially, as long as appropriate credit is given and the new creations are licensed under the identical terms.

**For reprints contact:** WKHLRPMedknow\_reprints@wolterskluwer.com

**How to cite this article:** Agarwal A, Rastogi S, Malviya D, Mahapatra S, Kumar V, Tripathi M, *et al.* Functional outcome of percutaneous spine endoscopic intervention in lumbar disc herniation- A retrospective analysis. Indian J Pain 2021;35:150-6.

### Access this article online

#### Quick Response Code:



**Website:**  
www.indianjpain.org

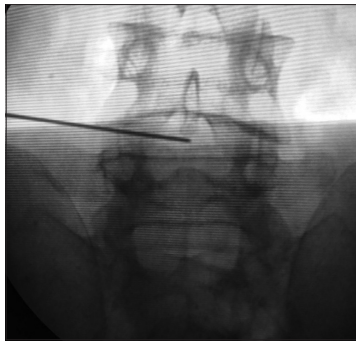
**DOI:**  
10.4103/ijpn.ijpn\_78\_20

concept of mechanical decompression of prolapsed disc by percutaneous methods was popularized by Onik *et al.*<sup>[6]</sup> Further enhancements in minimally invasive treatments for PIVD have been made possible with the development of percutaneous spine endoscopes and fine instruments. This field has made rapid progress in the last decade with more and more patients opting for minimally invasive and percutaneous treatments over conventional surgeries. Lumbar disc herniation after identification of offending level can be managed by percutaneous spine endoscopy under local anesthesia. In endoscopic lumbar spine interventions, two approaches are most popular: transforaminal (TF) and inter-laminar endoscopy.<sup>[7]</sup> Each approach has its specific indications. Advanced instrumentation such as rod-lens-type endoscope enabling single-portal working and very high-frequency radiofrequency probe for better hemostasis, have popularized percutaneous endoscopic disc decompression (PEDD) as an attractive technique for minimally invasive spine interventions.<sup>[8]</sup> As these procedures are performed under local anesthesia, patients can be usually discharged on the same day with minimal medications without the additional risks of general anesthesia. The major advantage of PEDD includes preservation of spine stability by entering the spinal canal with minimal bone resection. There is minimal damage to muscles and ligaments, thus allowing early rehabilitation and earlier return to function.<sup>[9]</sup> The technique of lumbar PEDD is highly effective with minimal morbidity and complication and should be more widely practiced by all pain physicians. The objective of this study was to evaluate the efficacy and functional results following percutaneous spine endoscopic techniques in lumbar disc herniation performed by a single team of pain physicians.

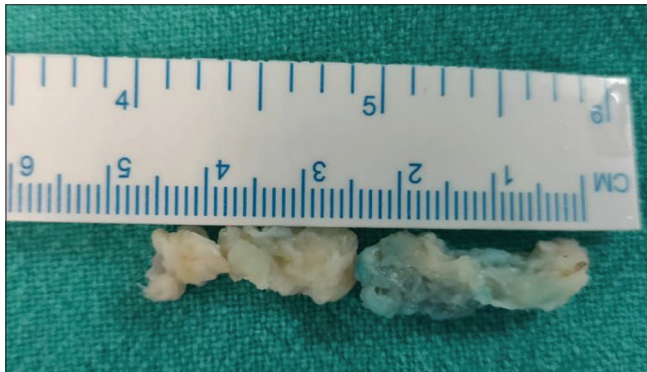
## MATERIALS AND METHODS

This study was conducted at a tertiary care 1100-bedded multispecialty teaching hospital. This was a retrospective observational study conducted in the pain medicine unit of department of anesthesiology after institutional ethical committee approval. All patients who had undergone minimally invasive and percutaneous spine endoscopic interventions for treatment of lumbar PIVD in our department from June 2017 to June 2019 were identified as per records. Patients in the age group of 20 to 70 years, who had undergone PEDD for a single-level disc herniation, were included in our study. Patients with major life-threatening comorbidities, multi-level disease, progressive neurological deficit, cauda-equina syndrome, and coagulopathies were excluded from the study. After following all the inclusion and exclusion criteria, 56 out of the total of 123 patients were found to be eligible to participate in the study. Patient details including epidemiological parameters, clinical parameters, and preoperative pain and functional scores were recorded. After confirmation of the offending prolapsed disc by magnetic resonance imaging (MRI), patients were planned for intervention. After adequate consent and preoperative workup, lumbar PEDD was performed by consultant pain physicians by transforaminal or inter-laminar route. The approach was decided

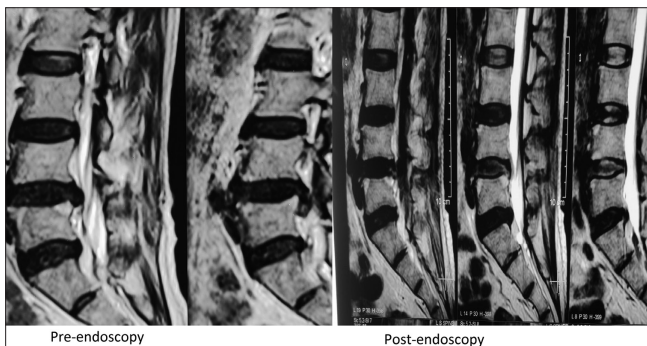preendoscopically by X-rays and MRI studies. Transforaminal approach was the favored approach in all patients with L4–5 level disc prolapse, and inter-laminar route was employed in L5–S1 disc herniations as the high iliac crest precludes the effective use of transforaminal approach at that level, and also a wide inter-laminar space at L5–S1 facilitated the use of inter-laminar route at L5–S1. The endoscopic procedure was done in a dedicated pain medicine operation suite with C-arm guidance. Out of 56 patients, 11 had L5–S1 herniations which were operated by inter-laminar route and the rest all with L4–5 herniations were operated by trans-foraminal route. All patients were operated in prone position with monitored anesthesia care. Local anesthesia (lidocaine 1% for skin infiltration and 0.5% at or beyond superior articular process) was used for transforaminal approach, whereas for inter-laminar approach, epidural analgesia with dilute concentration of local anesthesia (0.5% lidocaine) was used to get sensory analgesia only without any motor block. After sterile preparation and draping, disc level was confirmed under image guidance. For the TF approach, an 18G, 15-cm spinal needle was used to enter the offending disc via the intervertebral foramen and an evocative discography was performed with a mixture of 1% methylene blue injection and omnipaque dye. The stylet of the spinal needle was replaced by a guide wire [Figures 1 and 2]. Sequential dilators were used through a skin incision of 8 mm to create a tract for an 8-mm working cannula, which was railroaded over the 7-mm dilator. After the placement of the working cannula, a spine endoscope with 25° optics was introduced and the offending fragment of nucleus pulposus was identified and removed by rongeurs, under direct vision and continuous irrigation with normal saline [Figure 3]. As per the specific requirement of each case, other endoscopic instruments such as endoscopic burrs, side-cutting drills, and curved hook were used to facilitate the safe removal of disc fragment. For the inter-laminar approach, a stab incision was made just off the midline at the level of offending disc, confirmed under c-arm guidance. A conical dilator of 8 mm was placed up to the ligamentum flavum and confirmed under the lateral view of c-arm fluoroscope [Figure 4]. The working channel and endoscope were placed using the conventional technique to visualize the ligamentum flavum. After preparation of the ligamentum flavum with the help of rongeurs and Friedman Rongeurs probe, it was opened from the medial to the lateral side using curved hook punches. After opening of the ligamentum flavum and confirmation of the neural structures such as thecal sac and traversing route, medialization of neural structures (traversing nerve root) was done (as all cases of inter-laminar PEDD at L5–S1 were done by the shoulder approach), though lateralization of neural structures (traversing nerve root and thecal sac) may be required in the cases of axillary approach specifically for downmigrated disc fragments. This maneuver was done with the help of tapered working cannulae till the prolapsed disc came into the endoscopic view. The prolapsed disc fragment was removed under direct vision and continuous irrigation. Free pulsation of the dural sac and nerve root was



**Figure 1:** Guide wire in the disc – anteroposterior fluoroscopic view

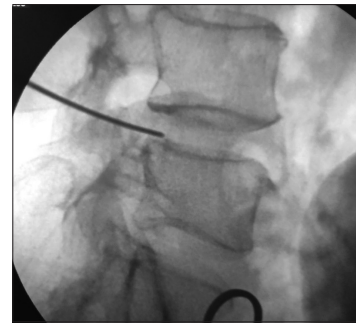

**Figure 3:** Removed painted disc material

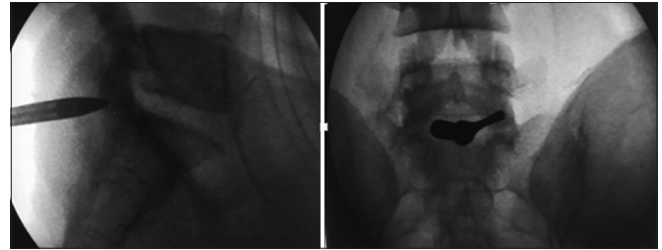


**Figure 5:** Comparative magnetic resonance imaging (pre- and post-endoscopy) – axial view (percutaneous endoscopic disc decompression transforaminal)

confirmed, and hemostasis was achieved in all cases before removal of the endoscope. Closure of the skin incision was done with a single suture. Adequate removal of the disc was confirmed using post-procedure MRI [Figures 5 and 6]. Three scoring systems were used in functional analysis. Patients were followed up at 1-week, 1-month, 3-month, and 1-year interval with clinical parameters, visual analog scale (VAS) for pain, modified Oswestry Disability Index score (modified ODI score) for functional improvement, and MACNAB's criteria for patient satisfaction. All data were entered into excel sheets and tabulated. Statistical analysis of the data was done using statistical package for social sciences (SPSS) version 21 (Armonk, NY: IBM Corp).  $P \leq 0.05$  with 95% confidence



**Figure 2:** Guide wire in the disc – Lateral fluoroscopic view



**Figure 4:** Dilator and sleeve placement in “inter-laminar approach” – anteroposterior and lateral fluoroscopic views



**Figure 6:** Comparative magnetic resonance imaging (pre- and post-endoscopy) sagittal view (percutaneous endoscopic disc decompression transforaminal)

interval was considered statistically significant. Analysis of variance was used to analyze the difference in mean values, the Fisher's exact test and Chi-square test were utilized for evaluating categorical variables, and paired *t*-test was applied to compare the preoperative and postoperative VAS, ODI, and MACNAB scores.

## RESULTS

The mean age of the patients in our series was  $42.09 \pm 10.57$  years [Table 1]. There were 30 male patients and 26 female patients who fulfilled the inclusion criteria and had undergone lumbar PEDD [Graph 1]. The mean VAS scores at preoperative, 1 week, 1 month, 3 months, and 1 year were  $7.02 \pm 2.61$ ,  $2.62 \pm 1.7$ ,  $1.8 \pm 1.55$ ,  $1.42 \pm 1.19$ , and  $1.85 \pm 1.16$ , respectively. The VAS score showed clinically significant but statistically nonsignificant, difference during preoperative, 1 week, and 1 month [Table 2]. There was a statistically



**Table 1: Demographic data in the study**

Type	n	Mean ± SD	SEM	$\chi^2$	Range	df	P
Age	56	42.09 ± 10.57	2.29	1.34	47	16	0.73 (NS)

Total study population is  $n = 56$ ,  $\chi^2 P = 0.73$ . SD: Standard deviation; SEM: Standard error of mean; DF: Degree of freedom

**Table 2: Clinical outcomes for visual analog scale scores preoperatively and postoperatively**

VAS score	Mean ± SD	SEM	t	df	P
VAS preoperative	7.02 ± 2.61	0.353	20.046	54	0.704 (NS)
VAS 1 week	2.62 ± 1.7	0.227	11.549		0.886 (NS)
VAS 1 month	1.8 ± 1.55	0.21	8.57		0.234 (NS)
VAS 3 months	1.42 ± 1.19	0.161	8.78		0.034 (S)
VAS 1 year	1.85 ± 1.16	0.157	11.84		0.012 (S)

VAS: Visual Analog Scale; SD: Standard deviation; SEM: Standard error of mean; S: Significant; NS: Nonsignificant; DF: Degree of freedom

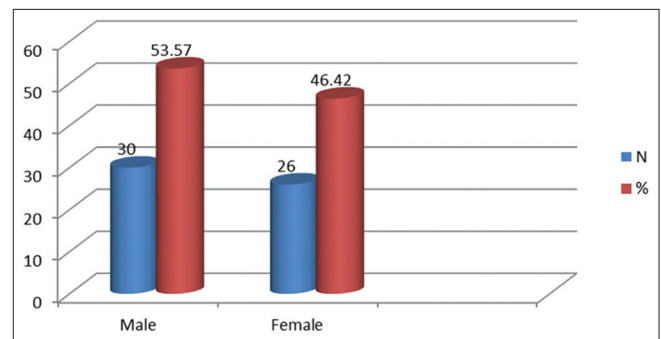
significant difference in improvement at 3 months ( $P = 0.034$ ) and at 1 year ( $P = 0.012$ ) postoperatively. The mean modified ODI scores at preoperative, 1 week, 1 month, 3 months, and 1 year were  $20.72 \pm 8.48$ ,  $11.02 \pm 6.82$ ,  $8.35 \pm 7.07$ ,  $5.35 \pm 5.13$ , and  $5.76 \pm 6.17$ , respectively. The modified ODI score showed a statistically nonsignificant but clinically significant difference during preoperative, 1 week, and 1 month, but there was a statistically significant difference during ODI 3-month ( $P = 0.015$ ) and ODI 1-year score ( $P = 0.008$ ) [Table 3]. The modified MACNAB scores at 1 week, 1 month, 3 months, and 1 year showed significant improvement in patient satisfaction with  $P = 0.001$  [Graph 2]. Seven patients of PEDD by trans-foraminal route complained of post endoscopy transient dysesthesia, one patient of PEDD by inter-laminar route had mild transient motor weakness (Grade IV power) of S1 nerve root, one patient had recurrent disc herniation, and 14 patients required additional TF neuroplasty (epidural steroid injection) for complete relief [Graph 3].

The ODI score showed a statistically nonsignificant difference during preoperative, 1 week, and 1 month, but there was a statistically significant difference during ODI 3-month ( $P = 0.015$ ) and ODI 1-year score ( $P = 0.008$ ).

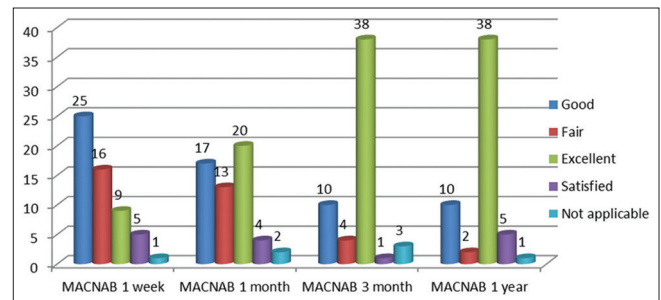
## DISCUSSION

LBP is one of the major public health problems which may cause profound morbidity and leave absenteeism and massive financial burden to the individual and health-care system.<sup>[10,11]</sup> LBP may be nonspecific, potentially associated with radiculopathy or spinal stenosis, and potentially associated with another specific spinal cause, as advised by the American Pain Society. Among all causes, prolapsed lumbar disc is the most common spinal disorder associated with LBP with radiculopathy.<sup>[12]</sup>

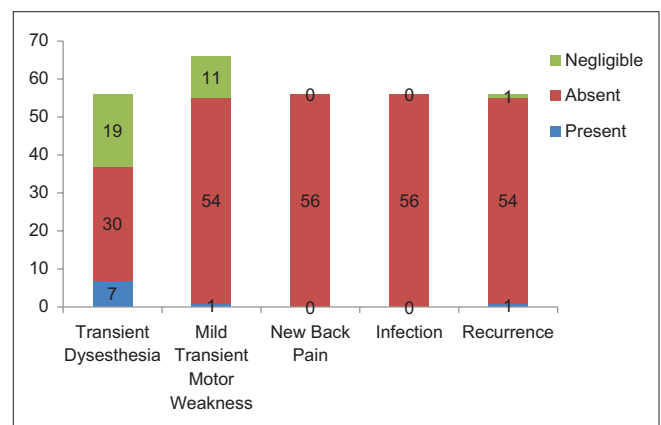
The advent and progression of the treatment of LBP by pain physicians has been gradual and progressive, starting with conservative treatment and progressing to minimally invasive pain and spine interventions. The evolution has taken place in the last two decades with many highs and lows [Figure 7].<sup>[13-15]</sup>



**Graph 1:** Gender-wise distribution of the study population.  $\chi^2 = 0.286$ ,  $P = 0.573$



**Graph 2:** Distribution of MACNAB scores.  $\chi^2 = 8.690$ ,  $P = 0.001$



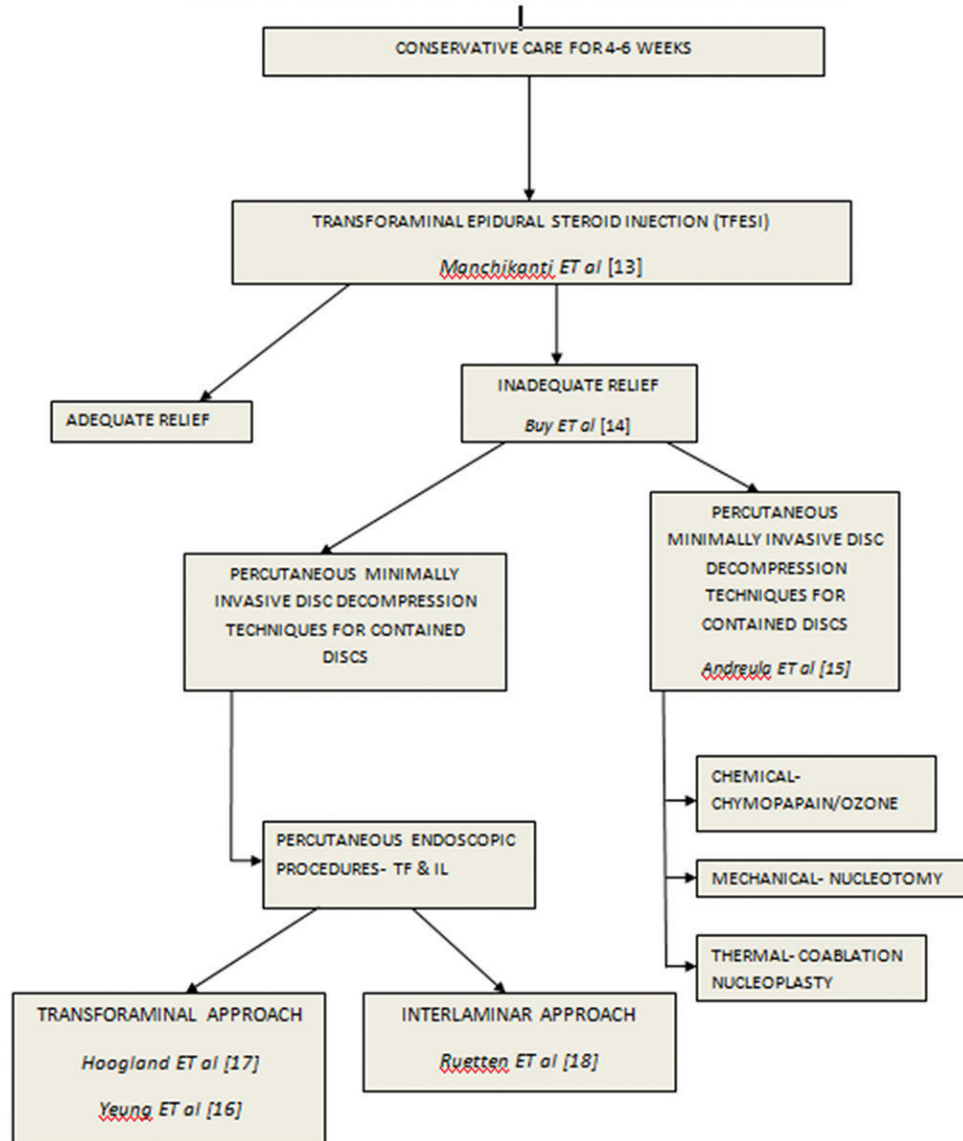
**Graph 3:** Complications

**Table 3: Clinical outcomes of Oswestry Disability Index scores**

ODI score	Mean $\pm$ SD	SEM	t	df	P
ODI preoperative	20.72 $\pm$ 8.48	1.25	16.56	54	0.789 (NS)
ODI 1 week	11.02 $\pm$ 6.82	1.04	10.59		0.462 (NS)
ODI 1 month	8.35 $\pm$ 7.07	1.118	7.46		0.312 (NS)
ODI 3 months	5.35 $\pm$ 5.13	0.733	7.29		0.015 (S)
ODI 1 year	5.76 $\pm$ 6.17	0.833	6.92		0.008 (S)

ODI: Oswestry Disability Index; SD: Standard deviation; SEM: Standard error of mean; S: Significant; NS: Nonsignificant; DF: Degree of freedom

### EVOLUTION OF PERCUTANEOUS MINIMALLY INVASIVE SPINE INTERVENTIONS FOR RADICULOPATHY


**Figure 7: Evolution of percutaneous endoscopic disc decompression**

The major milestones in percutaneous spine endoscopic procedures and approaches are credited to the development of rod lens spine endoscope by Yeung and Tsou, named the Yeung endoscopic spine system<sup>[16]</sup> and TF endoscopic spine system by Hoogland.<sup>[17]</sup> Reutten introduced the percutaneous endoscopic interlaminar discectomy approach.<sup>[18]</sup>

Our series had a preponderance of male patients, which is the usual presentation in lumbar disc prolapse. Our data are similar to that of a study by R Prasad *et al.*, who had a similar male patient predominance.<sup>[19]</sup> The age and sex distribution of our study population was nonsignificant, hence depicting a homogenous study population which had no impact on the

results [Table 1 and Graph 1]. We used VAS as a measure of patient's pain. It is a single-dimensional measure of intensity of pain measured using a 10-cm scale with one end of the scale being 0 (no pain) and the other end being 10 (worst pain imaginable).<sup>[20]</sup> In our study, the patients had significant improvement in VAS scores at 3 months and 1 year. Till 3 months, many patients had clinically significant improvement but that was not statistically significant. This may be explained by the fact that the nerve edema due to compression may take some time to settle down. Fourteen patients in our series with persistent radicular pain required additional TF neuroplasty (TF epidural steroid injection) even after adequate decompression. In addition, the patients could continue full-scale physiotherapy and exercises once the procedural and neuropathic pain settled. Our VAS improvement was comparable to that of studies by Mashhadinezhad *et al.* who noticed the results of micro-discectomy and open discectomy in disc herniation.<sup>[21]</sup> The ODI score in our series improved immediately after the procedure in most patients but became statistically significant at 3 months and continued to improve even till 1 year. Our data are comparable to that of studies by Ren *et al.* and Choi *et al.*, who showed excellent improvement in postoperative ODI scores with endoscopic disc decompression.<sup>[22,23]</sup> A recent meta-analysis by Alvi *et al.* has also shown the positive impact of endoscopic discectomy as compared to that of open and micro discectomy.<sup>[24]</sup> Patients' satisfaction after the procedure was analyzed by the Modified MACNABS criteria.<sup>[20]</sup> This is a subjective assessment scale in which the patient rates his/her symptoms after intervention as excellent, good, fair, and poor. There were significant improvements in the MACNABS score in our series after intervention. Our findings are similar to those of many studies where endoscopic or open procedures have been done for lumbar disc herniation.<sup>[25,26]</sup> Seven patients in our series had mild transient dysesthesia after TF endoscopy and one patient had mild transient motor weakness after inter-laminar endoscopy. Dysesthesia may be explained by the inadvertent pressure on the dorsal root ganglion during TF approach by the working sleeve.<sup>[27]</sup> Motor weakness may be explained by pressure injury during medialization of root by the working sleeve in inter-laminar approach. Both these complications were transient and recovered within few weeks. One patient in our series had recurrent symptoms 3 weeks after our intervention of PEDD-TF; on repeat MRI, an inadequate fragment removal was found, for which he underwent open surgical decompression. Dural tear, discitis, and nerve root neurotmesis<sup>[28]</sup> which are the reported complications in open spine surgery have not been reported in our series. Studies by Choi *et al.* and Fan *et al.* on the results of endoscopic discectomy also report minimal major complications.<sup>[25,26]</sup>

Percutaneous spine endoscopic procedures are day-care interventions for lumbar disc herniations. They require short time, have minimal risk of infection, cause low economic burden to the individual and the health-care system, and most importantly result in fast recovery. These procedures are

becoming increasingly popular both with pain physicians and patients as the definitive treatment of PIVD. As compared to open surgery, PEDD uses only an 8-mm incision. Use of local anesthesia enables the physician to communicate with the patient during endoscopy, thus ensuring safety and improving efficacy.<sup>[29]</sup>

### Strengths and limitations of the study

- Our study was regarding endoscopic disc decompression for lumbar disc herniation. Our study was short, was simple, and gave direct introspection into this novel yet not very popular, treatment modality by pain physicians
- Because our study focused only on single-level lumbar disc herniation and its treatment by PEDD, no insight into the efficacy of this technique in multi-level and degenerative spine conditions is provided
- We had a small sample size and further studies including trials are required to gain a complete insight into percutaneous spine endoscopy and its extended usage.

### CONCLUSION

Pain medicine has evolved from percutaneous injection of steroid to percutaneous endoscopic spine procedures in the treatment of PIVD and radiculopathy. Our study shows the feasibility and comparable results of PEDD in single-level lumbar disc herniation with improved pain, functional outcomes, and patient satisfaction scores in a day-care setting. From our results, we could conclude safely that PEDD for single-level lumbar disc herniation is a safe, effective, and low-cost definitive treatment modality with minimal complications. More research and trials are required in various, more complex pathologies by pain physicians for expansion and popularization of these techniques.

### Financial support and sponsorship

Nil.

### Conflicts of interest

There are no conflicts of interest.

### REFERENCES

1. Praemer A, Furner S, Rice DP American Academy of Orthopaedic Surgeons. Musculoskeletal Conditions in the United States. Park Ridge: American Academy of Orthopaedic Surgeons; 1992.
2. Boden SD. The use of radiographic imaging studies in the evaluation of patients who have degenerative disorders of the lumbar spine. *J Bone Joint Surg Am* 1996;78:114-24.
3. Boden SD, Davis DO, Dina TS, Patronas NJ, Wiesel SW. Abnormal magnetic-resonance scans of the lumbar spine in asymptomatic subjects. A prospective investigation. *J Bone Joint Surg Am* 1990;72:403-8.
4. Sanders SH, Rucker KS, Anderson KO, Harden RN, Jackson KW, Vicente PJ, *et al.* Clinical practice guidelines for chronic non-malignant pain syndrome patients. *J Back Musculoskelet Rehabil* 1995;5:115-20.
5. Hoogland T. Transforaminal endoscopic discectomy with foraminoplasty for lumbar disc herniation. *Surg Tech Orthop Traumatol* 2003;40:55-120.
6. Onik G, Helms CA, Ginsburg L, Hoaglund FT, Morris J. Percutaneous lumbar discectomy using a new aspiration probe. *AJR Am J Roentgenol* 1985;144:1137-40.
7. Choi G, Pophale CS, Patel B, Uniyal P. Endoscopic spine surgery. *J*

- Korean Neurosurg Soc 2017;60:485-97.
8. Ahn Y. Percutaneous endoscopic decompression for lumbar spinal stenosis. *Expert Rev Med Devices* 2014;11:605-16.
9. Peng CW, Yeo W, Tan SB. Percutaneous endoscopic lumbar discectomy: Clinical and quality of life outcomes with a minimum 2 year followup. *J Orthop Surg Res* 2009;4:20.
10. Heliövaara M, Sievers K, Impivaara O, Maatela J, Knekt P, Mäkelä M, *et al.* Descriptive epidemiology and public health aspects of low back pain. *Ann Med* 1989;21:327-33.
11. Cassidy JD, Carroll LJ, Côté P. The Saskatchewan health and back pain survey. The prevalence of low back pain and related disability in Saskatchewan adults. *Spine (Phila Pa 1976)* 1998;23:1860-6.
12. Chou R, Qaseem A, Snow V, Casey D, Cross JT Jr, Shekelle P, *et al.* Diagnosis and treatment of low back pain: A joint clinical practice guideline from the American College of Physicians and the American Pain Society. *Ann Intern Med* 2007;147:478-91.
13. Manchikanti L, Buenaventura RM, Manchikanti KN, Ruan X, Gupta S, Smith HS, *et al.* Effectiveness of therapeutic lumbar transforaminal epidural steroid injections in managing lumbar spinal pain. *Pain Physician* 2012;15:E199-245.
14. Buy X, Gangi A. Percutaneous treatment of intervertebral disc herniation. *Semin Intervent Radiol* 2010;27:148-59.
15. Andreula C, Muto M, Leonardi M. Interventional spinal procedures. *Eur J Radiol* 2004;50:112-9.
16. Yeung AT, Tsou PM. Posterolateral endoscopic excision for lumbar disc herniation: Surgical technique, outcome, and complications in 307 consecutive cases. *Spine (Phila Pa 1976)* 2002;27:722-31.
17. Hoogland T, Schubert M, Miklitz B, Agnes R. Transforaminal posterolateral endoscopic discectomy with or without the combination of a low-dose chymopapain: A prospective randomized study in 280 consecutive cases. *Spine (Phila Pa 1976)* 2006;31:E890-7.
18. Ruetten S, Komp M, Godolias G. A New full-endoscopic technique for the interlaminar operation of lumbar disc herniations using 6-mm endoscopes: Prospective 2-year results of 331 patients. *Minim Invasive Neurosurg* 2006;49:80-7.
19. Prasad, R., Hoda, M.F., Dhakal, M.M. *et al.* Epidemiological characteristics of lumbar disc prolapse in a tertiary care hospital. *The Internet J. Neurosurg.* 2006;3:1.
20. Haefeli M, Elfering A. Pain assessment. *Eur Spine J* 2006;15:S17-24.
21. Mashhadinezhad H, Sarabi E, Mashhadinezhad S, Ganjeifar B. Clinical outcomes after microdiscectomy for recurrent lumbar disk herniation: A single-center study. *Arch Bone Jt Surg* 2018;6:397-401.
22. Ren C, Li Y, Qin R, Sun P, Wang P. Transforaminal Endoscopic Lumbar Discectomy for Lumbar Disc Herniation Causing Bilateral Symptoms. *World Neurosurg.* 2017;106:413-421.
23. Choi G, Prada N, Modi HN, Vasavada NB, Kim JS, Lee SH. Percutaneous endoscopic lumbar herniectomy for high-grade down-migrated L4-L5 disc through an L5-S1 interlaminar approach: A technical note. *Minim Invasive Neurosurg* 2010;53:147-52.
24. Alvi MA, Kerezoudis P, Wahood W, Goyal A, Bydon M. Operative approaches for lumbar disc herniation: A systematic review and multiple treatment meta-analysis of conventional and minimally invasive surgeries. *World Neurosurg* 2018;114:391-40700.
25. Fan G, Gu X, Liu Y, Wu X, Zhang H, Gu G, *et al.* Lower learning difficulty and fluoroscopy reduction of transforaminal percutaneous endoscopic lumbar discectomy with an accurate preoperative location method. *Pain Physician* 2016;19:E1123-34.
26. Choi KC, Kim JS, Ryu KS, Kang BU, Ahn Y, Lee SH. Percutaneous endoscopic lumbar discectomy for L5-S1 disc herniation: transforaminal versus interlaminar approach. *Pain Physician* 2013;16:547-56.
27. Choi G, Lee SH, Raiturker PP, Lee S, Chae YS. Percutaneous endoscopic interlaminar discectomy for intracanalicular disc herniations at L5-S1 using a rigid working channel endoscope. *Neurosurgery.* 2006 Feb;58(1 Suppl).
28. Kaushal M, Sen R. Posterior endoscopic discectomy: Results in 300 patients. *Indian J Orthop* 2012;46:81-5.
29. Liu C, Zhou Y. Comparison between percutaneous endoscopic lumbar discectomy and minimally invasive transforaminal lumbar interbody fusion for lumbar disc herniation with biradicular symptoms. *World Neurosurg* 2018;120:e72-9.