

CASE REPORT

Pier abutment: Bridge the gap with non rigid connector - A clinical case report

Vineet Sharma*, Kamal Kumar Meena, Balwant Singh Gurjar, Ramawatar Nagar

Department of Prosthodontics and crown & bridge, RUHS College of Dental Sciences, Jaipur, India

Pier abutment is defined as a freestanding abutment with edentulous space on both sides. This case report described the rehabilitation of a patient who presented to the department with the primary complaint of missing teeth and difficulty in mastication. Intraoral examination revealed missing right maxillary canine and the second premolar, with the lone standing first premolar acting as a pier abutment. To reduce the stress transferred to the abutment and prosthetic assembly, a non-rigid (Tenon-mortise) connector was used in the case, with a keyway (mortise) distal to the pier abutment and a key (Tenon) mesial to the distal pontic.

Keywords: nonrigid connector, key-keyway, tenon-mortise, pier abutment

Received 5 January 2022 / Accepted 2 May 2022

Introduction

Most fixed dental prostheses are fabricated using rigid connectors between pontics and retainers [1]. A fixed dental prosthesis with the pontic rigidly attached to the retainers gives prosthesis the desired strength and stability while minimizing restoration stresses [2]. However, a completely rigid restoration is not recommended in all cases when a fixed prosthesis is required. In the event of an edentulous space on either side of a tooth, a standalone pier abutment will result. It is not recommended to use a rigid fixed dental prosthesis because of the movement of the teeth, the position of the abutments in the arch, and the difference in retention abilities of the retainers [1,3]. This case report demonstrates the use of a fixed dental prosthesis with a non-rigid (Tenon-Mortise) connector posterior to the pier abutment (first premolar) to replace a missing maxillary canine and second premolar. Because the peri cemental area of the maxillary lateral incisor was insufficient to support the missing canine, the maxillary central incisor was used as an additional support.

Case report

A 30-year-old female patient presented to the department of prosthodontics at the RUHS College of Dental Sciences in Jaipur with the chief complaint of missing teeth and difficulty in mastication for the past eight months. Past dental history reveals the extraction of the right maxillary canine (13) and second premolar (15) due to dental caries eight months ago, as well as root canal treatment of the left maxillary second premolar (25) due to dental caries. No relevant medical history was revealed. Intraoral examination revealed missing 13 and 15 with the right maxillary first premolar (14) acting as a pier abutment (Fig. 1). An evaluation of the clinical and radiographic findings revealed healthy abutments with the favorable crown to root ratio.

There were three treatment options: implant-retained dental prosthesis, fixed dental prosthesis with a rigid connector, and fixed dental prosthesis with a non-rigid connector. The patient was not willing to undergo surgical intervention, so implant-retained dental prostheses were ruled out. Finally, it was decided to rehabilitate the patient using a PFM fixed dental prosthesis with the non-rigid connector on the distal aspect of the pier abutment.

Clinical Procedure

After obtaining written consent from the patient, maxillary right central incisor (11), lateral incisor (12), first premolar (14), and first molar (16) were prepared to receive PFM crowns with shoulder finish lines and equigingival margins (Fig. 2). The gingival retraction cord was used, and the final impression was made with elastomeric impression material utilizing a two-stage putty wash technique and poured into die stone to obtain the master cast. Bite registration material (Occlufast Rock, Zhermack SpA, Italy) was used to make an interocclusal record. Provisional restorations were made from a tooth-colored auto polymerizing acrylic resin (UNIFAST™ Trad, GC Corporation, Japan) and cemented with non-eugenol temporary cement (NETC, Meta Biomed, Inc., USA) (Fig. 3). Using an interocclusal record,

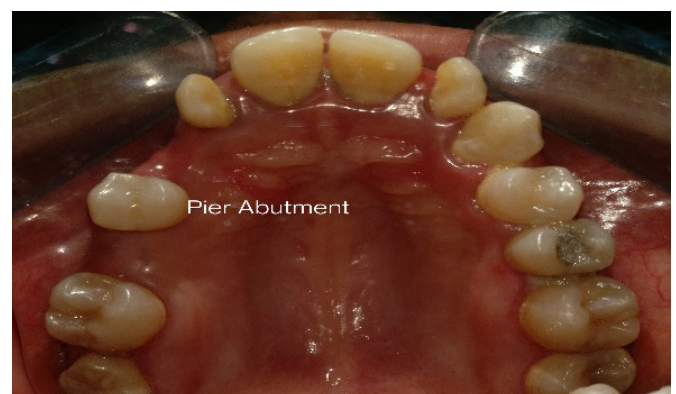

Fig. 1. Intraoral photograph with missing 13, 15, and 14 as pier abutment.

* Correspondence to: Vineet Sharma
E-mail: vineetalwar007@gmail.com

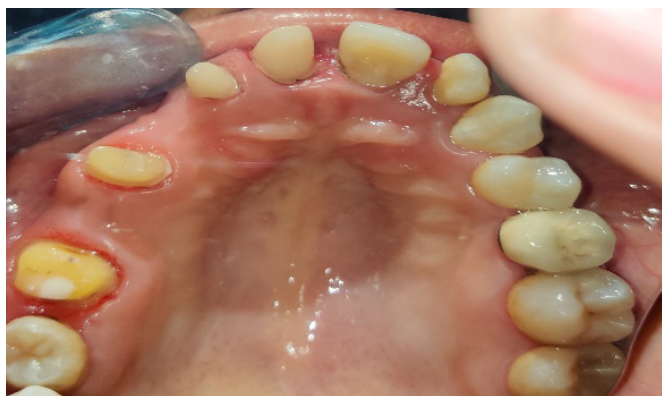

Fig. 2. Tooth preparation

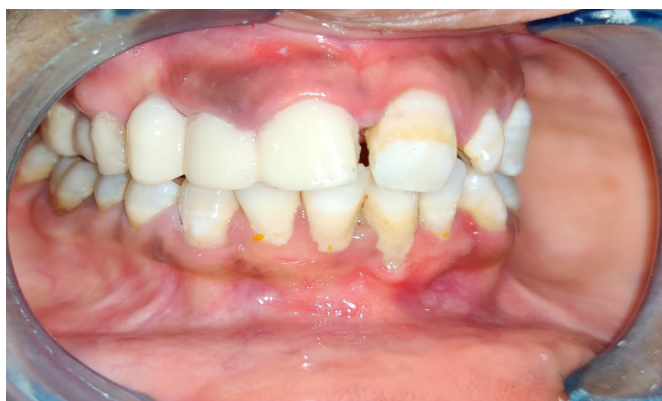

Fig. 3. Provisional crowns- In situ

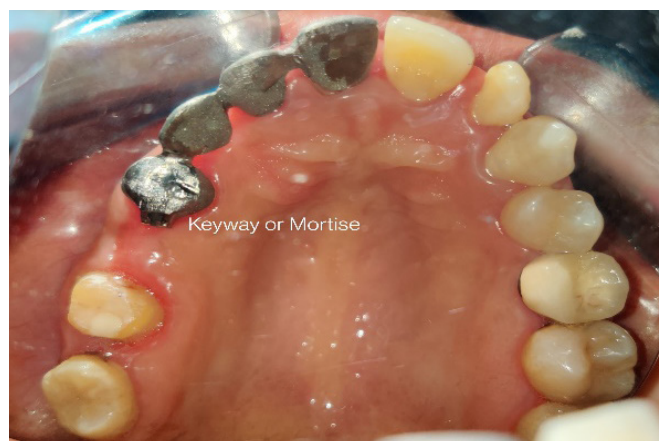

Fig. 4. Try in of Anterior metal assembly with keyway on distal of 14.

the master cast was then mounted on an articulator. Wax patterns were fabricated for 11, 12, 13, and 14 first. A plastic castable female attachment (Mortise) was waxed upon the distal surface of the wax pattern. The parallelism of plastic male attachment was determined through surveying. Investing and casting were completed. In the patient's mouth, a metal try-in of the anterior attachment with keyway or mortise was done, and a pickup impression was made with elastomeric impression material (Fig. 4,5). The Key was seated in the casted keyway, and wax patterns for 15 and 16 were made connecting the key into the keyway. Casting procedures were carried out in the similar manner.

The metal fit was checked in the lab after both male and female portions were inserted. Clinically, both the anterior and posterior segments were tried to ensure that the restoration's marginal fit was correct. Following shade selection, it was ceramized. The laboratory procedure was completed by assembling the anterior segment with the female portion (keyway mortise) and the posterior segment with the male portion (key tenon) in the working cast (Fig. 6). A four-unit segment consisting of 11, 12, 13, and 14 (pier abutment) was cemented first, followed by a two-unit posterior segment consisting of 15 and 16, with a key on the mesial contour of 15 (Fig. 7). Glass ionomer cement (GC

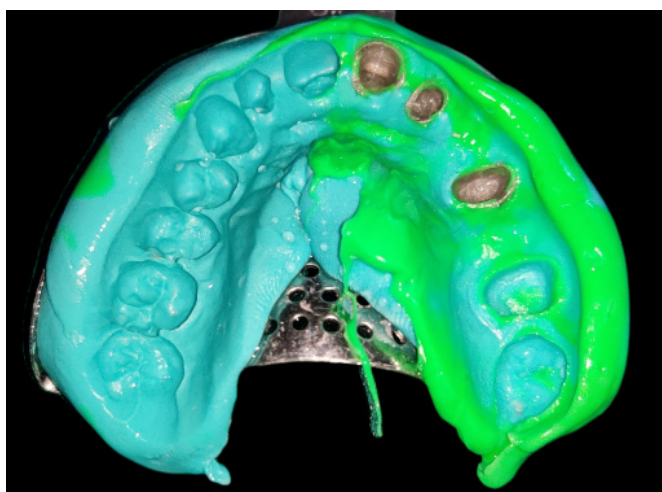


Fig. 5. Pick up impression made with elastomeric impression material

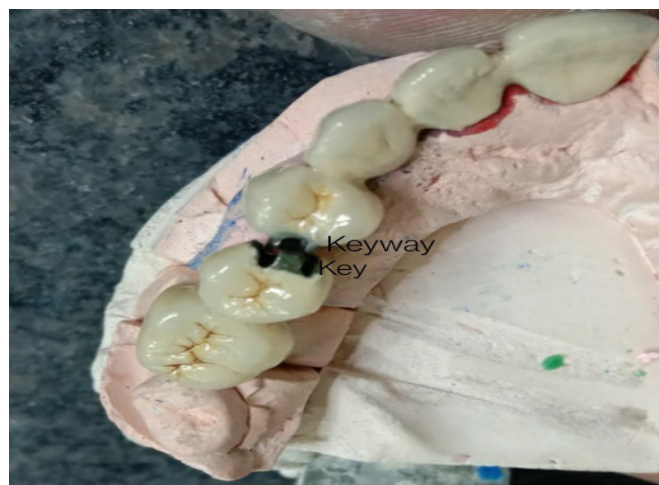

Fig. 6. Completed FDP with non-rigid (Tenon-mortise) connector between 14 and 15.

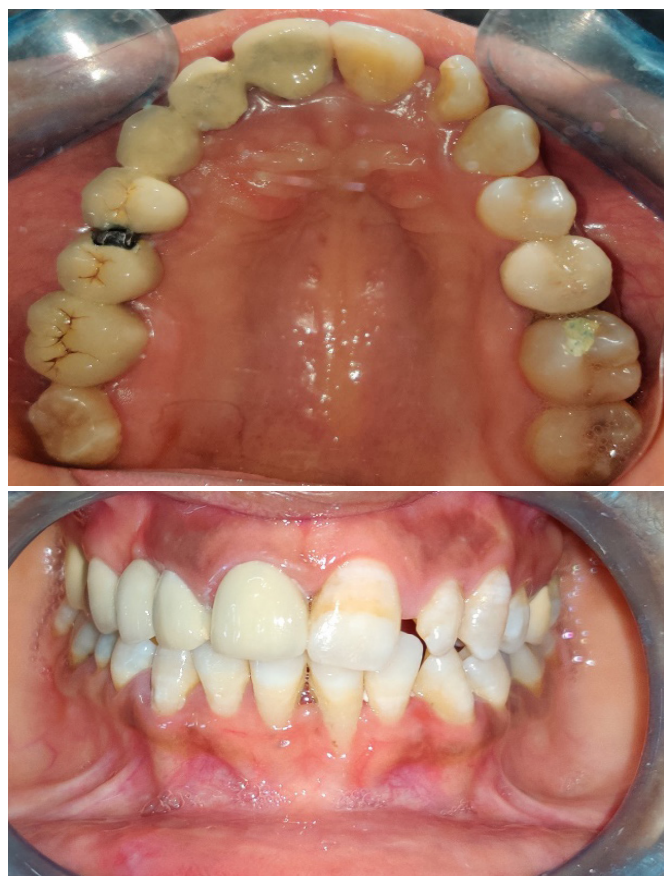

Fig. 7. FDP with non-rigid connector- In situ

Gold Label 1, GC INDIA) was used for the cementation. An articulating paper was used to check the occlusion after removing the extra cement.

Discussion

As a result of the pier abutment, a fulcrum-like situation occurs, which can cause failure of the weakest of the terminal abutments [3]. In a stress breaker, shear stresses are concentrated on the supporting bone and not on the connector. This is the reason that stress breaks are recommended at both ends of the pier abutment. The first molar to central incisor facial lingual movement ranges from 56 to 108 μm , with an intrusion value of 28 μm [4,5]. Furthermore, due to the curvature of the arch, the faciolingual movement of an anterior tooth occurs at a different angle to that of a molar [6]. A long-span prosthesis may experience stresses that will be transferred to the abutments because of these movements [3,7,8]. Due to the distances at which movement occurs, the independent movement of the abutment teeth, and the tendency of the prosthesis to flex, stress may develop around the abutment teeth and between retainers and abutment preparations [1]. It has been suggested that a nonrigid connector be used to reduce this risk [9]. Despite an apparent close fit, movement in a nonrigid connector is sufficient to prevent stress transfer from the loaded segment to the rest of the fixed partial denture [8]. The nonrigid connector is broken stress [3,10-13]. In this case, the maxillary canine and second premolar are missing, leaving the first premolar as a pier abutment.

A Tenon-Mortise (Key-Keyway) connector was employed in this case, which consists of a T-shaped key attached to the pontic and a dovetail keyway placed within a retainer.

The rigid connector can only be used with short-span FDP's that replace one tooth [14,15]. Instead of focusing shear stress in the connectors, a nonrigid FDP transmits it to the supporting bone. It appears to reduce mesiodistal abutment torquing while allowing them to move independently [16,17]. The connector's keyway should be distal to the pier abutment, and the key should be on the mesial side of the distal pontic. This is because the long axes of the posterior teeth often incline somewhat in a mesial direction, and vertically applied occlusal forces cause more movement in this direction. When the connector's keyway is situated on the distal side of the pier abutment, mesial movement more securely seats the key into the keyway [9]. However, placing the keyway on the mesial side causes the key to become unseated during mesial movements [10,18,19]. This could result in pathologic movement of the anterior teeth over time. Using a non-rigid connector distal to the pier abutment, the stress concentration in the pier is minimized. Despite the complexity of fabricating non-rigid connectors, it has been confirmed that the stress-breaking effect caused by incorporation of these connectors particularly in pier abutment situations contributes to long-term durability of the prostheses [20].

Conclusion

This case report discussed the use of a non-rigid connector between the right maxillary first premolar and second premolar, with the first premolar acting as a pier abutment while the central incisor and first molar acted as terminal abutments. Nonrigid connector acted as stress breakers. A tenon-mortise type of non-rigid connector was employed for this case, which reduces the stress transferred to the pier abutment and the rest of the fixed prosthesis, thereby increasing the longevity of the prosthesis and abutments.

Authors' contribution

VS - Conceptualization, Methodology, Resources, Software, Writing – original draft, Writing – review & editing
KKM - Conceptualization, Writing – original draft, Writing – review & editing
BSG and RN - Methodology, Resources, Writing – review & editing

Conflict of interest

None to declare.

References

- Shillingburg HT, Sather DA. Fundamentals of fixed prosthodontics. 4th ed. Quintessence Publishing Co, Inc; 2012.
- Sivakumar S, Management of Partial Edentulism Using Nonrigid Connectors as a Treatment Modality: A Case Report. *Cureus* 2020;12(4): e7790
- Kuruvi A, Joseph S, Jayalekshmi NL, Menon SK. The key to the management of pier abutment: An alternative approach. *J Int Oral Health* 2017;9:136-9.
- Rudd KD, O'Leary TJ, Stumpf AJ. Horizontal tooth mobility in carefully

- screened subjects. *Periodontics* 1964;2:65–68.
5. Parfitt GJ. Measurement of the physiological mobility of individual teeth in an axial direction. *J Dent Res* 1960;39:608–618.
 6. McCall JO, Hugel IM. Movable-removable bridgework: Principles and practice as developed by Herman ES Chayes, DDS. *Dent Items Interest* 1949;71:512–525.
 7. Banerjee S, Khongshei A, Gupta T, Banerjee A. Non-rigid connector: The wand to allay the stresses on abutment. *Contemp Clin Dent*. 2011 Oct;2(4):351-4.
 8. Akulwar RS, Kodgi A. Non-Rigid Connector for Managing Pier Abutment in FPD: A Case Report. *J Clin Diagn Res*. 2014 Jul;8(7):ZD12-3.
 9. Shillingburg HT Jr, Fisher DW. Nonrigid connectors for fixed partial dentures. *J Am Dent Assoc* 1973;87:1195–1199.
 10. Standlee JP, Caputo AA. Load transfer by fixed partial dentures with three abutments. *Quintessence Int* 1988;19:403–410.
 11. Rani P, Malhotra P. Breaking the stress with a non-rigid connector. *Niger Postgrad Med J*. 2020 Oct-Dec;27(4):391-393.
 12. De Souza N, Da Costa GC, Chalakkal P, Mascarenhas K. Fixed functional space maintainer incorporating a tenon-mortise connector. *Contemp Clin Dent* 2018;9:649-51.
 13. Mishra A, Palaskar J, Madhav VN, Chopade SR. Pier abutment: Break the stress. *Ann Prosthodont Rest Dent* 2016;2:126-8
 14. Markley MR. Broken-stress principle and design in fixed bridge prosthesis. *J Prosthet Dent* 1951;1:416–423.
 15. Yaqoob A, Rasheed N, Ashraf J, YaqubG. Nonrigid semi-precision connectors for FPD. *Dent Med Res* 2014;2:17-21
 16. Sutherland JK, Holland GA, Sluder TB, White JT. A photoelastic analysis of the stress distribution in bone supporting fixed partial dentures of rigid and nonrigid design. *J Prosthet Dent* 1980;44:616–623.
 17. Babu K A S, Haripriya P, Pottem S R, Voleti H C K, Tannamala P K, FPD with difference in connectors: A case report. *Int J Oral Health Dent* 2019;5(3):147-150
 18. Prasad DK, Hegde C, Bardia A, Prasad DA. Questionable abutments: General considerations, changing trends in treatment planning and available options. *J Interdiscip Dentistry* 2013;3:12-7.
 19. Patel R, Dahane T, Khungar P, Godbole S, Kambala SS. Safeguarding the pier abutment. *J Datta Meghe Inst Med Sci Univ* 2020;15:495-9
 20. Oruc S, Eraslan O, Tukay HA, Atay A. Stress analysis of effects of non rigid connector on fixed partial denture dentures with pier abutments. *J Prosthet Dent* 2008;99:185-92