

## CASE REPORT

# Double Trouble: Interrupting DAPT and COVID-19

Theofana Mihăilă<sup>1,2</sup>, Aurelian Roșca<sup>1,2</sup>, Bianca Ion<sup>1,2</sup>

<sup>1</sup> “George Emil Palade” University of Medicine, Pharmacy, Science and Technology, Târgu Mureș, Romania

<sup>2</sup> Clinic of Cardiology, Emergency Clinical County Hospital, Târgu Mureș, Romania

## ABSTRACT

Cardiovascular disorders have been described as relevant risk factor for severe COVID infection. Stent thrombosis is a life-threatening complication that may occur subacutely. We present an interesting case of a middle-aged woman who developed acute stent thrombosis while interrupting dual antiplatelet therapy (DAPT) ticagrelor, during an episode of coronavirus disease (COVID-19). In our case, the patient's not-compliance to DAPT, associated with COVID-19 infection and a hyperinflammatory and hypercoagulable state associated with it played a major role in the development of stent thrombosis. The hypercoagulable and hyperinflammatory state associated with COVID-19 has important implications for cardiac patients, especially those undergoing complex coronary intervention, predisposing them to an increased risk of post-PCI complications.

**Keywords:** COVID-19, stent thrombosis, dual antiplatelet therapy, hypercoagulability

## ARTICLE HISTORY

Received: July 13 2022

Accepted: August 15, 2022

## CORRESPONDENCE

**Aurelian Roșca**

Str. Gheorghe Marinescu nr. 50

540136 Târgu Mureș, Romania

Tel: +40 265 372 653

E-mail: rosca\_aurelian@yahoo.com

## INTRODUCTION

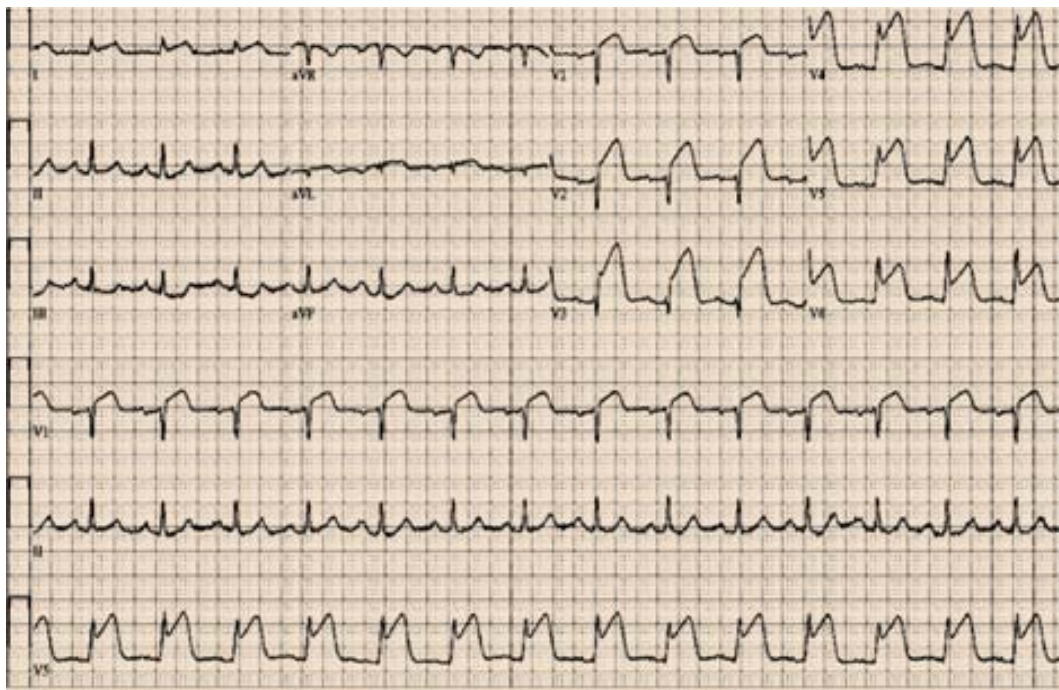
The COVID-19 pandemic has adversely affected the management of the entire spectrum of noncommunicable diseases. It also had a very strong effect on delivery of healthcare for cardiovascular disease, which remains the leading cause of death worldwide.<sup>1–3</sup>

COVID-19 was associated with a significant and abrupt reduction in cardiovascular diagnostic tests across the globe. At the same time, SARS-CoV-2 infection was associated with a significantly longer hospital stay and ventilation time, higher mortality rates, and various postoperative complications.<sup>1,4</sup>

Cardiovascular disorders have been described as relevant risk factors for severe COVID infection. On the other hand, COVID infection has also been associated with new-onset cardiovascular injuries.<sup>2–5</sup>

Coronary artery disease is considered a high-risk comorbidity of COVID-19 infection. The treatment of patients with acute coronary syndromes (ACS) routinely involves percutaneous coronary intervention (PCI) and the use of intracoronary stents. Stent thrombosis is a life-threatening complication that may occur acutely (in the first 24 hours), subacutely (from 24 hours to 30 days), or late after stent placement.<sup>4,6</sup>

The development and clinical use of drug-eluting stents (DES) in the 2000s was a major breakthrough in the field of interventional cardiology. First-generation DES remarkably reduced the rates of in-stent restenosis and consequent target-lesion revascularization compared to bare-metal stents. However, a major safety concern regarding stent thrombosis emerged with the use of first-generation DES, with its attendant high rates of myocardial infarction (MI) and mortality.<sup>2,4</sup>



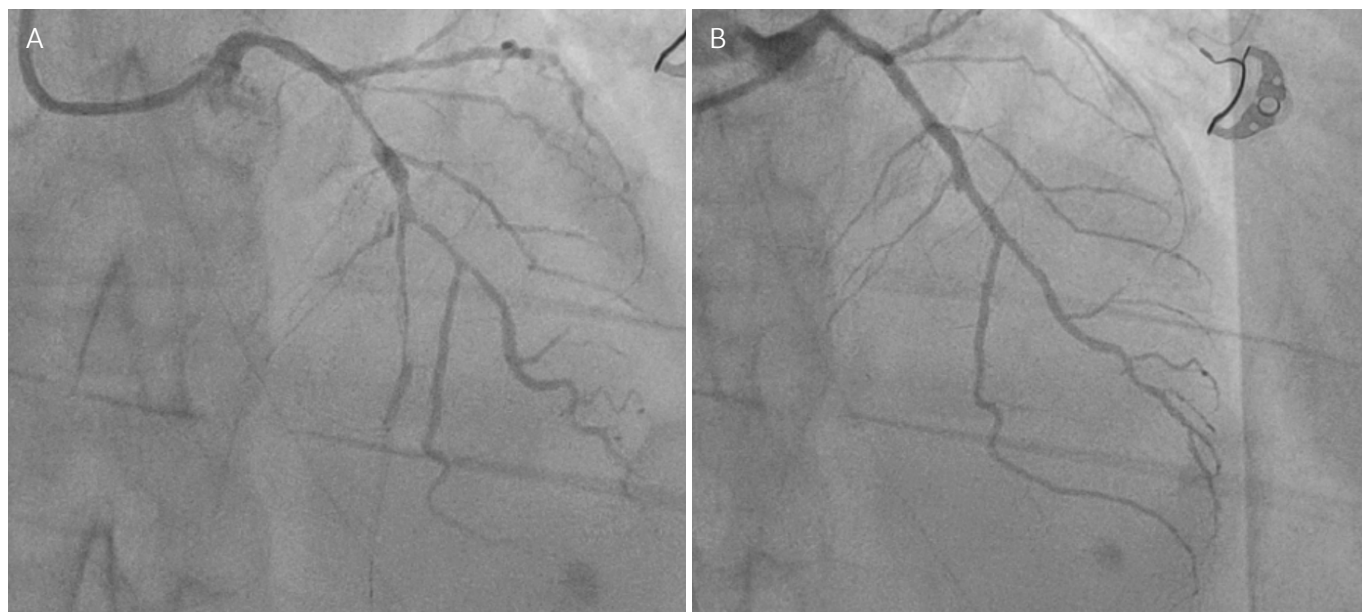**FIGURE 1.** Pre-interventional ECG – first presentation

Ticagrelor is a reversible nonthienopyridine oral P2Y<sub>12</sub> antagonist that provides more potent and consistent platelet inhibition with faster onset and offset of action than clopidogrel.<sup>6,7</sup>

We present an interesting case of a middle-aged woman who developed acute stent thrombosis while interrupting dual antiplatelet therapy (DAPT) ticagrelor, during an episode of coronavirus disease (COVID-19).<sup>7-9</sup>

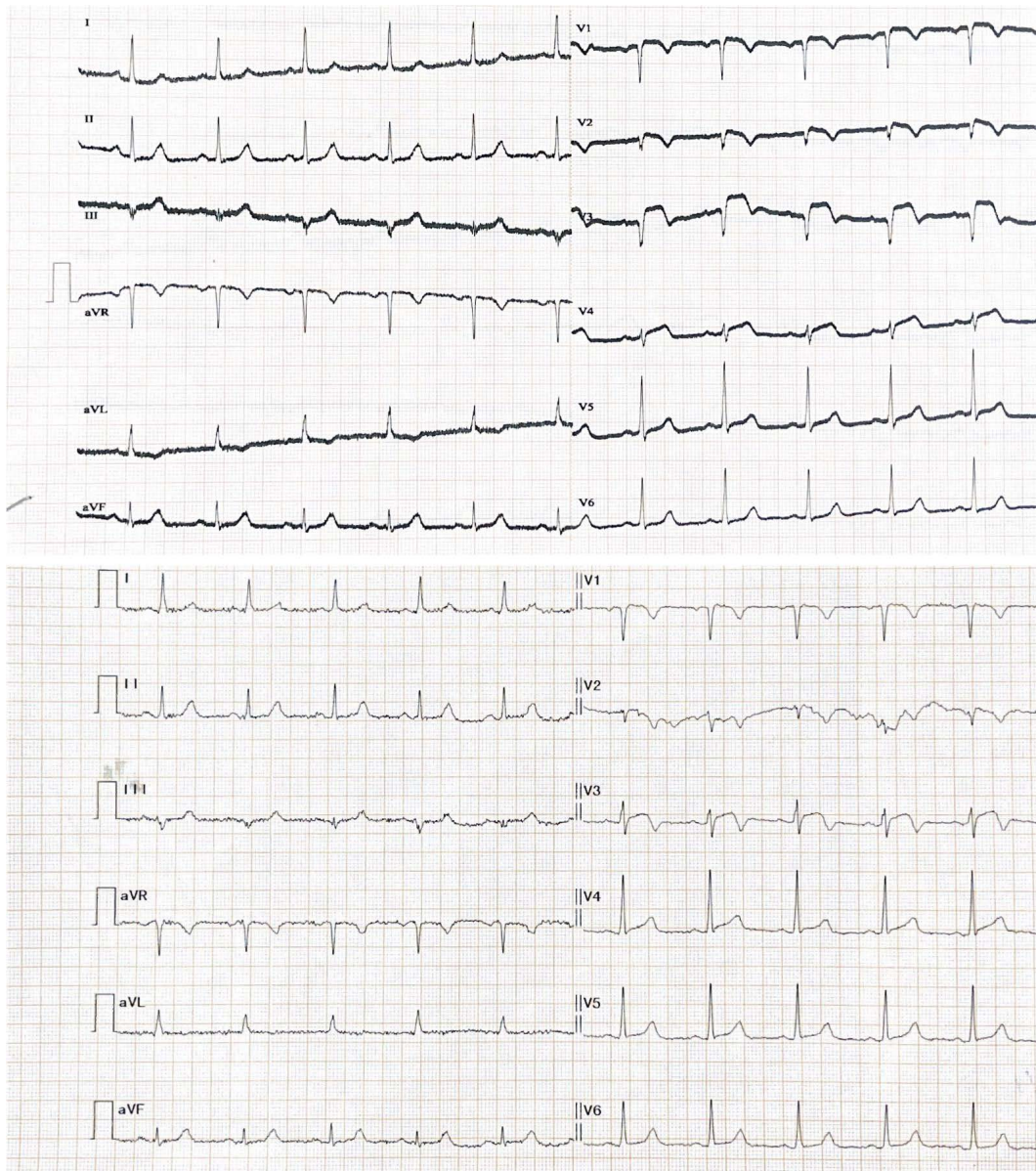
## CASE PRESENTATION

A 54-year-old hypertensive, actually ex-smoker but habitual smoker, dyslipidemic woman was hospitalized two times in a month in our clinic. At the first presentation, the patient was admitted with cardiogenic shock due to multiple episodes of successfully resuscitated ventricular fibrillation, preceded by angina. The onset of anginal



**FIGURE 2.** Interventional aspects. **A** – Pre-interventional aspect of LAD; **B** – Post-interventional aspect of LAD after stenting





**FIGURE 3.** Pre- and post-interventional ECG – second presentation

pain was seven hours before admission. As this case was performed at the peak of a COVID-19 wave in the region, a COVID-19 reverse transcriptase polymerase chain reaction (RT-PCR) was performed prior to the procedure, as mandated by the institutional protocol, and it was found to be negative. The electrocardiography (ECG) revealed ST elevation of 5–7 mm in V1 to V6 and DI, as well as ST-depression in DII and aVF, and she had elevated levels of high-sensitivity cardiac troponin I (hs-cTnI) (3,231 ng/L) and mildly elevated levels of CK-MB. The echocardiographic investigation revealed global akinesia with left ventricular ejection fraction (LVEF) of 35%.

The patient was diagnosed with extensive anterior MI, and after receiving loading doses of aspirin, ticagrelor,

and atorvastatin, she underwent percutaneous coronary angiography which revealed thrombosis of the left anterior descending (LAD) artery treated by thrombectomy and stent implantation. The patient was hemodynamically stable and was discharged home free of angina seven days later, with a LVEF of 40%.

One week after discharge, the patient was returned to the emergency room with anterior MI demonstrated by a new ST-segment elevation in V2 to V4, elevated levels of cardiac enzymes, and anterior wall akinesia with a LVEF of 40%.

Although she was afebrile, had no respiratory symptoms, and had a normal SpO<sub>2</sub>, her RT-PCR COVID-19 test turned out to be positive. She reported the occurrence of

generalized body weakness and fatigue since six to seven days prior to presentation, and that she had stopped taking ticagrelor by her own initiative two days prior to presentation. Urgent coronary angiography was performed immediately, which showed stent thrombosis in the LAD near the origin of the diagonal branch, treated with implantation of a new stent.

The patient and the ethics committee of the institution agreed with the publication of the case.

## DISCUSSION

In a study conducted by He *et al.* in 2020, myocardial injuries were associated with a poorer prognosis for COVID patients.<sup>2</sup> However, the exact interaction mechanism between COVID infection and cardiovascular disorders is yet to be understood. Several mechanisms have been hypothesized for SARS-CoV-2-associated cardiovascular involvements, including coronary plaque destabilization, hypoxia, systemic inflammation, T cell cytokine response, myocardial fibrosis, and direct cardiomyocyte damage.<sup>7</sup>

Although COVID-19 usually presents with respiratory signs and symptoms, various cardiovascular manifestations, including myocardial injury/myocarditis, arrhythmias, MI, and thromboembolism, have been reported since the outbreak of the pandemic. The occurrence of various types of stent thrombosis, from acute to very late stent thrombosis, has been reported in patients with COVID-19 illness. Pathophysiologically, a heightened systemic inflammatory response and a hypercoagulable state associated with the COVID-19 illness have been involved as the major causative factors for increased incidence of both arterial and venous thrombosis during this illness. Also, SARS-CoV-2 has been involved in endothelial injury, endothelial dysfunction, and microcirculatory impairment.<sup>1,5,9</sup>

In our case, the patient's non-compliance to DAPT, associated with COVID-19 infection and a hyperinflammatory and hypercoagulable state associated with it played a major role in the development of stent thrombosis.

## CONCLUSIONS

The hypercoagulable and hyperinflammatory state associated with COVID-19 has important implications for cardiac patients, especially those undergoing complex coronary interventions, predisposing them to an increased risk of post-PCI complications.

## CONFLICT OF INTEREST

Nothing to declare.

## REFERENCES

1. Ayati A, Hosseini K, Hadizadeh A, et al. Surgical coronary revascularization in patients with COVID-19; complications and outcomes: A retrospective cohort study. *Health Sci Rep.* 2022;5:e751. doi: 10.1002/hsr2.751.
2. He XW, Lai JS, Cheng J, et al. Impact of complicated myocardial injury on the clinical outcome of severe or critically ill COVID-19 patients. *Zhonghua Xin Xue Guan Bing Za Zhi.* 2020;48:456–460. doi: 10.3760/cma.j.cn11214.8-20200228-00137.
3. WHO. Clinical management of severe acute respiratory infection when novel coronavirus (2019-ncov) infection is suspected: interim guidance. World Health Organization; 2020. Available at: <https://apps.who.int/iris/handle/10665/330893>
4. Buccheri D, Piraino D, Andolina G, Cortese B. Understanding and managing in-stent restenosis: a review of clinical data, from pathogenesis to treatment. *J Thorac Dis.* 2016;8:E1150–E1162. doi: 10.21037/jtd.2016.10.93.
5. Patel P, DeCuir J, Abrams J, Campbell AP, Godfred-Cato S, Belay ED. Clinical characteristics of multisystem inflammatory syndrome in adults: a systematic review. *JAMA Netw Open.* 2021;4:e2126456. doi: 10.1001/jamanetworkopen.2021.26456.
6. Jariwala P, Bhatia H, Kumar EA. Sub-acute stent thrombosis secondary to ticagrelor resistance – Myth or reality!! *Indian Heart J.* 2017;69:804–806. doi: 10.1016/j.ihj.2017.10.012.
7. Hinterseer M, Zens M, Wimmer RJ, et al. Acute myocardial infarction due to coronary stent thrombosis in a symptomatic COVID-19 patient. *Clin Res Cardiol.* 2021;110:302–306. doi: 10.1007/s00392-020-01663-4.
8. Ortega-Paz L, Capodanno D, Montalescot G, Angiolillo DJ. Coronavirus disease 2019-associated thrombosis and coagulopathy: review of the pathophysiological characteristics and implications for antithrombotic management. *J Am Heart Assoc.* 2021;10:e019650. doi: 10.1161/JAHA.120.019650.
9. Bansal K, Gore M, Nalabothu P. Anterior Myocardial Infarction. Available at: <https://www.ncbi.nlm.nih.gov/books/NBK562234/>