

Management of Dens Invaginatus in a Maxillar Lateral Incisor with Open Apex and Persistent Sinus Tract: a Case Report

SUMMARY

Background/Aim: *Dens invaginatus is a developmental anomaly of teeth. The endodontic treatment of these teeth may be difficult because of adversity in accessing the root canals and also complicated variations of internal structure. In this case, the report is presented the nonsurgical management and follow-up of a tooth with class II dens invaginatus with an open apex and sinus tract. Case Report:* In the radiographic examination, there are two root canals; a primary (main) canal and an invaginated canal. The main canal wide-open at the portal of exit and associated with a large chronic periapical lesion extending to the apex of the maxillary left central incisor. An invaginated canal was not reaching the apex. In a clinical examination, a sinus tract was detected in the labial gingiva. After apexification with using MTA was applied, the endodontic treatment was completed. In 12 month recall, a gray discoloration was detected and internal bleaching with 35% hydrogen peroxide was applied. Finally, the tooth was restored using composite resin. 12 months follow-up radiographs revealed resolution of periapical radiolucency, trabecular bone formation, and closure of the root apex with the totally asymptomatic tooth. **Conclusions:** The case report shows that tooth with DI that has wide apex and sinus tract can be treated with non-surgical methods, such as immature tooth without anomalies.

Key words: Dens in Dente, Dens Invaginatus, Apexification

**Funda Fundaoğlu Küçükkekenci,
Ahmet Serkan Küçükkekenci**

Faculty of Dentistry, OrduUniversity, Ordu,
Turkey

CASE REPORT (CR)

Balk J Dent Med, 2018;111-114

Introduction

Dens invaginatus (DI) is a developmental malformation of teeth, that perhaps results from an invagination of enamel organ into dental papilla¹. DI, further known as ‘dens in dente’ can spread out to the roots and the pulp cavity, occasionally attaining the apex². Oehlers has classified the DI into three categories. Type I defines a small invagination, covered by enamel, in the crown. In Type II, the DI lengths to the root. It may contact or not with the pulp. In Type III, the invagination invades through the root, reaching the apical space with a secondary foramen. There is no contact with the dental pulp. The invagination is entirely covered by enamel or cement^{3,4}.

DI radiographically seems as radiopaque lines within the dentin⁵. Clinically, DI exhibits unusual crown morphology². The enamel lining is sometimes defective and develops caries, which can lead to dentin or pulpal exposure and eventual pulpal pathosis. The affected pulp tissue frequently undergoes necrosis⁶. If DI is detectable early, it is possible to prevent pulp infection by invagination. There are various treatment options for an invaginated tooth such as preventive sealing, endodontic treatment, periapical surgery, and extraction⁷. Clinicians should be make a plan to prevention for teeth with DI before pathological of pulp signs occur⁸. Tooth with type I and for some forms of Type II may be treated employing conservative therapy, whereas DI Type III that the infection has extended, causing pulp necrosis is

necessary endodontic therapy⁶. Some cases show that DI sometimes associated with wide apical foramen and apical periodontitis^{9,10}. In some cases, it is imperative to provoke the closure of the apical foramen with mineralized tissue or to achieve an unnatural apical barrier to let for condensation of the root filling material¹¹. In cases, DI with open apices could be used MTA to promote an apical seal¹². MTA is a biomaterial with excellent biocompatibility and good sealing property that is usable even in the presence of moisture.

Furthermore, both the patient and the clinicians utilize from the use of MTA as the total treatment time is reduced¹³. Unfortunately, many studies have shown that MTA cause to be discoloration^{14,15}. Should discoloration occur with the use of MTA, the internal bleaching may be used to improve the esthetics¹⁶.

The present case report describes apexification using MTA followed by the endodontic treatment of DI in a maxillary lateral incisor with an open apex and sinus tract, moreover intracoronary bleaching efficacy on the discoloration caused by MTA.

Case report

A 21-year-old female patient applied to, Ordu University, Faculty of Dentistry owing to discontent with the esthetic view of her maxillary lateral tooth. Clinically, both of right (#12) and left lateral incisors (#22) showed an abnormal coronal shape, with smaller mesiodistal diameter. 12 was showed tenderness when exposed to the cold test and electric pulp test but 22 wasn't positive for sensitivity. Moreover, there was a sinus tract in the periapical side around the 22 and the patient was asymptomatic (Figure 1a). Upon radiographic examination, the anomalous was detected the internal structure of 22 that was consistent with Oehlers' Type II dens invaginatus but the malformation didn't show on 12 (Figure 1b). A large radiolucent lesion around the apex of the 22 along with wide-open apical end was detected by intraoral periapical radiograph (Figure 1c). Because of the periradicular lesion was associated with the main canal, a diagnosis of pulpal necrosis with asymptomatic apical periodontitis was made. Nonsurgical endodontic treatment and apexification were planned.

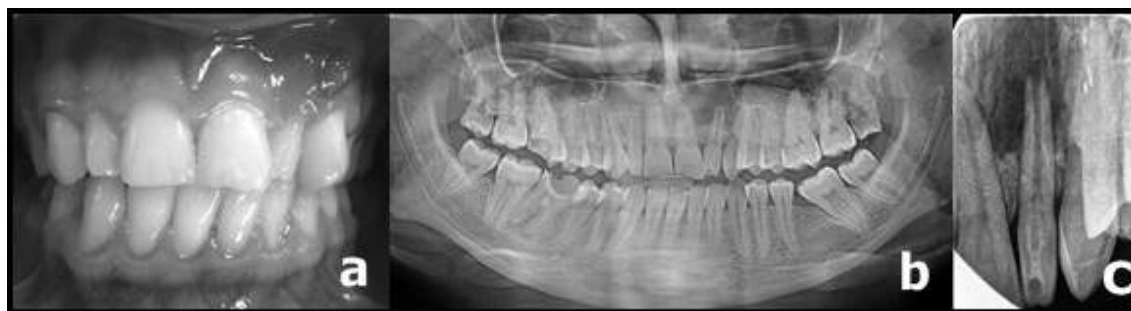

Figure 1 (a) Photograph shows that maxillary left incisor has a sinus tract, (b) panoramic radiograph shows that the contralateral tooth did not reveal malformation, (c) periapical radiography shows that a dens invagination and periradicular lesion

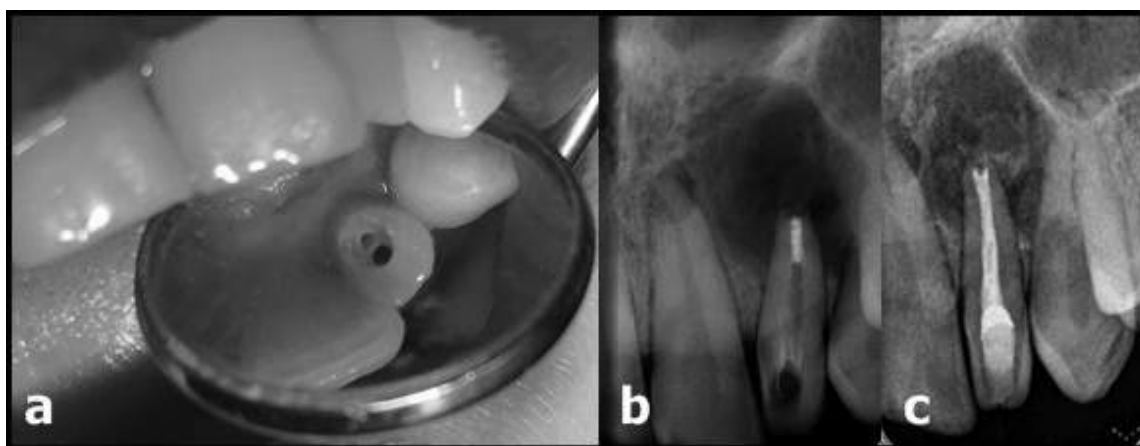


Figure 2 (a) Photograph of the access cavity shows that invagination and main canal, (b) radiograph shows that placement of MTA, (c) radiograph shows that root canal filling

Proper aseptic precautions were carried out, and access (Figure 2a). Necrotic pulp and other organic debris were extirpated using barbed broach under copious irrigation using 2.5% sodium hypochlorite (NaOCl) (ImidentMed, Konya, Turkey) solution. The root canal was prepared using K-type hand files. The root canals were irrigated with 2 ml 2.5 % NaOCl after use of each

file. The final irrigation was made using 5 ml of 17 % EDTA (ImidentMed, Konya, Turkey) for 1 min and 5 ml of 2.5 % NaOCl for 1 min. After irrigation, root canals were dried, and short term canal dressing with calcium hydroxide (Ca(OH₂)) was placed and the access cavity was temporarily sealed with Cavit (3M ESPE US, Norristown, PA, USA) for a period of two weeks for disinfection.

The patient was recalled, $\text{Ca}(\text{OH})_2$ dressing of tooth was removed. Irrigation was performed using 2.5% sodium hypochlorite, 17% EDTA followed by normal saline. Margelos et al. showed that using the combination of EDTA + NaOCl removed more CH compared to using these irrigants alone¹⁷. The canal was dried, and MTA (Pro Root MTA; Dentsply Tulsa dental, Tulsa, UK) was mixed with distilled water to the sandy consistency and was placed with MTA carrier in the apical portion of the canal. Hand pluggers were used to condensing the increments till the thickness of 3-4 mm (Figure 2b). A wet cotton was inserted into the canal, and the access cavity was sealed. The patient was call back following day and the root canal was filled using lateral condensation technique with gutta percha (Meta BioMed, Korea) and AHPlus sealer (DentsplyDetreyGmbH, Germany) (Figure 2c). The direct restoration was done with resin-based composite (Filtek Z350, Body A2, 3M ESPE, USA) and the patient was evaluated subsequently. The patient was recalled a month later and demonstrated no clinical signs and

symptoms. At 6-month recall, the tooth exhibited mobility within physiologic limits and no evidence of periodontal pockets and was functioning normally. Unfortunately, gray discoloration was detected on the tooth (Figure 3a). Radiographic examination revealed repair of the lesion (Figure 3b). 12 months follow-up radiographs revealed resolution of periapical radiolucency, trabecular bone formation, and closure of the root apex with a totally asymptomatic tooth (Figure 3c). Because of discoloration, internal bleaching was planned. The 35% hydrogen peroxide (H_2O_2) was placed into the pulp chamber. (Opalescence®Endo; Ultradent Products Inc., South Jordan, UT, USA). The access cavity was sealed using Cavit. After four days the cavt was removed, the H_2O_2 was irrigated with distilled water, and a fresh H_2O_2 was placed into the access cavity. Next appointment tooth color was satisfactory so that bleaching was stopped. $\text{Ca}(\text{OH})_2$ was placed access cavity for antioxidizing effect and the cavity sealed temporarily. After a week tooth was restored using composite resin (Figure 3d).

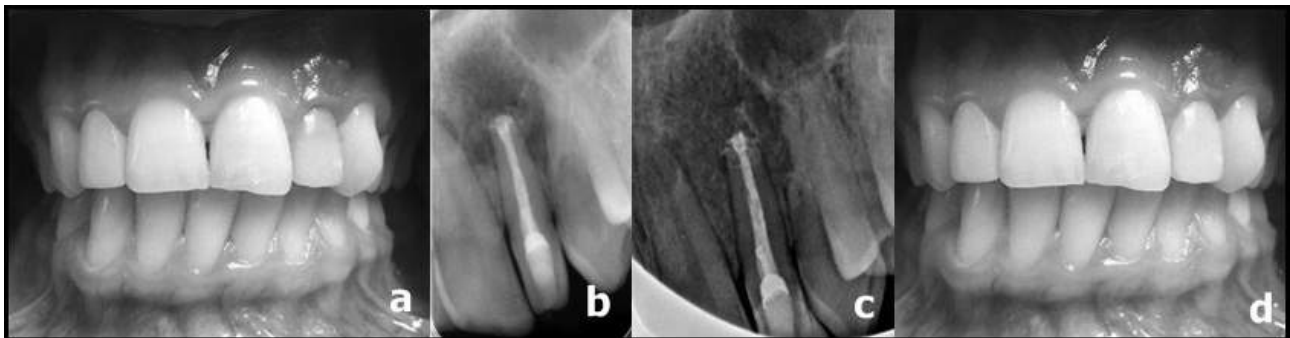

Figure 3 (a) Photograph shows that discoloration of tooth, (b) 6 months follow up with radiographically, (c) 1 year follow up with radiographically, (d) photograph of after bleaching and aesthetic restoration

Discussion

DI is clinically important because of the resultant aberration in anatomy. Teeth with DI have profound fissures, which can harbor structural deformity. It is possible for dental caries to easily reach the pulp chamber in DI cases. This relationship is caused by dental pulp infection and necrosis, followed by periapical or periodontal abscess¹⁸.

This case report shows of Oehlers' type II DI with a sinus tract, necrosis pulp, and a periradicular pathology. The left lateral incisor wasn't tender to the pulp sensitivity test. Two canals were identified in the tooth. The invaginated canal did not reach the apex. The only main canal was associated with a periapical lesion. In spite of the fact that the invagination is not a real canal and it doesn't reach to apex, obturation is important because the enamel and dentin of the invagination are poor, and that's why irritants may smoothly diffuse to the main canal and cause infection⁷. Some cases report that the main canal was supposed to include vital pulp, and CBCT examination did not show any contact between the invagination and the

root canal¹⁹. Currently, advanced CBCT imaging can help the indication as well as the treatment plan and follow-up of teeth with DI²⁰. But before CBCT examination, a consideration of danger against utility should be considered, particularly in juvenile patients. In this case, periapical radiographs were sufficient for defining the type and pulpal relationship of DI.

The complicated anatomy of teeth with DI makes endodontic therapy challenging, particularly in cases with wide apex. But conservative root canal treatment of a tooth with DI is probable in some cases^{10,21}. We chose nonsurgical endodontic procedures in the present case.

MTA can be used in cases of DI with open apex for apexification. MTA is both of biocompatibility and it is less cytotoxic because of its alkaline pH²². Due to the presence of calcium and phosphate ions in MTA, it can support cementum deposition²³. Current data show that MTA may be used as an apical barrier in teeth with necrotic dental pulp and open apex²⁴. However, apexification with MTA apical plug requires specific facilities such as points and carriers to facilitate its insertion, and correct adaptation within the ideal apical

limit may be more difficult in extremely large foramina. We used MTA plugger for placed MTA into apically. The plugger enables insertion of the MTA easier, although radiographic confirmation at this stage cannot be overlooked²⁵. We benefited from radiography to display the MTA plug at this stage. Another disadvantage of MTA is that it causes tooth discoloration²⁶. The discoloration associated with the use of MTA was observed. The discoloration was bleached with intracoronal bleaching technique. The aesthetic restoration of the tooth was accomplished using a composite resin that provides an aesthetic appearance.

The 6 months follow-up, the tooth was asymptomatic and there was a reduce in the dimension of the periapical lesion. The 12 months follow-up, the tooth offered no tenderness to percussion, and the periodontal structure was healthy and aesthetic appearance was satisfaction. Radiographic examination indicated an improvement of the lesion.

Conclusions

The case report shows that tooth with DI that has wide apex and sinus tract can be treated with non-surgical methods, such as immature tooth without anomalies.

References

1. Vier-Pelisser FV, Morgental RD, Fritscher G, Ghisi AC, Borba MG, Scarparo RK. Management of Type III Dens Invaginatus in a Mandibular Premolar: A Case Report. *Braz Dent J*, 2014;25:73-78.
2. Hulsmann M. Dens invaginatus: aetiology, classification, prevalence, diagnosis, and treatment considerations. *Int Endod J*, 1997;30:79-90.
3. Oehlers FA. Dens invaginatus (dilated composite odontoma). I. Variations of the invagination process and associated anterior crown forms. *Oral Surg Oral Med Oral Pathol*, 1957;10:1204-1218.
4. Bramante CM, de Sousa SM, Tavano SM. Dens invaginatus in mandibular first premolar. *Oral Surg Oral Med Oral Pathol*, 1993;76:389.
5. Gound TG, Maixner D. Nonsurgical management of a dilacerated maxillary lateral incisor with type III dens invaginatus: a case report. *J Endod*, 2004;30:448-451.
6. de Sousa SM, Bramante CM. Dens invaginatus: treatment choices. *Endod Dent Traumatol*, 1998;14:152-158.
7. Yang J, Zhao Y, Qin M, Ge L. Pulp revascularization of immature dens invaginatus with periapical periodontitis. *J Endod*, 2013;39:288-292.
8. Tsurumachi T. Endodontic treatment of an invaginated maxillary lateral incisor with a periradicular lesion and a healthy pulp. *Int Endod J*, 2004;37:717-723.
9. Steffen H, Splieth C. Conventional treatment of dens invaginatus in maxillary lateral incisor with sinus tract: one year follow-up. *J Endod*, 2005;31:130-133.
10. Demartis P, Dessi C, Cotti M, Cotti E. Endodontic treatment and hypotheses on an unusual case of dens invaginatus. *J Endod*, 2009;35:417-421.
11. Al Ansary MA, Day PF, Duggal MS, Brunton PA. Interventions for treating traumatized necrotic immature permanent anterior teeth: inducing a calcific barrier & root strengthening. *Dent Traumatol*, 2009;25:367-379.
12. Reddy YP, Karpagavinayagam K, Subbarao CV. Management of dens invaginatus diagnosed by spiral computed tomography: a case report. *J Endod*, 2008;34:1138-1142.
13. Simon S, Rilliard F, Berdal A, Machtou P. The use of mineral trioxide aggregate in one-visit apexification treatment: a prospective study. *Int Endod J*, 2007;40:186-197.
14. Kohli MR YM, Setzer FC, Karabucak B. Spectrophotometric Analysis of Coronal Tooth Discoloration Induced by Various Bioceramic Cements and Other Endodontic Materials. *J Endod*, 2015;41:1862-1866.
15. Kang SH SY, Lee HS, Kim SO, Shin Y, Jung IY, Song JS. Color changes of teeth after treatment with various mineral trioxide aggregate-based materials: an ex vivo study. *J Endod*, 2015;41:737-741.
16. Belobrov I, Parashos P. Treatment of tooth discoloration after the use of white mineral trioxide aggregate. *J Endod*, 2011;37:1017-1020.
17. Margelos J, Eliades G, Verdelis C, Palaghias G. Interaction of calcium hydroxide with zinc oxide-eugenol type sealers: a potential clinical problem. *J Endod*, 1997;23:43-48.
18. Cengiz SB, Korasli D, Zirman F, Orhan K. Nonsurgical root canal treatment of dens invaginatus: reports of three cases. *Int Dent J*, 2006;56:17-21.
19. Pitt Ford HE. Peri-radicular inflammation related to dens invaginatus treated without damaging the dental pulp: a case report. *Int J Paediatr Dent*, 1998;8:283-286.
20. Patel S. The use of cone beam computed tomography in the conservative management of dens invaginatus: a case report. *Int Endod J*, 2010;43:707-713.
21. Chen YH, Tseng CC, Harn WM. Dens invaginatus. Review of formation and morphology with 2 case reports. *Oral Surg Oral Med Oral Pathol Oral Radiol Endod*, 1998;86:347-352.
22. Jung M. Endodontic treatment of dens invaginatus type III with three root canals and open apical foramen. *Int Endod J*, 2004;37:205-213.
23. Maroto M, Barbería E, Planells P, Vera V. Treatment of a non-vital immature incisor with mineral trioxide aggregate (MTA). *Dent Traumatol*, 2003;19:165-169.
24. Nair PN. Pathogenesis of apical periodontitis and the causes of endodontic failures. *Crit Rev Oral Biol Med*, 2004;15:348-381.
25. Chueh LH, Ho YC, Kuo TC, Lai WH, Chen YHM, Chiang CP. Regenerative endodontic treatment for necrotic immature permanent teeth. *J Endod*, 2009;35:160-164.
26. Parirokh TM. Mineral trioxide aggregate: a comprehensive literature review-Part III: Clinical applications, drawbacks, and mechanism of action. *J Endod*, 2010;36:400-413.

Received on March 26, 2017.

Revised on May 24, 2017.

Accepted on June 2, 2017.

Correspondence:

Ahmet Serkan Küçükekenci
Department of Prosthodontics, Dentistry Faculty
Ordu University, Ordu, Turkey
e-mail address: serkankucukekenci@gmail.com