

## Case Report

# A case report of simultaneous robot-assisted nephroureterectomy and robot-assisted total laparoscopic hysterectomy

Shugo Yajima,<sup>1</sup>  Yasukazu Nakanishi,<sup>1</sup> Shin Takenaka,<sup>2</sup> Yuki Koike,<sup>2</sup> Suguru Odajima,<sup>2</sup> Naoya Okubo,<sup>1</sup> Yosuke Umino,<sup>1</sup> Madoka Kataoka,<sup>1</sup> Hiroshi Tanabe<sup>2</sup> and Hitoshi Masuda<sup>1</sup>

Department of <sup>1</sup>Urology and <sup>2</sup>Gynecology, National Cancer Center Hospital East, Kashiwa City, Chiba, Japan

### Abbreviations & Acronyms

CT = computed tomography

MRI = magnetic resonance imaging

RANU = robot-assisted nephroureterectomy

RARC = robot-assisted radical cystectomy

RATLH = robot-assisted total laparoscopic hysterectomy

**Correspondence:** Yasukazu Nakanishi M.D., Ph.D., National Cancer Center Hospital East, 6-5-1 Kashiwa no ha, Kashiwa City, Chiba 277-8577, Japan. Email: [yanakani@east.ncc.go.jp](mailto:yanakani@east.ncc.go.jp)

### How to cite this article:

Yajima S, Nakanishi Y, Takenaka S *et al.* A case report of simultaneous robot-assisted nephroureterectomy and robot-assisted total laparoscopic hysterectomy. *IJU Case Rep.* 2023; 6: 190–193.

This is an open access article under the terms of the [Creative Commons Attribution-NonCommercial-NoDerivs](#)

License, which permits use and distribution in any medium, provided the original work is properly cited, the use is non-commercial and no modifications or adaptations are made.

Received 22 November 2022; accepted 9 March 2023.

Online publication 21 March 2023

**Introduction:** Robot-assisted surgery is spreading across surgical specialties as a less invasive alternative to conventional laparoscopic and open surgery.

**Case presentation:** In this report, robot-assisted total laparoscopic hysterectomy and robot-assisted nephroureterectomy were performed simultaneously for a 69-year-old Japanese female with giant cervical polyp and ureteral cancer. All specimens could be removed from the vagina. The operative time was 379 min, the estimated intraoperative blood loss was 29 mL, and the patient was discharged on the sixth postoperative day without complications.

**Conclusion:** We reported our experience with simultaneous robot-assisted nephroureterectomy and robot-assisted total laparoscopic hysterectomy. To our knowledge, this is the first report of simultaneous robot-assisted nephroureterectomy and robot-assisted total laparoscopic hysterectomy surgery.

**Key words:** radical nephroureterectomy, robotic surgery, total hysterectomy, ureteral cancer, urothelial carcinoma.

## Keynote message

We reported the case of simultaneous robotic-assisted nephroureterectomy and robotic-assisted total laparoscopic hysterectomy. By converting the three ports used for nephroureterectomy to hysterectomy, a total of nine ports could be used to perform the procedure, and since all specimens could be removed through the vagina, there was no need to widen the port wound. The operative time was 379 min, the estimated intraoperative blood loss was 29 mL, and the patient was discharged on the sixth postoperative day without any complications.

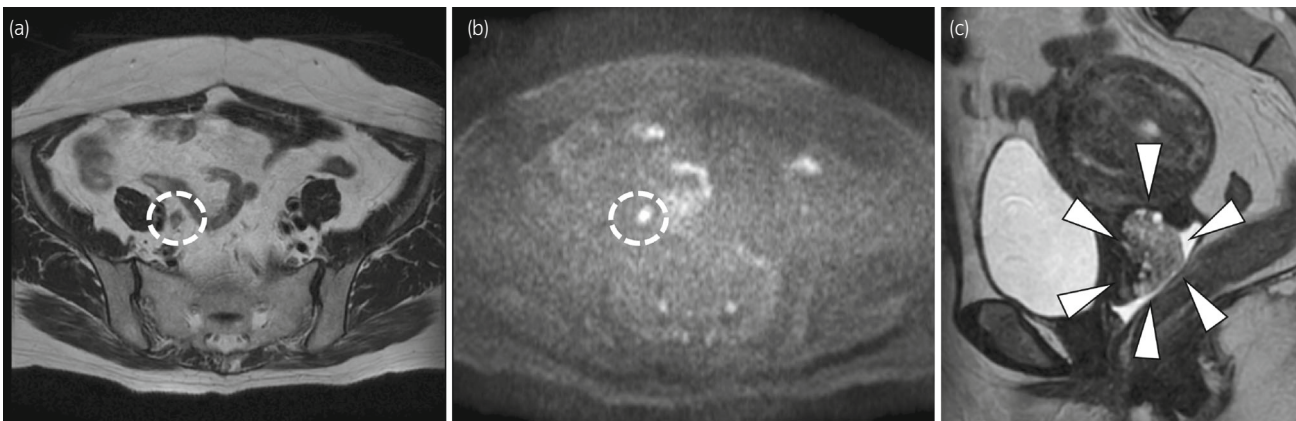
## Introduction

Robot-assisted surgery is increasingly being utilized across surgical specialties as an alternative to conventional laparoscopic and open surgery techniques. In Japan, the National Health Insurance system, which is run by the Health, Labor, and Welfare Ministry, has covered RATLH since April 2018 and RANU since April 2022.

Simultaneous robot-assisted surgeries have been reported, including simultaneous surgery for liver metastases from colorectal cancer,<sup>1</sup> and simultaneous robot-assisted radical cystectomy and RANU.<sup>2–5</sup> These reports describe cases in which several diseases involved multiple organs, but there are few reports of robot-assisted surgery performed simultaneously for two different diseases. Herein, we report a case in which RANU and RATLH were performed simultaneously, and all specimens were removed from the vagina.

## Case presentation

The patient was a 69-year-old Japanese nulligravid female who had previously undergone left oophorectomy at age 40 for a left ovarian cyst. CT and MRI performed for abdominal pain indicated right hydronephrosis and right lower ureteral cancer (Fig. 1a,b), and she was



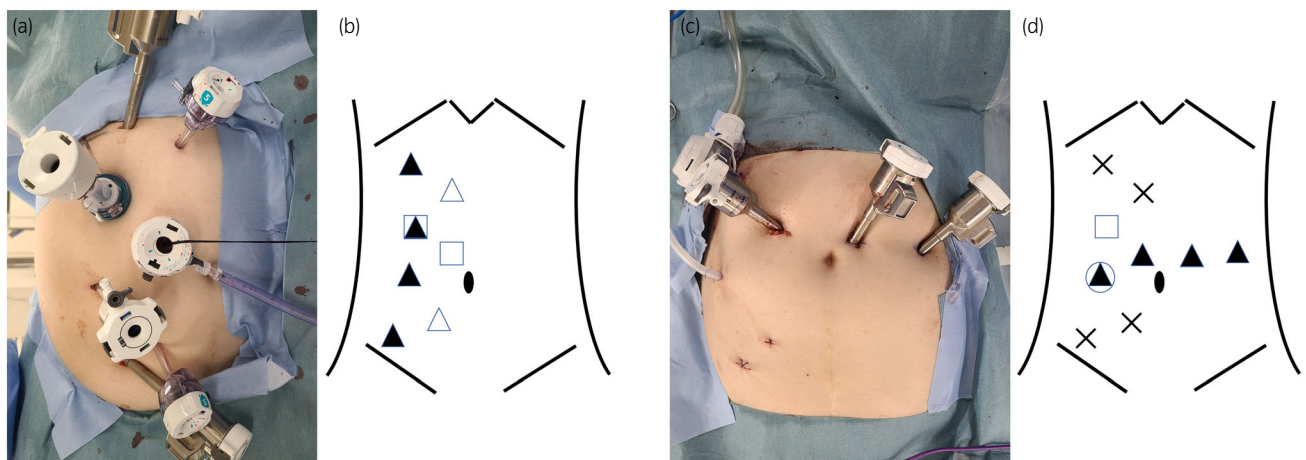
**Fig. 1** MRI showed right ureteral cancer (broken white circles; (a) T2-weighted image, (b) diffusion-weighted image) and giant cervical polyps (c; white arrowheads).

referred to our hospital. There was no distant metastasis. The patient was diagnosed with ureteral cancer, clinical T3, N0, and M0. MRI also showed giant cervical polyps (Fig. 1c). A biopsy was performed on the cervix, which confirmed the absence of malignancy. Due to the patient's distress caused by large amounts of vaginal discharge, the decision was made to perform a hysterectomy. A urology and gynecology team was formed because of concerns about intra-abdominal adhesions during the two-stage procedure. The plan was to perform RANU and RATLH simultaneously and remove all specimens from the vagina.

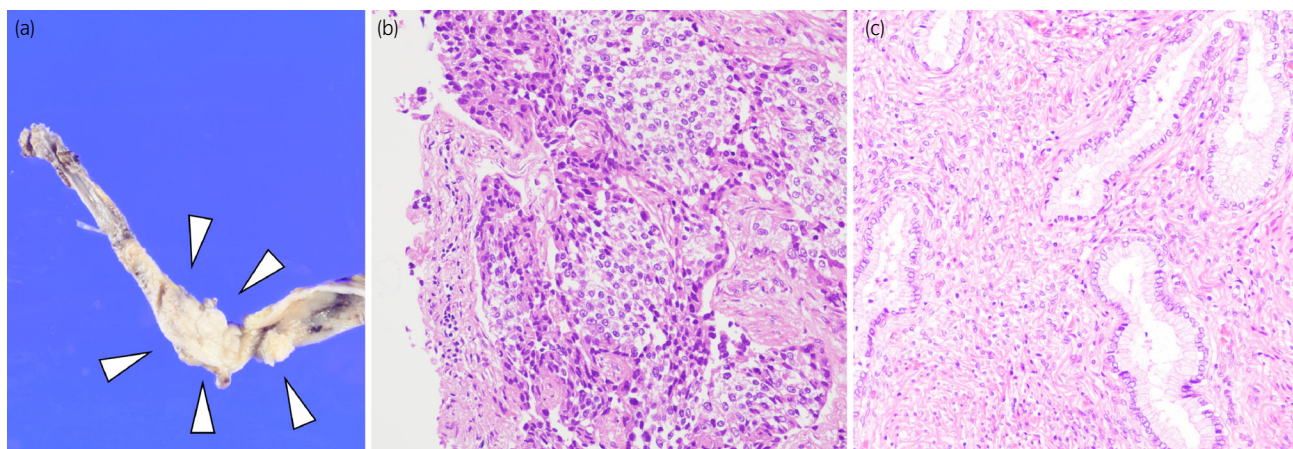
Simultaneously, RANU and RATLH were performed by a highly skilled and experienced team, including a urologist and a gynecologist, using the Da Vinci Xi surgical system (Intuitive Surgical Inc.). The patient was placed in a flank position for RANU. The first 12-mm trocar was placed using the open method, and an additional 8-mm robotic port was inserted into this 12-mm port to serve as a camera port. The remaining three robotic ports and a total of three assistant

ports (one 12 mm and two 5 mm) were placed. An intraoperative photograph and the schema for trocar placement during RANU are shown in Figure 2a,b. Lymph node dissection was not performed. We have performed lower ureteral resections using an extravesical approach; the lower ureter was resected through an incision in the bladder wall near the ureteral orifice, with the bladder cuffed.<sup>6</sup>

After RANU, the kidney and ureter were stored in the specimen retrieval pouch, and the robot was undocked. The patient was placed in the lithotripsy position before the operative field was reprepared and draped again; the trocar used for RANU was diverted to RATLH whenever possible, and two 8-mm robotic ports were added. The port holes not used for RATLH were stitched with nylon sutures to prevent pneumoperitoneal gas leakage. Figure 2c,d shows an intraoperative photograph and the schema of trocar placement during RATLH. First, the uterus was removed from the vagina, and then the specimen retrieval pouch containing the kidney and ureter was also removed from the vagina.



**Fig. 2** Intraoperative photograph (a) and schema of trocar placement (b) in RANU; intraoperative photograph (c) and schema of trocar placement (d) in RATLH. Black triangles indicate 8-mm robotic ports, white triangles indicate 5-mm assistant ports, and squares indicate 12-mm assistant ports. The black triangle in the square indicates a port-in-port (b), and the circle indicates that the port was used as a drain hole (d). Cross marks indicate that the port holes were stitched with nylon sutures to prevent pneumoperitoneal gas leakage (d).



**Fig. 3** The tumor was located in the middle ureter and filled the ureteral lumen (a; white arrowheads). Microscopically, numerous urothelial cells with enlarged atypical nuclei which strongly stain the chromatin were revealed, and they were proliferating in a papillary fashion, suggesting invasive high-grade urothelial carcinoma (b). In the cervix, cervical glandular epithelium and stromal hyperplasia were observed, with an overall polypoid appearance, suggesting a benign endocervical polyp (c).

Console times for RANU and RATLH were 150 and 142 min, respectively; the total operative time was 379 min. The estimated blood loss during surgery was 29 mL. Cystography on the sixth postoperative day confirmed that there were no leaks in the urinary tract, and the patient was discharged the same day. There were no postoperative complications (grade 0) according to the Clavien–Dindo classification. The pathological diagnoses were as follows: The ureter was invasive urothelial carcinoma, high grade, T3. The uterus was a benign endocervical polyp. Figure 3 shows the macroscopic (a) and microscopic (b) findings of ureteral cancer and the microscopic findings of the cervical polyp (c).

## Discussion

This is the first report of a case in which RANU and RATLH were performed simultaneously, and all specimens were removed from the vagina. Robot-assisted surgery is increasingly being utilized in various surgical procedures, not only in urology. The safety of simultaneous surgeries on multiple organs has also been evidenced, for example, in a report on 29 patients who underwent simultaneous robot-assisted surgery for colorectal cancer and synchronous liver metastases. In that procedure, major complications (Clavien–Dindo classification III or higher) were reported in only 7% of cases, and all surgeries were performed with negative margins.<sup>1</sup>

In the current case, to avoid intra-abdominal adhesions in a two-stage procedure, we planned to perform the surgery in one stage and remove all specimens from the vagina. Indeed, with only a small incision on the perineum, all specimens, including the kidney and ureter, could be removed from the vagina, so there was no need to widen the port hole. Furthermore, three of the ports used for RANU were converted to RATLH, allowing the procedure to be completed with nine ports in total. In this report, the console time was 150 min for RANU and 142 min for RATLH, for a total operative time of 379 min, that is, 87 min of nonconsole time. In our previous report on simultaneous RANU and RARC

procedures, the total operative time was 386 min, with a console time of 66 min for RANU and 207 min for RARC, where the nonconsole time was 113 min.<sup>5</sup> Although it must be taken into account that the simultaneous RANU/RARC surgery needed additional time to create the cutaneous ureterostomy, nonconsole time was not short for simultaneous RANU/RATLH surgery or RANU/RARC surgery. For multiple cumbersome procedures such as docking/redocking the robot, repositioning, and inserting new ports, it might be possible to reduce nonconsole time even more by training not only physicians but also nurses and other bedside assistants as a team. Furthermore, in the present case, time was lost by changing the patient's position from the flank position to the lithotripsy position when transferring from RANU to RATLH. However, since the robotic arm can reach the cervix even in a flank position, it may have been possible to perform RANU and RATLH simultaneously without the position change. Although there may not be many opportunities to perform simultaneous RANU and RATLH, whether all procedures can be performed in the flank position is an issue that can be examined in the future.

In conclusion, we have reported our experience with simultaneous RANU and RATLH for a patient with right ureteral cancer with concomitant giant cervical polyps. More information regarding simultaneous surgeries is expected to accumulate in the future.

## Acknowledgments

I wish to acknowledge the help provided by the staff in our institution.

## Author contributions

Shugo Yajima: Writing – original draft. Yasukazu Nakanishi: Writing – review and editing. Shin Takenaka: Writing – review and editing. Yuki Koike: Writing – review and editing. Suguru Odajima: Writing – review and editing. Naoya



Okubo: Writing – review and editing. Yosuke Umino: Writing – review and editing. Madoka Kataoka: Writing – review and editing. Hiroshi Tanabe: Writing – review and editing. Hitoshi Masuda: Supervision; writing – review and editing.

## Conflict of interest

The authors declare no conflict of interest.

## Approval of the research protocol by an Institutional Reviewer Board

Not applicable.

## Informed consent

Written informed consent for the release of this case report and accompanying images has been obtained from the patient.

## Registry and the Registration No. of the study/trial

Not applicable.

## References

- 1 Machairas N, Dorovinis P, Kykalos S *et al*. Simultaneous robotic-assisted resection of colorectal cancer and synchronous liver metastases: a systematic review. *J. Robot. Surg.* 2021; **15**: 841–8.
- 2 Buse S, Alexandrov A, Mazzone E, Mottrie A, Haferkamp A. Surgical benchmarks, mid-term oncological outcomes, and impact of surgical team composition on simultaneous enbloc robot-assisted radical cystectomy and nephroureterectomy. *BMC Urol.* 2021; **21**: 73.
- 3 Alkan E, Canda AE, Turan M, Balbay MD. Simultaneous robot assisted laparoscopic radical nephroureterectomy; genital tract and paravaginal nerve sparing radical cystectomy; superextended lymph node dissection and intracorporeal Studer pouch reconstruction for bladder cancer: robotic hat-trick. *Cent. Eur. J. Urol.* 2014; **67**: 257–60.
- 4 Ou YC, Yang CR, Yang CK, Cheng CL, Hemal AK. Simultaneous robot-assisted nephroureterectomy and cystectomy in patients with uremia and multifocal urothelial carcinoma. *J. Endourol.* 2011; **25**: 979–84.
- 5 Yajima S, Nakanishi Y, Yasujima R *et al*. Simultaneous robot-assisted nephroureterectomy and radical cystectomy. *IJU Case Rep.* 2022; **6**: 14–7.
- 6 Zargar H, Krishnan J, Autorino R *et al*. Robotic nephroureterectomy: a simplified approach requiring No patient repositioning or robot redocking. *Eur. Urol.* 2014; **66**: 769–77.