




## Case Report

# Drug-induced interstitial pneumonia after intravesical Bacillus Calmette-Guerin administration for bladder cancer with scleroderma

Fumie Yoshioka,<sup>1</sup> Taigo Kato,<sup>1</sup>  Yoshihito Shima,<sup>2,3</sup> Koji Hatano,<sup>1</sup> Atsunari Kawashima,<sup>1</sup>   
Shinichiro Fukuhara,<sup>1</sup>  Ryoichi Imamura<sup>1</sup> and Norio Nonomura<sup>1</sup>

Departments of <sup>1</sup>Urology, <sup>2</sup>Respiratory Medicine and Clinical Immunology, and <sup>3</sup>Thermo-Therapeutics for Vascular Dysfunction, Osaka University Graduate School of Medicine, Osaka, Japan

## Abbreviations

ABG = arterial blood gas  
ABPC = ampicillins  
AZM = azithromycin  
BCG = Bacillus Calmette-Guerin  
CIS = carcinoma in situ  
CMV = cytomegalovirus  
CT = computed tomography  
DLST = drug-induced lymphocyte stimulation test  
GCV = ganciclovir  
MEPM = meropenem  
mPSL = methylprednisolone  
NMIBC = nonmuscle invasive bladder cancer  
PSL = prednisolone  
SBT = sulbactam  
ST = sulfamethoxazole and trimethoprim  
TURBT = transurethral resection of the bladder tumor

**Introduction:** Intravesical Bacillus Calmette-Guerin administration is the standard therapy for high-risk nonmuscle invasive bladder cancer and is usually well tolerated. However, some patients experience severe, potentially fatal, complications including interstitial pneumonitis.

**Case presentation:** A 72-year-old female with scleroderma was diagnosed with bladder carcinoma in situ. She developed severe interstitial pneumonitis with the first administration of intravesical Bacillus Calmette-Guerin after the cessation of immunosuppressive agents. Six days after the first administration, she experienced dyspnea at rest, and computed tomography revealed scattered frosted shadows in the upper lung. The following day, she required intubation. We suspected drug-induced interstitial pneumonia and started steroid pulse therapy for 3 days, resulting in a complete response. No exacerbation of scleroderma symptoms or recurrence of cancer was observed 9 months after Bacillus Calmette-Guerin therapy.

**Conclusion:** For patients receiving intravesical Bacillus Calmette-Guerin therapy, close observation of the respiratory condition is necessary for early therapeutic intervention.

**Key words:** BCG, bladder cancer, DLST, interstitial pneumonia, scleroderma.

**Correspondence:** Taigo Kato M.D., Ph.D., Department of Urology, Osaka University Graduate School of Medicine, 2-2 Yamadaoka, Suita, Osaka 565-0871, Japan. Email: kato@uro.med.osaka-u.ac.jp

**How to cite this article:** Yoshioka F, Kato T, Shima Y *et al.* Drug-induced interstitial pneumonia after intravesical Bacillus Calmette-Guerin administration for bladder cancer with scleroderma. *IJU Case Rep.* 2023; 6: 133–136.

This is an open access article under the terms of the [Creative Commons Attribution-NonCommercial-NoDerivs](#) License, which permits use and distribution in any medium, provided the original work is properly cited, the use is non-commercial and no modifications or adaptations are made.

Received 22 August 2022; accepted 12 December 2022.

Online publication 24 January 2023

## Keynote message

Intravesical administration of Bacillus Calmette-Guerin (BCG) is the standard therapy for high-risk nonmuscle invasive bladder cancer and sometimes evokes fatal conditions. We report a case in which steroid pulse therapy was very effective for managing severe interstitial pneumonitis with an early diagnosis, in patients on the first induction of intravesical BCG.

## Introduction

Intravesical administration of BCG is widely used as an adjuvant immunotherapeutic modality for CIS and for the prevention of recurrence of NMIBC.<sup>1,2</sup> Intravesical BCG therapy is usually well-tolerated, however, severe local and systemic complications may occur.<sup>3,4</sup> In particular, interstitial pneumonitis is a rare complication in 0.7% of patients following intravesical BCG therapy that may lead to potentially lethal outcomes.<sup>5</sup>

Here, we describe the case of a 72-year-old woman who received intravesical BCG therapy for CIS of the bladder after the withdrawal of immunosuppressive agents for scleroderma. The patient developed severe interstitial pneumonitis and was treated with steroids, with a complete response.

## Case presentation

A 72-year-old woman with scleroderma presented with frequent urination. Urine cytology was positive, and subsequent cystoscopy revealed irregular bladder mucosa on the posterior wall. Based on these findings, we suspected bladder cancer and performed TURBT. At 2 months, after she was diagnosed with Grade 3 pT1 plus pTis urothelial carcinoma in

TURBT, she underwent a second TURBT, resulting in no malignant findings in the resected specimens. We decided to perform intravesical BCG administration (80 mg Tokyo 172 strain), and she ceased azathioprine and steroids 2 months and 2 days before the administration of BCG because her scleroderma was stable (KL-6 of 651 U/mL).

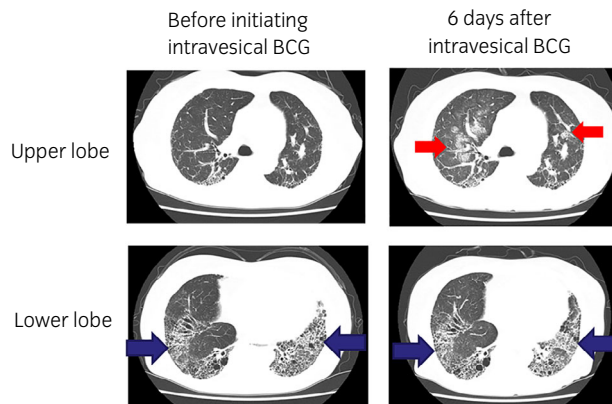
The day after the first administration of intravesical BCG, the patient presented with frequent urination, hematuria, low-grade fever, and oxygen desaturation. Five days later, she experienced dyspnea at rest, and CT revealed scattered frosted shadows centered on the pulmonary hilum in the upper lung fields in addition to coexisting interstitial pneumonitis in the lower lung fields with primary scleroderma (Fig. 1). The clinical course of this patient is shown in Figure 2. We initially suspected drug-induced interstitial pneumonia due to BCG allergy and performed a DLST. *Pneumocystis carinii* and CMV pneumonia were dismissed due to negative results for  $\beta$ -D glucan and CMV antigenemia. PCR tests for tuberculosis bacillus and COVID-19 also ruled out lung tuberculosis and COVID-19 pneumonia.

On the 7th day after intravesical BCG, her respiratory condition deteriorated rapidly, her SpO<sub>2</sub> fell below 90% under 15 L/min of oxygen, and an ABG test revealed a PaO<sub>2</sub> of 55.6 mmHg and PaCO<sub>2</sub> of 34.0 mmHg. There was no change in KL-6 level (621 U/mL). She was intubated with a

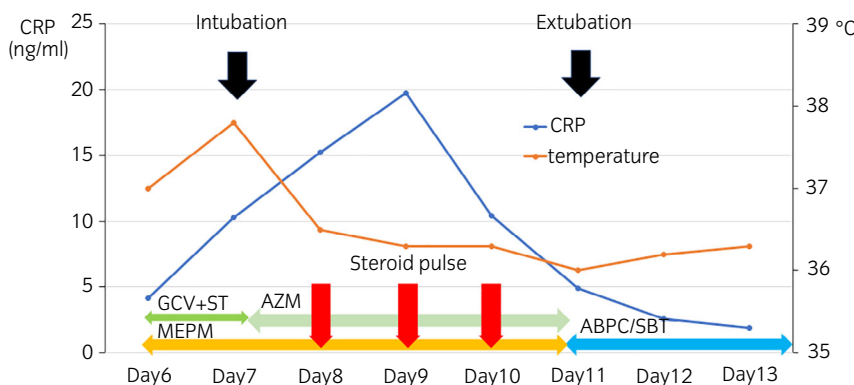
diagnosis of drug-induced interstitial pneumonia (Fig. 3a), then we started 1000 mg mPSL of steroid pulse therapy for 3 days. After switching to oral PSL, pneumonia gradually improved within the next 4 days, and the patient was extubated on the 11th day with the result of an ABG test (PaO<sub>2</sub> of 95.0 mmHg and PaCO<sub>2</sub> of 32.0 mmHg) (Fig. 3b). With a gradual decrease in PSL, the patient's general condition stabilized. Antibiotics were administered throughout the treatment period to prevent secondary bacterial pneumonia. On the 18th day after intravesical BCG administration, the DLST result was positive, and we finally diagnosed the patient with BCG drug-induced pneumonia. During the therapeutic course of interstitial pneumonia, there was no exacerbation of scleroderma symptoms. Finally, the patient maintained no recurrence of cancer for 9 months after BCG therapy.

## Discussion

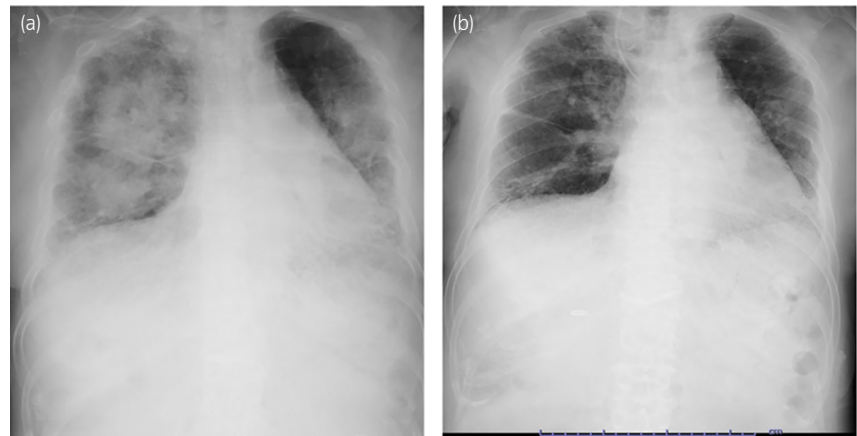
Interstitial pneumonitis is a rare complication of intravesical BCG therapy with signs and symptoms including fever, chills, productive cough, and dyspnea.<sup>5,6</sup> Diagnosis is usually made by the presence of a diffuse infiltrative pattern on chest X-ray or CT scan and a positive biopsy for noncaseating epithelioid granuloma.<sup>6</sup> To date, in Japan, 21 cases of interstitial pneumonia after intravesical BCG therapy have been



**Fig. 1** Chest CT before and after the initiation of intravesical BCG. Six days after initiating the first intravesical BCG therapy, CT examination revealed scattered frosted shadows centered on the pulmonary hilum in the upper lung fields (red arrows), in addition to coexisting interstitial pneumonitis in the lower lung fields with primary scleroderma (blue arrows).



**Fig. 2** Clinical course of the case in the present study. After steroid pulse therapy for 3 days (red arrows), pulmonary infiltration gradually resolved, and the patient was extubated. During the clinical course of treatment, antibiotics were administered to prevent secondary bacterial infection.



**Fig. 3** Chest X rays at the time of intubation and extubation. (a) Chest X ray at the time of intubation.  $\text{PaO}_2/\text{FiO}_2$  ratio was 170. (b) Chest X ray at the time of extubation.  $\text{PaO}_2/\text{FiO}_2$  ratio was 300.

reported, including the case presented here (Table 1). The median patient age was 73 years (range 49–84 years). All cases were male, except for our case. Sixteen patients (76.2%) developed interstitial pneumonia during the first three cycles of intravesical BCG. The mortality rate was 23.8%, despite intensive steroid treatment. There was no patient with autoimmune disease except for our case.

In this case, the patient had scleroderma treated with immunosuppressive drugs before starting intravesical BCG. Intravesical BCG therapy is usually contraindicated in patients receiving immunosuppressive drugs owing to the risk of disseminated infection and the limited efficacy, although a retrospective small cohort study reported the safety of BCG therapy in selected patients who are immunosuppressed (Level C evidence).<sup>7,8</sup> In consideration of the patients' safety, we first confirmed that there was no sign of worsening scleroderma after the withdrawal of azathioprine and steroids in stages.

As drug-induced interstitial pneumonia is highly lethal, early detection is crucial for a prompt differential diagnosis. We successfully excluded the possibility of various infectious diseases, including *Pneumocystis carinii*, CMV, tuberculosis, and COVID-19 pneumonia, and suspected drug-induced interstitial pneumonitis that was later diagnosed using the DLST test. As shown in Table 1, only five cases were diagnosed as DLST-positive since the DLST test may not be conducted in the other cases, which evokes the importance of performing this test.

Although it has been the major treatment for high-risk NMIBC for almost 40 years,<sup>9</sup> the mechanism of intravesical BCG in controlling urothelial carcinoma continues to evolve.<sup>10</sup> Recently, Antonelli *et al.* reported that intravesical BCG leads to proliferation, activation, and differentiation of  $\text{CD4}^+$  T cells as well as previously reported  $\text{CD8}^+$  T cell-driven immunoreactivity.<sup>11,12</sup> Given that the adverse reaction of intravesical BCG may be associated with a

**Table 1** Summary of the previous reports of interstitial pneumonitis after the initiation of intravesical BCG

| Case | Age | Sex    | The number of intravesical BCG | Steroid       | DLST     | Outcome |
|------|-----|--------|--------------------------------|---------------|----------|---------|
| 1    | 58  | Male   | 2                              | PSL 40 mg/day | Unknown  | Alive   |
| 2    | 76  | Male   | 6                              | PSL 40 mg/day | Unknown  | Alive   |
| 3    | 61  | Male   | 3                              | Pulse         | Positive | Alive   |
| 4    | 84  | Male   | 4                              | Pulse         | Unknown  | Alive   |
| 5    | 61  | Male   | 3                              | Pulse         | Unknown  | Alive   |
| 6    | 80  | Male   | 6                              | Unknown       | Unknown  | Alive   |
| 7    | 72  | Male   | 8                              | Pulse         | Unknown  | Death   |
| 8    | 75  | Male   | 2                              | Pulse         | Unknown  | Alive   |
| 9    | 53  | Male   | 6                              | Unknown       | Unknown  | Alive   |
| 10   | 65  | Male   | 6                              | Pulse         | Unknown  | Alive   |
| 11   | 76  | Male   | 4                              | Pulse         | Unknown  | Death   |
| 12   | 67  | Male   | 8                              | PSL 30 mg/day | Unknown  | Alive   |
| 13   | 70  | Male   | 5                              | Pulse         | Unknown  | Death   |
| 14   | 75  | Male   | 4                              | Pulse         | Unknown  | Death   |
| 15   | 78  | Male   | 8                              | Unknown       | Unknown  | Alive   |
| 16   | 81  | Male   | 5                              | Pulse         | Positive | Death   |
| 17   | 80  | Male   | 5                              | Pulse         | Unknown  | Alive   |
| 18   | 49  | Male   | 5                              | Pulse         | Positive | Alive   |
| 19   | 60  | Male   | Unknown                        | Pulse         | Unknown  | Alive   |
| 20   | 75  | Male   | 7                              | Pulse         | Positive | Alive   |
| 21   | 72  | Female | 1                              | Pulse         | Positive | Alive   |

Steroid pulse therapy was performed with 1000 mg/day of mPSL for 3 days.

hypersensitivity immune reaction, corticosteroid use should be initiated immediately for lifesaving while ruling out the possibility of viral infectious disease.<sup>13</sup>

In conclusion, intravesical BCG therapy has proven effective against NMIBC; however, interstitial pneumonia can be fatal. For patients receiving intravesical BCG therapy, close observation of their respiratory condition is necessary for early therapeutic intervention to achieve better clinical outcomes.

## Acknowledgments

The authors thank the patient and her family, who participated in this case report, for their important contributions.

## Author contributions

**Fumie Yoshioka:** Conceptualization; data curation; writing – original draft. **Taigo Kato:** Conceptualization, data curation, formal analysis, writing – original draft, writing – review and editing. **Yoshihito Shima:** Conceptualization; writing – review and editing. **Koji Hatano:** Formal analysis; writing – review and editing. **Atsunari Kawashima:** Formal analysis; writing – review and editing. **Shinichiro Fukuhara:** Formal analysis; writing – review and editing. **Ryoichi Imamura:** Formal analysis; writing – review and editing. **Norio Nonomura:** Supervision; writing – review and editing.

## Conflict of interest

The authors declare that they have no conflict of interest.

## Approval of the research protocol by an Institutional Reviewer Board

Not applicable.

## Informed consent

Written informed consent was obtained.

## Registry and the Registration No. of the study/trial

Not applicable.

## References

- Witjes JA, vd Meijden AP, Debruyne FM. Use of intravesical bacillus Calmette-Guérin in the treatment of superficial transitional cell carcinoma of the bladder: an overview. *Urol. Int.* 1990; **45**: 129–36.
- Morales A, Eidinger D, Bruce AW. Intracavitary Bacillus Calmette-Guerin in the treatment of superficial bladder tumors. *J. Urol.* 1976; **116**: 180–3.
- Green DB, Kawashima A, Menias CO *et al.* Complications of intravesical BCG immunotherapy for bladder cancer. *Radiographics* 2019; **39**: 80–94.
- Pérez-Jacoiste Asín MA, Fernández-Ruiz M, López-Medrano F *et al.* Bacillus Calmette-Guérin (BCG) infection following intravesical BCG administration as adjunctive therapy for bladder cancer: incidence, risk factors, and outcome in a single-institution series and review of the literature. *Medicine* 2014; **93**: 236–54.
- Lamm DL, Blumenstein BA, Crissman JD *et al.* Maintenance Bacillus Calmette-Guerin immunotherapy for recurrent TA, T1 and carcinoma in situ transitional cell carcinoma of the bladder: a randomized Southwest Oncology Group Study. *J. Urol.* 2000; **163**: 1124–9.
- Lamm DL, van der Meijden PM, Morales A *et al.* Incidence and treatment of complications of Bacillus Calmette-Guerin intravesical therapy in superficial bladder cancer. *J. Urol.* 1992; **147**: 596–600.
- Herr HW, Dalbagni G. Intravesical bacille Calmette-Guérin (BCG) in immunologically compromised patients with bladder cancer. *BJU Int.* 2013; **111**: 984–7.
- Kamat AM, Bellmunt J, Galsky MD *et al.* Society for immunotherapy of cancer consensus statement on immunotherapy for the treatment of bladder carcinoma. *J. Immunother. Cancer* 2017; **5**: 68.
- Hudson MA, Ratliff TL, Gillen DP, Haaff EO, Dresner SM, Catalona WJ. Single course versus maintenance Bacillus Calmette-Guerin therapy for superficial bladder tumors: a prospective, randomized trial. *J. Urol.* 1987; **138**: 295–8.
- Li R, Gilbert SM, Kamat AM. Unraveling the mechanism of the antitumor activity of Bacillus Calmette-Guérin. *Eur. Urol.* 2021; **80**: 1–3.
- Antonelli AC, Binyamin A, Hohl TM, Glickman MS, Redelman-Sidi G. Bacterial immunotherapy for cancer induces CD4-dependent tumor-specific immunity through tumor-intrinsic interferon- $\gamma$  signaling. *Proc. Natl. Acad. Sci. USA* 2020; **117**: 18627–37.
- Pettenati C, Ingersoll MA. Mechanisms of BCG immunotherapy and its outlook for bladder cancer. *Nat. Rev. Urol.* 2018; **15**: 615–25.
- Molina JM, Rabian C, D'Agay MF, Modai J. Hypersensitivity systemic reaction following intravesical Bacillus Calmette-Guerin: successful treatment with steroids. *J. Urol.* 1992; **147**: 695–7.