



# Perianal basosquamous carcinoma treated with radiation therapy, a case report

Stephanie Y. Kwan<sup>1^</sup>, Dani Ran Castillo<sup>2</sup>, Allison A. Aka<sup>3</sup>, Gokul Kandala<sup>4</sup>, James Y. Tsai<sup>2</sup>, Kristine Zmaj<sup>5</sup>, Mark E. Reeves<sup>3</sup>, Gary Y. Yang<sup>1</sup>

<sup>1</sup>Department of Radiation Medicine, Loma Linda University Medical Center, Loma Linda, CA, USA; <sup>2</sup>Division of Hematology/Oncology, Loma Linda University Medical Center, Loma Linda, CA, USA; <sup>3</sup>Division of Surgical Oncology, Loma Linda University Medical Center, Loma Linda, CA, USA; <sup>4</sup>Department of Pathology, Loma Linda University Medical Center, Loma Linda, CA, USA; <sup>5</sup>Department of Surgery, Loma Linda VA Medical Center, Loma Linda, CA, USA

**Contributions:** (I) Conception and design: GY Yang, SY Kwan; (II) Administrative support: GY Yang, SY Kwan; (III) Provision of study materials or patients: All authors; (IV) Collection and assembly of data: SY Kwan, DR Castillo; (V) Data analysis and interpretation: All authors; (VI) Manuscript writing: All authors; (VII) Final approval of manuscript: All authors.

**Correspondence to:** Stephanie Y. Kwan. Department of Radiation Medicine, Loma Linda University Medical Center, 11234 Anderson Street, B121, Loma Linda, CA, USA. Email: [Stephaniekwan@llu.edu](mailto:Stephaniekwan@llu.edu).

**Background:** Perianal basal cell carcinoma (BCC) is very rare and estimated to account for 0.08% of all BCC and 0.02% of all anorectal neoplasms. Perianal lesions are more likely to be squamous cell carcinoma (SCC) as BCC usually develops on areas of skin exposed to ultraviolet (UV) light such as the face and arms. Proper diagnosis with the assistance of immunohistochemistry (IHC) stains to distinguish the two entities can help inform the suitable course of treatment.

**Case Description:** Our case is an 82-year-old male with a history of cutaneous BCC on the arms and trunk presenting with a symptomatic perianal lesion. Initial biopsy demonstrated BCC with subsequent IHC studies differentiating from basaloid SCC. Standard treatment includes wide local excision (WLE) but given his poor performance status, radiation only was recommended. He was successfully treated and tolerated 30 Gy in 5 daily fractions.

**Conclusions:** Radiation only is a unique and feasible non-surgical treatment for basosquamous carcinoma of the anus.

**Keywords:** Perianal; basosquamous; basal cell carcinoma (BCC); case report

Submitted Dec 07, 2022. Accepted for publication Feb 17, 2023. Published online Feb 24, 2023.

doi: [10.21037/jgo-22-1244](https://doi.org/10.21037/jgo-22-1244)

**View this article at:** <https://dx.doi.org/10.21037/jgo-22-1244>

## Introduction

Three to four percent of anorectal malignancies occur in the perianal region (1). The most common histology is squamous cell carcinoma (SCC) (2). There have also been case reports of perianal basal cell carcinoma (BCC) (3-6), however the number of cases reported in the literature has been less than 200 (7). BCC of the anus is a very unusual

and unique presentation as most BCC develops on skin exposed to ultraviolet (UV) light. Suggested etiologies include chronic trauma to the area, chronic dermatitis, nevroid BCC syndrome, p53 mutation, immune deficiency, and sexually transmitted infections (5,7). Standard workup requires biopsy for pathologic confirmation and treatment includes wide local excision (WLE) of the lesion (8,9). However as these lesions occur more frequently in

<sup>^</sup> ORCID: [0000-0001-8988-1032](https://orcid.org/0000-0001-8988-1032).

patients with advanced age, patients often do not have optimal functional status to undergo surgical intervention. Additionally, lesions larger than 2 cm may require more extensive surgery (7) and result in larger surgical defects, which can negatively impact a patient's quality of life. We then turn to nonsurgical treatments including topical medications and radiation therapy (RT). We present the following case in accordance with the CARE reporting checklist (available at <https://jgo.amegroups.com/article/view/10.21037/jgo-22-1244/rc>).

## Case description

Our patient is an 82-year-old man with extensive past medical history including cutaneous BCC of the trunk and arm, benign prostate hypertrophy (BPH), coronary artery disease (CAD), chronic obstructive pulmonary disorder (COPD), congestive heart failure (CHF), hypertension (HTN), and monoclonal gammopathy of undetermined significance (MGUS). His previous cutaneous BCC was managed with surgical resection. He first noticed a "small boil" in the perianal area approximately two years previously. It continued to grow in size to a "mushroom shape". He denied any pain or discomfort but occasional bleeding and catching while wiping.

He was referred and presented to surgery clinic and

was noted to have an approximately 3 cm pedunculated perianal mass on the left with some bleeding, no discharge. Rectal exam under anesthesia demonstrated a left lateral anal mass with central ulceration and no palpable inguinal lymphadenopathy. Tissue biopsy that was obtained initially demonstrated BCC. Immunohistochemistry (IHC) staining was diffusely positive for BCL2, negative for EMA, diffusely positive for p40, and partially positive for BerEP4. Diffuse positivity for BCL2, negative EMA, morphology with retraction artifact and peripheral palisading also support the diagnosis. He also had a computed tomography (CT) chest/abdomen/pelvis that demonstrated no evidence of metastatic disease.

His case was presented at a multidisciplinary tumor board. He was staged as American Joint Committee on Cancer (AJCC) 8<sup>th</sup> Edition Anal Carcinoma (Perianal) Stage IIA (cT2N0M0). The decision was made not to proceed with local resection as this would drastically affect his quality of life given his Eastern Cooperative Oncology Group (ECOG) 2 status and decreased mobility. The board recommended proceeding with definitive chemoradiation or radiation only treatment.

Additional pathology testing with p16 staining revealed positivity in two out of three specimens. The diagnosis was revised to BCC with focal squamous differentiation (basosquamous carcinoma) involving the deep margin of lateral border sample and margins of medial aspect sample.

He was treated with a total of five daily treatments using intensity-modulated radiation therapy (IMRT) simultaneous integrated boost (SIB)—6 Gy × 5, total 30 Gy to gross tumor volume (GTV—marked gross tumor) and 5 Gy × 5, total 25 Gy to clinical target volume (CTV—approximate 1 cm expansion from tumor) over five treatment days (seven calendar days). He tolerated treatment well and on follow up three months post radiation, reported that the lesion had decreased in size. He denied any ongoing ulceration or bleeding. At his most recent followup eight months post radiation, he had no evidence of disease. There was an adjacent wound with skin breakdown, which was managed conservatively with wound care (*Figures 1, 2A-2C*). He had no other associated adverse events. He died approximately 14 months after completing radiation treatment due to kidney failure and failure to thrive secondary to dementia.

All procedures performed in the study were in accordance with the ethical standards of the institutional and/or national research committee(s) and with the Helsinki Declaration (as revised in 2013). Written informed consent was obtained from the patient for publication of this case

## Highlight box

### Key findings

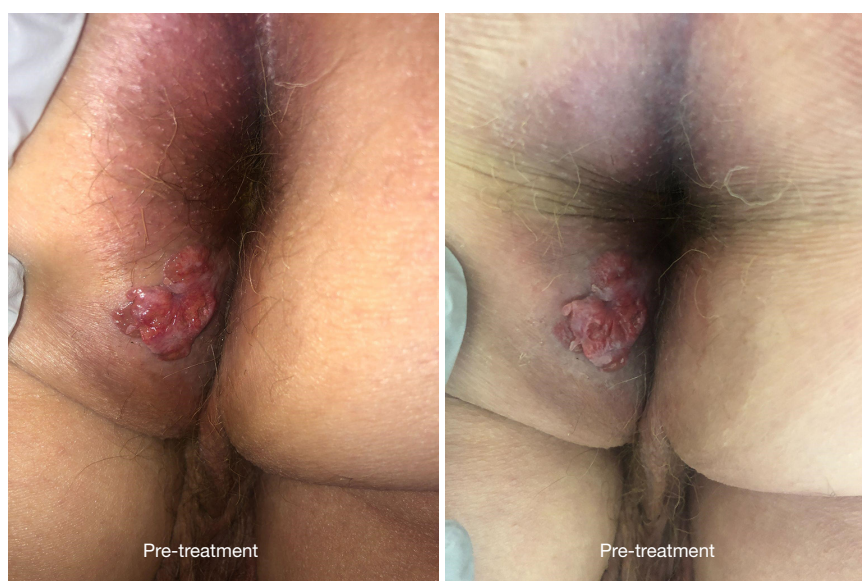- Radiation only for basosquamous carcinoma is a feasible non-surgical treatment option.

### What is known and what is new?

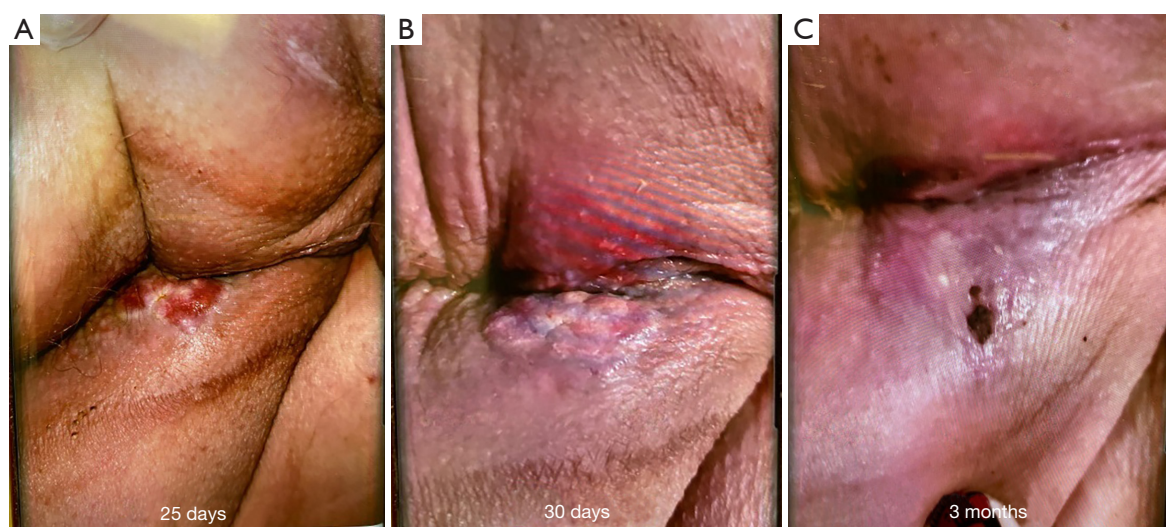
- The most common perianal histology is squamous cell carcinoma (SCC). Basal cell carcinoma (BCC) of the perianal area is very rare as the region is not commonly exposed to UV light. Standard treatment is typically surgical excision.
- This case report demonstrates the viability of radiation only as a non-surgical treatment option. Additionally for patients who cannot tolerate a longer 3–6 weeks course of daily radiation (50–60 Gy), a hypofractionated short course of 5 daily fractions (30 Gy) may be comparable.

### What is the implication, and what should change now?

- Care must be taken to properly differentiate between BCC and basaloid SCC to ensure the proper treatment course. Radiation only should be considered for perianal malignancies for patients who are not surgical candidates or where large surgical defects may affect a patient's quality of life.



**Figure 1** Pre-treatment lesion.



**Figure 2** Post-treatment perianal region. (A) 25 days post-treatment lesion; (B) 30 days post-treatment lesion; (C) 3 months post-treatment lesion.

report and accompanying images. A copy of the written consent is available for review by the editorial office of this journal.

### Discussion

Perianal BCC is rare and could possibly be overdiagnosed as there may be a component of SCC. For our case, IHC

stains helped to corroborate our diagnosis and differentiate from basaloid SCC. These factors include IHC positive staining for BerEP4, BLC2, and retraction artifact (10). Care should be taken to always confirm with a pathologist in order to properly direct treatment. It is also important to distinguish the exact location, i.e., whether it is inside or outside of the anal verge to assist in separating perianal BCC from more aggressive basaloid SCC. These can all



assist in determining the most appropriate and timely treatment.

As noted earlier, there are a variety of possible etiologies. Patients with a history of cutaneous malignancies have an increased risk for perianal BCC (7) with as much as a 50% risk of developing an additional primary BCC within 5 years (6). Additionally areas of chronic trauma such as irritation or wiping as well as scar tissue have an increased risk of developing both BCC and SCC (6). There have also been genetic predispositions such as mutations of p53 or inappropriate activation of sonic hedge-hog pathway (4,5). Our patient had a history of cutaneous BCC of the upper trunk and arms.

Treatment for perianal malignancies typically involves surgical removal of the tumor, as per the National Comprehensive Cancer Network (NCCN) with WLE to clear margins (9,11). However, not all patients are ideal surgical candidates. Radiation becomes an option, as demonstrated by two case reports of patients receiving 54 Gy (4) and 51 Gy (12), but additional details are minimal. There is no standardized radiation regimen given the rarity of such cases. Current NCCN guidelines regarding definitive RT have similar dose fractionation and treatment durations for both BCC and SCC.

Given the patient's poor performance status and presumed inability to complete a long course of radiation treatment, NCCN recommends shorter courses of either 40 Gy over 2 weeks or 30 Gy in 5 fractions over 2–3 weeks. We extrapolated that 30 Gy in 5 fractions over 2–3 weeks has a comparable biologically effective dose (BED) to 25–30 Gy in 5 daily fractions over 1 week. We did not target nodal regions as pre-treatment CT did not demonstrate any sites of metastatic disease and the incidence of metastatic lymph nodes in a mass of this size is low (13). Recurrence after surgical resection is low, <5% with negative margin (4). There are also reported good outcomes with case reports of radiation treatment (4,12) and as evidenced in our patient who had excellent response. We believe that the patient had a good outcome due to the relatively small size of the lesion and no distant metastatic spread. His overall prognosis was poor due to his many other more morbid medical conditions.

## Conclusions

Perianal pure BCC does exist, but it is important to ensure that it is not SCC. Our case suggests short course radiation is a feasible non-surgical treatment for basosquamous carcinoma of the anus.

## Acknowledgments

*Funding:* None.

## Footnote

*Reporting Checklist:* The authors have completed the CARE reporting checklist. Available at <https://jgo.amegroups.com/article/view/10.21037/jgo-22-1244/rc>

*Conflicts of Interest:* All authors have completed the ICMJE uniform disclosure form (available at <https://jgo.amegroups.com/article/view/10.21037/jgo-22-1244/coif>). GYY serves as the current Editor-in-Chief of *Journal of Gastrointestinal Oncology*. The other authors have no conflicts of interest to declare.

*Ethical Statement:* The authors are accountable for all aspects of the work in ensuring that questions related to the accuracy or integrity of any part of the work are appropriately investigated and resolved. All procedures performed in the study were in accordance with the ethical standards of the institutional and/or national research committee(s) and with the Helsinki Declaration (as revised in 2013). Written informed consent was obtained from the patient for publication of this case report and accompanying images. A copy of the written consent is available for review by the editorial office of this journal.

*Open Access Statement:* This is an Open Access article distributed in accordance with the Creative Commons Attribution-NonCommercial-NoDerivs 4.0 International License (CC BY-NC-ND 4.0), which permits the non-commercial replication and distribution of the article with the strict proviso that no changes or edits are made and the original work is properly cited (including links to both the formal publication through the relevant DOI and the license). See: <https://creativecommons.org/licenses/by-nc-nd/4.0/>.

## References

1. Wietfeldt ED, Thiele J. Malignancies of the anal margin and perianal skin. *Clin Colon Rectal Surg* 2009;22:127–35.
2. Eliachevsky C, Templeton E, Nanda AK. Perianal squamous cell carcinoma: A case report. *Int J Surg Case Rep* 2021;81:105739.
3. Gibson GE, Ahmed I. Perianal and genital basal cell carcinoma: A clinicopathologic review of 51 cases. *J Am*

- Acad Dermatol 2001;45:68-71.
4. Hagen ER, Hite N, Griffin J, et al. Perianal basal cell carcinoma: a common cancer in an uncommon location. *J Surg Case Rep* 2020;2020:rjaa151.
  5. Bulur I, Boyuk E, Saracoglu ZN, et al. Perianal Basal cell carcinoma. *Case Rep Dermatol* 2015;7:25-8.
  6. Carr AV, Feller E, Zakka FR, et al. A Case Report of Basal Cell Carcinoma in a Non-Sun-Exposed Area: A Rare Presentation Mimicking Recurrent Perianal Abscess. *Case Rep Surg* 2018;2018:9021289.
  7. Aldana PC, Yfantis HG, John PR. Perianal Basal Cell Carcinoma Successfully Managed with Excisional Biopsy. *Case Rep Dermatol Med* 2019;2019:6268354.
  8. Liu S, Mathis KL, Graham RP, et al. Perianal Basal Cell Carcinoma: 35-Year Experience. *Dis Colon Rectum* 2023;66:217-20.
  9. NCCN Guidelines. 2022. Basal cell skin cancer (Ver 1.2022). Available online: [https://www.nccn.org/professionals/physician\\_gls/pdf/nmsc.pdf](https://www.nccn.org/professionals/physician_gls/pdf/nmsc.pdf). [Accessed 8 February 2022].
  10. Pathologyoutlines.com. 2022. Basal cell carcinoma. Available online: <https://www.pathologyoutlines.com/topic/anusbasalcell.html>. [Accessed 08 October 2021].
  11. NCCN Guidelines. 2022. Squamous cell skin cancer (Ver 2.2022). Available online: [https://www.nccn.org/professionals/physician\\_gls/pdf/squamous.pdf](https://www.nccn.org/professionals/physician_gls/pdf/squamous.pdf). [Accessed 10 November 2022].
  12. Lee HS, Kim SK. Basal cell carcinoma presenting as a perianal ulcer and treated with radiotherapy. *Ann Dermatol* 2015;27:212-4.
  13. Leonard D, Beddy D, Dozois EJ. Neoplasms of anal canal and perianal skin. *Clin Colon Rectal Surg* 2011;24:54-63.

**Cite this article as:** Kwan SY, Castillo DR, Aka AA, Kandala G, Tsai JY, Zmaj K, Reeves ME, Yang GY. Perianal basosquamous carcinoma treated with radiation therapy, a case report. *J Gastrointest Oncol* 2023;14(1):463-467. doi: 10.21037/jgo-22-1244