

REVIEW

How we treat medulloblastoma in adults

E. Franceschi¹, C. Seidel², F. Sahm^{3,4}, K. W. Pajtler^{5,6} & P. Hau^{7*}

¹Department of Medical Oncology, Azienda USL/IRCCS Institute of Neurological Sciences, Bologna, Italy; ²Department of Radiation Oncology, University Hospital Leipzig, Leipzig; ³Department of Neuropathology, University Hospital Heidelberg, Heidelberg; ⁴CCU Neuropathology, German Cancer Research Center (DKFZ) and German Cancer Consortium (DKTK), Heidelberg; ⁵Hopp Children's Cancer Center Heidelberg (KiTZ), Division of Pediatric Neurooncology, German Cancer Research Center (DKFZ) and German Cancer Consortium (DKTK), Heidelberg; ⁶Department of Pediatric Hematology and Oncology, Heidelberg University Hospital, Heidelberg; ⁷Wilhelm Sander NeuroOncology Unit & Department of Neurology, University Hospital Regensburg, Regensburg, Germany



Available online 9 June 2021

Medulloblastoma is a rare tumour in postpubertal patients and adults that is potentially curable. Several subgroups have been defined that are associated with clinical features, have different prognoses, and in some cases offer personalized treatment options. In adults, the sonic hedgehog (SHH) subtype is the most common subtype, followed by the wingless (WNT) and group 4 subtypes. Multimodal therapies allow 5-year overall survival rates of up to 70%. However, in adults, therapeutic evidence from prospective randomized trials is largely lacking. Therefore, regardless of individual risk, most patients are currently treated uniformly with craniospinal chemoradiation with a boost to the tumour bed, followed by maintenance chemotherapy, usually with alkylating agents. In Europe, the so-called Packer regimen, together with cisplatin–etoposide regimens, is the most commonly used chemotherapy option. Targeted treatment approaches have not yet been implemented, although tumour biology is well understood and offers personalized approaches, especially for the SHH subgroup. At relapse, rapid resistance occurs frequently, necessitating repositioning of these agents in an earlier treatment phase. Due to the good to intermediate prognosis, patients with medulloblastoma require structured long-term clinical follow-up including MRI of the brain, monitoring of side effects, and psychosocial and fertility counselling. Recently, clinical trials have been initiated with the aim of de-escalating treatment to reduce toxicity and adding targeted therapies to increase efficacy, with the main goal of therapy to cure the tumour while maintaining the physical and psychosocial integrity of affected patients. This article summarizes our opinion on the diagnosis and treatment of medulloblastoma in adults.

Key words: medulloblastoma, adult, classification, radiotherapy, chemotherapy

DIAGNOSIS AND STAGING

Due to the tumour's typical location in the posterior fossa, patients with medulloblastoma often present with symptoms of increased intracranial pressure, hydrocephalus, cerebellar signs with gait disturbances or ataxia of the extremities and signs of leptomeningeal disease. Due to the high incidence of sonic hedgehog (SHH)-mutated tumours located in the hemispheres of the cerebellum, adults will more often present with ataxia of the extremities. Neurocognitive deficits may also occur, mostly consisting of impaired attention, visual perception and verbal fluency.¹ Medulloblastomas have a propensity to disseminate within the subarachnoid space and, less frequently, to

extraneural locations, e.g. the lymph nodes, bone marrow, skeleton, lung and liver, which may cause symptoms. Therefore, we recommend a thorough clinical and neurological examination at presentation of first symptoms.

Magnetic resonance imaging (MRI) is the modality of choice to assess and follow up medulloblastoma (Table 1). Recommendations for MRI imaging have been defined by the Response Assessment in Pediatric Neuro-Oncology committee (RAPNO) (Figure 1).² Most medulloblastomas show heterogenous enhancement with little oedema. SHH medulloblastomas often have a lateral localization within the cerebellar hemispheres, more oedema and a strong diffusion restriction. As medulloblastomas can produce drop metastases and leptomeningeal involvement, spinal MRI should be carried out preoperatively or after surgery, before an adjuvant treatment decision in all patients and during follow-up if clinical symptoms appear that may be linked to spinal cord affections. As medulloblastoma can present with unusual MRI patterns, we recommend review of MRI scans by an experienced neuroradiologist.

*Correspondence to: Prof. Peter Hau, Wilhelm Sander NeuroOncology Unit & Department of Neurology, University Hospital Regensburg, Franz Josef Strauß-Allee 11, Regensburg 93053, Germany
E-mail: peter.hau@ukr.de (P. Hau).

2059-7029/© 2021 The Author(s). Published by Elsevier Ltd on behalf of European Society for Medical Oncology. This is an open access article under the CC BY-NC-ND license (<http://creativecommons.org/licenses/by-nc-nd/4.0/>).

Table 1. Key recommendations for diagnosis and treatment in adult medulloblastoma

Measures	References
Diagnosis	
Medulloblastoma must be classified according to the latest WHO classification. A renewed classification is expected for 2021, which will amend the recent classification of 2016	6
Craniospinal MRI is the standard of diagnostic imaging. CT should be carried out only in emergencies and contraindications to MRI	2
Staging and response assessment must include CSF cytology to detect leptomeningeal dissemination and other measures if metastases to the lung, lymph nodes, bone or bone marrow are suspected	2
T-stage evaluation should be carried out because it is likely to have prognostic value in adults. Assessment of M stage can be carried out, but its prognostic value in adults is unclear. M0 and M1 patients in adults are therefore usually classified in the same prognostic group	3,4
Therapy	
Gross total resection should be carried out, if possible, without harming the patient. In cases where a gross total resection is not possible, maximum safe resection should be carried out	5
Adults with medulloblastoma should be treated with radiotherapy of the craniospinal axis, with a boost to the tumour bed	8
Adults with medulloblastoma should be treated with systemic therapy, regardless of their risk category	11,12
Early and late side-effects are important issues in adults with medulloblastoma. These include neurotoxicity and systemic toxicity as well as psychosocial and fertility issues. Psychological and social support should be offered to all patients	14

CSF, cerebrospinal fluid; CT, computed tomography; MRI, magnetic resonance imaging; WHO, World Health Organization.

Staging and response assessment should include cerebrospinal fluid (CSF) cytology to detect leptomeningeal dissemination² which should be carried out before surgery or later than 14 days after surgery. T-stage evaluation should be carried out because it is likely to have prognostic value in adults. Assessment of M stage can be carried out, but its prognostic value in adults is unclear. M0 and M1 patients in adults are therefore usually classified in the same prognostic group.^{3,4} Presurgical and postsurgical neurological, neurocognitive, endocrine, auditory, ocular, peripheral nerve and renal function should be documented. All patients should be offered psychological and social support. Given the high cure rates, patients should be counselled for preservation of fertility.

SURGICAL ASPECTS

Surgery with definite tumour removal should be used to relieve a frequent obstruction-causing hydrocephalus. In case immediate definite surgery is not possible, an emergency external ventricular drain should be placed. Vasogenic tumour oedema should be reduced by administration of corticosteroids before surgery.

Preoperative management should follow multidisciplinary discussion in a brain tumour board.

A gross total resection (GTR) should be carried out in all patients if feasible.⁵ In cases where GTR is not feasible, a

maximal safe resection sparing eloquent areas and leaving residual tumour behind should be carried out.

HISTOLOGICAL CLASSIFICATION AND MOLECULAR DIAGNOSIS

According to the concept of an integrated diagnosis of the current and upcoming World Health Organization (WHO) classification of tumours of the central nervous system, medulloblastoma types must be defined by both histological and molecular/genetic features.⁶ All medulloblastoma types correspond to WHO grade 4. Medulloblastomas can morphologically be stratified as classic medulloblastoma, desmoplastic/nodular medulloblastoma, medulloblastoma with extensive nodularity or large cell/anaplastic medulloblastoma. These morphological types correlate to some extent with molecular findings, but overlap and cannot serve as a reliable surrogate. The four molecularly defined types in adult patients include WNT (wingless)-activated, SHH-activated and *TP53* wild-type, SHH-activated and *TP53* mutant, and non-WNT/non-SHH.⁶ Diagnosis of the molecular type can be based on DNA methylation analysis, robustly separating WNT-activated, SHH-activated, and group 3/4 medulloblastoma, the latter representing the non-WNT/non-SHH type. Alternatively, the type can be derived either by detection of WNT or SHH activation for the respective types, or by absence of any of these for the non-WNT/non-SHH type. Pathway analysis and *TP53* assessment required for SHH medulloblastoma workup can be based on DNA sequencing or immunohistochemistry. However, only DNA sequencing reveals exact mutations, with the advantage of informing targeted therapies in SHH medulloblastoma. In adults, SHH-activated, *TP53* wild-type medulloblastomas represent the most frequent type with ~60%-70% of cases.⁷ Approximately 15% of adult medulloblastomas show WNT activation. Non-WNT/non-SHH medulloblastomas represent ~20% of adult medulloblastoma, which are group 4 in almost all cases.

RADIOTHERAPY

Post-operative craniospinal irradiation (CSI) with adequate target volume coverage and sparing of organs at risk is mandatory.⁸ For photon CSI, advanced techniques like helical tomotherapy or volumetric intensity modulated arc therapy (VMAT) should be applied. Proton therapy is an alternative for reduction of long-term side-effects.⁹ A total dose of 36 Gy in daily fractions of 1.8 Gy (5 times/week) or of 35.2 Gy in daily fractions of 1.6 G (5 times/week) can be used. A CSI with a reduced total dose of 23.4 Gy has been established in paediatric trials¹⁰ and will be evaluated in prospective trials in adults with M0-M1 disease. In addition to CSI, a local dose escalation to the tumour bed, with a single dose of 1.8 Gy up to 54.0 or 55.8 Gy, needs to be carried out.⁸ In accordance with paediatric protocols, we recommend initiation of radiotherapy within 28 to 42 days after surgery. A current cerebral MRI is recommended for planning of the tumour bed boost.

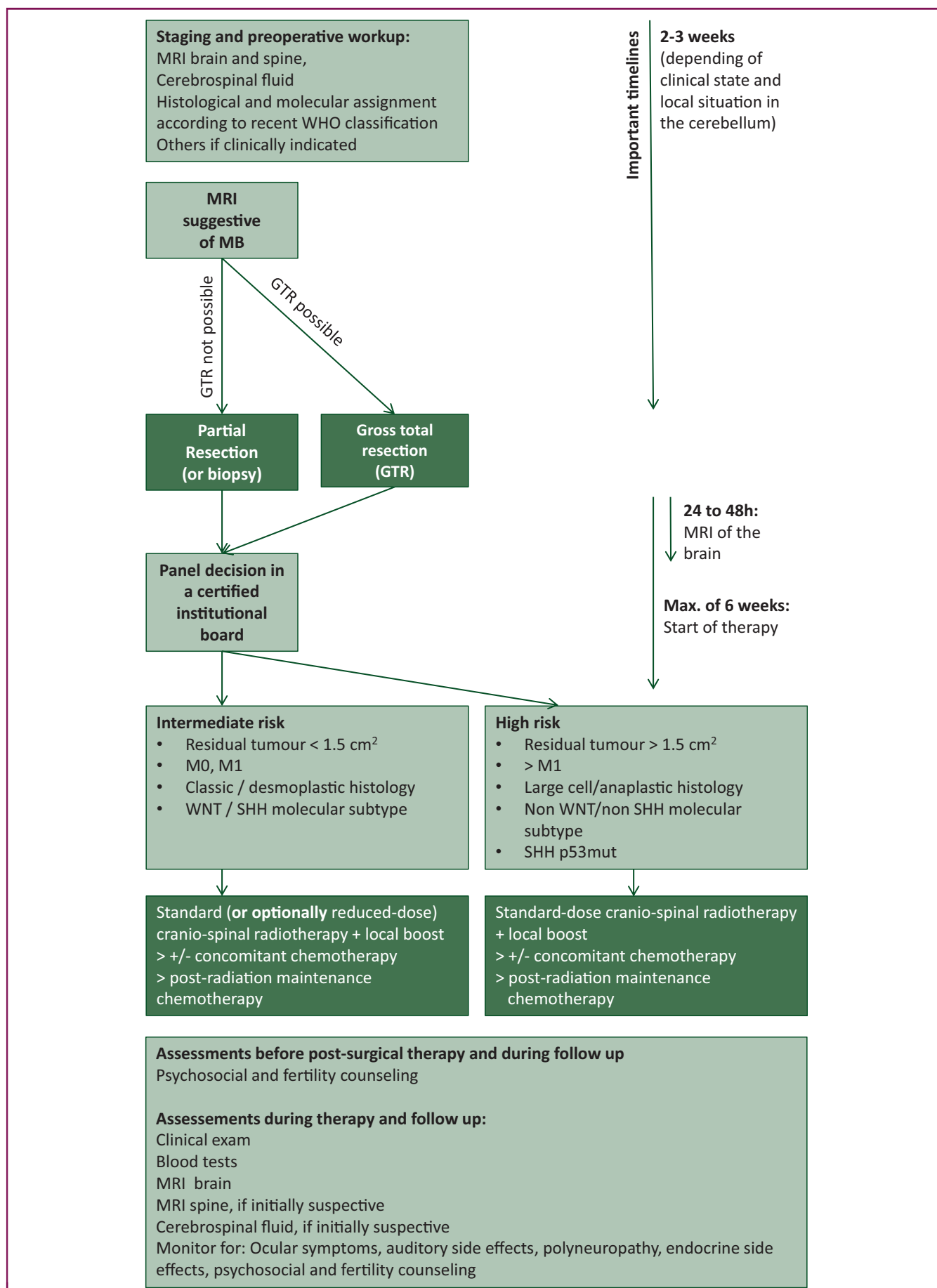


Figure 1. Diagnostic and therapeutic pathway in adult medulloblastoma (first-line therapy situation).

GTR, gross total resection; MB, medulloblastoma; MRI, magnetic resonance imaging; SHH, sonic hedgehog; WHO, World Health Organization; WNT, wingless.

SYSTEMIC THERAPY

Medulloblastomas are chemosensitive tumours. Adult patients with medulloblastoma should be treated with systemic therapy in addition to resection and radiotherapy, irrespective of their risk category. Treatment recommendations are based on paediatric trials, on retrospective analysis of adult cohorts within paediatric trials and on single-arm prospective trials in adults.^{11,12} Meta-analyses also suggest an effect of radiotherapy and chemotherapy in comparison to radiotherapy alone.

The Packer chemotherapy regimen, which is based on lomustine, vincristine and cisplatin,¹⁰ is commonly used in adults, at least in Europe. Tolerance to Packer chemotherapy appears to be worse in adults than in children.¹¹ We therefore recommend reducing the dosing frequency of vincristine to twice weekly to spare neurological toxicity and the maintenance phase to six cycles of chemotherapy to reduce bone marrow toxicity. Substitution of cisplatin by carboplatin to further prevent non-haematologic side-effects is routinely done in patients with cisplatin ototoxicity and nephrotoxicity, but has not been investigated as a primary therapy in adults. Other regimens based on cisplatin and etoposide have also been used in adult patients.¹²

There are no data supporting high-dose chemotherapy with autologous stem-cell transplantation to further improve outcome in adults with medulloblastoma.

OTHER THERAPEUTIC APPROACHES

With the recognition of medulloblastoma subtyping, targeted therapies can be considered in individual cases and are part of recent prospective clinical trials. Smoothed (SMO) inhibitors were investigated in several trials.¹³ Alternative chemotherapy regimens and targeted, immunological and antiangiogenic agents have been investigated in adults, always in small phase I or II trials, and have not been implemented as standard of care yet.

MONITORING AND FOLLOW-UP

In addition to clinical monitoring, MRI should be used to evaluate disease status, treatment response and follow-up. Three-monthly MRI scanning during treatment is common practice and recommended for all subgroups. After the active treatment phase, a 3 to 6-monthly follow-up schedule with cranial MRI until the end of year 5, and a 6-monthly to annual follow-up for up to 10 years may be practical.¹⁴ In case of suspected progressive disease, short-term confirmatory MRI should be carried out. Clinical monitoring and follow-up should include at least clinical examination of endocrinological functions, evaluation of vision, hearing, kidney function, skin integrity, polyneuropathy and fertility, and consider psychosocial and fertility aspects at each visit.

Recent publications suggest that certain subtypes of SHH medulloblastoma may have a higher propensity to relapse, therefore warranting follow-up for extended periods of time.

DIAGNOSIS AND THERAPY IN RELAPSE

Most recurrences are focal or multifocal within the brain. Systemic metastases occur, including extraneural dissemination to the bone marrow, skeleton, lung and liver, with a relatively low rate in SHH-dependent medulloblastoma, a moderate rate of ~5% in WNT-dependent medulloblastoma and a considerably high rate of ~30% in group 4 medulloblastomas. The interval to recurrence varies greatly with median intervals ranging from 24 to 50 months.

For adult patients with medulloblastoma, no definite recommendations have been published for therapy in relapse. Patients should be treated within controlled clinical trials whenever possible. Second surgery should be carried out if a total resection appears possible and in cases of disseminated tumour if symptoms can be relieved. In selected cases, salvage treatment with a second CSI appears feasible. In cases of focal relapse, focal radiotherapy can be used also in adults.

The role of chemotherapy in relapse has not been systematically investigated in adults. We recommend, however, a second chemotherapy approach if the clinical state of the patient allows systemic therapy. Recommendations for the treatment of children with medulloblastoma can be used as a basis for decision making, taking into account the age-specific biology. Intravenous chemotherapy with carboplatin and etoposide was explored in the HIT-REZ-2005 study (NCT00749723); an oral alternative consists of combination chemotherapy with etoposide and trofosfamide. If molecular data are available, targeted agents as sonidegib in SHH-subgroup patients with mutations at the level of SMO or above, with or without cytostatic therapy, should be considered.¹³ There are no data supporting high-dose chemotherapy with stem-cell rescue in recurrent disease.

ACKNOWLEDGEMENTS

We acknowledge the authors of the EANO-EURACAN practice guideline for their tremendous effort that was also of high value for this article.¹⁵

FUNDING

None declared.

DISCLOSURE

EF has received honoraria for lectures, consultation or advisory board participation from the following for-profit company: Karyopharm Therapeutics. CS has received honoraria for lectures, consultation or advisory board participation from the following for-profit companies: AbbVie, Bristol-Myers Squibb, HRA Pharma, Medac, Roche. FS has received honoraria (speaker) lectures, consultation or advisory board participation from the following for-profit companies: AbbVie, Bayer, Illumina. PH has received honoraria for lectures, consultation or advisory board participation from the following for-profit companies: Antisense Pharma, Bristol-Myers Squibb, GlaxoSmithKline, Lilly, Medac, Merck Sharp & Dome, Nanotherm, Novartis, Novocure, Roche. The following for-profit companies have supported clinical trials and contracted research conducted

by PH with payments made to his institution: Antisense Pharma. KWP has declared no conflicts of interest.

REFERENCES

1. Dirven L, Luerding R, Beier D, et al. Neurocognitive functioning and health-related quality of life in adult medulloblastoma patients: long-term outcomes of the NOA-07 study. *J Neurooncol*. 2020;148(1):117-130.
2. Warren KE, Vezina G, Poussaint TY, et al. Response assessment in medulloblastoma and leptomeningeal seeding tumors: recommendations from the Response Assessment in Pediatric Neuro-Oncology committee. *Neuro Oncol*. 2018;20(1):13-23.
3. Padovani L, Sunyach MP, Perol D, et al. Common strategy for adult and pediatric medulloblastoma: a multicenter series of 253 adults. *Int J Radiat Oncol Biol Phys*. 2007;68(2):433-440.
4. Brandes AA, Franceschi E, Tosoni A, Blatt V, Ermani M. Long-term results of a prospective study on the treatment of medulloblastoma in adults. *Cancer*. 2007;110(9):2035-2041.
5. Thompson EM, Hielscher T, Bouffet E, et al. Prognostic value of medulloblastoma extent of resection after accounting for molecular subgroup: a retrospective integrated clinical and molecular analysis. *Lancet Oncol*. 2016;17(4):484-495.
6. Louis DN, Perry A, Reifenberger G, et al. The 2016 World Health Organization classification of tumors of the central nervous system: a summary. *Acta Neuropathol*. 2016;131(6):803-820.
7. Remke M, Hielscher T, Northcott PA, et al. Adult medulloblastoma comprises three major molecular variants. *J Clin Oncol*. 2011;29(19):2717-2723.
8. Packer RJ, Sutton LN, Elterman R, et al. Outcome for children with medulloblastoma treated with radiation and cisplatin, CCNU, and vincristine chemotherapy. *J Neurosurg*. 1994;81(5):690-698.
9. Yock TI, Yeap BY, Ebb DH, et al. Long-term toxic effects of proton radiotherapy for paediatric medulloblastoma: a phase 2 single-arm study. *Lancet Oncol*. 2016;17(3):287-298.
10. Packer RJ, Goldwein J, Nicholson HS, et al. Treatment of children with medulloblastomas with reduced-dose craniospinal radiation therapy and adjuvant chemotherapy: a Children's Cancer Group Study. *J Clin Oncol*. 1999;17(7):2127-2136.
11. Beier D, Proescholdt M, Reinert C, et al. Multicenter pilot study of radiochemotherapy as first-line treatment for adults with medulloblastoma (NOA-07). *Neuro Oncol*. 2018;20(3):400-410.
12. Franceschi E, Minichillo S, Mura A, et al. Adjuvant chemotherapy in average-risk adult medulloblastoma patients improves survival: a long term study. *BMC Cancer*. 2020;20(1):755.
13. Kieran MW, Chisholm J, Casanova M, et al. Phase I study of oral sonidegib (LDE225) in pediatric brain and solid tumors and a phase II study in children and adults with relapsed medulloblastoma. *Neuro Oncol*. 2017;19(11):1542-1552.
14. Salloum R, Chen Y, Yasui Y, et al. Late morbidity and mortality among medulloblastoma survivors diagnosed across three decades: a report from the Childhood Cancer Survivor Study. *J Clin Oncol*. 2019;37:JCO1800969.
15. Franceschi E, Hofer S, Brandes AA, et al. EANO-EURACAN clinical practice guideline for diagnosis, treatment, and follow-up of post-pubertal and adult patients with medulloblastoma. *Lancet Oncol*. 2019;20(12):e715-e728.