

CASE REPORT

Open Access



Development of localized interictal epileptiform discharges following vagus nerve stimulation for lennox-gastaut syndrome: a case report

Renli Qi^{1†}, Wei Wang^{1†}, Yaoduan Xu², Zongling Shen³, Xin Geng¹, Na Li^{3*}, Jinghui Li^{1*} and Hualin Yu^{1,4*}

Abstract

Background: Lennox-gastaut syndrome (LGS) is an epileptic encephalopathy often associated with behavioral and psychiatric disorders. Vagus nerve stimulation (VNS) has been approved effective for LGS treatment. Surgical resection is also an option for LGS patients with focal pathology, offering a high probability of seizure control. However, it is challenging to accurately localize the seizure focus.

Case presentation: The case presented here is a 19-year-old male with a 16-year history of epilepsy with comorbid severe cognitive and psychiatric disorders. He was diagnosed with LGS due to generalized slow spike-wave discharges and multiple seizure types. He was treated with VNS in 2017 at the age of 15. After that, the frequency of the short tonic seizures decreased from 4–5 times per day to 2–5 times per year, and the generalized tonic-clonic seizure pattern did not recur, which had a frequency of 2–4 times per month before the surgery. In 2019, the generalized abnormal interictal epileptiform discharges changed to be localized in the right frontal-temporal lobe at the age of 17 years (2019).

Conclusions: This case report suggested that the generalized epileptiform discharges evolve into localized discharges after VNS treatment, which may help reveal the primary seizure focus for resection surgery in patients with LGS.

Keywords: Vagus nerve stimulation, Lennox-gastaut syndrome, Epileptiform discharges

Background

Vagus nerve stimulation (VNS) has been approved by the US Food and Drug Administration for the treatment of epilepsy and depression in patients aged > 12 years [1, 2]. Approximately 40% of patients treated with VNS show

a 50% reduction of seizures 2–3 years after the treatment [3, 4].

Lennox-Gastaut syndrome (LGS) is considered as a type of epileptic encephalopathy, characterized by multiple drug-resistant seizure types (such as tonic, atonic, atypical absence and tonic-clonic seizures), early onset (3–5 years of age), cognitive decline, and slow spike-wave discharge patterns on EEG [5]. Many patients with LGS have behavioral and psychiatric disorders [6, 7]. The treatment of LGS is very challenging because it requires a combination of anti-epileptic treatments to balance the side effects of medications and further cognitive impairment [8]. VNS has been established as a safe and effective

[†]Renli Qi and Wei Wang contributed equally to this work.

*Correspondence: phoebe11@sina.com; km_ljh@126.com; yhl308@126.com

¹ Second Department of Neurosurgery, First Affiliated Hospital of Kunming Medical University, Kunming 650032, China

³ Department of Psychiatry, First Affiliated Hospital of Kunming Medical University, Kunming 650032, China

Full list of author information is available at the end of the article



treatment for LGS [9, 10]. Approximately 55% of patients with LGS achieve a >50% reduction of seizure frequency 1 to 10 years after VNS treatment. Surgical resection is also an option for LGS patients with focal pathology, which offers a 50% probability for seizure control [11]. Patients have to be carefully identified for surgical resection based on a comprehensive evaluation with seizure semiology, EEG, magnetic resonance imaging (MRI) and functional neuroimaging [12]. Some studies have indicated that patients without localized brain lesions can be reevaluated after corpus callosotomy, when the epileptiform discharges may change from generalized to localized [13].

Here, we report an LGS patient with severe cognitive and psychiatric disorders, whose seizures were successfully controlled with VNS and psychiatric symptoms improved. Beyond our expectation, the epileptic discharges changed from synchronous activity in the whole brain to localized activity after VNS treatment, resembling the previously reported EEG development after corpus callosotomy. To our knowledge, this is the first report of such epileptic discharge change after VNS in LGS patients.

Case presentation

A 19-year-old, right-handed man started to suffer seizures at 3 years of age. The seizures were displayed in two patterns, including tonic seizures manifesting as ascending of bilateral shoulders and proximal upper limbs and head tilting forward, and generalized tonic-clonic seizures often induced by a sudden sound. The tonic seizures occurred approximately 4–5 times per day and the generalized tonic-clonic seizures occurred 2–4 times per month. He was initially treated with valproic acid (VPA) at 3 years of age, which had minimal benefits, and EEG showed continuous and periodic 1- to 2-Hz slow spike-wave interictal epileptiform discharges (IEDs) in the whole brain (Fig. 1a). Then, he was treated with the Chinese patent medicine “Dian Xian Ning” (for detailed information on this medicine, see a previous study [14]), and was free from seizures for 48 months. EEG showed continuous but not periodic 1- to 2-Hz slow spike-wave

discharges at that time (Fig. 1b). However, the patient discontinued the medication on his own and 6 months later, the effectiveness of “Dian Xian Ning” disappeared, so he restarted its use. Then, he was successively treated with 400 mg of carbamazepine, 1200 mg of oxcarbazepine, 400 mg of phenobarbital or 10 mg of topiramate (TPM) daily, all of which provided seizure control at first but became ineffective 1–2 months later. He was treated with 150 mg of lamotrigine (LTG) and 1000 mg of VPA daily before and after the operation. The 48-h long-term video EEG performed before the surgery showed the generalized spike/spike-and-slow wave patterns of IEDs (Fig. 1c). Five tonic seizures with ascending of bilateral shoulders and proximal upper limbs and head tilting forward gestures were recorded during the awake (Fig. 1d) and sleeping states (Fig. 1e). The EEG monitoring also showed two suspected atypical absence seizures (Fig. 1f) and a generalized tonic-clonic seizure (Fig. 1g). All of these seizure types were shown to be generalized.

His parents complained about the symptoms of psychiatric disorders since the age of 1 year and 8 months, such as hyperactivity, running around aimlessly, inability to fall asleep and short sleep times (Pittsburgh Sleep Quality Index [PSQI] score 16, poor sleep quality). Related scales of psychiatric tests before the operation were Hamilton Depression Rating Scale (HAMD) 14, Hamilton Anxiety Scale (HAMA) 14, Positive and Negative Syndrome (PNASS) 95, Clinical Global Impression (CGI) 6, and Social Disability Screening Schedule (SDSS) 15. He had severe mental retardation, which manifested as only speaking very simple words after training, such as ‘father’ and ‘mother’; inabilities to communicate effectively, to learn, to count or to work; and needing to be taken care of in life. He was treated with psychotropic drugs risperidone (2 mg daily) and diazepam (2.5 mg daily) before the operation. His older brother had normal development, and his family history was noncontributory. He had no history of asphyxia at birth or major trauma. Previous chromosome tests were normal. A genetic test for metabolic disease genes suggested no significant abnormalities.

(See figure on next page.)

Fig. 1 **a** Continuous and periodic 1- to 2-Hz generalized spike-and-slow wave discharges were recorded during long-term video-EEG monitoring at the age of 3, in 2005. **b** Continuous 1- to 2-Hz slow spike-wave discharges mainly occurred in the bilateral prefrontal cortex at 4 years of age (2006) when the seizures were controlled. **c** The inter-ictal generalized spike/spikes-and-slow wave discharges before VNS treatment were recorded at the age of 14 (2016). **d** A generalized tonic seizure was recorded when he was 12 years old (2014). The ictal EEG showed low-amplitude fast rhythmic activity and behavioral symptoms included ascending of bilateral shoulders and proximal upper limbs as well as head tilting forward, which lasted about 20 s. **e** A generalized tonic seizure in sleep was recorded at 14 years of age (2016). The ictal EEG showed generalized low-amplitude fast rhythmic activity which lasted about 12 s. **f** An atypical seizure was recorded. The ictal EEG showed generalized 2.5- to 3-Hz slow spike-wave activity which lasted about 12 s, with slight limb shaking and short of breath. **g** Onset of a generalized tonic-clonic seizure (black solid line) recorded at 14 years of age (2016), which showed 3–4-s generalized low-amplitude activities. **h** Inter-ictal spike discharges after VNS treatment recorded at 17 years of age (2019). The spike discharges were confined to the right frontal and anterior temporal lobes during 6-h EEG monitoring

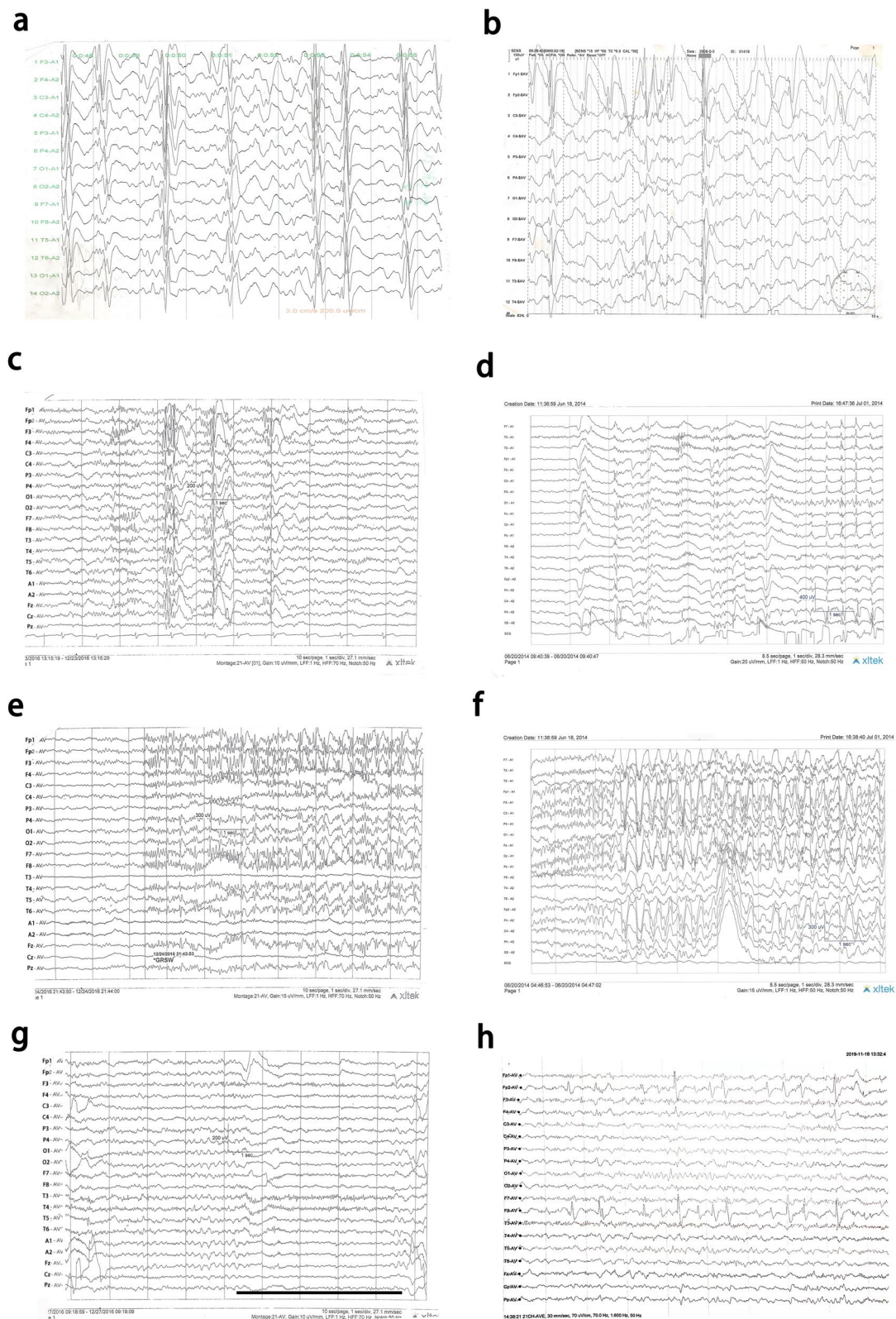


Fig. 1 (See legend on previous page.)

A vagus nerve stimulator (Electrode model L301; Generator model G102R; PINS, Beijing Pinchi Medical Equipment Co., Ltd, Beijing, China) was implanted in January 2017 at age of 15. The initial stimulation parameters were as follows: current output 0.5 mA, frequency 30 Hz, pulse width 500 μ s, signal-on time 30 s, and signal-off time 5 min. The frequency of generalized tonic-clonic seizures decreased from 2–4 times to zero per month, and the frequency of tonic seizures decreased from 4–5 times per day to 1–2 times per month. He became seizure-free when the stimulation current increased to 1.5 mA in 2018. There was no significant improvement of cognition after VNS. His psychiatric symptoms were mildly improved following VNS, including increased sleep time and reduced difficulty to fall asleep (PSQI score 11, average sleep quality), and mild decrease of psychiatric test scores (HAMD 12, HAMA 12, PNASS 95, CGI 5, SDSS 15). In the last telephone follow-up in 2021, his mother told us that he was taking the

same dosages and types of antiepileptic and psychotropic medications as before (LTG 150 mg and VPA 1000 mg daily, risperidone 2 mg and diazepam 2.5 mg daily). During the whole year of 2020, there were approximately five short tonic seizures (3–5 s), which manifested as ascending of bilateral shoulders and proximal upper limbs and staring induced by a sudden sound. Beyond our expectation, the 6-h EEG demonstrated a significant reduction in slow spike-wave discharges, and the abnormal discharges were confined to the right frontal and anterior temporal lobes (Fig. 1h). MRI was performed under sedation at age of 12 (2014), and no obvious lesion was found (Fig. 2). The patient's demographic information and clinical characteristics are presented in Table 1.

Discussion

The management and treatment of LGS is challenging. For medication treatment, VPA, LTG, and TPM are considered to be the first-line treatments for patients

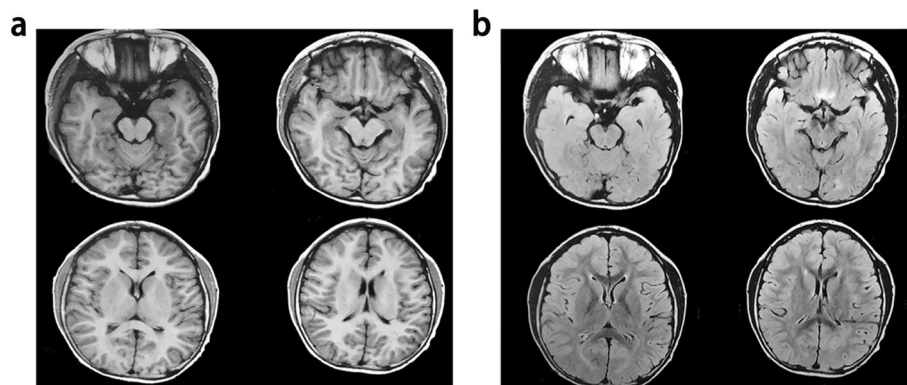


Fig. 2 MRI was performed only once at the age of 12, in 2014. T1-weighted images of 3-mm thickness (**a**) and Flair sequence images (**b**) are shown. There was a suspected focal cortical dysplasia in the right anterior temporal cortex according to the unclear boundary between gray and white matter, but this conclusion was not accepted by experts after multidisciplinary discussion

Table 1 The demographic information and clinical characteristics of the patient

| Age: 19 years | Gender: Male | Diagnosis: LGS | No history of asphyxia or trauma |
|-------------------------------------------------------------------------------------|--------------|----------------------------------------------------------------------------------------------------------------------------------------------|----------------------------------|
| Onset age of epilepsy: 3 years | | Date of VNS implantation: January 19, 2017 | |
| Anti-epilepsy medication: LTG 150 mg and VPA 1000 mg daily, before and after VNS | | Psychotropic medication: risperidone 2 mg and diazepam 2.5 mg daily, before and after VNS | |
| Epilepsy (pre-VNS) | | Epilepsy (post-VNS) | |
| • Seizure patterns and frequency | | Seizure patterns and frequency | |
| i. Generalized tonic-clonic seizures, 2–4 times per month | | i. No generalized tonic-clonic seizures observed | |
| ii. Short tonic seizures, 4–5 times per day | | ii. Short tonic seizures, 2–5 times per year | |
| • EEG manifestation: generalized spike/spike-and-slow wave discharges dominated | | • EEG manifestation: localized spikes in the right frontal-temporal lobe dominated | |
| • Psychiatric disorders (pre-VNS): | | • Psychiatric disorders (post-VNS): | |
| inable to fall asleep and a short sleep time (PSQI score of 16, poor sleep quality) | | increased sleep time and reduced difficulty to fall asleep (PSQI score 11, average sleep quality), HAMD 12, HAMA12, PNASS 95, CGI 5, SDSS 15 | |
| HAMD 14, HAMA 14, PNASS 95, CGI 6, SDSS 15 | | • Mental retardation | |
| • Mental retardation | | | |

with LGS [15, 16]. Nonpharmacological therapies, including ketogenic diet, surgical resection, VNS, and corpus callosotomy, should be considered. However, the seizures in LGS patients are usually drug-resistant, and it is difficult to achieve seizure freedom with resolution of intellectual and psychosocial dysfunctions [5].

LGS exhibits diverse etiologies, from genetic and/or metabolic to structural causes including destructive lesions and cortical malformations. One study reported seizure free outcomes after surgical resection in patients with LGS at a rate of up to 50% [13]. To have successful resective surgery, the epileptogenic region for resection should be localized before surgery, based on clinical history or using EEG, MRI or positron emission tomography, etc. [12]. A study reported that seven patients with LGS had satisfactory outcomes, four patients had Engel class I and one patient had Engel class II after cortical resection, because corpus callosotomy revealed the presumed seizure focus in the localized cortical area [13]. Corpus callosotomy is a palliative surgery for controlling generalized seizures, because it is hypothesized to be the most important pathway for epileptic activity spread between the two hemispheres [17, 18]. These studies indicated that corpus callosotomy could change EEG findings, which may be helpful in revealing the primary seizure focus for resection in patients with LGS.

In our study, we found that the abnormal discharges changed from generalized activity and slow-spike waves in the whole brain to localized activity in the right frontal lobe after VNS treatment. This finding may help delineate the primary seizure focus in patients with LGS. At age of 12 (2014), MRI showed suspected dysplasia of the right temporal cortex with an unclear boundary between the gray and white matter (Fig. 2), which may be consistent with the result of abnormal discharges after VNS treatment. Although the anti-epileptic mechanism of VNS is still unclear, many studies have suggested the relationship to EEG desynchronization [19, 20]. VNS increases activity in the locus coeruleus (LC) and raphe nuclei and modulates the downstream release of norepinephrine (NE) and serotonin, both of which have been shown to modify neuronal activities of the hippocampus and amygdala and change the plasticity of excitatory synapses in the brain [21, 22]. LC-NE is an important part of the ascending activation system, whose activation modulates the activity of the thalamic-cortical network, decreases the synchrony of epileptic discharge, and then decreases the frequency of seizures [23]. Recent studies indicated that the effectiveness of VNS is correlated with the VNS induced EEG desynchronization [24, 25]. Estimated changes of synchronization level are a promising biomarker for predicting responses to VNS [26, 27].

However, the change of epileptic discharges from being generalized to localized after VNS treatment in this study has not been reported before.

There were some limitations in this case report. First, the latest and clearest MRI was not collected due to the patient's severe psychiatric disorders. Second, the diagnosis of LGS in this case is open to discussion. On the one hand, it was difficult for the patient to cooperate during examination due to the severe cognitive and psychiatric disorders, so most of the information was collected from previous examination reports, and some of the results were incomplete. For instance, it was difficult to identify the specific seizure types without electromyography recordings. On the other hand, there is some evidence supporting an LGS diagnosis, including early onset (approximately 3 years of age), multiple seizure types (tonic, generalized tonic-clonic and atypical absence seizures), tonic seizures during the sleep stage, a cognitive disorder, and a slow spike-wave discharge pattern (2- to 2.5-Hz) of IEDs. Third, the EEG manifestation of LGS has been reported to change with age [28]. A few patients with LGS grow up to have more localized discharges [29]. The EEG changes in this case were considered to be a result of the long-term VNS, but a verification cannot be made because it was impossible to turn off the stimulation for a long time to verify whether the focal discharges were due to the patient's age or the VNS.

Conclusions

In this study, we found for the first time that the generalized epileptiform discharges evolve into localized discharges after VNS treatment, similar as the previously reported EEG development after corpus callosotomy in LGS patients. This result suggests that the EEG manifestation changes induced by VNS can help reveal the primary seizure focus in patients with LGS. Moreover, it can also advance our understanding of the anti-epileptic mechanisms of VNS and the evolution of LGS.

Abbreviations

CGI: Clinical Global Impression; EEG: Electroencephalography; HAMA: Hamilton Anxiety Scale; HAMD: Hamilton Depression Rating Scale; IEDs: Interictal epileptiform discharges; LC: Locus coeruleus; LGS: Lennox-Gastaut syndrome; LTG: Lamotrigine; MRI: Magnetic resonance imaging; NE: Norepinephrine; PNASS: Positive and Negative Syndrome; PSQI: Pittsburgh Sleep Quality Index; SDSS: Social Disability Screening Schedule; TPM: Topiramate; VNS: Vagus nerve stimulation; VPA: Valproic acid.

Acknowledgements

We thank Kunming Children's Hospital, the Huaqiao Affiliated Hospital of Jinan University, and the Psychiatry Department of the First Affiliated Hospital of Kunming Medical University for providing diagnosis and treatment together and data sharing. We greatly thank the patient's mother for recording the changes of symptoms.

Authors' contributions

Renli Qi and Wei Wang collected the data and wrote the first draft of the manuscript. Na Li and Zongling Shen provided psychiatric diagnosis and analysis. Yaoduan Xu and Xin Geng provided the clinical backgrounds of epilepsy and revised the manuscript. Jinghui Li, Na Li and Hualin Yu supervised and revised the writing of the manuscript. The author(s) read and approved the final manuscript.

Funding

This study was supported by the Natural Science Foundation of Yunnan Province (202105AC160029, KYRLMY20200026 and YNGXCXTD2018012) and the Major Science and Technology Special Project of Yunnan Province (202002AA100204).

Availability of data and materials

The raw data supporting the conclusion of this article are available from the corresponding authors, without undue reservation.

Declarations

Ethics approval and consent to participate

This report was approved by the Ethics Committee of the First Affiliated Hospital of Kunming Medical University (Register number: 2021L44) and in accordance with the Declaration of Helsinki. Informed consent for clinical was obtained from the parents prior to the study.

Consent for publication

Informed consent for the publication of this report was obtained from the patient's parents.

Competing interests

The authors declare that the research was conducted in the absence of any commercial or financial relationships that could be construed as a potential conflict of interest.

Author details

¹Second Department of Neurosurgery, First Affiliated Hospital of Kunming Medical University, Kunming 650032, China. ²Department of Neurosurgery, The Third People's Hospital of Honghe Prefecture, Gejiu 661000, China. ³Department of Psychiatry, First Affiliated Hospital of Kunming Medical University, Kunming 650032, China. ⁴Yunnan Provincial Clinical Research Center for Neurological Disease, Kunming 650032, China.

Received: 26 March 2022 Accepted: 7 July 2022

Published online: 07 December 2022

References

- Elliott RE, Rodgers SD, Bassani L, Morsi A, Geller EB, et al. Vagus nerve stimulation for children with treatment-resistant epilepsy: a consecutive series of 141 cases. *J Neurosurg Pediatr.* 2011;7(5):491–500.
- Shahwan A, Bailey C, Maxiner W, Harvey AS. Vagus nerve stimulation for refractory epilepsy in children: More to VNS than seizure frequency reduction. *Epilepsia.* 2010;50(5):1220–8.
- Toffa DH, Touma L, El Mesrine T, Bouthillier A, Nguyen DK. Learnings from 30 years of reported efficacy and safety of vagus nerve stimulation (VNS) for epilepsy treatment: A critical review. *Seizure.* 2020;83(Suppl 2):104–23.
- Wheless JW, Gienapp AJ, Ryvlin P. Vagus nerve stimulation (VNS) therapy update. *Epilepsy Behav.* 2018;88S:2–10.
- Asadi-Pooya AA. Lennox-Gastaut syndrome: a comprehensive review. *Neurol Sci.* 2017;39(8):1–12.
- Camfield PR. Definition and natural history of Lennox-Gastaut syndrome. *Epilepsia.* 2011;52(Suppl 5):3–9.
- Resnick T, Sheth RD. Early diagnosis and treatment of Lennox-Gastaut Syndrome. *J Child Neurol.* 2017;32(11):883073817714394.
- Helen CJ, Stéphane A, Mercè F, Pasquale S, Alexis A. Expert opinion on the management of Lennox-Gastaut Syndrome: treatment algorithms and practical considerations. *Front Neurol.* 2017;8:505.
- Frost M, Gates J, Helmers SL, Wheless JW, Levisohn P, Tardo C, et al. Vagus nerve stimulation in children with refractory seizures associated with Lennox-Gastaut syndrome. *Epilepsia.* 2001;42(9):1148–52.
- Marras CE, Colicchio G, De Palma L, De Benedictis A, Di Gennaro G, Cavaliere M, et al. Health technology assessment report on vagus nerve stimulation in drug-resistant epilepsy. *Int J Environ Res Public Health.* 2020;17(17):6150.
- Kang JW, Eom S, Hong W, Kwon HE, Park S, Ko A, et al. Long-term outcome of resective epilepsy surgery in patients with Lennox-Gastaut Syndrome. *Pediatrics.* 2018;142:e20180449.
- Douglass LM, Salpekar J. Surgical options for patients with Lennox-Gastaut syndrome. *Epilepsia.* 2014;4:21–8.
- Hur YJ, Kang HC, Kim DS, Choi SR, Kim HD, Lee JS. Uncovered primary seizure foci in Lennox-Gastaut syndrome after corpus callosotomy. *Brain Dev.* 2011;33(8):672–7.
- He L, Wen T, Yan S, Li R, Liu Z, Ren H, et al. Reevaluation of the effect of Dianxianning on seizure rate of refractory epilepsy as additive treatment in clinical practice. *Front Med.* 2011;5(2):229–34.
- Auvin S. Lennox-Gastaut syndrome: New treatments and treatments under investigation. *Rev Neurol (Paris).* 2020;176(6):444–7.
- Marson AG, Al-Kharusi AM, Alwaidh M, Appleton R, Baker GA, Chadwick DW, et al. The SANAD study of effectiveness of valproate, lamotrigine, or topiramate for generalised and unclassifiable epilepsy: an unblinded randomised controlled trial. *Lancet.* 2007;369(9566):1016–26.
- Cukiert A, Cukiert CM, Burattini JA, Lima AM, Forster CR, Baise C, et al. Long-term outcome after callosotomy or vagus nerve stimulation in consecutive prospective cohorts of children with Lennox-Gastaut or Lennox-like syndrome and non-specific MRI findings. *Seizure.* 2013;22(5):396–400.
- Vaddiparti A, Huang R, Blihar D, Du Plessis M, Montalbano MJ, Tubbs RS, et al. The evolution of corpus callosotomy for epilepsy management. *World Neurosurg.* 2021;145:455–61.
- Workewych AM, Arski ON, Mithani K, Ibrahim GM. Biomarkers of seizure response to vagus nerve stimulation: A scoping review. *Epilepsia.* 2020;61(10):2069–85.
- Yuan H, Silberstein SD. Vagus nerve and vagus nerve stimulation, a comprehensive review: Part II. Headache. 2016;56(2):259–66.
- Berger A, Vespa S, Dricot L, Dumoulin M, Iachim E, Doguet P, et al. How is the norepinephrine system involved in the antiepileptic effects of vagus nerve stimulation? *Front Neurosci.* 2021;15:790943.
- Krahl SE, Clark KB. Vagus nerve stimulation for epilepsy: A review of central mechanisms. *Surg Neurol Int.* 2012;3(Suppl 4):S255–9.
- Ben-Menachem E. Vagus-nerve stimulation for the treatment of epilepsy. *Lancet Neurol.* 2002;1(8):477–82.
- Sangare A, Marchi A, Pruvost-Robieux E, Soufflet C, Crepon B, Ramdani C, et al. The effectiveness of vagus nerve stimulation in drug-resistant epilepsy correlates with vagus nerve stimulation-induced electroencephalography desynchronization. *Brain Connect.* 2020;10(10):566–77.
- Vespa S, Heyse J, Stumpp L, Liberati G, Ferrao Santos S, Rooijakkers H, et al. Vagus nerve stimulation elicits sleep EEG desynchronization and network changes in responder patients in epilepsy. *Neurotherapeutics.* 2021;18(4):2623–38.
- Bodin C, Aubert S, Daquin G, Carron R, Scavarda D, McGonigal A, et al. Responders to vagus nerve stimulation (VNS) in refractory epilepsy have reduced interictal cortical synchronicity on scalp EEG. *Epilepsy Res.* 2015;113:98–103.
- Fraschini M, Puligheddu M, Demuru M, Polizzi L, Maleci A, Tamburini G, et al. VNS induced desynchronization in gamma bands correlates with positive clinical outcome in temporal lobe pharmacoresistant epilepsy. *Neurosci Lett.* 2013;536:14–8.
- Berg AT, Levy SR, Testa FM. Evolution and course of early life developmental encephalopathic epilepsies: Focus on Lennox-Gastaut syndrome. *Epilepsia.* 2018;59(11):2096–105.
- Yagi K. Evolution of Lennox-Gastaut syndrome: a long-term longitudinal study. *Epilepsia.* 2010;37(Suppl 3):48–51.