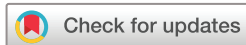

# How I treat MALT lymphoma: ‘a subjective interpretation of the gospel according to Isaacson....’



Markus Raderer, Barbara Kiesewetter 

**To cite:** Raderer M, Kiesewetter B. How I treat MALT lymphoma: ‘a subjective interpretation of the gospel according to Isaacson....’. *ESMO Open* 2020;5:e000812. doi:10.1136/esmoopen-2020-000812

Received 28 April 2020  
Revised 25 May 2020  
Accepted 26 May 2020

Published online  
28 July 2020

## ABSTRACT

Mucosa-associated lymphoid tissue lymphoma (MALT lymphoma) is an indolent B-cell lymphoma characterised by a fascinating interplay between chronic antigenic stimulation, an immune response insufficient for elimination of the antigen and a mucosal ‘battleground’. The archetype of this association is infection of the gastric mucosa with *Helicobacter pylori* (HP): a single course of antibiotic HP-eradication treatment may result in long-term remission in up to 80% of patients and is the gold standard for first-line therapy of HP-associated gastric MALT lymphoma. In extragastric or disseminated disease, treatment options range from wait and see in asymptomatic individuals to radiotherapy in localised stages, anti-CD20-antibodies in patients with low symptomatic burden and chemotherapy-based treatment or radio-immunotherapy in symptomatic disease. In addition, more refined immunomodulatory strategies beyond simple eradication of bacteria such as long-term use of the macrolide clarithromycin or the immunomodulatory drug lenalidomide are active. In view of the indolent clinical course, the least toxic individual treatment should be chosen in a disease usually not influencing overall survival in affected patients.

## INTRODUCTION

Mucosa-associated lymphoid tissue lymphoma (MALT lymphoma) accounts for 8% of B-cell lymphomas according to the recent WHO classification.<sup>1</sup> Initially described as gastric lymphoma by British pathologists Peter Isaacson and Dennis Wright in 1984, the debate whether this disease was in fact a lymphoma rather than a more ‘sophisticated gastritis’ ended only in 1994 after a decade of heated discussion, when ‘extranodal marginal zone B-cell lymphoma of the MALT’ was finally included in the Revised European American Lymphoma Classification. The work of Peter Isaacson has thus both defined a distinct lymphoma entity, but in the following years laid the foundation for defining the underlying cause as well as developing individualised therapy for HP-associated gastric MALT lymphoma—a feat that is in fact unrivalled in modern oncology. While the stomach is still the most common localisation documented in up to 30%–50%

of cases, a shift towards more extragastric manifestations including ocular adnexa, lung, thyroid and parotid glands is apparent.<sup>2</sup> MALT lymphoma is a lymphoid B-cell malignancy highly depended on microenvironmental factors, exemplified by the association of gastric MALT lymphoma with HP. Autoimmune disorders (AD), for example, Sjogren’s syndrome and chronic autoimmune thyroiditis Hashimoto are also associated with the development of MALT lymphoma. According to current concepts, both HP-gastritis and AD trigger lymphomagenesis via a multistep process of perpetual (auto-)antigenic stimulation of marginal zone B-cells and activation of the NF-Kappa B pathway.

## THE PARADIGM OF ANTIBIOTIC TREATMENT FOR MALT LYMPHOMA

### Shoot on sight—HP-eradication

HP-associated gastritis was initially defined as the leading cause of gastric MALT lymphoma demonstrated in up to 90%–95%.<sup>2–3</sup> The bacteria, however, are not always histologically detectable and diagnostics may be completed with stool antigen or breath test and eventually serology for HP-specific IgG. According to current guidelines, a single course of antibiotics is the standard for upfront treatment of HP-positive gastric MALT lymphomas resulting in long-term remissions in 70%–80% of patients, and complete remissions (CR) in up to 60%.<sup>3–4</sup> HP-eradication is currently our treatment of choice irrespective of the stage of gastric lymphoma.<sup>2–4</sup> Choice of antibiotics should be matched to local resistance patterns, but usually includes at least two antibiotics for 7–14 days in combination with a proton pump inhibitor. In spite of emerging rates of resistance to clarithromycin, the macrolide (plus either amoxicillin or metronidazole) is still an option due to additional immunomodulatory and antilymphoma effects. Response to eradication is assessed by re-endoscopy 3–6 months after treatment and should always include gastric mapping

© Author (s) (or their employer(s)) 2020. Re-use permitted under CC BY-NC. No commercial re-use. Published by BMJ on behalf of the European Society for Medical Oncology.

Department of Medicine I,  
Division of Oncology, Medical  
University of Vienna, Wien,  
Austria

### Correspondence to

Markus Raderer;  
markus.raderer@meduniwien.  
ac.at

biopsies and assessment of specimens by an experienced hematopathologist according the GELA response criteria. However, as MALT lymphoma is a malignancy in slow-motion, time to best response may vary between weeks up to 2 years. This is underlined by a series of 108 stage IE patients with residual MALT lymphoma at 12 months after eradication, of whom 32% further improved to CR without further therapy.<sup>5</sup> In line with current guidelines, we recommend no further treatment in patients with successful *HP*-eradication and residual disease in the absence of progression.

A point controversially discussed is the value of eradication in gastric MALT lymphoma with *HP*-negativity or disseminated disease. Response to *HP*-eradication has been reported in series also from our institution in patients with *HP*-negative or disseminated gastric MALT lymphoma including stage IV patients with bone marrow infiltration.<sup>2</sup> While the exact reason remains somewhat elusive, it might again be related to direct immunomodulatory effects of macrolides, and current data and guidelines suggest *HP*-eradication as safe for these cohorts in absence of a high symptomatic burden.<sup>3,4</sup>

### Antibacterial eradication for extragastric MALT lymphoma

In ocular adnexal MALT lymphoma (OAML), *Chlamydia psittaci* (CP) has been suggested as a potential trigger,<sup>6</sup> and a phase II trial showed efficacy of doxycycline 200 mg for 3 weeks in 27 patients. Patients tested positive for CP-DNA had better results than negative patients (64% vs 38%,  $p=0.25$ ). Strong geographic differences in CP-prevalence of OAML patients have been reported since, and in fact in our own collective of 60 patients none tested CP-positive. In addition, further series reported no response to doxycycline irrespective of CP-status, therefore we do not apply doxycycline for CP-eradication in OAML. Further pathogens associated with MALT lymphoma include *Borrelia burgdorferi* for MALT lymphoma of the skin, *Achromobacter xylosoxidans* for pulmonary MALT lymphoma and *HP* for various extragastric sites, but no consistent data on efficacy of eradication are available and eradication cannot generally be recommended.

## SYSTEMIC TREATMENT OF MALT LYMPHOMA

### Chemotherapy-based therapy

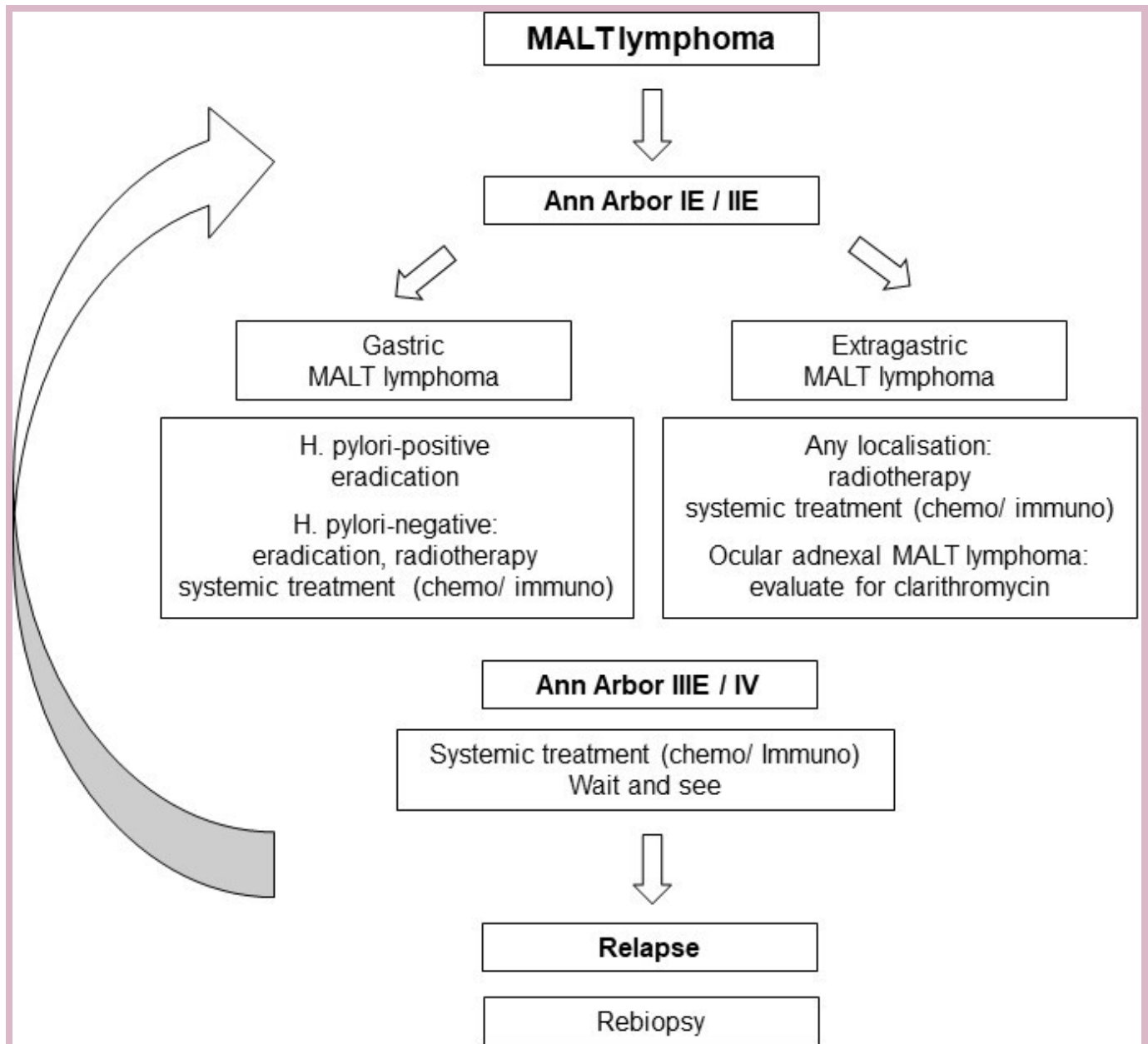
Chemotherapy-based treatment evaluated for MALT lymphoma include various types of combination regimens adapted from other indolent B-cell lymphomas, including chlorambucil±rituximab (R) and R-bendamustine with both regimens resulting in overall response rates (ORR) >90%.<sup>7,8</sup> Chlorambucil was evaluated with great efforts in the largest randomised trial for MALT lymphoma, the IELSG-19 study, based on a three-arm protocol comparing chlorambucil (6 weeks continuously followed by 16 weeks intermittent intake)±R versus R-monotherapy.<sup>7</sup> Final long-term results after a median follow-up of >7 years reported a significantly better 5-year

EFS for R-chlorambucil versus chlorambucil (68% vs 51%; HR: 0.54, 95% CI: 0.38 to 0.77) and also initial ORR was higher for the combination arm (95% vs 86%). No favour in terms of overall survival (OS), however, was seen. Based on these data, R-chlorambucil is regarded as standard therapy as it has been tested in a randomised study—even though the ORR in the phase II setting are lower than for other agents, suggesting that it might not have been the optimal choice as test arm over two relatively ineffective monosubstances. In addition, long-term administration of chlorambucil is highly dependent on patient-compliance. R-bendamustine is a regimen commonly used in indolent lymphoma, with activity and safety proven in large randomised phase III trials for mixed collectives of lymphoma entities. For MALT lymphoma, a Spanish phase II trial reported an ORR of 100% in 60 patients, with comparable long-term results to the IELSG-study (EFS 87.7% at 7 years, 95% CI: 76 to 94), with a step-down protocol allowing a treatment stop after cycle 4 in case of CR and only patients with response but residual disease continued for a total of six cycles.<sup>8</sup> In addition, the onset of responses is relatively quick, which in addition to the shorter overall duration makes R-Benda our current therapy of choice for patients requiring therapy, that is, symptomatic disease. Anthracycline-based therapy should be reserved for patients with transformation to aggressive lymphoma. Finally, current data in MALT lymphoma are not supporting maintenance treatment following R-chemo.

### Targeting CD20

Several small phase II trials including patients with gastric and extragastric disease, as well as the control arm of the IELSG-19 trial provided sufficient evidence for use of single agent rituximab in routine practice.<sup>7,9</sup> Response rates range between 60%–80% and whereas long-term outcome appears slightly inferior in terms of relapse rates (but not OS) compared with chemotherapy, we consider R-monotherapy feasible and particularly suitable for frail patients or patients with symptomatic disease but low tumour burden. A four-time-weekly schedule of 375 mg/m<sup>2</sup> is commonly being used in our practice with the potential for retreatment in case of relapse, while in the IELSG-19 trial, a prolonged treatment of 6 months was applied.<sup>7</sup>

In addition to R, also ‘next generation’ anti-CD20 antibodies have been used for treatment of MALT lymphoma. In small series, both ofatumumab and obinutuzumab have been applied in patients with marginal zone lymphoma, and have shown low toxicity along with clinically meaningful responses.<sup>10,11</sup> No trial in MALT lymphoma patients only has been published for obinutuzumab, but its use and efficacy have been shown in a wider population of patients with marginal zone lymphoma.<sup>10</sup> In the O-MAL trial, ofatumumab showed an ORR of 81% with a CR rate of 50% in 16 patients with MALT lymphoma.<sup>11</sup> Those next generation compounds might be of interest



**Figure 1** A potential treatment approach for MALT lymphoma. MALT, mucosa-associated lymphoid tissue.

for further studies to potentially overcome resistance to R-monotherapy and also for combination regimens.

An attractive but unfortunately rarely used treatment strategy is radio-immunotherapy with 90Y-ibritumumab-tiuxetan, which showed high response rates in various CD20+ malignancies including series of heavily pretreated patients with MALT lymphoma.<sup>12</sup>

### Immunomodulatory treatment for MALT lymphoma

In view of the dependency of MALT lymphoma cells on their microenvironment, immunomodulatory treatment appears reasonable and investigation of such concepts was an important focus at our centre in recent years. The immunomodulatory drug lenalidomide was investigated as monotherapy and in combination with R in *HP*-resistant or extragastric MALT lymphomas, and

especially the combination showed high activity with an ORR of 80% reported in 46 patients.<sup>13</sup> Positive long-term results including additional delayed remissions have been reported after 5 years follow-up. Unfortunately, in the AUGMENT trial that led to approval of R-lenalidomide for relapsed follicular lymphoma, the small and underpowered subgroup of marginal zone lymphoma was negative, thus no approval is expected in the near future.<sup>14</sup> Nevertheless, the recent ESMO guidelines on MALT lymphoma have included R-lenalidomide for relapsed and refractory MALT lymphoma in their algorithm.<sup>4</sup> Currently, there are no data to justify the use of lenalidomide and R in the first-line treatment of MALT lymphoma, although promising results for application in 110 untreated indolent lymphomas (including a cohort

of 30 patients with marginal zone lymphoma) have been published.<sup>15</sup> A long-term analysis of the marginal zone cohort only showed an ORR of 93% with 70% CR/Cru, and a median PFS of 59.8 months.<sup>16</sup> However, as with other studies of mixed marginal-zone lymphoma cohorts, only 11/30 patients had MALT lymphoma which does not allow for further distinct analysis. Toxicities of lenalidomide in MALT lymphoma (both as monotherapy as well as in combination) nevertheless appear mild, and constituted mostly rash and pruritus along with mild leukocytopenia and thrombocytopenia in the respective studies.

A further compound of interest in the context of immunomodulation is clarithromycin, which displays both antimicrobial effects and direct immunomodulatory and antiproliferative effects including inhibition of IL-6 and mTOR. Clarithromycin monotherapy was active in two phase II studies for relapsed or extragastric MALT lymphoma in the absence of active *HP/CP*-infection and showed response rates up to 50%, with the highest activity reported in OAML.<sup>17,18</sup> In addition, a recent retrospective analysis including 55 patients reported 2×500 mg daily for (3 to) 6 months as most feasible in terms of responses and side effects.<sup>19</sup> Based on the data reported so far and in view of the favourable toxicity profile, we use clarithromycin for antiproliferative treatment of MALT lymphoma patients with low tumour burden and particularly with OAML.

### Targeted therapies

Due to the role of the NF-κB pathway in the pathogenesis of MALT lymphoma, the proteasome inhibitor bortezomib was tested in two pilot studies at different dose levels (1.3 mg/m<sup>2</sup> and 1.5 mg/m<sup>2</sup>, respectively).<sup>9</sup> A high activity was shown in both studies, with the ORR being up to 80%, but the rate of neurotoxicity was nevertheless substantial. In view of the increasing role of novel agents targeting BTK and PI3K in various indolent lymphomas, their use in patients with MALT lymphoma might also be of interest. In fact, ibrutinib has been approved for therapy of relapsed/refractory marginal zone lymphoma due to the results of a phase II study, which also included 32 patients with MALT lymphoma.<sup>20</sup> In spite of the approval, both the median PFS of 13.8 months as well as the response rate of 50% appear slightly sobering, and are in fact (indirectly) comparable to application of clarithromycin, which—in our opinion—also has the advantage of a more favourable cost-profile and toxicity-profile.

### CONCLUSION

*HP*-eradication is the standard of care in patients with gastric MALT lymphoma irrespective of stage. For patients with symptomatic disease and need for systemic treatment, R-bendamustine and R-monotherapy are currently the most commonly applied therapies outside of clinical trials, while for the less symptomatic patients, clarithromycin is a good alternative. Localised disease can also be treated with low-dose radiotherapy (eg, 2×2 Gy), which

has excellent palliative outcome and can also be applied in patients with bilateral OAML.<sup>21</sup> See figure 1. Finally, the indolent clinical course of MALT lymphoma is highlighted by an overall survival >80% at 10 years.<sup>2</sup> In view of this, active surveillance constitutes an important option in the care of patients with MALT lymphoma.

**Contributors** Concept, writing and final approval of the manuscript: MR and BK.

**Funding** The authors have not declared a specific grant for this research from any funding agency in the public, commercial or not-for-profit sectors.

**Competing interests** MR declares honoraria for lectures from Novartis, Ipsen, Eisai and Celgene; BK declares honoraria for lectures from Novartis, Ipsen and Celgene.

**Patient consent for publication** Not required.

**Provenance and peer review** Commissioned; externally peer reviewed.

**Open access** This is an open access article distributed in accordance with the Creative Commons Attribution Non Commercial (CC BY-NC 4.0) license, which permits others to distribute, remix, adapt, build upon this work non-commercially, and license their derivative works on different terms, provided the original work is properly cited, any changes made are indicated, and the use is non-commercial. See: <http://creativecommons.org/licenses/by-nc/4.0/>.

### ORCID iD

Barbara Kiesewetter <http://orcid.org/0000-0002-5490-2371>

### REFERENCES

- 1 Cook JR, Chott A, Nakamura S, *et al*. Extranodal marginal zone lymphoma of mucosa-associated lymphoid tissue (MALT lymphoma). In: Swerdlow SH CE, Harris NL, Jaffe ES, *et al*, eds. *Who classification of tumours of haematopoietic and lymphoid tissues (revised 4th edition)* Lyon, France: IARC, 2017: 259–62.
- 2 Raderer M, Kiesewetter B, Ferreri AJM. Clinicopathologic characteristics and treatment of marginal zone lymphoma of mucosa-associated lymphoid tissue (MALT lymphoma). *CA: A Cancer Journal for Clinicians* 2016;66:152–71.
- 3 Ruskoné-Fontmestroux A, Fischbach W, Aleman BMP, *et al*. EGILS consensus report: gastric extranodal marginal zone B-cell lymphoma of malt. *Gut* 2011;60:747–58.
- 4 Zucca E, Arcaini L, Buske C, *et al*. Marginal zone lymphomas: ESMO clinical practice guidelines for diagnosis, treatment and follow-up. *Ann Oncol* 2020;31:17–29.
- 5 Fischbach W, Goebeler ME, Ruskoné-Fontmestroux A, *et al*. Most patients with minimal histological residuals of gastric MALT lymphoma after successful eradication of *Helicobacter pylori* can be managed safely by a watch and wait strategy: experience from a large international series. *Gut* 2007;56:1685–7.
- 6 Kiesewetter B, Raderer M. Antibiotic therapy in nongastrointestinal malt lymphoma: a review of the literature. *Blood* 2013;122:1350–7.
- 7 Zucca E, Conconi A, Martinelli G, *et al*. Final results of the IELSG-19 randomized trial of mucosa-associated lymphoid tissue lymphoma: improved event-free and progression-free survival with rituximab plus chlorambucil versus either chlorambucil or rituximab monotherapy. *J Clin Oncol* 2017;35:1905–12.
- 8 Salar A, Domingo-Domenech E, Panizo C, *et al*. Long-Term results of a phase 2 study of rituximab and bendamustine for mucosa-associated lymphoid tissue lymphoma. *Blood* 2017;130:1772–4.
- 9 Kiesewetter B, Ferreri AJM, Raderer M. Chemoimmunotherapy for mucosa-associated lymphoid tissue-type lymphoma: a review of the literature. *Oncologist* 2015;20:915–25.
- 10 Grunenberg A, Kaiser LM, Woelfle S, *et al*. Phase II trial evaluating the efficacy and safety of the anti-CD20 monoclonal antibody obinutuzumab in patients with marginal zone lymphoma. *Future Oncol* 2020;16:817–25.
- 11 Kiesewetter B, Neuper O, Mayerhoefer ME, *et al*. A pilot phase II study of ofatumumab monotherapy for extranodal marginal zone B-cell lymphoma of the mucosa-associated lymphoid tissue (MALT) lymphoma. *Hematol Oncol* 2018;36:49–55.
- 12 Vanazzi A, Grana C, Crosta C, *et al*. Efficacy of <sup>90</sup>Yttrium-ibritumomab tiuxetan in relapsed/refractory extranodal marginal-zone lymphoma. *Hematol Oncol* 2014;32:10–15.

- 13 Kiesewetter B, Willenbacher E, Willenbacher W, *et al.* A phase 2 study of rituximab plus lenalidomide for mucosa-associated lymphoid tissue lymphoma. *Blood* 2017;129:383–5.
- 14 Leonard JP, Trneny M, Izutsu K, *et al.* Augment: a phase III study of lenalidomide plus rituximab versus placebo plus rituximab in relapsed or refractory indolent lymphoma. *J Clin Oncol* 2019;37:1188–99.
- 15 Fowler NH, Davis RE, Rawal S, *et al.* Safety and activity of lenalidomide and rituximab in untreated indolent lymphoma: an open-label, phase 2 trial. *Lancet Oncol* 2014;15:1311–8.
- 16 Becnel MR, Nastoupil LJ, Samaniego F, *et al.* Lenalidomide plus rituximab (R) in previously untreated marginal zone lymphoma: subgroup analysis and long-term follow-up of an open-label phase 2 trial. *Br J Haematol* 2019;185:874–82.
- 17 Govi S, Dognini GP, Licata G, *et al.* Six-Month oral clarithromycin regimen is safe and active in extranodal marginal zone B-cell lymphomas: final results of a single-centre phase II trial. *Br J Haematol* 2010;150:226–9.
- 18 Ferreri AJM, Sassone M, Kiesewetter B, *et al.* High-Dose clarithromycin is an active monotherapy for patients with relapsed/refractory extranodal marginal zone lymphoma of mucosa-associated lymphoid tissue (MALT): the HD-K phase II trial. *Ann Oncol* 2015;26:1760–5.
- 19 Ferreri AJM, Cecchetti C, Kiesewetter B, *et al.* Clarithromycin as a "repurposing drug" against MALT lymphoma. *Br J Haematol* 2018;182:913–5.
- 20 Noy A, de Vos S, Thieblemont C, *et al.* Targeting Bruton tyrosine kinase with ibrutinib in relapsed/refractory marginal zone lymphoma. *Blood* 2017;129:2224–32.
- 21 Pinnix CC, Dabaja BS, Milgrom SA, *et al.* Ultra-low-dose radiotherapy for definitive management of ocular adnexal B-cell lymphoma. *Head Neck* 2017;39:1095–100.