

TSH-secreting pituitary adenoma: benefits of pre-operative octreotide

I R Wallace¹, E Healy², R S Cooke³, P K Ellis⁴, R Harper⁵ and S J Hunter¹

¹Regional Centre for Endocrinology and Diabetes ²Department of Neuropathology ³Department of Neurosurgery

⁴Department of Radiology, Royal Victoria Hospital, Grosvenor Road, Belfast BT12 6BA, UK

⁵Department of Endocrinology and Diabetes, Ulster Hospital, Dundonald BT16 1RH, UK

Correspondence
should be addressed
to I R Wallace
Email
iwallace01@qub.ac.uk

Summary

TSH-secreting pituitary adenomas are rare and the optimal investigation and management is uncertain. We describe a case of a 43 year-old woman with a TSH-secreting pituitary adenoma, highlighting diagnostic testing and our use, pre-operatively of somatostatin analogue therapy, which induced biochemical euthyroidism and a reduction in tumour size.

Learning points:

- The differential diagnosis of the syndrome of inappropriate TSH secretion is non-thyroidal illness, medications, assay interference due to heterophilic antibodies, thyroid hormone resistance and TSH-secreting pituitary adenoma.
- TRH stimulation test and triiodothyronine suppression test assist in differentiating thyroid hormone resistance and TSH-secreting pituitary adenoma.
- Somatostatin analogue therapy can induce biochemical euthyroidism and reduce tumour size.

Background

Thyrotropin (TSH)-secreting pituitary adenomas are rare accounting for 0.5–1% of all pituitary adenomas with an estimated prevalence of 1 per million (1). We describe the effects of pre-operative octreotide in a single case.

Case presentation

A 43 year-old woman presented with a 3 month history of three stone weight loss, palpitations, anxiety, heat intolerance, sleep disturbance, tremor and increased energy. She had initially attributed her symptoms to stress, working in a full-time administrative role, she was a widow with three teenage daughters and also ran seven miles on alternate days. She denied headaches or visual disturbance. She was on no regular medications and was otherwise well. Her sister was receiving carbimazole as treatment for autoimmune primary hyperthyroidism. On examination she had no evidence of

dysthyroid eye disease and no goitre with visual fields intact to confrontation.

Investigation

Initial thyroid biochemistry revealed a free thyroxine (T₄) concentration 29.5 pmol/l (reference range 9.0–19.0 pmol/l), TSH concentration 3.672 mU/l (reference range 0.4–4.5 mU/l) and free triiodothyronine (T₃) concentration 6.5 nmol/l (reference range 0.9–2.5 nmol/l). This abnormality persisted when serum was reanalysed using an alternative assay. Assay interference was excluded by polyethylene glycol (PEG) precipitation.

Markers of peripheral thyroid hormone activity including sex hormone binding globulin 90 nmol/l (reference range 20–115 nmol/l), total cholesterol, angiotensin converting enzyme and ferritin concentrations were all within the normal reference ranges.

An ultrasound of thyroid demonstrated a hypervascular gland, with a peak systolic velocity of 13–17 cm/s. α -subunit concentration was 1.1 IU/l (reference range <1.0 IU/l), follicle-stimulating hormone 24.4 U/l, luteinizing hormone 7.8 U/l, oestradiol 128 pmol/l, prolactin 310 mU/l (reference range <400 mU/l), IGF1 19.6 mmol/l (reference range 12–35 mmol/l).

Dynamic testing elicited a blunted response to thyrotropin releasing hormone (TRH 400 μ g administered intravenously) (Table 1) and a failure to suppress TSH secretion in response to administration of T_3 (20 μ g orally four times daily for 8 days) (Table 2). α -subunit to TSH molar ratio was 4.2 μ g/mU, below the cut-off of 5.5 μ g/mU proposed for normogonadotrophic pre-menopausal females (2). There was no evidence of co-secretion of other pituitary hormones.

MRI of pituitary illustrated a pituitary macroadenoma (maximal diameter 21 mm) abutting the optic chiasm (Fig. 1A). A test regimen of octreotide 100 μ g three times daily for 3 days resulted in suppression of TSH secretion (Table 3).

Treatment

After multidisciplinary discussion this woman was commenced on octreotide for a period of 3 months with the aim of inducing clinical and biochemical euthyroidism prior to transsphenoidal resection of her pituitary macroadenoma. Octreotide therapy resulted in normalisation of thyroid biochemistry (free T_4 10.6 pmol/l, TSH 0.866 mU/l), a resolution of clinical symptoms and a reduction in tumour size demonstrated on MRI (Fig. 1B) (The mass had reduced in size from 21 to 11 mm and was no longer abutting the optic chiasm, with an estimated reduction in tumour volume of 35% based on calculation using volumetric software). Octreotide was discontinued following surgery.

Table 1 TRH test. Blunted response to administration of 400 μ g TRH intravenously. A normal response is an increase in TSH to >5 mU/l or >200% with the peak at 20 min. In patients with thyroid hormone resistance, there is always an increase in TSH, which is usually exaggerated (12).

Time (min) after administration of TRH	TSH (mU/l)
0	2.590
20	2.595
60	2.874

Table 2 T_3 suppression test. Failure to suppress TSH secretion in response to 20 μ g T_3 orally four times daily for 8 days. This is in keeping with autonomous TSH secretion. A normal response is a complete suppression of T_4 and TSH (12).

Time	Free T_4 (pmol/l)	TSH (mU/l)
0	25.1	2.5
8 days	16.4	2.1

Outcome and follow-up

Following surgery, the patient had a transient period of diabetes insipidus with an otherwise uneventful post-operative course. Histological appearances were characteristic of a TSH-secreting pituitary adenoma (Fig. 2). At 3 months post-surgery, she remained clinically and biochemically euthyroid (free T_4 12.1 pmol/l, TSH 0.930) with normal responses of other pituitary axes to dynamic testing. Repeat MRI demonstrated a residual pituitary mass of 6 mm in maximal diameter. A repeat T_3 suppression test showed persistent failure to completely suppress TSH secretion in response to T_3 (Table 4).

Discussion

The differential diagnosis of the syndrome of inappropriate TSH secretion is non-thyroidal illness, medications, assay interference due to heterophilic antibodies, thyroid hormone resistance and TSH-secreting pituitary adenoma. Repeating sample analysis using an alternative assay should elicit a different result in the case of assay interference. However, use of an alternative assay methodology

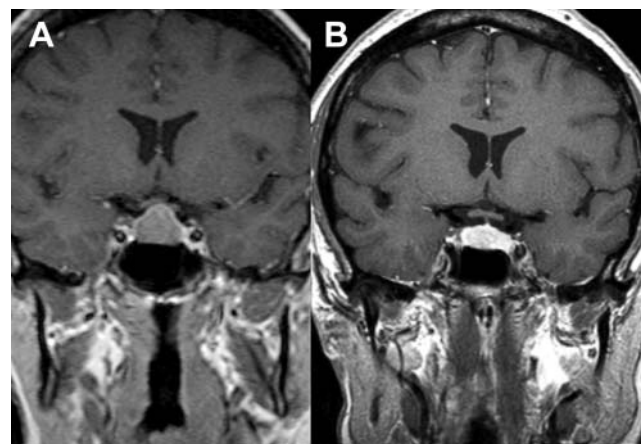


Figure 1 MRI coronal section illustrating a pituitary mass abutting the optic chiasm before octreotide therapy (A) and (B) after 3 months octreotide therapy illustrating a 35% reduction in volume of the pituitary mass.

Table 3 Results after 72 h trial of octreotide, showing a reduction in both T_4 and TSH concentrations.

Time	Free T_4 (pmol/l)	TSH (mU/l)
Prior to 1st dose	18.8	3.150
1 h post 1st dose	18.0	2.290
Day 4	13.0	0.033

such as PEG precipitation or equilibrium dialysis may be required to exclude assay interference. Patients are classically euthyroid in thyroid hormone resistance (with in some cases palpitations) and hyperthyroid in the case of TSH-secreting pituitary adenomas. Assessment of peripheral thyroid hormone activity (SHBG, angiotensin converting enzyme, cholesterol concentrations, and basal metabolic rate) can have utility in differentiating these states with increased activity seen in TSH-secreting pituitary adenoma and normal or decreased in thyroid hormone resistance. Dynamic testing is performed using the TRH test, which is classically blunted in TSH-secreting pituitary adenoma and the T_3 suppression test, where there is failure to completely suppress TSH secretion in the case of TSH-secreting pituitary adenomas. In contrast to thyroid hormone resistance where there is classically a normal or exaggerated response to TRH stimulation and complete TSH inhibition following T_3 administered as a suppression test (1).

Management of TSH-secreting pituitary adenomas is principally via surgical adenectomy. Postoperative external irradiation is a frequent adjunctive therapy (1). Somatostatin analogues are now the cornerstone of medical therapy. However their use has primarily been in palliative cases or in those without cure following surgery. Suppression of TSH secretion in >90%, a normalisation of free thyroid hormone concentrations in 70%

Table 4 Post-operative T_3 suppression test. Failure to suppress TSH secretion in response to T_3 20 μ g orally four times daily for 8 days. This is in keeping with a degree of residual autonomous TSH secretion (12).

Time	Free T_4 (pmol/l)	TSH (mU/l)
0	16.6	1.56
8 days	12.1	0.93

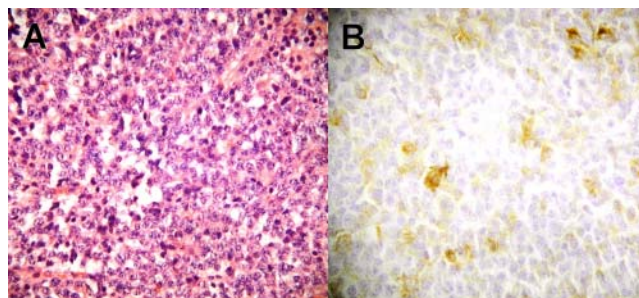
and a reduction in tumour size in ~50% of cases has been reported (3)(4). Pre-operative use has been infrequently described (5).

Somatostatin analogues exert their effects via interactions with somatostatin receptors (sstr). It is postulated that effects on TSH secretion are mediated via interactions with sstr2 and that tumour size reduction is effected via interactions with sstr5. Potentially only those tumours expressing sstr5 will reduce in size in response to a somatostatin analogue (6)(7).

The use of pre-operative somatostatin analogue has been described in the management of patients with acromegaly, with some centres using somatostatin analogue therapy as primary treatment, some for a period of three to 6 months pre-operatively and some only if there is no biochemical cure following surgery. A reduction of tumour size has also been described. Current guidance states that there is presently insufficient evidence to recommend pre-surgical somatostatin analogue use routinely for improved surgical outcome or post-operative complications in the management of acromegaly (8)(9)(10). In a recent Endocrine Society clinical practice guideline pre-operative use of somatostatin analogue is suggested in patients with severe pharyngeal thickness, sleep apnoea or high output cardiac failure to reduce surgical risk (11).

TSH-secreting pituitary adenoma is much more rare with less experience of the use of somatostatin analogue therapy. In a recent longitudinal Dutch study, of 18 patients followed for a median of 7 years, three were treated exclusively with somatostatin analogue and 72% required medical therapy (mostly after surgery) (12).

Whilst our case is symptomatically and biochemically euthyroid following surgery, failure to completely suppress TSH secretion in response to T_3 suggests that she is not completely cured (13). Should she relapse, therapy with a somatostatin analogue remains an option. In our case, octreotide was used with the aim of inducing euthyroidism pre-operatively. A reduction in tumour bulk (35% reduction in volume) was also obtained (Figs 1 and 2).

**Figure 2**
Histology of resected pituitary tissue. (A) Haematoxylin and eosin stain showing chromophobe adenoma tissue completely replacing normal pituitary tissue. (B) Immunohistochemical staining showing cells staining positive for TSH.

Our case highlights the differential diagnosis and investigative approach for the syndrome of inappropriate TSH secretion, and uncertainties in the management of a rare pituitary adenoma. Octreotide achieved the desired clinical and biochemical euthyroidism with the additional benefit of a reduction in tumour size. Correlation with other cases is required to assess if this effect is potentially beneficial to post-operative outcomes. We suggest, that in this rare tumour pre-operative octreotide may have a role.

Declaration of interest

The authors declare that there is no conflict of interest that could be perceived as prejudicing the impartiality of the research reported.

Funding

This research did not receive any specific grant from any funding agency in the public, commercial or not-for-profit sector.

Patient consent

Written informed consent has been obtained from the patient for publication of this anonymised case report.

Author contribution statement

All authors contributed to the clinical management of this patient. All authors contributed to the writing and editing of this case report.

References

- 1 Beck-Peccoz P, Brucker-Davis F, Persani L, Smallridge RC & Weintraub BD 1996 Thyrotropin-secreting pituitary tumors. *Endocrine Reviews* **17** 610–638. (doi:10.1210/edrv-17-6-610)
- 2 Beck-Peccoz P, Persani L & Faglia G 1992 Glycoprotein hormone α -subunit in pituitary adenomas. *Trends in Endocrinology and Metabolism* **3** 41–45. (doi:10.1016/1043-2760(92)90041-X)
- 3 Chanson P, Weintraub BD & Harris AG 1993 Octreotide therapy for thyroid-stimulating hormone-secreting pituitary adenomas: a follow-up of 52 patients. *Annals of Internal Medicine* **119** 236–240. (doi:10.7326/0003-4819-119-3-199308010-00010)
- 4 Beck-Peccoz P & Persani L 2002 Medical management of thyrotropin-secreting pituitary adenomas. *Pituitary* **5** 83–88. (doi:10.1023/A:1022360414062)
- 5 Iglesias P & Diez JJ 1998 Long-term preoperative management of thyrotropin-secreting pituitary adenoma with octreotide. *Journal of Endocrinological Investigation* **21** 775–778. (doi:10.1007/BF03348045)
- 6 Horiguchi K, Yamada M, Umezawa R, Satoh T, Hashimoto K, Tosaka M, Yamada S & Mori M 2007 Somatostatin receptor subtypes mRNA in TSH-secreting pituitary adenomas: a case showing a dramatic reduction in tumor size during short octreotide treatment. *Endocrine Journal* **54** 371–378. (doi:10.1507/endocrj.K06-177)
- 7 Yoshihara A, Isozaki O, Hizuka N, Nozoe Y, Harada C, Ono M, Kawamata T, Kubo O, Hori T & Takano K 2007 Expression of type 5 somatostatin receptor in TSH-secreting pituitary adenomas: a possible marker for predicting long-term response to octreotide therapy. *Endocrine Journal* **54** 133–138. (doi:10.1507/endocrj.K06-133)
- 8 Melmed S, Colao A, Barkan A, Molitch M, Grossman AB, Kleinberg D, Clemmons D, Chanson P, Laws E, Schlechte J *et al.* 2009 Guidelines for acromegaly management: an update. *Journal of Clinical Endocrinology and Metabolism* **94** 1509–1517. (doi:10.1210/jc.2008-2421)
- 9 Katznelson L, Atkinson JL, Cook DM, Ezzat SZ, Hamrahian AH & Miller KK 2011 American Association of Clinical Endocrinologists medical guidelines for clinical practice for the diagnosis and treatment of acromegaly – 2011 update. *Endocrine Practice* **17** S1–S44. (doi:10.4158/EP.17.S4.1)
- 10 Jacob JJ & Bevan JS 2014 Should all patients with acromegaly receive somatostatin analogue therapy before surgery and, if so, for how long? *Clinical Endocrinology* **81** 812–817. (doi:10.1111/cen.12553)
- 11 Katznelson L, Laws ET, Melmed S, Molitch ME, Murad MH, Utz A & Wass JAH 2014 Acromegaly: an Endocrine Society clinical practice guideline. *Journal of Clinical Endocrinology and Metabolism* **99** 3933–3951. (doi:10.1210/jc.2014-2700)
- 12 Van Varsseveld NC, Bisschop PH, Biermasz NR, Pereira AM, Fliers E & Drent ML 2014 A long-term follow-up study of eighteen patients with thyrotrophin-secreting pituitary adenomas. *Clinical Endocrinology* **80** 395–402. (doi:10.1111/cen.12290)
- 13 Brucker-Davis F, Oldfield EH, Skarulis MC, Doppman JL & Weintraub BD 1999 Thyrotropin-secreting pituitary tumors: diagnostic criteria, thyroid hormone sensitivity and treatment outcome in 25 patients followed at the National Institutes of Health. *Journal of Clinical Endocrinology and Metabolism* **84** 476–486. (doi:10.1210/jcem.84.2.5505)

Received in final form 11 May 2015

Accepted 21 May 2015