

Onset of Graves' disease during long-term immunosuppressive therapy in a patient with membranous nephropathy

Hiroaki Iwasaki

Division of Endocrinology and Metabolism, Department of Internal Medicine, Toshiba Rinkan Hospital, 7-9-1 Kami-tsushima, Minami-ku, Sagami-hara, Kanagawa 252-0385, Japan

Correspondence
should be addressed
to H Iwasaki

Email
iwasaki.har@gmail.com

Summary

A 67-year-old man was referred to our department for thyrotoxicosis with intermittent palpitation and 4-kg weight loss during the previous month. At the first visit, the patient was treated with cyclosporine A (CyA) for membranous nephropathy during the last 3 years and 8 months. Laboratory studies revealed that the serum TSH level was $<0.005 \mu\text{U/ml}$, and free thyroxine (fT_4) and triiodothyronine (fT_3) levels were elevated at 2.76 ng/dl and 5.96 pg/ml respectively. Anti-TSH receptor antibody (TRAb) level was increased at 26.4%. A clinical diagnosis of Graves' hyperthyroidism was given, and then thyrostatic treatment with thiamazole (MMI) at a dose of 10 mg daily was initiated after CyA withdrawal. After the initiation of MMI therapy, serum fT_4 and fT_3 attained the normal level within 1.5 months, with relief of symptoms followed by a remarkable decrease in urinary protein excretion from 2.0–5.2 g/day to ≤ 0.03 g/day. The patient maintained euthyroid with a low titre of TRAb for the succeeding 2 years and then MMI was finally stopped. Neither a relapse of hyperthyroidism nor a flare-up of nephrotic syndrome was observed for 3 years after MMI discontinuation. CyA has conflicting effects on immunologic self-tolerance by modulation of self-reactive T cells and natural $\text{CD4}^+\text{CD25}^+\text{Foxp3}^+$ regulatory T cell (Treg) functions, and possibly becomes a triggering factor in the development of autoimmune disorders. This case may be interesting when considering the effect of each T cell subset on the development of Graves' disease.

Learning points:

- The balance between intrathyroidal self-reactive T cell and natural $\text{CD4}^+\text{CD25}^+\text{Foxp3}^+$ Treg functions determine self-tolerance in the thyroid.
- CyA not only halts the expansion of self-reactive T cells but also impairs the function of Treg, which can provoke an unwanted immune response.
- A change in thyroid autoimmunity during treatment with CyA may result in the development of autoimmune thyroid diseases (AITD).
- Renal involvement in AITD frequently manifests as nephrotic syndrome, and thyrostatic treatment with thiamazole may be effective for excessive proteinuria.

Background

The adaptive immune system does not only consist of immune-stimulatory CD4^+ helper T cells (Th1, Th2 and Th17) and cytotoxic CD8^+ T cells (Tc) but is also regulated by suppressor T cells, including the naturally present

$\text{CD4}^+\text{CD25}^+\text{Foxp3}^+$ regulatory T cells (Treg) (1). Disruption of Treg function leads to wrongly identifying self molecules as non-self antigens and uncontrolled expansion of autoaggressive Th1, Th2, Th17 and Tc, ultimately



This work is licensed under a [Creative Commons Attribution-NonCommercial-NoDerivs 3.0 Unported License](http://creativecommons.org/licenses/by-nc-nd/3.0/).

© 2015 The author

<http://www.edmcasereports.com>
Published by Bioscientifica Ltd

resulting in self-intolerance subsequent to the development of autoimmune diseases (1).

Graves' disease is recognised as a disease that involves both Th2-mediated autoantibodies and Th1-stimulated Tc cytokines (2). The pathophysiological role of Treg in thyroid autoimmunity remains to be determined; however, intrathyroidal Treg in patients with Graves' hyperthyroidism is shown to be decreased by apoptosis or to be functionally defective, suggesting that its suppressor function may be insufficient to maintain adequate autoimmunity in the thyroid (2). Immune dysregulation, polyendocrinopathy and enteropathy X-linked (IPEX) syndrome due to mutations in the forkhead box protein P3 (*FOXP3*) gene cause Treg dysfunction and lead to severe multiple manifestations including autoimmune thyroid disease (AITD) (1).

Cyclosporine A (CyA) has been utilised for immunosuppression during organ transplantation and the treatment of autoimmune diseases, including membranous nephropathy (3) and Graves' ophthalmopathy (4). CyA acts on intracellular phosphatase calcineurin, and disturbs the activation of nuclear factor of activated T cells (NFAT). This agent attenuates self-reactive T cell activation through inhibition of the NFAT-AP1 complex, and impairs Treg function through inhibition of the NFAT-Foxp3 complex (1). Therefore, treatment with CyA possibly affects self-intolerance in the thyroid, and may even result in the development or worsening of AITD.

This case report describes the development of Graves' hyperthyroidism during long-term immunosuppressive therapy with CyA against nephrotic syndrome due to membranous nephropathy. A review of the literature revealed that the occurrence of Graves' disease during this immunological treatment appears to be quite rare. Although more experience and information will be needed to elucidate the mechanism(s) responsible for the development of Graves' hyperthyroidism, this case may emphasise the CyA-induced imbalance of different T cell subsets for the pathogenesis of AITD.

Case presentation

A 67-year-old man was referred for the evaluation of thyrotoxicosis that was ordered to assess the previous months' history of dyspnoea, palpitation, excessive sweating and 4-kg weight loss. The patient had a past history of bronchial asthma throughout his childhood, although oral or intravenous glucocorticoids were not administered according to the history provided by the patient. He also had hyperuricaemia with urolithiasis and

nephrolithiasis at the age of 27 years, for which he received continuous treatment with allopurinol. A diagnosis of type 2 diabetes mellitus with obesity (body weight=65 kg and BMI=25.2) was made at the age of 57 years; voglibose was administered at a clinic for 3 years until he voluntarily stopped treatment. Five years before his first visit to our department, the patient underwent a health check-up at a clinic and nephrotic-range proteinuria (spot protein ≥ 300 mg/dl) was noted; therefore, he was referred to the Department of Nephrology at our hospital, and a more extensive serological and biochemical analysis was performed, along with a renal biopsy. Laboratory examinations revealed hypoalbuminaemia with massive proteinuria and dyslipidaemia. Light microscopy of the initial renal biopsy specimen showed a slight increase in mesangial nuclei and matrix (Fig. 1, upper panels). Glomerular basement membranes (GBM) were mildly thickened in some lobules, indicating glomerular lesions specific to early membranous nephropathy (stage 1–2 as described by Enrenreich and Chung) (3). The measurements of autoantibodies against M-type phosphatase A₂ receptor and thrombospondin type-1 domain-containing 7A help differentiate idiopathic from secondary membranous nephropathy (5) (6). These autoantibodies were not measured in this case; however, evaluation of the aetiology for his membranous nephropathy by imaging and laboratory examinations possibly ruled out a secondary nephropathy due to neoplastic, infectious or autoimmune diseases. The following clinical course and follow-up studies supported the validity of the diagnosis of the idiopathic form.

The patient remained asymptomatic without peripheral oedema. The patient's blood pressure at each medical examination was found to be between 98/60 and 118/76 mmHg without antihypertensive drugs for more than 3 years after the diagnosis of nephropathy. His serum LDL and non-HDL cholesterol levels were elevated (247 and 295 mg/dl respectively (target values: <120 and <150 mg/dl respectively)); therefore, treatment using only atorvastatin calcium hydrate was initiated by the nephrologist. Although the glomerular filtration rate was essentially unchanged (creatinine clearance (Ccr): 111 ml/min, reference range: ≥ 60 ml/min), his excessive proteinuria was sustained at the level of 2.0–5.2 g/day (Fig. 2). Three years and 8 months before his first visit, the patient began immunosuppressive therapy by oral CyA (150 mg daily). Glucocorticoid was not simultaneously administered to avoid deterioration of his reasonable glycemic control (glycated hemoglobin (HbA_{1c}) levels: 5.8–6.2%, reference range: 4.6–6.2%) to reduce the risk of

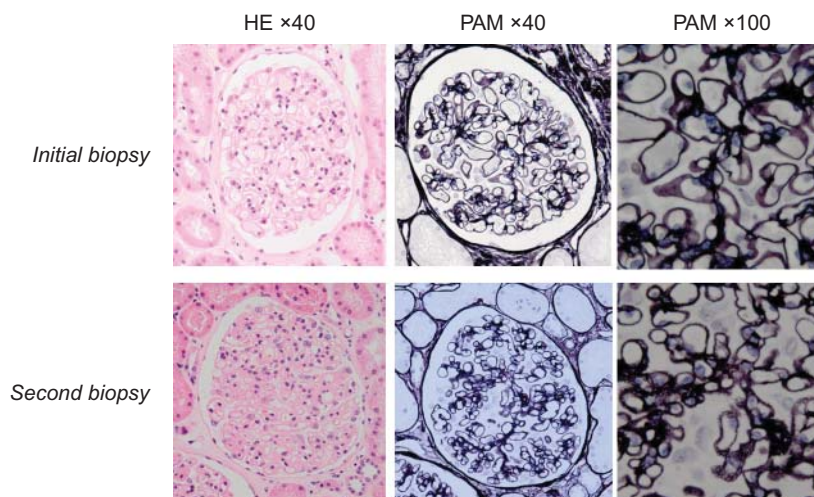


Figure 1

Glomerulus from the initial and second renal biopsy specimens. The initial specimens showed a slight increase in mesangial nuclei and matrix with mildly thickened basement membranes (upper panels), whereas the second specimens revealed a more pronounced increase in the mesangial nuclei and matrix and exhibited diffusely thickened basement membranes with

spikes protruding from their sub-epithelial spaces (lower panels) (left panels: hematoxylin–eosin (HE) stain, original magnification $\times 40$; middle and right panels: periodic acid methenamine silver (PAM) stain, original magnifications $\times 40$ and $\times 100$ respectively).

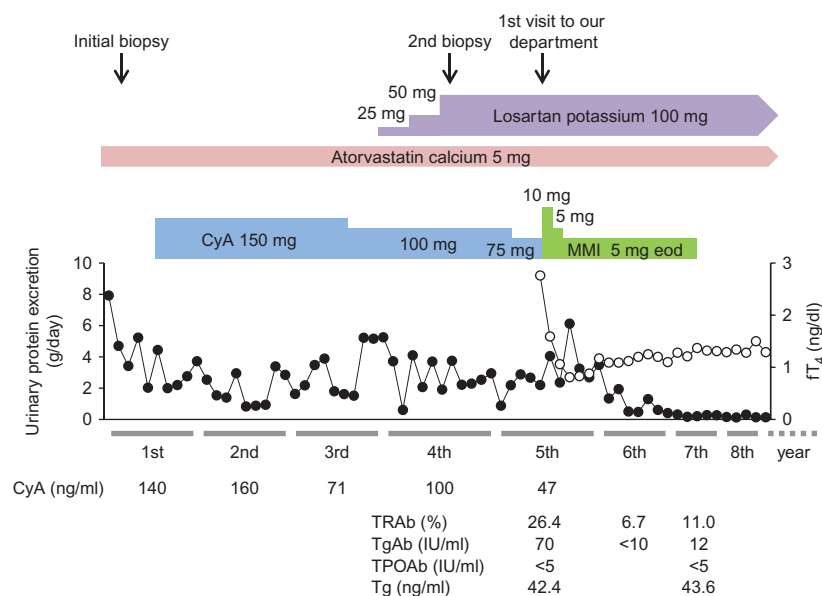
microvascular complications without treatment with any oral hypoglycemic agents or insulin. The patient's proteinuria resolved transiently by <1 g/day over the first year of treatment but then began to worsen again. One year and 6 months before his first visit, losartan potassium, an angiotensin receptor type 1 antagonist (ARB) was initiated for mild hypertension rising to 138/75 mmHg with CyA-resistant proteinuria, which failed to provide an optimal response to ameliorate his proteinuria. CyA was gradually tapered to 100 mg and then 75 mg daily, although the serum level was almost maintained at the therapeutic trough level (47–170 ng/dl, reference range: 80–140 ng/ml). A second renal biopsy was performed to exclude CyA-induced renal injury at 10 months before his first visit. The specimens revealed a more pronounced increase in mesangial nuclei and matrix (Fig. 1, lower panels). The GBM were diffusely thickened with spikes protruding from the sub-epithelial spaces, indicating that his membranous nephropathy had advanced to stage 2–3 (3).

The patient's father died because of pancreatic cancer, but there was no family history of diabetes mellitus, hypertension, dyslipidemia, ischemic heart disease, stroke, renal failure or autoimmune endocrinopathy, including AITD. There was no obvious evidence of thyrotoxicosis at the time of diagnosis for membranous nephropathy, although euthyroid or subclinical Graves' disease was not entirely excluded. Graves'

hyperthyroidism developed at 3 years and 8 months owing to the treatment with CyA, and the patient was subsequently referred to our department.

Investigation

His height was 160.7 cm and body weight was 51.3 kg (BMI: 19.9). Physical examination revealed blood pressure of 138/80 mmHg, a regular pulse rate of 96 beats/min, fine tremor and mild diffuse goitre without tenderness. There were no signs of Graves' orbitopathy such as upper lid retraction, stare and lid lag, i.e., von Graefe and Dalrymple signs, and all other findings were normal. Laboratory examination at the first visit to our department revealed that the serum levels of free triiodothyronine (fT₃), free thyroxine (fT₄) and thyroglobulin (Tg) were elevated to 5.96 pg/ml (reference range: 2.2–3.9 pg/ml), 2.76 ng/dl (reference range: 0.8–1.6 ng/dl) and 42.4 ng/ml (reference range: 0.0–33.7 ng/ml) respectively (Table 1). The serum thyroid-stimulating hormone (TSH) level dropped to <0.005 μ U/ml (reference range: 0.3–4.2 μ U/ml). The serum TSH receptor (TRAb), anti-thyroid peroxidase (TPOAb) and anti-Tg antibody (TgAb) levels were 26.4% (reference value: $<15.0\%$), <5 IU/ml (reference range: 0.0–16.0 IU/ml) and 70 IU/ml (reference range: 0.0–28.0 IU/ml) respectively. Thyroid ultrasonography revealed a slightly enlarged thyroid gland (thyroid volume, 15 cm³; right lobe dimensions, 5.3 \times 1.7 \times 1.5 cm, left lobe

**Figure 2**

Clinical course of the present patient with the sequential occurrence of membranous nephropathy and Graves' hyperthyroidism. The lines show levels of serum free thyroxine (fT₄, open circles) and urinary protein excretion (closed circles) before and after treatment with cyclosporine A (CyA) and thiamazole (MMI). Levels of serum CyA, anti-thyroid-stimulating

hormone receptor antibody (TRAb), anti-thyroglobulin (Tg) antibody (TgAb), anti-thyroid peroxidase antibody (TPOAb), and Tg are indicated under the graph. The reference ranges and values for each item are addressed in the text. eod, every other day.

dimensions, 5.3×1.7×1.6 cm) with several small cysts. Thyroid-stimulating antibody (TsAb), the fractional radioactive iodine uptake (RAIU) and ^{99m}Tc scan were not performed in this case; however, the obtained data were sufficient for the diagnosis of primary hyperthyroidism due to Graves' disease according to the current guidelines of the Japan Thyroid Association.

Graves' disease is a multifactorial disease in which genetic susceptibility and environmental factors are implicated (2). Strong independent associations between the human leukocyte antigen (HLA) class II region with Graves' disease were detected, and genetically predisposed individuals can possibly develop the Th2-dependent autoimmune process specific to Graves' disease (7). The HLA-DRB1*08:03 haplotype appears to be of major importance with respect to the genetic background in Japanese patients (7). The HLA-DRB1*04:10 and DRB1*14:54 alleles of the patient suggest that his HLA class II polymorphism was not committed to the development of Graves' hyperthyroidism (Table 1).

Autoimmune polyglandular syndrome (APS) is a unique manifestation of diseases characterized by the coexistence of at least two endocrine gland failures due to autoimmune disease in combination with or without those of non-endocrine organs (8) (9). A functional screening test

for the susceptible patients with autoimmune hypoparathyroidism was negative by serum calcium level (9.2 mg/dl; reference range: 8.8–10.1 mg/dl) and corrected calcium level for albumin (9.4 mg/dl; reference range: 8.8–10.1 mg/dl) under euthyroid, which also possibly ruled out primary hyperparathyroidism with urolithiasis and nephrolithiasis. Adrenal insufficiency was also excluded in the patient by a 0900 h plasma adrenocorticotropin (24.4 pg/ml; reference range: 7.4–55.7 pg/ml) and cortisol concentrations (16.1 µg/dl; reference range: 6.2–19.4 µg/dl) without corticotropin stimulation test (10). Anti-glutamic acid decarboxylase antibody level (<0.3 U/ml; negative: ≤1.4 U/ml) was negative for the diagnosis of type 1 diabetes mellitus. Considered together, the present case did not fulfill the diagnostic criteria for any of the APS subtypes.

Treatment

A clinical diagnosis of primary hyperthyroidism due to Graves' disease was established, and thyrostatic treatment with thiamazole (MMI; 10 mg daily) was initiated. CyA was discontinued after confirming its final concentration (47 ng/ml) (Fig. 2). For Graves' orbitopathy, the patient had no history for deterioration in vision and change in

Table 1 Laboratory findings at the first visit to our department.

Parameters	Values
Urine analysis	
pH	5.0
Protein	3+
Glucose	–
Ketone	–
Occult blood	1+
Sediments	
Red blood cells	5–9/HPF
Hyaline casts	5–9/HPF
24-h urinary protein	2.2 g/day
Complete blood count	
WBC	8800/mm ³
RBC	368×10 ⁴ /mm ³
Hb	10.8 g/dl
Ht	32.4%
Plt	22.8×10 ⁴ /mm ³
HLA serotype	DR4, DR14
DNA typing	DRB1*04:10, 14:54
Biochemistry	
TP	5.4 g/dl
Alb	3.4 g/dl
T.Bil	0.32 mg/dl
AST	17 IU/l
ALT	18 IU/l
γGTP	64 IU/l
LDH	159 IU/l
ALP	317 IU/l
BUN	23.9 mg/dl
Cr	1.19 mg/dl
UA	6.3 mg/dl
Na	144 mEq/l
K	4.9 mEq/l
Cl	111 mEq/l
Ca	9.8 mg/dl
TC	202 mg/dl
LDL-C	112 mg/dl
HDL-C	49 mg/dl
TG	113 mg/dl
Glu	92 mg/dl
Serological tests	
TSH	<0.005 μU/ml
Free T ₃	5.96 pg/ml
Free T ₄	2.76 ng/dl
Tg	42.4 ng/ml
TRAb	26.4%
TPOAb	<5 IU/ml
TgAb	70 IU/ml
GADAb	<0.3 U/ml
HBs-Ag	<0.01 IU/ml
HCV-Ab	<0.10 C.O.I
STS	–
TPHA	<0.10 C.O.I
Tumor markers	
CEA	2.0 ng/ml
CA19-9	5.6 U/ml
PSA	1.90 ng/ml
CyA	47 ng/ml
HbA _{1c}	5.7%

intensity or quality of color vision in one or both of his eye(s). Clinical activity score (CAS) of the patient was low (0/7) and the patient was placed under observation (4).

Outcome and follow-up

The symptoms were immediately cleared within 1.5 months after the initiation of MMI treatment, as shown by the normalized serum fT₃ and fT₄ levels (3.83 pg/ml and 1.59 ng/dl respectively) (Fig. 2). The dosage of MMI was tapered to 5 mg daily followed by 5 mg every other day. The titres of TRAb and TgAb were also normalized to 6.7% and <10 IU/ml at 1 year after the MMI treatment, respectively. The patient maintained euthyroid with a low titre of TRAb for the succeeding 2 years, and then MMI was finally stopped. Notably, his proteinuria gradually decreased and went into remission (≤32 mg/day) at 2 years after MMI therapy. He has neither undergone a relapse of hyperthyroidism nor a flare-up of nephrotic syndrome, and has taken no additional treatments 3 years after MMI discontinuation.

Discussion

Renal involvement usually manifesting as proteinuria is observed in 10–30% of patients with AITD (11). In majority of these cases in this specific setting, AITD appears to precede or to simultaneously occur with excessive proteinuria, and Tg planted in the glomerulus is shown to be a target antigen in some cases. The present case did not show any symptoms concerning thyrotoxicosis at the time of diagnosis for membranous nephropathy, suggesting that his nephrotic syndrome was unlikely to have occurred as a secondary nephropathy in the clinical course of Graves' disease. In favor of this notion, an immunohistochemistry study using the second biopsy specimens showed the absence of Tg in the glomeruli (H Iwasaki, M Wakasa & T Hatahara 2011, unpublished observation).

Urinary losses of T₄-binding globulins, prealbumins and albumins generally result in a reduction in serum total T₄ and sometimes T₃ levels (12). A majority of the patients with nephrotic syndrome maintains euthyroid with normal fT₄ and fT₃; however, overt hypothyroidism possibly develops in patients with low thyroid reserves, high proteinuria and low serum albumin levels. Urinary protein excretion of the patient was almost sustained at the level of 2.0–4.0 g/day and his serum albumin levels were relatively stable at the level of 3.2–3.8 g/dl for more than 1 year before the history of dyspnea, palpitation,

excessive sweating and 4-kg weight loss. Therefore, it is difficult to fully explain whether the hormonal changes due to nephrotic syndrome was mainly responsible for the development of Graves' hyperthyroidism.

Several previous reports have described the development of Graves' disease in patients after organ transplantation (13) (14) (15) (16) and a patient with Henoch-Schönlein nephritis during long-term CyA treatment (17). CyA preferentially inhibits the production of Th1-related cytokines such as interferon- γ and interleukin-2 (1). No clinical or biochemical findings of acute allograft rejections were observed in the above cases of organ transplantation (13) (14) (15) (16). Because the serum CyA levels of the patient are comparable to those of the previous cases (67–100 ng/ml), his Th1 response was likely to be sufficiently ameliorated during CyA treatment. It has been reported that a patient who developed Graves' disease despite adequate immunosuppression with CyA possessed a distinct subtype of TRAb that reacts with 90–165 residues of the TR, but not a common subtype related to 352–366 residues, and exhibited resistance to the thyrostatic treatment with MMI (16). The present case attained normal hormone levels within 1.5 months after MMI treatment, and had maintained euthyroid subsequent to remission without relapsing during the 3 years after its discontinuance. Discrepancy in the clinical courses between the two cases suggests that Th2-mediated production of the specific TRAb during CyA treatment may be unrelated to his Graves' hyperthyroidism. Moreover, the HLA alleles of the patient did not appear to be high-risk haplotypes for the enhancement of the Th2-dependent autoimmune process for Graves' disease (7). CyA is known to inhibit the formation of the NFAT-Foxp3 complex subsequent to the impairment of Treg function (1). IPEX syndrome with *FOXP3* mutations causes Treg dysfunction leading to AITD. Notably, membranous nephropathy is also a component of IPEX syndrome (11), which highlights the possible involvement of Treg dysfunction as the common pathological mechanism for both the worsening of his excessive proteinuria and the development of Graves' hyperthyroidism during CyA treatment.

In the present case, urinary protein excretion was remarkably decreased after MMI treatment, and his nephrosis did not flare-up during the euthyroid period. First, spontaneous remission of excessive proteinuria may be considered, because it is confined to 65% of patients with idiopathic membranous nephropathy, particularly the patients whose lesions stay in the early phase (stage 1 or 2) as shown in the present case (3). Second, his clinic blood pressure had lowered during MMI treatment;

therefore, the reduction in proteinuria may partially be associated with a change in hemodynamics, representing appropriate plasma renal flow and glomerular filtration. However, treatment with ARB failed to reduce his proteinuria before onset of Graves' hyperthyroidism; therefore, ameliorating blood pressure is insufficient to explain the remission of his nephrosis. Finally, MMI treatment is shown to increase circulating suppressor T cells and to decrease self-reactive T cells (18), and may directly modulate renal autoimmunity to ameliorate excessive proteinuria together with CyA withdrawal.

In conclusion, the sequential occurrence of Graves' hyperthyroidism in the patient with membranous nephropathy may have been caused by the immunosuppressive therapy with CyA. The previous cases that developed AITD during CyA treatment included glucocorticoids, which can independently modulate their thyroid autoimmunity and affect the development of Graves' disease through Th1- and Th2-mediated autoimmune processes (13) (14) (15) (16) (17). Therefore, the present case may convincingly lend credence to the relationship between CyA and the development of Graves' hyperthyroidism. Although the precise mechanism(s) remains to be determined, self-intolerance in the thyroid by CyA-mediated Treg dysfunction may be considered.

Declaration of interest

The author declares that there is no conflict of interest that could be perceived as prejudicing the impartiality of the research reported.

Funding

This research did not receive any specific grant from any funding agency in the public, commercial or not-for-profit sector.

Patient consent

Written informed consent was obtained from the patient for the publication of this case report.

Author contribution statement

H Iwasaki was the patient's physician, was responsible for case description and literature review, and wrote the manuscript.

Acknowledgements

The author thanks Mikio Wakasa, Kasumi Sato and Mitsuko Iwasaki (Department of Nephrology, Toshiba Rinkan Hospital) for their collaboration.

References

- 1 Sakaguchi S, Ono M, Setoguchi R, Yagi H, Hori S, Fehervari Z, Shimizu J, Takahashi T & Nomura T 2006 Foxp3⁺CD25⁺CD4⁺ natural regulatory T cells in dominant self-tolerance and autoimmune disease. *Immunological Reviews* **212** 8–27. (doi:10.1111/j.0105-2896.2006.00427.x)
- 2 McLachlan SM & Rapoport B 2014 Breaking tolerance to thyroid antigens: changing concepts in thyroid autoimmunity. *Endocrine Reviews* **35** 59–105. (doi:10.1210/er.2013-1055)
- 3 Ponticelli C 2007 Membranous nephropathy. *Journal of Nephrology* **20** 268–287.
- 4 Bartalena L, Baldeschi L, Dickinson A, Eckstein A, Kendall-Taylor P, Marcocci C, Mourits M, Perros P, Boboridis K, Boschi A *et al.* 2008 Consensus statement of the European Group on Graves' orbitopathy (EUGOGO) on management of GO. *European Journal of Endocrinology/European Federation of Endocrine Societies* **158** 273–285. (doi:10.1530/EJE-07-0666)
- 5 Beck LH, Bonogio RG, Lambeau G, Beck DM, Powell DW, Cummins TD, Klein JB & Salant DJ 2009 M-type phospholipase A2 receptor as target antigen in idiopathic membranous nephropathy. *New England Journal of Medicine* **361** 11–21. (doi:10.1056/NEJMoa0810457)
- 6 Tomas NM, Beck LH, Meyer-Schwesinger C, Seitz-Polski B, Ma H, Zahner G, Dolla G, Hoxha E, Helmchen U, Dabert-Gay A-S *et al.* 2014 Thrombospondin type-1 domain-containing 7A in idiopathic membranous nephropathy. *New England Journal of Medicine* **371** 2277–2287. (doi:10.1056/NEJMoa1409354)
- 7 Tomer Y & Davies TF 2003 Searching for the autoimmune thyroid disease susceptibility genes: from gene mapping to gene function. *Endocrine Reviews* **24** 694–717. (doi:10.1210/er.2002-0030)
- 8 Dittmar M & Kahaly GJ 2003 Polyglandular autoimmune syndromes: immunogenetics and long-term follow-up. *Journal of Clinical Endocrinology and Metabolism* **88** 2983–2992. (doi:10.1210/jc.2002-021845)
- 9 Kahaly GJ 2009 Polyglandular autoimmune syndromes. *European Journal of Endocrinology/European Federation of Endocrine Societies* **161** 11–20. (doi:10.1530/EJE-09-0044)
- 10 Charmandari E, Nicolaides NC & Chrousos GP 2014 Adrenal insufficiency. *Lancet* **383** 2152–2167. (doi:10.1016/S0140-6736(13)61684-0)
- 11 Ronco P & Debiec H 2009 Pathophysiological lessons from rare associations of immunological disorders. *Pediatric Nephrology* **24** 3–8. (doi:10.1007/s00467-008-1009-5)
- 12 Iglesias P & Díez JJ 2009 Thyroid dysfunction and kidney disease. *European Journal of Endocrinology/European Federation of Endocrine Societies* **160** 503–515. (doi:10.1530/EJE-08-0837)
- 13 Höfle G, Moncayo R, Baldissera I, Pfister R & Finkenstedt G 1995 Endocrine ophthalmopathy in a patient under continuous immunosuppressive therapy after cardiac transplantation. *Thyroid* **5** 477–480.
- 14 Khovidhunkit W, Greenspan FS & Jaume JC 2000 Development of overt autoimmune hyperthyroidism in a patient therapeutically immunosuppressed after liver transplantation. *Thyroid* **10** 829–832. (doi:10.1089/thy.2000.10.829)
- 15 Suher M, Koc E, Ensari C & Oztugut SU 2004 Graves' disease in a renal transplant. *Journal of Nephrology* **17** 736–738.
- 16 Wortsman J, McConnachie P, Tahara K & Kohn LD 1998 Thyrotropin receptor epitopes recognized by Graves' autoantibodies developing under immunosuppressive therapy. *Journal of Clinical Endocrinology and Metabolism* **83** 2302–2308.
- 17 Shin JI, Park JM, Lee JS, Kim DH & Jeong HJ 2005 Development of Graves' disease during cyclosporine treatment for severe Henoch–Schönlein nephritis. *Nephrology, Dialysis, Transplantation* **20** 2014–2015. (doi:10.1093/ndt/gfh959)
- 18 Cooper DS 2005 Antithyroid drugs. *New England Journal of Medicine* **352** 905–917. (doi:10.1056/NEJMra042972)

Received in final form 28 July 2015

Accepted 5 August 2015