



---

*Case Report*

## **Abdominal pregnancy—a diagnosis never to miss**

**Victor Okey Dinwoke, Michael Oluchukwu Amara\* and Linda Uzo Amara**

Enugu State University Teaching Hospital, Parklane, Enugu, Nigeria

\* **Correspondence:** Email: micoluchukwu4u911@yahoo.com.

**Abstract: Background:** Abdominal pregnancy is very rare, with only a few gynecologists being fortunate to encounter it all through their professional careers. It makes up only 1% of all ectopic pregnancies but has very high perinatal and maternal mortality of 95% and 18% respectively. Hemorrhagic and infectious complications account for these. Removal of the placenta at laparotomy is a big dilemma as torrential bleeding may ensue. **Case:** We report the case of an undergraduate teenager who was referred with features of septicemia and anemia following unsafe vaginal instrumentation by a patent medicine dealer (a person without formal training in pharmacy but sells orthodox medications on retail basis) in a bid to terminate an extrauterine pregnancy. Ultrasonography confirmed a nonviable abdominal pregnancy of 20 weeks. **Result:** She had exploratory laparotomy with the evacuation of the dead fetus and successful complete removal of the placenta. Her postoperative recovery was uneventful. **Conclusion:** In view of the grave complications like a pelvic abscess, disseminated intravascular coagulation and bowel obstruction that may accompany retention of the placenta in advanced abdominal pregnancy, optimal placental removal at surgery is recommended whenever feasible.

**Keywords:** pregnancy; abdominal; ectopic; case reports

---

### **1. Introduction**

Abdominal pregnancy, the implantation of pregnancy on the peritoneal surfaces exclusive of the fallopian tubes, the ovaries, and the broad ligaments, represents 1% of all ectopic pregnancies, while ectopic pregnancies, generally, are seen in 1% of all pregnancies. It occurs in about 1 in 10,000 to 1 in 30,000 pregnancies [1]. Most often, it results from a ruptured tubal ectopic pregnancy with

subsequent re-implantation of the embryo in the peritoneal cavity. The developing placenta invades pelvic and abdominal structures. Treatment is typically surgical. Attempts to remove the placenta from invaded abdominal and pelvic structures may provoke torrential and uncontrollable bleeding. This risk of massive bleeding lends credence to the practice of leaving the placenta in situ for subsequent resorption after surgery. Leaving the placenta in situ for subsequent resorption may also be problematic as the retained placenta may get infected, leading to a pelvic abscess and its sequelae [1,2].

Abdominal pregnancies are different from intrauterine pregnancies. In resource-poor settings where ultrasound evaluation is not widely available, women with abdominal pregnancies continue to suffer significant morbidity. In addition, restrictive abortion laws and consequently high rates of unsafe abortions contribute to a delay in gynecological evaluation with an increased risk of complications related to this condition. Unfortunately, there are no reliable non-radiological clinical criteria for early and accurate diagnosis of abdominal pregnancy. Signs and symptoms such as painful fetal movement and unusual fetal lie and presentation become apparent only when an abdominal pregnancy has become advanced. So, physicians must maintain a high index of suspicion of abdominal pregnancy, especially in the background of failed attempts at pregnancy termination.

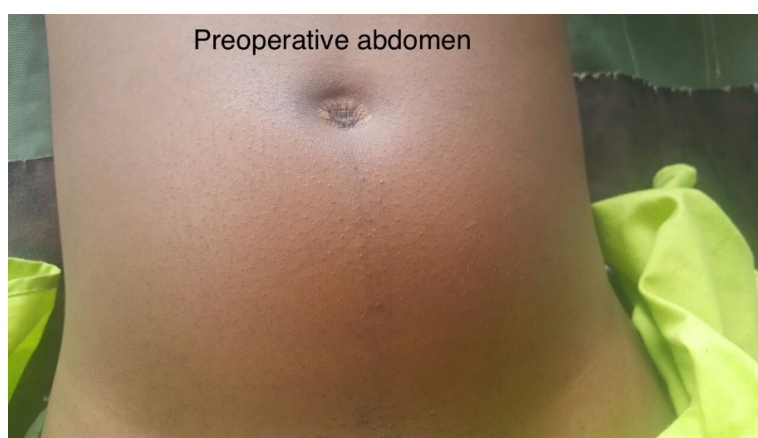## 2. Case report

Our case was a 19-year-old single nulliparous undergraduate with amenorrhea of 20 weeks duration. She was referred from a rural health facility due to severe abdominal pain, fever, and profuse vaginal bleeding following vaginal instrumentation by a patent medicine dealer. About four months earlier, following amenorrhea of six weeks and a positive pregnancy test, she took abortifacient medications (misoprostol tablets) with the intent to terminate her pregnancy. This action led to only minimal vaginal bleeding, and she took no further action until two weeks prior to presentation when she obtained a repeat urine pregnancy test that still turned out positive. She went to a patent medicine dealer who attempted to terminate the pregnancy using some metallic instruments inserted through her vagina. She subsequently developed fever, severe generalized abdominal pain, and profuse vaginal bleeding with associated offensive vaginal discharge. These symptoms led to her presentation in a rural private hospital where parenteral antibiotics, intravenous fluids, and a unit of blood were given before referring her to our center for expert management. Physical examination on arrival in our facility showed an ill-looking, febrile (39 °C) and markedly pale young lady with a pulse rate of 120 bpm, blood pressure of 90/60 mmHg, and respiratory rate of 28 cpm. Her abdomen was distended with marked generalized tenderness and guarding that limited adequate palpation (Figure 1).

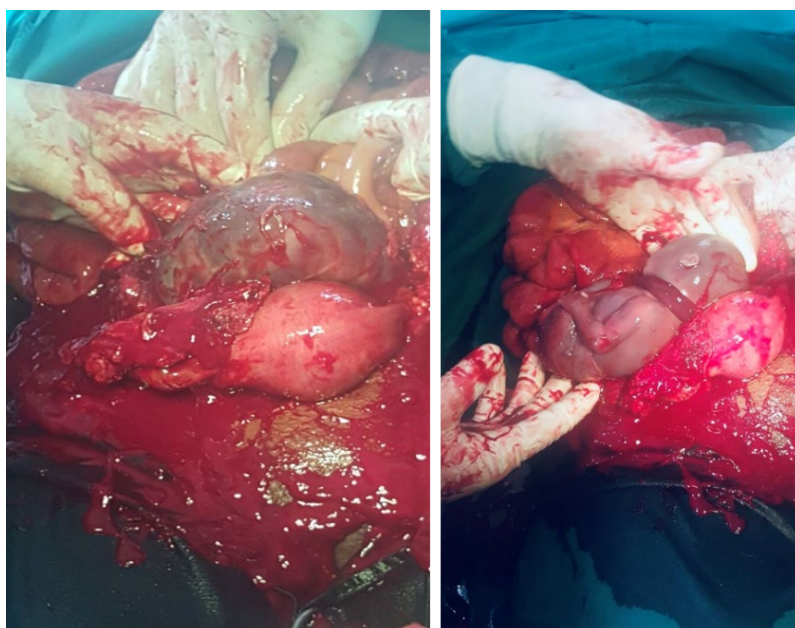
Vaginal examination revealed offensive blood-stained discharge with positive cervical excitation, uterine and adnexal tenderness, and a closed cervical os. Uterine size could not be properly delineated on bimanual palpation due to tenderness.

An abdominal ultrasound scan revealed a slightly enlarged uterus with an empty uterine cavity. A gestational sac containing a dead fetus was noted in the pouch of Douglas. The estimated gestational age was 20 weeks. Sonographic diagnosis of abdominal pregnancy was made. Blood and urine samples were taken for laboratory investigations. Her packed cell volume was 16%, WBC was 15,000 per microliter with neutrophilia, while her coagulation screen was normal. Resuscitative measures including transfusion of 3 units of blood, parenteral antibiotics, analgesics, and isotonic intravenous fluids were instituted. She became stable and had urgent exploratory laparotomy (under general anesthesia).

Intra-operative findings included a hemoperitoneum of over 1000 mL, an intact gestational sac in the pouch of Douglas containing a macerated male fetus with a loop of umbilical cord round the neck. There was no obvious fetal dysmorphic or structural malformation. The placenta was attached mainly to the posterior surface of the uterus, the right fallopian tube, the right broad ligament, and a few spots on the small intestine. The uterus was examined, and there was no evidence of uteroperitoneal fistula. The left fallopian tube was normal. The placenta was completely shelled off from the attached structures. The right fallopian tube and the right broad ligament invaded by the placenta were friable; and were excised. The friability of the right fallopian tube limited a distinct evaluation for the presence or absence of any tubo-peritoneal fistula. Hemostatic sutures were applied over the posterior wall of the uterus, and remnants of the right broad ligament were anchored over the posterior surface of the uterus to provide tamponade. Compression was sufficient to secure hemostasis over few bleeding spots on the bowel. An abdominal drain was placed. (Figure 2)



**Figure 1.** Preoperative abdomen.



**Figure 2.** Intra-operative findings showing uterus, gestational sac, and fetus.

Her postoperative recovery was uneventful. She was counseled on the intra-operative findings, the treatment offered, the reproductive implications, and contraception. She was discharged on the 9th postoperative day with follow-up appointments.

### 3. Discussion

Abdominal pregnancy is very rare, accounting for only 1.4% of all ectopic pregnancies. Unfortunately, it is associated with very high perinatal and maternal morbidity and mortality due mainly to prematurity, congenital malformations, premature placental separation, uncontrollable heavy bleeding associated with removal of the placenta, and infections associated with placental retention. The perinatal mortality can be up to 95% and the maternal mortality up to 18% [2,3].

Abdominal pregnancy can be primary or secondary. Most abdominal pregnancies are secondary, which implies a secondary re-implantation unto the peritoneal surfaces of an embryo following rupture of a tubal ectopic pregnancy [3–6]. Primary abdominal pregnancy must satisfy the three criteria defined by Studdertford: both tubes and ovaries must be in normal condition with no evidence of recent or remote injury, no evidence of uteroperitoneal fistula should be found, and finally, the pregnancy must be related exclusively to the peritoneal surfaces and must be early enough in the gestation to eliminate the possibility of secondary re-implantation following primary implantation in the tube [7]. Although no evidence of uteroperitoneal fistula was observed intra-operatively in this report, the fact that the pregnancy had advanced to 20 weeks and the presence of right tubal injuries occasioned by the invading placenta made this case likely a secondary abdominal pregnancy. Early pelvic ultrasound could not be obtained due to late presentation.

Abdominal pregnancy is often associated with premature spontaneous separation of the placenta from its implantation sites leading to hemoperitoneum [8], as was seen in the index case. Placenta management is critical in treating of advanced abdominal pregnancy because of the significant risk of torrential bleeding following placental removal. This risk is more so when advanced abdominal pregnancy is complicated by fetal demise and partial spontaneous placental separation, both of which can potentially lead to coagulopathy. Unlike intrauterine pregnancy, massive hemorrhage may follow the removal of the placenta in abdominal pregnancy at the time of surgery due to the absence of myometrial constriction of blood vessels. This risk of a massive hemorrhage supports the practice of leaving the placenta behind and untouched for spontaneous resorption after surgery, with or without methotrexate injections. Jack and James [9] reported a case in which the placenta was attached to the sigmoid colon while Rahaman and colleagues [10] reported an advanced abdominal pregnancy in which the placenta was attached to the anterior and lateral pelvic side walls. In both instances, the placentas were left in situ and untouched because of the vital and potentially hemorrhagic structures involved. Spontaneous resolution of the placenta can be very slow and may last over five years before complete resolution is achieved. Previously, methotrexate injections were advocated to accelerate the destruction of the placenta. However, if the destruction of the placenta proceeds rapidly, especially with too frequent injections or high doses, accumulation of large amount of necrotic placental tissues in the peritoneal cavity may occur, which provides an excellent medium for infections [10] in addition to the antimetabolite side effects of methotrexate. Therefore, leaving the placenta behind too, is a dilemma because the placenta could get infected, leading to a pelvic abscess and other infectious morbidities [2,11]. Other complications may include disseminated intravascular coagulation, fistula formation, and bowel obstruction. When the placenta is seated at a favorable site

such as the posterior surface of the uterus with minimal involvement of other vulnerable structures such as the guts, and if by the discretion of the surgeon, the risk for removing the placenta is less compared to its retention, placental removal should be considered [11–13]. We removed the placenta in this case because of its favorable attachment on the posterior uterine surface and the right broad ligament. Kunwar and colleagues [11] reported a similar case in which the placenta was attached to the posterior surface of the uterus and the right broad ligament. They removed the placenta at the time of the surgery, and controlled hemorrhage by combining ligatures and abdominal packing. Rahman et al. [13] reported a series of 10 cases of advanced abdominal pregnancy where some patients were conservatively managed with methotrexate injections to allow spontaneous resorption of the placenta. In contrast, others were actively treated by placental removal during surgery. They concluded that removal of the placenta, when feasible, produced the best results. The decision to leave or remove the placenta should be carefully thought out, and physicians should not be dogmatic about either choice. Placental location, maternal clinical condition, expertise, and the available facilities should guide how best to manage the placenta in all cases of advanced abdominal pregnancy. Other methods of controlling challenging hemorrhage as described by other reporters include selective embolization, coagulation promoting agents, and resection of the organs to which the placenta is adherent. In the case described by Rahaman, he combined resection of some structures onto which the placenta was attached with embolization of ovarian and uterine arteries to achieve hemostasis [10]. Expertise and resources for interventional radiology is not widely available especially in resource-constrained settings.

Besides hemorrhagic complications, other sources of morbidity in cases of advanced abdominal pregnancy include wrong diagnoses and wrong treatments in the hands of unsuspecting physicians and even quacks. Singh et al. [12] reported a near-miss case of abdominal pregnancy in a young primigravida who had repeated surgical induction of abortion and even unsuccessful complicated laparotomy carried out by an inexperienced clinician. The patient in our report developed septicemia and profuse vaginal bleeding with severe anaemia following unsafe surgical abortion conducted by a patent medicine dealer who did not suspect her pregnancy could be extrauterine. Similar scenarios may be relatively common in rural communities of developing countries with a dearth of radiological and other healthcare services.

#### **4. Conclusions**

Given the grave complications like a pelvic abscess, disseminated intravascular coagulation, and bowel obstruction that may accompany retention of the placenta in advanced abdominal pregnancy, optimal placental removal at surgery is recommended whenever feasible. Clinicians should maintain a high index of suspicion for abdominal pregnancy, especially in low-resource settings where sonographic evaluation may not be widely available. Our patient was a 19-year-old single nulliparous student referred from a private hospital in the hinterland with abdominal pregnancy, septicemia, profuse vaginal bleeding, and anemia following failed surgical abortion conducted by a chemist. She had successful exploratory laparotomy and complete placental removal with a good outcome. This report aims to add to the literature regarding the variety of clinical presentations and management of abdominal pregnancy.

## Conflict of interest

The authors declare no conflict of interest.

## References

1. Dahiya K, Sharma D (2007) Advanced abdominal pregnancy: a diagnostic and management dilemma. *J Gynecol Surg* 23: 69–72. <https://doi.org/10.1089/gyn.2007.B-02259-1>
2. Jurkovic D (2012) Ectopic pregnancy, In: Edmonds K. Editor, *Dewhurst's Textbook of Obstetrics and Gynaecology for Postgraduates*, 8th Edition, Wiley-Blackwell, 76–86. <https://doi.org/10.1002/9781119979449.ch9>
3. Delke I, Veridiano NP, Tancer ML (1982) Abdominal pregnancy: review of current management and addition of 10 cases. *Obstet Gynecol* 60: 200–204.
4. Mengistu Z, Getachew A, Adefris M (2015) Term abdominal pregnancy: a case report. *J Med Case Rep* 9: 168. <https://doi.org/10.1186/s13256-015-0635-3>
5. Huang K, Song L, Wang L, et al. (2014) Advanced abdominal pregnancy: an increasingly challenging clinical concern for obstetricians. *Int J Clin Exp Pathol* 7: 5461–5472.
6. Kwawukume EY, Ekele BA, Idrisa A (2015) Ectopic pregnancy, In: Kwawukume E.Y., Ekele B.A., Danso K.A., Emuveyan E.E. Editors, *Comprehensive Obstetrics in the Tropics*, 2nd Edition, 282–286.
7. Glob Libr Women's Med, Stubblefield P, Averbach S, Septic Abortion: Prevention and Management, 2014. Available from: <https://doi.org/10.3843/GLOWM.10438>.
8. Mahbuba M, Fatema K, Saha RK (2013) Advanced abdominal pregnancy with a full-term live fetus: case report. *Faridpur Med College J* 8: 40–43. <https://doi.org/10.3329/fmcj.v8i1.16898>
9. Hallatt JG, Grove JA (1985) Abdominal pregnancy: A study of twenty-one consecutive cases. *Am J Obstet Gynecol* 152: 444–449. [https://doi.org/10.1016/S0002-9378\(85\)80155-1](https://doi.org/10.1016/S0002-9378(85)80155-1)
10. Rahaman J, Berkowitz R, Mitty H, et al. (2004) Minimally invasive management of an advanced abdominal pregnancy. *Obstet Gynecol* 103: 1064–1068. <https://doi.org/10.1097/01.AOG.0000127946.14387.48>
11. Kunwar S, Khan T, Srivastava K (2015) Abdominal pregnancy: Methods of hemorrhage control. *Intractable Rare Dis Res* 4: 105–107. <https://doi.org/10.5582/irdr.2015.01006>
12. Singh A, Mishra V, Arum D, et al. (2014) Management dilemma in case of abdominal pregnancy: a case report. *Open J Obstet Gynaecol* 4: 899–902. <https://doi.org/10.4236/ojog.2014.414126>
13. Rahman MS, Al-Suleiman SA, Rahman J, et al. (1982) Advanced abdominal pregnancy—observations in 10 cases. *Obstet Gynecol* 59: 366–372.



AIMS Press

© 2022 the Author(s), licensee AIMS Press. This is an open access article distributed under the terms of the Creative Commons Attribution License (<http://creativecommons.org/licenses/by/4.0>)