

Prevention Of Oral Epithelial Dysplasia And Neoplasia Using Guabiroba Extract: A Study With Wistar Rats

¹Luis Noldin Junior, ¹Paulo César Amorim, ²Sandra Denise Camargo Mendes, ³Stefany Grützmänn Arcari, ^{*1}Sarah Freygang Mendes Pilati

¹Vale do Itajaí University (UNIVALI), Department of Odontology, Box. 88302-901, Itajaí, Brasil

²Agricultural Research and Rural Extension (Epagri), Experimental Station, Box.88502-970. Lages. Brazil

³Federal Institute of Santa Catarina, IFSC Campus São Miguel do Oeste, Box.89900-000. São Miguel do Oeste. Brazil

Correspondence Author: Sarah Freygang Mendes Pilati, Vale do Itajaí University (UNIVALI), Department of Odontology, Box. 88302-901, Itajaí, Brasil
Email: sarahpilati@univali.br

Received date: 12 April 2022, Accepted date: 24 September 2022

Citation: L.N. Junior, P.C. Amorim, S.D.C Mendes, S.G. Arcari, S.F.M Pilati., 2022. Prevention Of Oral Epithelial Dysplasia And Neoplasia Using Guabiroba Extract: A Study With Wistar Rats. Australian Journal of Basic and Applied Sciences, 16(10): 6-12. DOI: 10.22587/ajbas.2022.16.10.2.

ABSTRACT:

BACKGROUND: In recent years, studies focused on the total antioxidant activity present in native fruits in Brazil due to the compounds present with properties of reducing the level of oxidative stress and consequently reducing the risk of several cardiovascular, neurodegenerative and cancer. **Objective:** The aim of the study was to analyze the effects of guabiroba fruit extract on chemically induced carcinogenesis in rats. **METHODS:** Carcinogenesis was chemically induced by the compound 9,10-dimethyl-1,2-benzanthracene in oral mucosa applications in Wistar rats using only the carcinogen in the control group, the gel vehicle, application of pure extract and for the experimental group, applications of 9,10-dimethyl-1,2-benzanthracene and topical application of guabiroba pulp extract in 24 rats divided into 4 groups. After 60 days, the animals were euthanized to collect tissue samples. The tissue samples were analyzed in a microscope using Hematoxylin Eosin coloration with World Health Organization criteria. **RESULTS:** Cases of moderate and intense dysplasia were found in 66.7% of the animals in the control group and 33.3% in the experimental group. In pure extract group and gel vehicle group animals, there were no cases of moderate and intense epithelial dysplasia. Inflammatory infiltrate was found in 100 % of the slides of the control group; in 33.3 % of the experimental group only and in 16.7 % of the pure extract group and the gel vehicle group. The results showed that there was a difference between the control and experimental groups, i.e., in the control group, which was only in contact with the 9,10-dimethyl-1,2-benzanthracene, dysplasia occurred in whole animals. In comparison, in the experimental group, in addition to the carcinogen, the guabiroba extract was also applied, and there were half as many samples with dysplasia. **Conclusion:** 9,10-dimethyl-1,2-benzanthracene proved to be effective in promoting chemical carcinogenesis and should be used in rat animal models of oral cancer. The results found in this study showed that guabiroba fruit extract has the ability to reduce the formation of epithelial dysplasia, suggesting its preventive efficacy; in addition, it can reduce the presence of inflammatory infiltrate in oral mucosa.

Keywords: Antioxidants. Carcinogenesis. Inflammation. Squamous cell carcinoma

INTRODUCTION

Guabiroba (*Campomanesia xanthocarpa* O. Berg) is a native Brazilian species of the *Myrtaceae* family found in the Atlantic Forest. It has dark green foliage and white flowers that bloom from September to October and bears fruit from November to December (Carnevali et al., 2015; Morzelle et al., 2015). The fruits have a green to yellow color when ripe and shape of rounded berries (Da Silva Santos et al., 2009; Morzelle et al., 2015). The pulp and residues of this fruit have high levels of phenolic compounds, which eliminate free radicals and have a high antioxidant capacity. Thus, guabiroba's antioxidants can

prevent the formation of free radicals, leading to cell aging and causing diseases such as neoplasia (Barbieri et al., 2019; Da Silva Santos et al., 2009).

According to Manimaran and Manoharan (2018) and Maulina et al. (2019), food and chemoprevention can inhibit the development of oral cancer, so it is useful to study products from the Brazilian flora whose antioxidants can delay the appearance of potentially malign lesions or even reduce the injury, improving their clinical and histological aspects such that characterizes a form of prevention. It is known that DNA damage can come from several chemical sources and oxidation and antioxidant foods can act at this stage; therefore, the study about Guabiroba is directly related to its antioxidant properties that can prevent the formation of free radicals and their excess amounts (Pereira et al., 2009). Mallery et al. (2014) evaluated the chemopreventive efficacy of a natural product-based bioadhesive gel in Oral Intraepithelial Neoplasia (OIN) lesions. First, the harvested black raspberries were freeze-dried and ground to prepare the raspberry gel (BRB). Then, the placebo gel was prepared by exchanging the raspberry for sucrose and food coloring. Forty non-smoking adults with premalignant oral epithelial lesions and no previous history of cancer participated in the survey. Lesions treated with gel had a significant reduction in lesions compared to pretreatment. However, there was no such reduction in the placebo gel application. Thus, it can be assumed that other fruit extracts with antioxidants in their composition may contribute to reducing the decrease in carcinogenesis.

There is now an improved understanding of the molecular connections between oral cancer and inflammation and how they may be associated. Some of the inflammatory mediators, such as nuclear factor kappa B, inflammatory cytokines, vascular endothelial growth factors, prostaglandin pathways, p53, species that are reactive with oxygen and nitrogen, and microRNAs can be considered important factors in the pathogenesis of oral cancer (Patel et al., 2016). The accumulation of genetic changes leads to cellular alterations that, in the mouth, are manifested primarily as epithelial dysplasias that present a greater risk of progressing to oral squamous cell carcinoma. Epithelial dysplasia is a spectrum of architectural and cytological epithelial changes caused by an increased risk of progression to squamous cell carcinoma (El-Naggar et al., 2017). Malignant neoplasia is a disease that has a disease that has disordered growth of cells that invade tissues and cells and can spread to other areas of the body through metastases. The loss of mechanisms that regulate cell growth represents the development of tumors; therefore, it is related to several mutations (Wein and Weber, 2015). The present study aims to check the effects of guabiroba extract on chemically induced carcinogenesis in rats. 9,10-dimethyl-1,2-benzanthracene (DMBA) has carcinogenic potential and may be helpful in animal models. In addition, the topical guabiroba extract in the oral mucosa, due to its antioxidant components, has anti-inflammatory potential and can act at the cellular level, reducing the damage that can lead to carcinogenesis. These can be observed histologically through the presence. Therefore, we hypothesized that the effects of guabiroba extract could be due to its antioxidant and anti-inflammatory potential and can act at the cellular level, reducing the damage that can lead to carcinogenesis or not of inflammatory cells and WHO dysplasia criteria.

2. MATERIAL AND METHODS

2.1. Material

2.1.1 Preparation of guabiroba fruits for In Vivo Studies

Guabiroba fruits were collected from native plant populations in Santa Catarina state, Brazil. The pulp and bark of Guabiroba were subjected to enzymatic treatment with the application of pectolytic enzyme in the concentration of 5 mL per 100 L (Novozymes). Briefly, fruit pulp and bark were digested for 2 hours at 40°C (with manual shaking every 10 min) and filtered using a 150 µm mesh filter, resulting in guabiroba extract. The extract was lyophilized (LIOTOP, L101, São Carlos, Brazil) at -46°C, with pressure ranging from 15 to 30 µHg. The extract consisted of 390.45 mg of gallic acid equivalent, Vitamin C 650.71mg, 0.24 mg beta-carotene, pro-vitamin A 142.13 mg for 100g of the section and the antioxidant activity was 416.93 uM equivalent to Trolox/100g. After that, a 12% guabiroba extract gel was prepared according to Mallery et al. (2014). This experimental product (Guabiroba extract) used in research is not labeled and is not FDA (Federal Drug Administration) approved by any manufacturer.

2.1.2 Animal Handling

A total of 24 young adult female Wistar rats, average weight of 250 g, were used. They were randomly distributed into four groups: control group, placebo group, pure extract group, and 12 % extract gel group. Animals were housed in conventional cages and maintained on a 12-hour light-dark cycle. Water, food, and shavings were changed, and the cages were cleaned every two days. Six animals were housed in each cage, corresponding to the four groups mentioned above. The number of animals was based on the experimental study of Selvasundaram et al. (2018) and sample size calculation was performed to obtain an impact factor of 0.6. This research was approved by CEUA/UNIVALI/BRASIL number 032/18p1

2.1.3 Induction of contact

For the study of carcinogenesis and its relationship with antioxidant action, an effective mouth model was developed with the compound 9,10-dimethyl-1,2-benzanthracene (DMBA), behaving experimentally as an initiating agent of carcinogenesis. DMBA carcinogen was diluted in acetone at 0.5 %. All the applications were carried out only on the buccal mucosa on the right side of each animal, according to the four groups. In the control group (CG) (n = 6), 10 microliters of 0,5 % DMBA were applied

daily for 60 days using a micropipette (Eppendorf, SC, B.R.). In the pure extract group (PEG) ($n = 6$), applications of guabiroba extract only using cotton swabs were performed every day for 60 days. In the placebo group (GVG) ($n = 6$), only the vehicle was applied using cotton swabs every day for 60 days. In the 12 % extract gel group (E.G.) ($n = 6$), 10 microliters of 0.5 % DMBA were applied daily for 60 days using a micropipette. The pulp extract of Guabiroba 12 % was applied using cotton swabs every day for 60 days. In this group, they were not involved simultaneously when the two products had to be applied on the same day. Application time followed the method of [Mallery et al. \(2014\)](#). At the end of the 60 days, animals were euthanized using an over-anesthetic dose. After removing the buccal mucosa, the specimens were fixed in 10 % formalin, processed and included in paraffin. Finally, the sections were stained using the hematoxylin and eosin (H.E.) technique for further microscopic analysis.

2.1.4 Histopathology analysis

The microscopic evaluation of slides of the control group (CG), placebo group (GVG), pure extract group (PEG) and 12 % gel group (EG) was performed blindly by the researchers (LNNJ, PCA and SFMP). In this analysis, histopathological diagnosis and the presence of inflammation were evaluated. First, epithelia were evaluated and classified as “absent dysplasia”, “mild dysplasia”, “moderate dysplasia” and “severe dysplasia” according to the WHO classification system (El-Naggar et al., 2017). Afterward, inflammation was classified as “absent”, “mild” (presence of few inflammatory cells), “moderate” (average amount of inflammatory cells), and “intense” (a large number of inflammatory cells).

2.1.5 Statistical analysis

Data were tabulated using the Microsoft Excel 2016® spreadsheet software and statistical analysis using Fisher's exact test using the software Action Stat Version 3.6.331.450.

3. RESULTS

Cases of moderate and intense dysplasia were present in 66.7 % of the animals in the control group. This rate was higher than the one found in the experimental group (33.3 % of the animals), but it was not a significant result ($p = 0.567$). There were no cases of epithelial dysplasia in pure extract and placebo groups. The relative risk of the carcinogen developing damage was twice higher when there was no application of guabiroba extract after the application. Thus, inflammation was present in at least one animal in all groups, but at different intensities. In the control group, the inflammatory infiltrate was present in 100 % of the slides, while in the experimental group, only 33.3 % had an inflammatory infiltrate. The percentage was slightly lower in the placebo and pure extract groups, only 16.7 %.

Histological alterations were found in the study slides, mainly in the CG, where the stratified squamous epithelium presented hyperkeratosis, acanthosis, irregular epithelial stratification, drop-shaped epithelial projections, inversion of basal cell polarity, nuclear pleomorphism, nuclear hyperchromatism and hydropic degeneration, in addition to the presence of inflammatory infiltrate in the lamina propria (Figures 1 and 2). Conversely, the histological changes found in the EG were less significant (Figures 3 and 4).

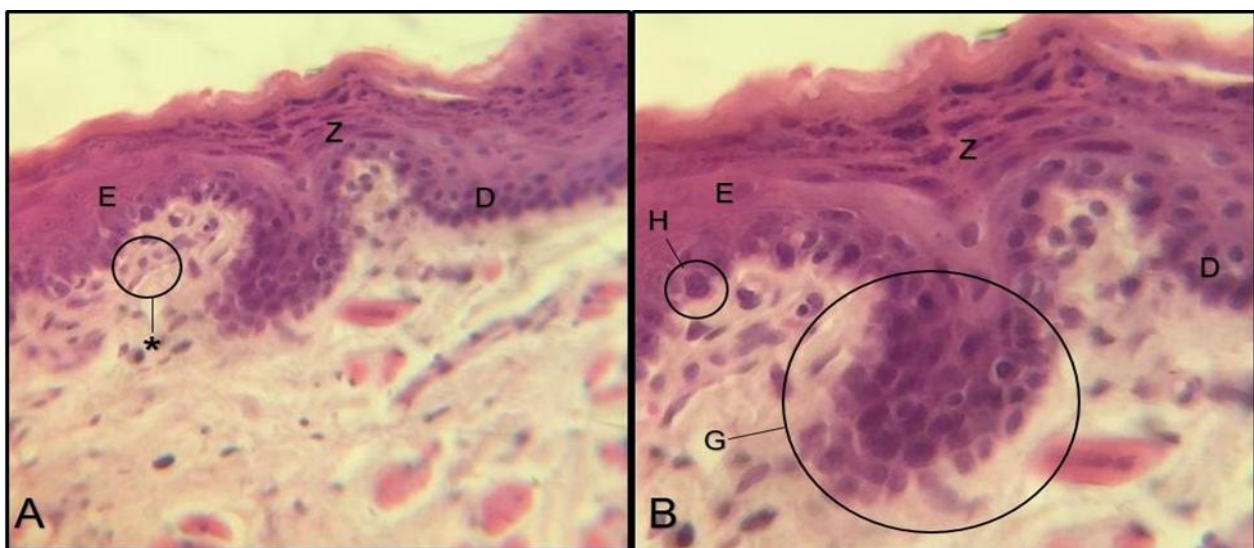


Fig. 1 – A - Mucosa section of the CG in 100X magnification stained with eosin and hematoxylin. Stratified squamous epithelium with hyperkeratosis (E) and acanthosis (Z) are observed. B - Mucosa section of the CG in 400X magnification stained with eosin and hematoxylin. Stratified squamous epithelium presenting hyperkeratosis (E), acanthosis (Z), drop-shaped epithelial projections (G), inversion of basal cell polarity (I), nuclear pleomorphism (P), irregular epithelial stratification (X) and addition the presence of inflammatory cells in lamina propria (*).

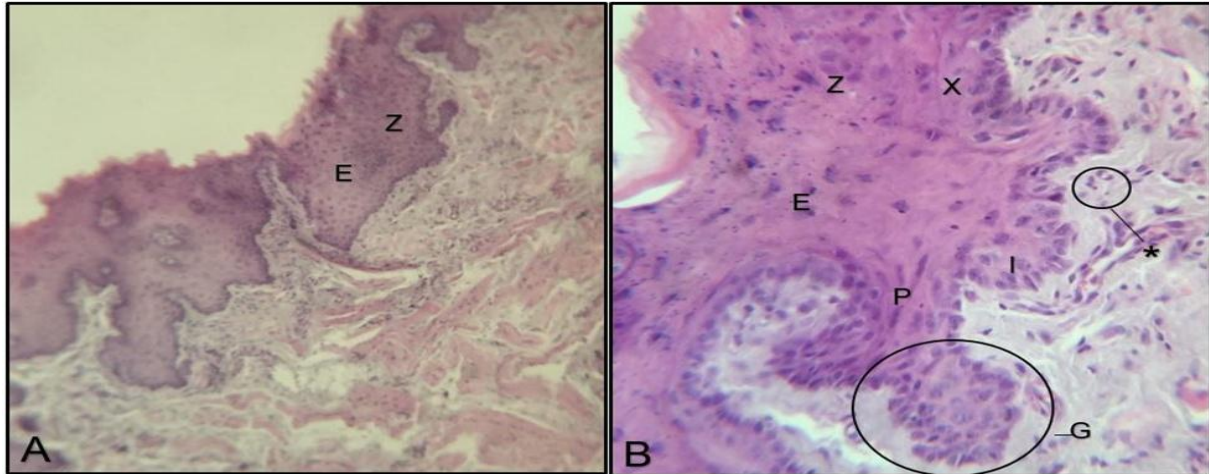


Fig. 2 – A - Mucosa section of the CG in 100X magnification stained with eosin and hematoxylin. Stratified squamous epithelium with hyperkeratosis (E) and acanthosis (Z), duplication of the basal layer (D), and in addition: the presence of inflammatory cells in the lamina propria (*). B - Mucosa section of the CG in 400X magnification stained with eosin and hematoxylin. Stratified squamous epithelium presented hyperkeratosis (E) observed, showing acanthosis (Z), drop-shaped epithelial projections (G), duplication of the basal layer (D) and nuclear hyperchromatism (H).

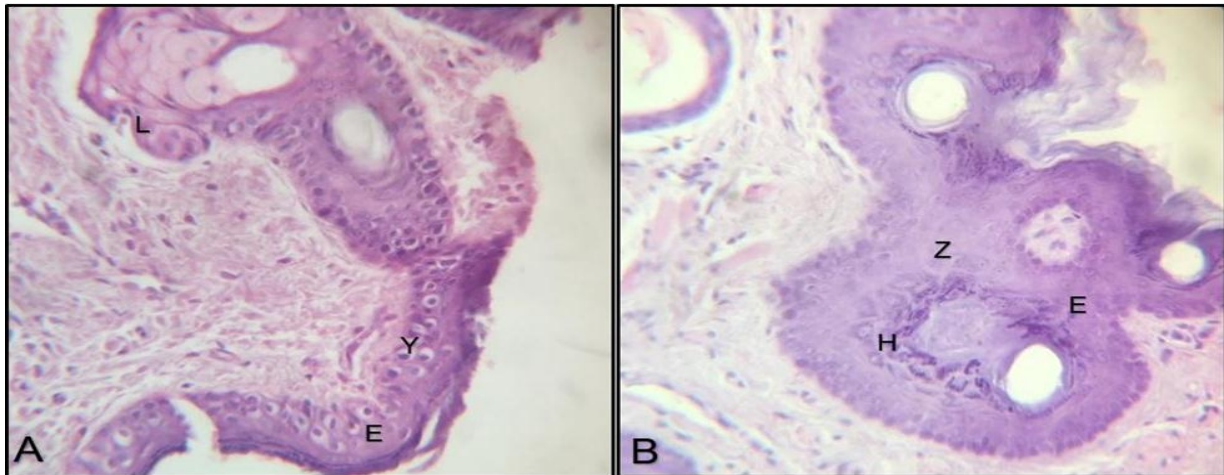


Fig. 3 – A - Mucosa section of the EG in 400X magnification stained with eosin and hematoxylin. Stratified squamous epithelium with hyperkeratosis (E) is observed, hydropic degeneration (Y) and glands (L). In the lamina propria, there is no inflammatory infiltration. B - Mucosa section of the EG in 400X magnification stained with eosin and hematoxylin. Stratified squamous epithelium presented hyperkeratosis (E) is observed, showing acanthosis (Z) and focal areas of nuclear hyperchromatism (H). In the lamina propria, there is no inflammatory infiltration.

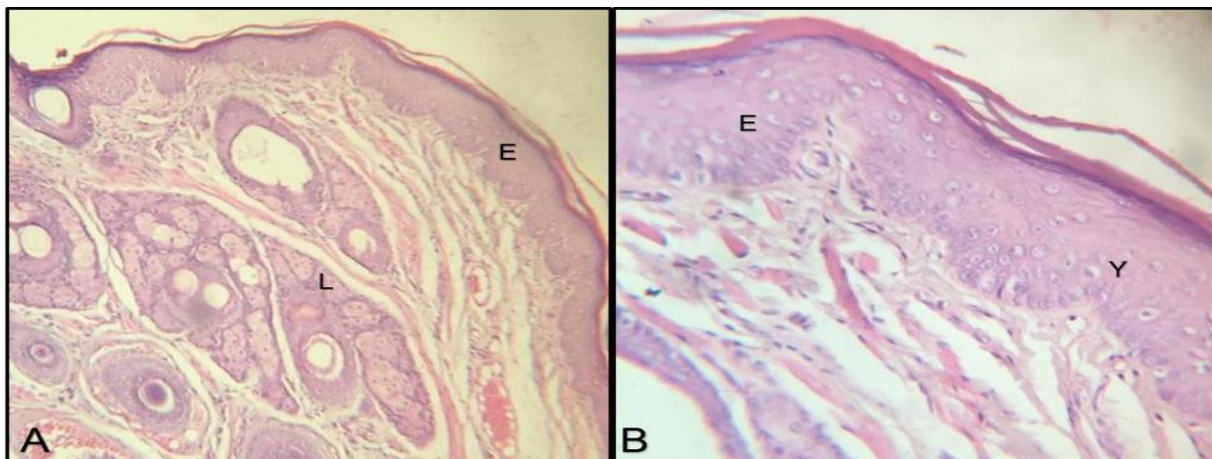


Fig. 4 – A - Mucosa section of the EG in 100X magnification stained with eosin and hematoxylin. Stratified squamous epithelium presented hyperkeratosis (E) is observed. In the lamina propria, there is no inflammatory infiltration. In depth, accessory glands are observed (L). B - Mucosa section of the EG in 400X magnification stained with eosin and hematoxylin. Stratified squamous

epithelium presented hyperkeratosis (E) is observed and focal areas of hydropic degeneration (Y). In the lamina propria, there is no inflammatory infiltration.

4. DISCUSSION

Mouth cancer reaches alarming levels globally, being the sixth most common among means (Patel et al., 2016). Therefore, it is necessary to consider the relationship between inflammation and oral cancer, as the inflammatory process has its role in the pathogenesis of oral squamous cell carcinoma. Furthermore, chronic inflammation, caused by chronic infections, or unregulated healing in areas of lesions that recur over time, may become a risk factor for cell transformation, thereby altering the epithelium (Feller et al. 2013). Patel et al. (2016) also agree that chronic inflammation can be considered a prominent and essential factor in developing oral cancer. Furthermore, Goertzen et al. (2018) suggested that inflammation associated with dysplasia is a transition stage between the non-neoplastic mucosa and oral squamous cell carcinoma, thus highlighting the importance of local control of chronic inflammation as a strategy for prevention.

Da Silva Santos et al. (2009) and Pereira et al. (2012) stated that the pulp and residues of guabiroba have acceptable amounts of phenolic compounds and high antioxidant activity. The present research findings confirmed the presence of polyphenols, vitamin C, carotenoids, pro-vitamin A activity and antioxidant activity in the guabiroba samples, in agreement with the study by Da Silva Santos et al. (2009) about the fruit. The protective effect of polyphenols is supposed to be related to their many biological actions, including antioxidant enzyme modulation (Pereira et al., 2012). Among these compounds, the activity of polyphenols is particularly important; according to Kuskoski et al. (2006) they demonstrate the ability to capture free radicals, enhance their antioxidant activity, and help prevent circulatory and cardiovascular diseases as well as cancer. Polyphenols also stand out, owing to their ability to decrease the action of carcinogenic substances; moreover, it has been found that they can inhibit the formation of nitrosamines, thus helping to prevent the formation of carcinogenic compounds (Patra et al., 2021). In his research, Gomes (2007) showed that carotenoids could be associated with organic protection against carcinogenesis and, thus, can also be considered an aid in preventing the disease. According to Patra et al. (2021), the demonstrated anticancer properties are mainly attributed to their anti-metastatic, anti-proliferative, anti-angiogenic, anti-inflammatory, cell cycle arrest, apoptotic and autophagic effects. Thus, all these characteristics explain the results observed in our histological research. Also, polyphenols have been demonstrated to reverse oncogenes, promote tumor suppressor genes, and inhibit cancer progression (Patel et al., 2021).

An adequate concentration of vitamin C in the guabiroba extract was observed in the results. This has been associated with reduced cell proliferation and induced apoptosis through the upregulation of p53. Chemoprevention can act both in the tumor initiation and promotion stages, preventing or delaying carcinogenesis through several pathways. One is acting on the p53 protein, which is strongly associated with oral squamous cell carcinoma. Also, The p53 protein is the guardian of the genome and plays a vital role in the vast majority of human malignancies (Merlin et al., 2021; Shankar et al., 2022).

The inflammatory infiltrate was also found in the animals; as shown by the results, it was present in at least 1 sample in all groups. However, there is a difference in the percentages, i.e., the inflammatory infiltrate was present in 100 % of the animals from the control group (the group that only received the application of DMBA) but in only 33.3 % of the animals from the experimental group (the group that received not only DMBA but also the extract of the pulp of Guabiroba at 12.0% in the form of a gel). This can be seen as a positive response triggered by the application of the extract since, for more than half of the animals, even with the regular application of DMBA, the application of the extract was able to prevent the inflammatory response and prevent its development. Moreover, one of the properties found in the fruit, namely its high antioxidant potential and its quantity of polyphenols, helped prevent the disease. The present research shows favorable results in the experimental group, which was in direct contact with a form of antioxidant; however, it should be noted that the research could have had even more expressive results with longer experimentation time and a bigger sample size. Nevertheless, it showed that antioxidant activity could indeed help prevent diseases. This finding can be seen in the research: the experimental group (which received DMBA and application of 12 % Guabiroba pulp extract in gel form) had a lower percentage of development of inflammatory activity in rodents.

Cancer chemoprevention is defined as the use of agents that can delay or disturb the process of tumorigenesis and natural products have been shown to have chemopreventive properties (Gairola et al., 2021). As regards our study and dysplastic changes, it was found that 66.7 % of the animals in the control group (application of DMBA only) presented moderate and intense dysplasia, while in the experimental group (application of DMBA and application of the extract of Guabiroba pulp at 12 % in the form of gel), 33.3 % of the animals had such characteristics. Therefore, when the guabiroba extract was not applied, the risk of developing injury was twice as high as in the group without the protective action of guabiroba. These data can be related to the studies by Mallery et al. (2014), Selvasundaram et al. (2018), and Maulina et al. (2019). These authors used a specific gel with a method similar to the one used in this research. They found interesting therapeutic responses to the dysplastic process in several cases; for example, clinical reduction of the size of lesions and a decrease in histopathological severity. Furthermore, in some situations, the progression of the disease was avoided, thereby limiting its effects and increasing its prevention (Mallery et al., 2014; Maulina et al., 2019; Selvasundaram et al., 2018). Several topical medications are FDA-approved for treating patients at risk for skin squamous cell carcinoma. Among these medications, Imiquimod, 5-Fluoracil and Sodium Diclofenac (Nemer and Council, 2019). Thus, our results show natural extracts that can be used in oral epithelium with an adequate outcome for an in vivo study. It should also be taken into account that these natural extracts have lower toxicity than conventional treatments

Therefore, the results showed a difference between the control and experimental groups, i.e., in the control group, which was only in contact with the DMBA, dysplasia occurred in its entire population. Compared to the experimental group, the guabiroba extract was applied in addition to the carcinogen. As a result, it was half as many samples with dysplasia. This finding shows that the application of the compound allowed the prevention of lesions in cheek mucosa owing to the antioxidant characteristics of such a compound and the presence of polyphenols (Da Silva Santos et al., 2009). Nevertheless, oral cancer remains a global problem, with a poor prognosis, invasive and aggressive treatments, and a low quality of life after treatment. Therefore, interventions like these, with low cost, without side effects and focusing on preventing the progression of the risk lesion to a tumoral one, are expected to be the way for future research (D'Souza and Adeppali, 2018).

The results found in this study showed that guabiroba could reduce the formation of epithelial dysplasia, which suggests its preventive efficacy; in addition, it reduces the presence of inflammatory cells. Further studies are suggested to complement and confirm these findings, with a bigger sample size and longer application time.

The study is supported by Univali, Epagri-SC and IFSC.

Authors declare no funding.

Authors declare no conflict of interest.

Conceptualization, Sarah Pilati; Data curation and Formal analysis, all authors; Methodology, Sandra Mendes and Stefany Arcari with Guabiroba and Sarah Pilati, Luis Noldin Jr e Paulo Amorim with animals and histology; Supervision, Sarah Pilati; Validation, Sandra Mendes, Sarah Pilati and Stefany Arcari; Writing – original draft, Paulo Amorim e Luis Noldin; Writing – review & editing, Stefany Arcari, Sarah Pilati and Sandra Mendes. All authors have read and agreed to the published version of the manuscript.

This research was approved by CEUA/UNIVALI/BRASIL number 032/18p1

REFERENCES

- Barbieri, S., S. Costa, A. Ruthes, C. Petkowicz, C. Kerkhoven, E. Silva and J. Silveira, 2019. Pectins from the pulp of gabirola (*Campomanesia xanthocarpa* Berg): Structural characterization and rheological behavior. *Carbohydrate Polymerase*, 15(214):250-258. doi: 10.1016/j.carbpol.2019.03.045.
- Carnevali T., M. Viera, A. Luciano, W. Gonçalves, W. Rodrigues and M. Ramos, 2015. Crescimento inicial de *Campomanesia xanthocarpa* O. Berg sob diferentes composições de substratos. *Revista brasileira de plantas medicinais*, 17(2):316-323. DOI: [10.1590/1983-084X/12_080](https://doi.org/10.1590/1983-084X/12_080)
- D'souza S. and V. Addepalli, 2018. Preventive measures in oral cancer: An overview. *Biomedicine Pharmacotherapy*, 107:72-80. doi: 10.1016/j.biopha.2018.07.114.
- El-Naggar A., J. Chan, J. Grandis, T. Takata and P. Slootweg, 2017. *WHO Classification of Head and Neck Tumours*. 4. ed. Lyon: OMS, 347. ISBN: 978-92-832-2438-9
- Feller L., M. Altini and J. Lemmer, 2013. Inflammation in the context of oral cancer. *Oral Oncology*, 49(9):887-892. DOI: [10.1016/j.oraloncology.2013.07.003](https://doi.org/10.1016/j.oraloncology.2013.07.003)
- Gairola K., S. Gururani, A. Bahuguna, V. Garia, R. Pujari and S. Dubey, 2021. Natural products targeting cancer stem cells: Implications for cancer chemoprevention and therapeutics. *Journal Food Biochemistry*, 45(7):13772. doi: 10.1111/jfbc.13772.
- Goertzen C., H. Mahdi, C. Laliberte, T. Meirson, D. Eymael, H. Gil-Henn and M. Magalhaes, 2018. Oral inflammation promotes oral squamous cell carcinoma invasion. *Oncotarget*, 9(49):29047-29063. doi: 10.18632/oncotarget.25540.
- Gomes F., 2007. Carotenóides: uma possível proteção contra o desenvolvimento de câncer. *Revista de nutrição*, 20(5):537-48. [Doi.org/10.1590/S1415-52732007000500009](https://doi.org/10.1590/S1415-52732007000500009).
- Kuskoski E, A. Asuero, M. Morales and R. Fett, 2006. Frutos tropicais silvestres e polpas de frutas congeladas: atividade antioxidante, polifenóis e antocianinas. *Ciência rural*. 36: 1283-1287 .<https://doi.org/10.1590/S0103-84782006000400037>
- Mallery S., M. Tong, B. Shumway, A. Curran, P. Larsen, G. Ness, K. Kennedy, G. Blakey, G. Kushner, A. Vickers, B. Han, P. Pei and G. Stoner, 2014. Tropical application of a mucoadhesive freeze-dried black raspberry gel induces clinical and histologic regression and reduces loss of heterozygosity events in premalignant oral intraepithelial lesions. *Clinical cancer research*, 20(7):1910-1924. DOI: 10.1158/1078-0432.CCR-13-3159.
- Manimaran A. and S. Manoharan, 2018. Tumor Preventive Efficacy of Emodin in 7,12-Dimethylbenz[a]Anthracene-Induced Oral Carcinogenesis: a Histopathological and Biochemical Approach. *Pathology Oncology Research* 24(1):19-29. doi: 10.1007/s12253-017-0205-7.
- Maulina T., I. Hadikrishna, A. Hardianto, E. Sjamsudin, B. Pontjo and H. Yusuf, 2019. The therapeutic activity of curcumin through its anticancer potential on oral squamous cell carcinoma: A study on Sprague Dawley rat. *SAGE open medicine*, 7. DOI: [10.1177/2050312119875982](https://doi.org/10.1177/2050312119875982)
- Merlin J., H. Rupasinghe, G. Dellaire and K. Murphy, 2021. Role of Dietary Antioxidants in p53-Mediated Cancer Chemoprevention and Tumor Suppression. *Oxidative Medicine Cellular Longevity*, 26 (2021)9924328. doi: 10.1155/2021/9924328.
- Morzelle, M., P. Bachiega, E. Souza, E. Vilas Boas and M. Lamounier, 2015. Caracterização química e física de frutos de curriola, gabirola e murici provenientes do Cerrado brasileiro. *Revista Brasileira de Fruticultura*, 37(1): 96-103. <http://dx.doi.org/10.1590/0100-2945-036/14>
- Nemer K. and M. Council, 2019. Topical and Systemic Modalities for Chemoprevention of Nonmelanoma Skin Cancer. *Dermatological Clinical*, 37(3):287-295. doi: 10.1016/j.det.2019.02.004.
- Patel J., F. Shah, G. Joshi and P. Patel, 2016. Clinical significance of inflammatory mediators in the pathogenesis of oral cancer. *Journal of cancer research Therapy*, 12(2): 447. DOI: [10.4103/0973-1482.147765](https://doi.org/10.4103/0973-1482.147765)
- Patra S., B. Pradhan, R. Nayak, C. Behera, S. Das, S. Patra, T. Efferth, M. Jena and S. Bhutia, 2021. Dietary polyphenols in chemoprevention and synergistic effect in cancer: Clinical evidence and molecular mechanisms of action. *Phytochemistry*, 90:153554. doi: 10.1016/j.phymed.2021.153554.
- Pereira A., T. Vidal and P. Constant, 2009. Antioxidantes alimentares: importância química e biológica: Dietary antioxidants: chemical and biological importance. *Revista Sociedade Brasileira Alimentar Nutricional Journal Brazilian Society Food Nutrition*, 34(3): 231-247.
- Pereira M., R. Steffens, A. Jablonski, P. Hertz, A. Rios, M. Vizotto and S. Flores, 2012. Characterization and Antioxidant Potential of Brazilian Fruits from the Myrtaceae Family. *Journal Agricola Food Chemistry*, 60 (12): 3061–3067. <https://doi.org/10.1021/jf205263f>
- Santos, M., P. Carneiro, G. Wosiacki, C. Petkowicz and E. Carneiro, 2009. Caracterização físico-química, extração e análise de pectinas de frutos de *Campomanesia Xanthocarpa* B. (Gabirola). *Semina ciência agrária*, 30 (1):101-106.
- Shankar G., M. Swetha, C. Keerthana, T. Rayginia and R. Anto, 2022. Cancer Chemoprevention: A Strategic Approach Using Phytochemicals. *Front Pharmacology*. 13(12):809308. doi: 10.3389/fphar.2021.809308.
- Wein R. and R. Weber, 2015. Malignant Neoplasms of the Oral Cavity. In: Flint PW, Haughey BH, Robbins KT, Thomas JR, Niparko JK, Lund VJ, Lesperance MM, editors. *Cummings Otolaryngology Head and Neck Surgery*. 6th ed. Philadelphia, PA: Elsevier Saunders; pp. 1359–87.