

Available online at [www.sciencedirect.com](http://www.sciencedirect.com)

ScienceDirect

journal homepage: [www.elsevier.com/locate/radcr](http://www.elsevier.com/locate/radcr)

## Case Report

# Imaging characterization of an adult H3 K27M-altered diffuse midline glioma of the medulla oblongata with a confounding steroid response ☆,☆☆

Claudia Godi, MD<sup>a,\*</sup>, Paolo Garofalo, MD<sup>b</sup>, Marcella Callea, MD<sup>c</sup>, Paolo Vezzulli, MD<sup>a</sup>, Maurizio Barbera, MD<sup>a</sup>, Carlo Mandelli, MD<sup>d</sup>, Elena Mazza, MD<sup>e</sup>, Bianca Pollo, MD<sup>f</sup>, Maria Rosa Terreni, MD<sup>c</sup>, Antonella Castellano, MD PhD<sup>a,g</sup>, Nicoletta Anzalone, MD<sup>a,g</sup>, Andrea Falini, MD PhD<sup>a,g</sup>

<sup>a</sup>Neuroradiology Unit and CERMAC, IRCCS San Raffaele Scientific Institute, Via Olgettina 60, 20132, Milan, Italy

<sup>b</sup>Policlinico Universitario di Monserrato, Cagliari University, Cagliari, Italy

<sup>c</sup>Department of Pathology, IRCCS San Raffaele Scientific Institute, Milan, Italy

<sup>d</sup>Department of Neurosurgery, IRCCS San Raffaele Scientific Institute, Milan, Italy

<sup>e</sup>Department of Medical Oncology, IRCCS San Raffaele Scientific Institute, Milan, Italy

<sup>f</sup>Neuropathology, Fondazione IRCCS Istituto Neurologico C. Besta, Milan, Italy

<sup>g</sup>Vita-Salute San Raffaele University, Milan, Italy

## ARTICLE INFO

## Article history:

Received 11 October 2022

Accepted 23 October 2022

Available online 18 December 2022

## Keywords:

Diffuse midline glioma

High-grade glioma

Medulla

Steroid response

Magnetic resonance imaging

## ABSTRACT

We report an uncommon, infratentorial localization of adult H3 K27M-altered diffuse midline glioma arising in a particularly rare site (medulla oblongata). In addition to this unusual presentation, the lesion exhibited a substantial contrast enhancement and size decrease after dexamethasone, generating diagnostic dilemmas. Histology, molecular details, advanced Magnetic Resonance imaging features and differential diagnoses are here described and discussed, as well as common misconceptions about steroid-sensitive mass lesions, and practical difficulties for clinicians involved in the process of making diagnosis.

© 2022 Published by Elsevier Inc. on behalf of University of Washington.

This is an open access article under the CC BY-NC-ND license

(<http://creativecommons.org/licenses/by-nc-nd/4.0/>)

## Introduction

Brainstem high-grade gliomas of the adult population are rare, representing 1%–2% of total malignant gliomas [1] (with the

☆ Funding: The authors did not receive support from any organization for the submitted work.

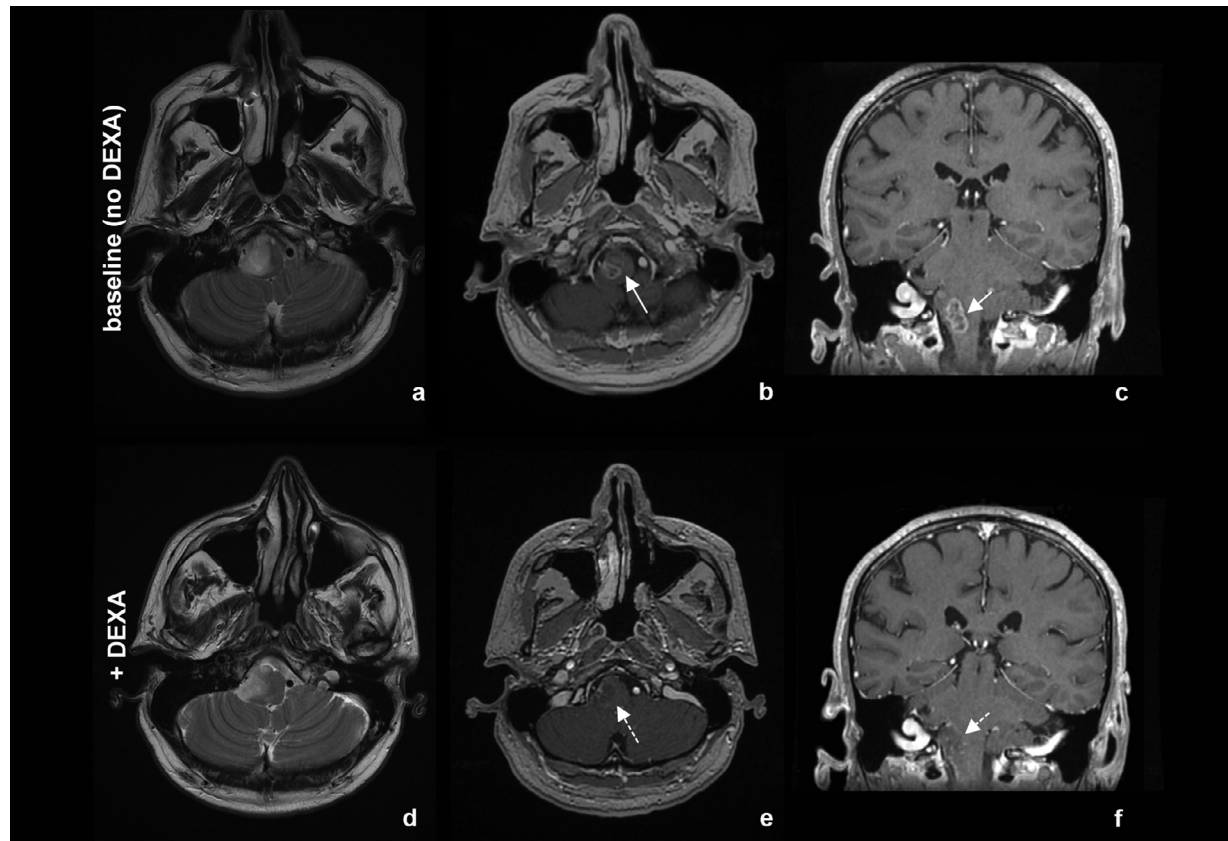
☆☆ Competing Interests: None.

\* Corresponding author.

E-mail address: [godiclaudia@hsr.it](mailto:godiclaudia@hsr.it) (C. Godi).

<https://doi.org/10.1016/j.radcr.2022.10.082>

1930-0433/© 2022 Published by Elsevier Inc. on behalf of University of Washington. This is an open access article under the CC BY-NC-ND license (<http://creativecommons.org/licenses/by-nc-nd/4.0/>)



**Fig. 1** – Upper panel: an intra-axial lesion centered in the right portion of the medulla oblongata, with high signal on T2-weighted images (A) and irregular, peripheral enhancement (arrows) after gadolinium administration on T1-weighted images (B, C). Lower panel: after 2 weeks of high-dose steroids (DEXA: dexamethasone), the mass appeared moderately reduced in size on T2-weighted images (D); contrast enhancement was decreased on T1-weighted images (dashed arrows in E, F).

majority of them occurring in the pons, and just about 30% of cases primarily arising in the medulla oblongata [2]). As they may have different genetic background or peculiar imaging phenotypes from pediatric or supratentorial adult counterparts, their description is important in order to improve our understanding of the entities introduced by the most recent WHO classifications of CNS tumors [3]. The current report includes an exceptionally rare presentation of an adult diffuse midline glioma H3 K27M-altered of the medulla oblongata, showing a significant and potentially confounding imaging response after steroids, with a two-fold aim: (1) to fully document imaging, pathology and molecular features of a rarely observed lesion, as it may add useful information for future classification studies; (2) to present diagnostic difficulties related to glioma steroid-responsiveness, and highlight the key contribution of advanced imaging for the diagnosis.

## Case presentation

A 54-year-old man, previous smoker with an unremarkable past medical history, was hospitalized for a lesion in the right medulla oblongata/upper cervical spinal cord.

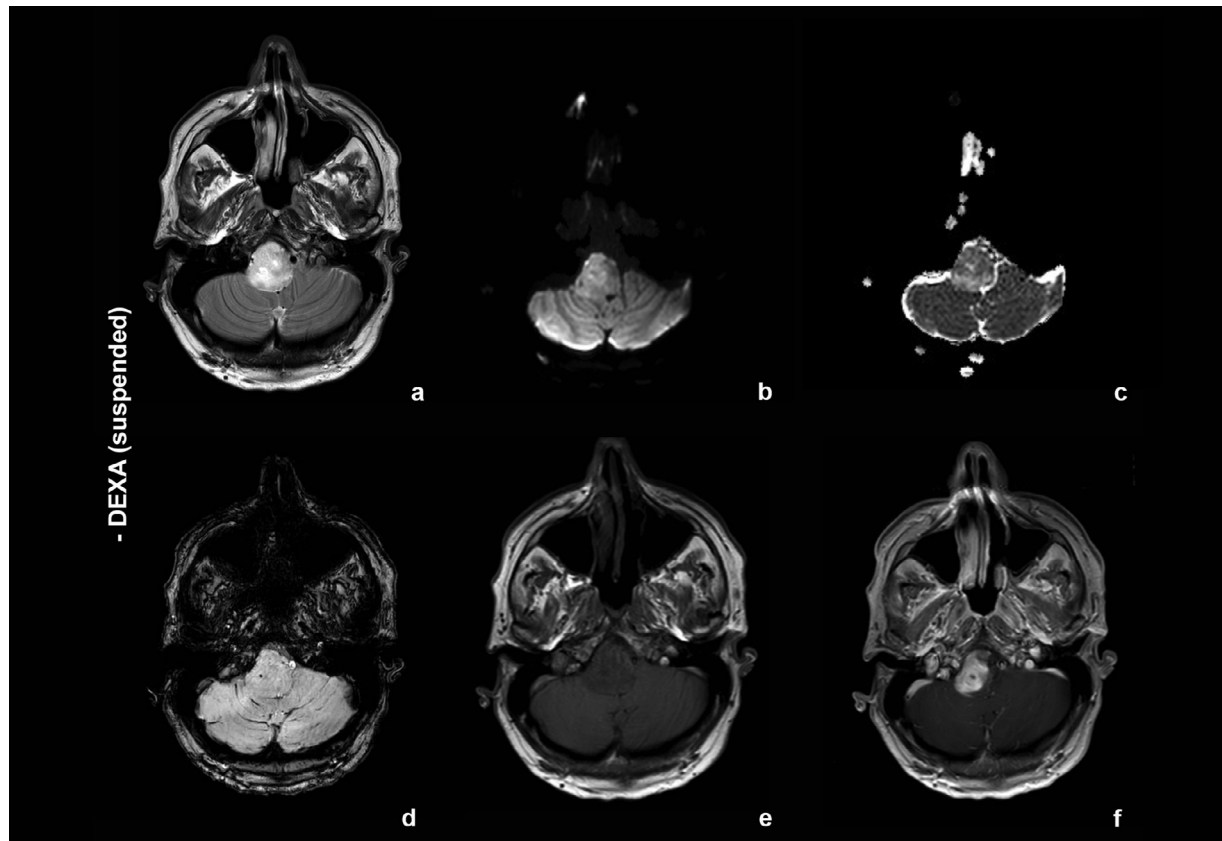
Three months before he started complaining of a thermal/pain anesthesia in the left arm, with a sensitive level at D4; he then underwent a brain and spinal MRI examination, which demonstrated an expansile, intra-axial strongly enhancing lesion with a necrotic core surrounded by edema in the right medulla oblongata (Figs. 1A–C). No other brain or spinal cord abnormalities were detected.

Total body 18F-FDG PET showed increased metabolic activity of the lesion. He underwent a total body CT scan with contrast that did not show any extra-cranial primary tumor.

Sensitive evoked potential tests were normal; considering the possibility of an infectious disease, serological tests (Ig-G and Ig-M for CMV, HIV, EBV, and quantiferon) were performed, but resulted negative; also CSF examination returned normal, with no cells nor inflammatory alterations.

To reduce mass effect in medulla, the patient was prescribed a short cycle of dexamethasone. Following a mild improvement of symptoms, a new MRI scan performed two weeks later (Figs. 1D–F) showed reduction of the area of T2 hyperintensity, and overall mass effect and contrast enhancement decrease. Shortly after, dexamethasone was withheld for the onset of an acute psychotic status.

Few weeks later, the patient underwent another brain MRI at 3 Tesla (Fig. 2) for neurological deterioration. MRI confirmed



**Fig. 2 – Brain MRI performed on 3 Tesla for neurological worsening few weeks after steroid withheld (DEXA: dexamethasone).**

a large intra-axial expansive lesion in the right medulla oblongata, extending along the upper right cervical spinal cord down to the level of C2. Compared with the previous studies (Fig. 1) the lesion had increased in size, and looked heterogeneously T2 hyperintense, T1 hypointense, with low ADC values (mean  $\pm$  SD:  $636.8 \pm 63.6 \times 10^{-6} \text{ mm}^2/\text{s}$ ). Susceptibility-weighted imaging (SWI) showed a little intralesional paramagnetic dot (Fig. 2D). Lesion enhancement was very intense (Figs. 2E and F). MR spectroscopy conducted with a single-voxel 2D PRESS technique and TE = 144 ms showed increased Choline (Cho) and decreased N-acetyl aspartate (NAA) peaks, with a Cho/NAA ratio of 3.42 (Fig. 3). pCASL, dynamic contrast enhancement (DCE) and dynamic susceptibility contrast (DSC) were acquired (Fig. 3), with leakage correction as recommended. ASL showed a highly perfused lesion (quantitative CBF = 46.76 mL/100 g per minute, with 3.95-fold increase in comparison to normal appearing contralateral parenchyma). Both DSC- and DCE-derived parameters were markedly elevated (rBV corrected = 14.48, Vp = 7.43) with normalized values of rBV and Vp of 6.29 and 6.32. A diagnosis of primary malignant neoplastic lesion was suggested. The patient was made informed about the difficulty of his individual case and involved in the decision process. After multi-disciplinary discussion, he eventually underwent a stereotactic brain biopsy.

Histological examination revealed a high-grade glioma with hypercellularity, marked atypia, mitosis and microvascular proliferation (Fig. 4). No lymphocytic infiltrates were

present in the tissue sample. Neoplastic cells were immunoreactive for GFAP and negative for IDH1 (clone H09/R132H) and p53; ATRX was retained.

Tumor sample was also immunostained with anti-H3K27M antibody showing a strong and diffuse nuclear staining in neoplastic cells; H3K27me3 expression was lost. Ki67 proliferation index was also assessed with value of about 20%.

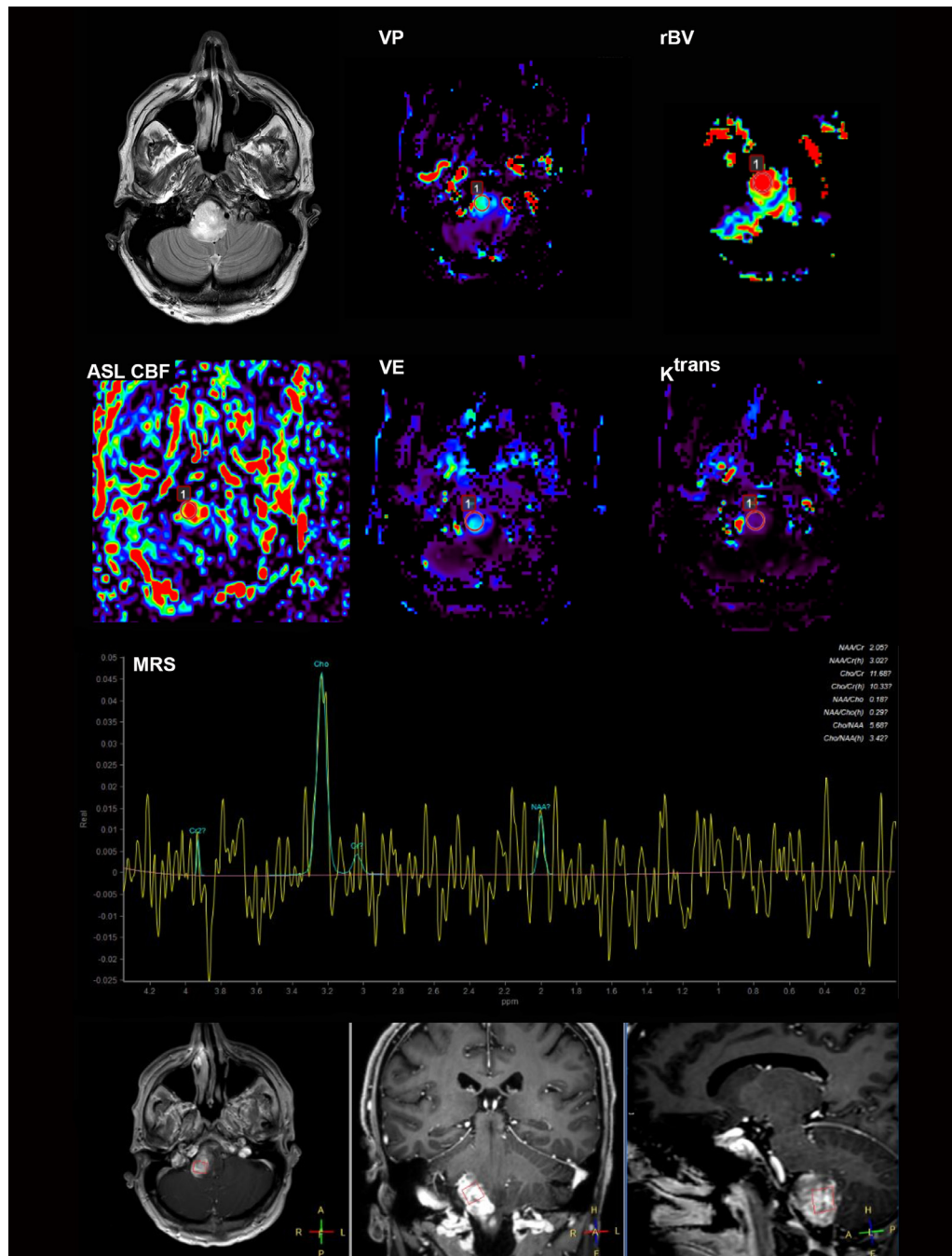
No mutations were detected either in IDH1 gene (codon 132) or in IDH2 gene (codon 172). The MGMT promoter was methylated.

According to the 2021 WHO Classification of Tumors of the Central Nervous System, the integrated histo-molecular diagnosis was diffuse midline glioma, H3 K27M-altered, grade 4 [4].

The patient was dismissed in a discrete global condition with an indication to start conformal fractionated radiotherapy (54 Gy in total, 27 daily fractions) in association with Temozolomide chemotherapy as standard of care [5,6]. Despite that, over the following weeks he underwent a progressive clinical deterioration until death.

## Discussion

We fully reported the imaging and molecular features an adult malignant brainstem diffuse midline glioma H3 K27M-altered



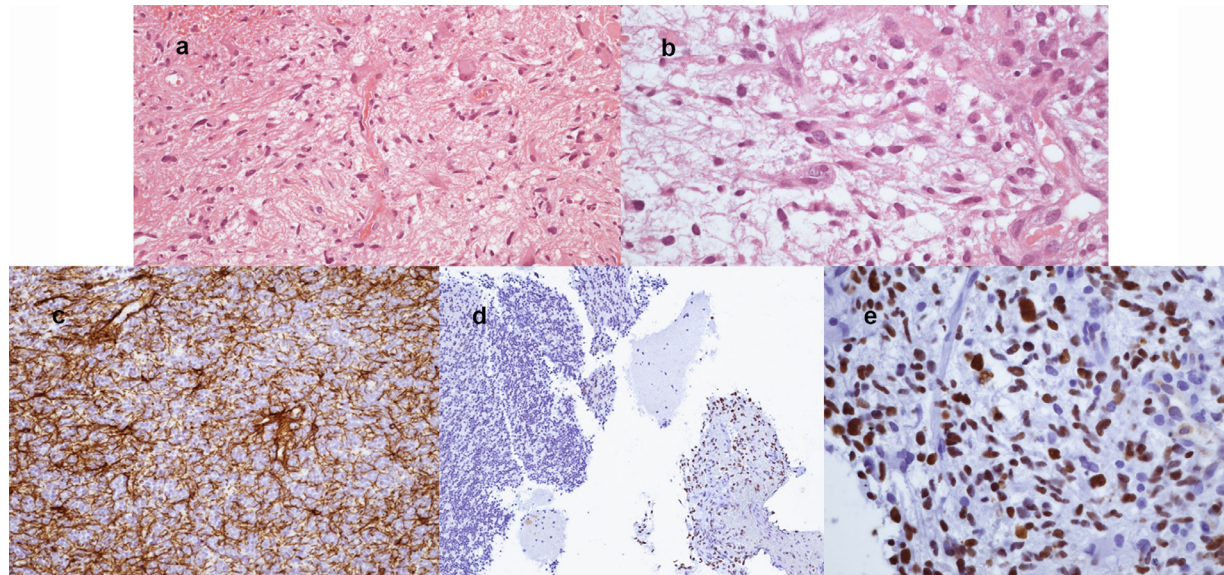
**Fig. 3** – DCE- and DSC-derived maps of plasma volume (VP), regional blood volume (rBV), extracellular volume (VE), and Ktrans at the level of the lesion. ROI indicated as «1» was placed on the non-necrotic portion of the mass; on the left side, corresponding axial T2-weighted (first row) and ASL CBF map (second row). Single-voxel spectroscopy (MRS) is displayed in the bottom panel of the figure: in the upper row, the spectrum obtained with TE = 144 ms demonstrated high Cho/Cr ratio, low NAA/Cr ratio, and no lipid/lactic acid peaks. In the lower row: axial, coronal, and sagittal T1-weighted images that were used to place the voxel.

with a significant response to steroids, with the primary goal of documenting an atypical presentation of a rare lesion.

The medulla oblongata is not a common site for a malignant glioma and the presented lesion was not close to the ventricular system as typically reported for infratentorial high-grade gliomas [1]. However, the basic MRI signal intensity

features were overall well-fitting with a hypothesis of glial tumor. Long TE MR Spectroscopy with very high Cho/NAA (>2) pointed toward an aggressive neoplasm rather than toward an inflammatory disease [7]. All in all, perfusion parameters with extremely high Vp and rBV suggested a densely vascularized lesion, in keeping with a malignant process [8]. Con-





**Fig. 4 – (A,B) Images of formalin-fixed paraffin-embedded (FFPE) tumor specimen hematoxylin and eosin (H&E) stained, 20× and 40×. Panels A and B highlight a high-grade glioma with increased cellularity, atypia, mitosis, and microvascular proliferation. (C-E) FFPE tumor sample immunostained with anti-GFAP antibody which shows a strong and diffuse immunoreactivity in neoplastic cells (C, 20×), and with anti-H3K27M antibody (D and E 10× and 40×, respectively) showing a strong nuclear staining in neoplastic cells. In contrast, normal cerebellar tissue (D, asterisk) is negative for anti-H3K27M antibody.**

sidering primary central nervous system lymphoma (PCNSL) as the main neoplastic diagnostic alternative, the absence of intralesional susceptibility signal on SWI and quite low ADC could have favored lymphoma [8], but the lack of a lipid peak at MR spectroscopy and very high Cho/Cr ratio were less characteristic.

In such a setting, an imaging-based approach correctly suggested the diagnosis of a high-grade glioma with little uncertainties; however, in a less specialized environment, a significant response to steroids may have introduced a diagnostic bias in favor of PCNSL or alternative diagnoses (eg, inflammatory), thus delaying biopsy and treatment. Indeed, steroid-induced lesion size reduction and contrast enhancement decrease is typical of inflammation and PCNSL, but this phenomenon has been also documented in other non-lymphomatous brain tumors (kidney metastasis, medulloblastoma, high-grade glioma) [9].

Steroids are commonly used for their anti-inflammatory and anti-edematous effects in neuro-oncology, and steroid-sensitivity is a renowned phenomenon in the management of gliomas, to the extent that variation of steroid dosage is one of the critical elements taken into account when evaluating treatment efficacy [10]. Despite this knowledge, steroids may anyway complicate imaging interpretation, especially for gliomas occurring in rare sites acting like “chameleons.” In such particular cases, it is particularly challenging to manage the information of previous steroid administration, and to balance its weight in the diagnostic reasoning. In our specific patient, it is also possible that the particularly constrained anatomical location (medulla oblongata) might have enhanced such steroid-induced fluctuations.

Whereas in PCNSL a dramatic imaging improvement after steroid treatment is known to be mediated by apoptosis of neoplastic lymphocytes [11], mechanisms of steroid action in gliomas are still not completely understood, despite short-term empirical use of dexamethasone for symptomatic relief and anti-edema effect is very common. Some pathological specimens of the few reported steroid-responding high-grade gliomas described peritumoral mature non-neoplastic lymphocytes [12], suggesting a similar mechanism with PCNSL. As these features were not present in our brain tissue sample, we cannot exclude a different pathway of steroid-sensitivity in our patient, maybe directly mediated by steroid receptors, which are expressed on glial neoplastic cells, as known from animal studies [13].

Regardless of the atypical presentation, our patient's extremely short survival was similar with other H3 K27M-altered gliomas: H3K27M mutation in the H3F3A gene is frequent in midline thalamic and brainstem gliomas, and it causes a gain-of-function mechanism in the neoplastic cells that eventually leads to abnormal cell-cycle control, autophagy inhibition, potentially increasing tumor resistance to radiotherapy. As in other works [14], also in our patient the presence of K27M mutation was mutually exclusive with IDH1 mutation. Noteworthy, our patient's lesion presented MGMT promotor methylation, a positive predictive factor of good response to therapy which is not frequently encountered in brainstem gliomas [15], but despite that, his final outcome was poor. It is possible that the positive effect provided by MGMT promotor methylation was mitigated by the coexisting K27M mutation, which is known to have a major impact on patients' prognosis [14].

## Conclusion

The current report includes a rare presentation of an adult diffuse midline glioma H3 K27M-altered occurring in the medulla oblongata, with a significant and potentially confounding imaging response after steroids. A practical lesson for clinicians involved in the process of making diagnosis is that an imaging-driven approach, independent from clinical information and steroid assumption, is always preferable and highly recommended when facing difficult cases. It is also worth bearing in mind that the phenomenon of steroid response is not confined to PCNSL or inflammatory lesions, and that it may occur with other CNS tumors, particularly glioma.

## Patient consent

The patient has provided written informed consent to use his clinical and imaging data for scientific use in the medical literature.

## REFERENCES

- [1] Stark AM, Maslehaty H, Hugo HH, Mahvash M, Mehdorn HM. Glioblastoma of the cerebellum and brainstem. *J Clin Neurosci* 2010;17(10):1248–51. doi:[10.1016/j.jocn.2010.02.015](https://doi.org/10.1016/j.jocn.2010.02.015).
- [2] Lakhan SE, Harle L. Difficult diagnosis of brainstem glioblastoma multiforme in a woman: a case report and review of the literature. *J Med Case Rep* 2009;3:87. doi:[10.1186/1752-1947-3-87](https://doi.org/10.1186/1752-1947-3-87).
- [3] Louis DN, Perry A, Reifenberger G, von Deimling A, Figarella-Branger D, Cavenee WK, et al. The 2016 World Health Organization classification of tumors of the central nervous system: a summary. *Acta Neuropathol* 2016;131(6):803–20. doi:[10.1007/s00401-016-1545-1](https://doi.org/10.1007/s00401-016-1545-1).
- [4] Louis DN, Perry A, Wesseling P, Brat DJ, Cree IA, Figarella-Branger D, et al. The 2021 WHO classification of tumors of the central nervous system: a summary. *Neuro Oncol*. 2021;23(8):1231–1251. doi:[10.1093/neuonc/noab106](https://doi.org/10.1093/neuonc/noab106).
- [5] Stupp R, Mason WP, van den Bent MJ, Weller M, Fisher B, Taphoorn MJB, et al. Radiotherapy plus concomitant and adjuvant temozolomide for glioblastoma. *N Engl J Med* 2005;352(10):987–96. doi:[10.1056/NEJMoa043330](https://doi.org/10.1056/NEJMoa043330).
- [6] Bunevicius A, Sheehan JP. Radiosurgery for glioblastoma. *Neurosurg Clin N Am* 2021;32(1):117–28. doi:[10.1016/j.nec.2020.08.007](https://doi.org/10.1016/j.nec.2020.08.007).
- [7] Majós C, Aguilera C, Alonso J, Julià-Sapé M, Castañer S, Sánchez JJ, et al. Proton MR spectroscopy improves discrimination between tumor and pseudotumoral lesion in solid brain masses. *AJNR Am J Neuroradiol* 2009;30(3):544–51. doi:[10.3174/ajnr.A1392](https://doi.org/10.3174/ajnr.A1392).
- [8] Kickingeder P, Wiestler B, Sahm F, Heiland S, Roethke M, Schlemmer H-P, et al. Primary central nervous system lymphoma and atypical glioblastoma: multiparametric differentiation by using diffusion-, perfusion-, and susceptibility-weighted MR imaging. *Radiology* 2014;272(3):843–50. doi:[10.1148/radiol.14132740](https://doi.org/10.1148/radiol.14132740).
- [9] Mazur MD, Nguyen V, Fuhs DW. Glioblastoma presenting with steroid-induced pseudoregression of contrast enhancement on magnetic resonance imaging. *Case Rep Neurol Med* 2012;2012:816873. doi:[10.1155/2012/816873](https://doi.org/10.1155/2012/816873).
- [10] Wen PY, Macdonald DR, Reardon DA, Cloughesy TF, Sorensen AG, et al. Updated response assessment criteria for high-grade gliomas: response assessment in Neuro-Oncology Working Group. *J Clin Oncol* 2010;28(11):1963–72. doi:[10.1200/JCO.2009.26.3541](https://doi.org/10.1200/JCO.2009.26.3541).
- [11] Greenstein S, Ghias K, Krett NL, Rosen ST. Mechanisms of glucocorticoid-mediated apoptosis in hematological malignancies. *Clin Cancer Res* 2002;8(6):1681–94.
- [12] Zaki HS, Jenkinson MD, Du Plessis DG, Smith T, Rainov NG. Vanishing contrast enhancement in malignant glioma after corticosteroid treatment. *Acta Neurochir (Wien)* 2004;146(8):841–5. doi:[10.1007/s00701-004-0282-8](https://doi.org/10.1007/s00701-004-0282-8).
- [13] Fan Z, Sehm T, Rauh M, Buchfelder M, Eyupoglu IY, Savaskan NE. Dexamethasone alleviates tumor-associated brain damage and angiogenesis. *PLoS One*. 2014;9(4):e93264. doi:[10.1371/journal.pone.0093264](https://doi.org/10.1371/journal.pone.0093264).
- [14] Feng J, Hao S, Pan C, Wang Y, Wu Z, Zhang J, et al. The H3.3 K27M mutation results in a poorer prognosis in brainstem gliomas than thalamic gliomas in adults. *Hum Pathol* 2015;46(11):1626–32. doi:[10.1016/j.humpath.2015.07.002](https://doi.org/10.1016/j.humpath.2015.07.002).
- [15] Reyes-Botero G, Giry M, Mokhtari K, Labussière M, Idhail A, Delattre JY, et al. Molecular analysis of diffuse intrinsic brainstem gliomas in adults. *J Neurooncol* 2014;116(2):405–11. doi:[10.1007/s11060-013-1312-2](https://doi.org/10.1007/s11060-013-1312-2).