

Available online at www.sciencedirect.com

ScienceDirect

journal homepage: www.elsevier.com/locate/radcr

Case Report

A case of Pseudo-Meigs' syndrome due to Brenner tumor[☆]Tetsuya Abe, MD^a, Tsukasa Saida, MD^{b,*}, Kaoru Fujieda, MD^c, Kei Inoue, MD^a, Toyomi Satoh, MD^c, Takahito Nakajima, MD^b^aDepartment of Radiology, University of Tsukuba Hospital, 2-1-1 Amakubo, Tsukuba, Ibaraki, 305-8576, Japan^bDepartment of Radiology, Faculty of Medicine, University of Tsukuba, 1-1-1 Tennodai, Tsukuba, Ibaraki, 305-8575, Japan^cDepartment of Obstetrics and Gynecology, Faculty of Medicine, University of Tsukuba, 1-1-1 Tennodai, Tsukuba, Ibaraki, 305-8575, Japan

ARTICLE INFO

Article history:

Received 15 December 2022

Revised 29 December 2022

Accepted 3 January 2023

Keywords:

Brenner

CA 125

Computed tomography

Meigs' syndrome

Magnetic resonance imaging

ABSTRACT

A 65-year-old woman with suspected ascites-associated abdominal distention had elevated CA125 levels. Contrast-enhanced computed tomography to search for the cause of the ascites showed bilateral pleural effusions, ascites, and an ovarian tumor. On magnetic resonance imaging the tumor exhibited a lobulated structure and markedly low signal intensity on both T1- and T2-weighted imaging, with no restrictions on diffusion-weighted images. Progressive enhancement was observed at tumor margins. Meigs syndrome due to fibroma was suspected, and total hysterectomy, bilateral salpingo-oophorectomy, and partial omentectomy were performed. Postoperatively, the pleural effusion and ascites resolved promptly without specific treatment. On pathological examination, the ovarian tumor was diagnosed as a benign Brenner tumor with scattered nests of transitional epithelium within a large amount of stroma. Based on the clinical course, the patient was diagnosed with pseudo-Meigs' syndrome due to a Brenner tumor.

© 2023 The Authors. Published by Elsevier Inc. on behalf of University of Washington.

This is an open access article under the CC BY-NC-ND license

(<http://creativecommons.org/licenses/by-nc-nd/4.0/>)

Introduction

Meigs' syndrome is a condition in which a fibroma is associated with a large amount of pleural effusion and ascites disappears after the removal of the ovarian tumor, and is frequently

associated with elevated CA-125 levels. A similar condition is seen in various tumors other than fibromas and is called pseudo-Meigs' syndrome. Herein, we present a case of a 65-year-old patient presenting pseudo-Meigs' syndrome caused by Brenner tumor, a relatively rare tumor.

[☆] Competing Interests: None.

* Corresponding author.

E-mail address: saida_sasaki_tsukasa@md.tsukuba.ac.jp (T. Saida).<https://doi.org/10.1016/j.radcr.2023.01.003>1930-0433/© 2023 The Authors. Published by Elsevier Inc. on behalf of University of Washington. This is an open access article under the CC BY-NC-ND license (<http://creativecommons.org/licenses/by-nc-nd/4.0/>)

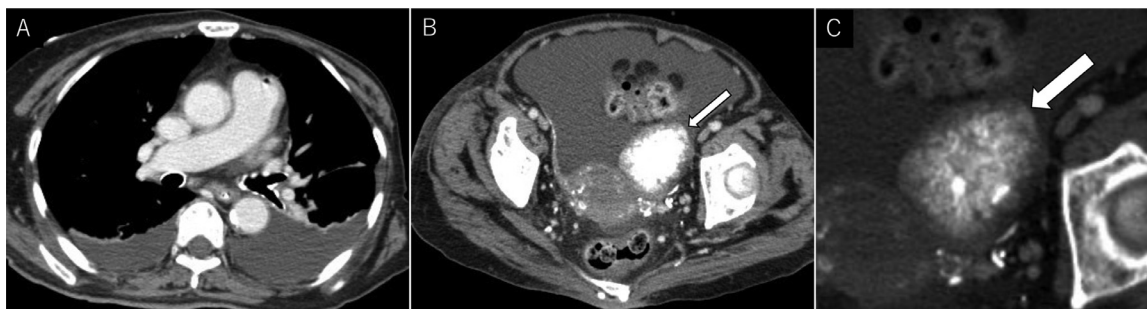

Fig. 1 – (A, B) A large amount of pleural effusion and ascites is seen, with no pleural or peritoneal thickening or nodules. **(B, C)** A left adnexal tumor with diffuse punctate calcification is seen (arrows).

Case report

A 65-year-old woman hospitalized for cerebrovascular disease presented with abdominal distention and was suspected of

having ascites. Her medical history included breast cancer 15 years prior and diabetes for the preceding 25 years. Because she was also anemic, contrast-enhanced computed tomography (CT) was performed to exclude malignancy and search for breast cancer recurrence. Her serum CA 125, CA19-9, and

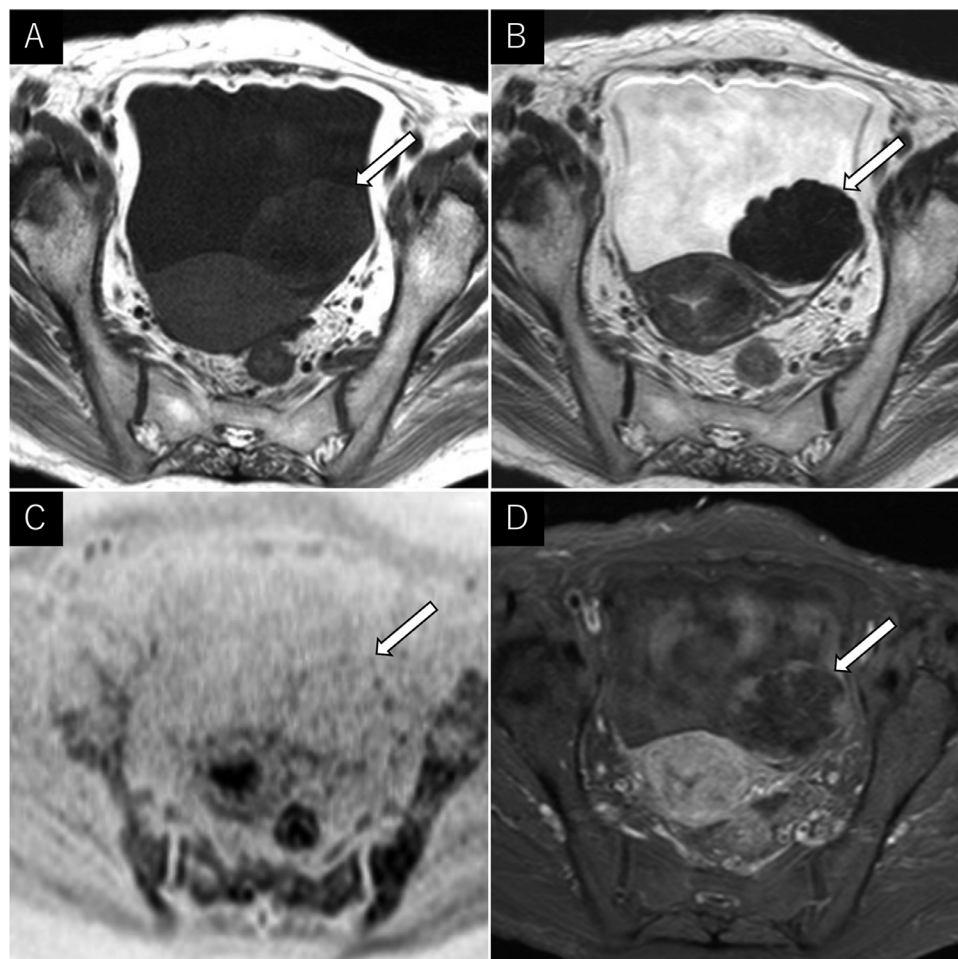


Fig. 2 – (A, B) The left adnexal tumor is lobulated, exhibiting markedly low signal intensity on T1- and T2-weighted images (arrows). **(C)** The tumor shows no restricted diffusion on black-and-white inverted diffusion-weighted imaging (arrow). **(D)** In the late phase of fat-saturated contrast-enhanced T1-weighted images, only the tumor margins exhibit a slightly inferior enhancement than that of the myometrium (arrow).

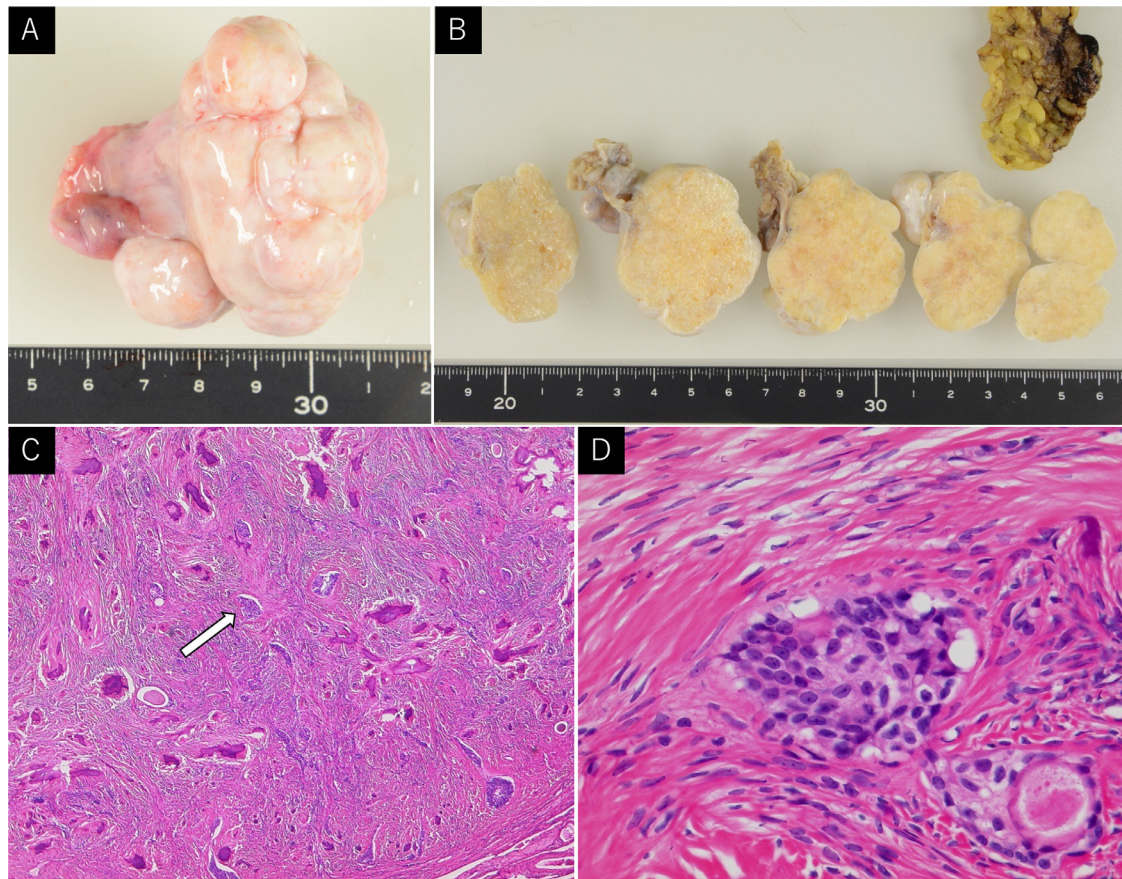


Fig. 3 – (A) The excised left ovarian tumor is a lobulated, smooth, and white. (B) The split surface is pale yellow and uniform with calcification. (C) A 100× image with hematoxylin-eosin staining shows tumor cells growing into small-to-medium-sized foci with large amounts of stromal vitellification and calcification. (D) In the 400× image of the arrow in C, the nuclei exhibit a characteristic "coffee bean-like" appearance with longitudinal grooves in the nuclei.

CEA levels were 557.2 IU/mL (normal range: <35 U/mL), 1.9 U/mL (normal range, <37 U/mL), and 4.7 ng/mL (normal range: <5 ng/mL), respectively. Subsequently, hemorrhoidal bleeding was endoscopically diagnosed as the etiology underlying her anemia later.

Contrast-enhanced CT revealed bilateral pleural effusions, but no pleural thickening or nodules (Fig. 1A). Massive ascites was also noted without peritoneal thickening or nodules (Fig. 1B). A 5 cm left adnexal mass was also observed (Fig. 1B and C). Pelvic magnetic resonance imaging (MRI) showed a lobulated left adnexal mass with markedly low signal intensities on both T1-weighted images and T2-weighted images (T2WI) (Fig. 2A and B). The mass showed no restricted diffusion on diffusion-weighted imaging (Fig. 2C). The enhancement effect in the dynamic contrast study was relatively poor, with slightly inferior enhancement to that of the myometrium at the tumor margins in the late contrast phase (Fig. 2D). Meigs' syndrome due to a fibroma was suspected based on the large amount of bilateral pleural effusions, ascites, and the adnexal mass with significantly low signal intensity on T2WI. Subsequently, total hysterectomy, bilateral salpingo-oophorectomy, and partial omentectomy were performed.

Postoperatively, pleural effusion and ascites resolved promptly without treatment. The excised left ovarian tumor was lobulated and measured 55 × 43 × 40 mm (Fig. 3A). The split surface was uniformly pale yellow with calcification (Fig. 3B). Capsular rupture or seeding was not observed. The right ovary and uterus were both normal. Pathologically, the tumor cells grew in small-to-medium-sized foci with substantial stromal vitellification and calcification (Fig. 3C). The nuclei had a characteristic "coffee bean-like" appearance with longitudinal grooves in the nuclei (Fig. 3D). The tumor cells lacked nuclear atypia, and the density of the tumor foci was low with no papillary growth. Consequently, the patient was diagnosed with a benign Brenner tumor.

Discussion

A Brenner tumor is composed of nests of bland transitional epithelium set within a dense fibromatous stroma. Brenner tumors are relatively rare and account for approximately 5% of all benign ovarian epithelial tumors. Most patients are asymp-

tomatic, and tumors are typically found incidentally in ovaries removed for other reasons. Larger tumors can result in abdominal enlargement or pain [1]. On imaging, it is typically visualized as a well-defined, enhancing tumor with markedly low signal intensity on T2WI. The enhancement of the solid components is inferior to or equal to that of the myometrium. High b-value diffusion images exhibit low-to-moderate signal intensity. Calcification is present in > 50% of cases, and punctate is the most common pattern of calcification, followed by coalescence. It frequently coexists with other epithelial tumors, especially mucinous tumors [2,3].

Various tumors reportedly cause pseudo-Meigs' syndrome, including sex cord stromal tumors, benign and malignant epithelial tumors, metastatic tumors, and uterine myoma [4,5]. Although a few cases of pseudo-Meigs syndrome have been associated with Brenner tumors, their MRI findings have not been described. In general, Brenner tumors are similar to fibromas or thecomas on MRI, but the lack of degeneration, even in large masses, the relatively strong enhancing effect, and a high frequency of calcification are their distinguishing features. Retrospective reference of this case was consistent with these findings and was considered a typical image of Brenner tumor.

Several mechanisms have been proposed for the ascites in Meigs' syndrome, including peritoneal irritation, release of toxins and inflammatory products released by the tumor, tumor-associated lymphatic and venous obstruction, and hypoproteinemia. This ascites then migrates into the pleural cavity through the lymphatic vessels and small holes in the diaphragm, resulting in pleural effusion. The mechanism of elevated CA-125 levels in pseudo-Meigs' syndrome has not been elucidated, but purportedly results from the stimulation of free fluid, leading to pleural and peritoneal surface inflammation [4,5].

Conclusion

Pseudo-Meigs' syndrome due to a Brenner tumor is rare. Although Brenner tumors and fibromas have similar MRI findings because both are rich in fibrous components, a retrospective evaluation of this case revealed that diffuse calcification consistent with the tumor was more indicative of a Brenner tumor.

Patient consent

A written consent was obtained from the patient for publication of this case and any accompanying images.

REFERENCES

- [1] Falkins AK, Palacios J, Xue WC. Tumours of the ovary; Brenner tumour. In: *Female genital tumours. WHO classification of tumours*. Lyon: IARC Press; 2020. p. 71–2.
- [2] Moon WJ, Koh BH, Kim SK, Kim YS, Rhim HC, Cho OK, et al. Brenner tumor of the ovary: CT and MR findings. *J Comput Assist Tomogr* 2000;24:72–6.
- [3] Montoriol PF, Hordonneau C, Boudinaud C, Molnar I, Abrial C, Kossai M. Benign Brenner tumour of the ovary: CT and MRI features. *Clin Radiol* 2021;76:593–8.
- [4] Jin C, Dong R, Bu H, Yuan M, Zhang Y, Kong B. Coexistence of benign struma ovarii, pseudo-Meigs' syndrome and elevated serum CA 125: case report and review of the literature. *Oncol Lett* 2015;9:1739–42.
- [5] Buttin BM, Cohn DE, Herzog TJ. Meigs' syndrome with an elevated CA 125 from benign Brenner tumors. *Obstet Gynecol* 2001;98:980–2.