

Available online at [www.sciencedirect.com](http://www.sciencedirect.com)

ScienceDirect

journal homepage: [www.elsevier.com/locate/radcr](http://www.elsevier.com/locate/radcr)

## Case Report

# Intrahepatic abscess secondary to retained stercolith, following laparoscopic appendectomy<sup>☆,☆☆</sup>

Jihad Boularab\*, Meryem Zhim, Chaymae Lahlou, Meriem Edderai, Jamal El Fenni

Department of Radiology, Mohammed V Military Hospital, Mohammed V University, Faculty of Medicine and Pharmacy, Rabat, Morocco

## ARTICLE INFO

## Article history:

Received 25 September 2022

Revised 4 October 2022

Accepted 8 October 2022

Available online 13 January 2023

## Keywords:

Retained stercolith

Abscess

CT

Laparoscopic appendectomy

## ABSTRACT

Abscesses of the peritoneal cavity and in particular hepatic abscess due to stercolith retention are a rare complication of appendectomy. Their prevalence is likely to increase as laparoscopic appendectomies become more common. This potentially serious complication can be prevented by following certain technical recommendations. Percutaneous drainage is bound to failure since it leaves the coprolite that causes the recurrence of the abscess, thus when it happens it requires surgical drainage. We report a case of a 40-year-old man, who underwent laparoscopic appendectomy 8 months prior, and presented to the emergency department for acute pain of the right hypochondrium. The radiologic investigations revealed 2 abscesses of the liver and the right iliac fossa containing a central spontaneously hyperdense stercolith. The patient was treated with open surgery removing the stercoliths and draining of the abscesses, with favorable postoperative outcome.

© 2023 Published by Elsevier Inc. on behalf of University of Washington.

This is an open access article under the CC BY-NC-ND license

(<http://creativecommons.org/licenses/by-nc-nd/4.0/>)

## Introduction

Acute appendicitis is the inflammation of the appendix; it can occur at any age, mostly between 10 and 40 years, with a peak frequency at the age of 10 years and a male predominance. The rapid surgical treatment, which includes an immediate laparoscopic appendectomy maintains a low mortality rate between 0.1% and 0.25%; however, it might expose patients to several complications [1].

Intra-abdominal abscess, despite its low incidence, remains one of the most serious complications of this procedure. The majority of post appendectomy intra-abdominal abscesses, especially postlaparoscopic appendectomies, correspond to early onset abscesses often located in the pelvis or the Douglas Cul-de-sac. They are treated by percutaneous drainage (interventional radiology) or by rectotomy or culdotomy [2].

Our observation reports a rarer and more particular situation of intra-abdominal abscesses complicating appendectomy: abscess on stercolith retention [2].

<sup>☆</sup> Guarantor of Submission: The corresponding author is the guarantor of submission.

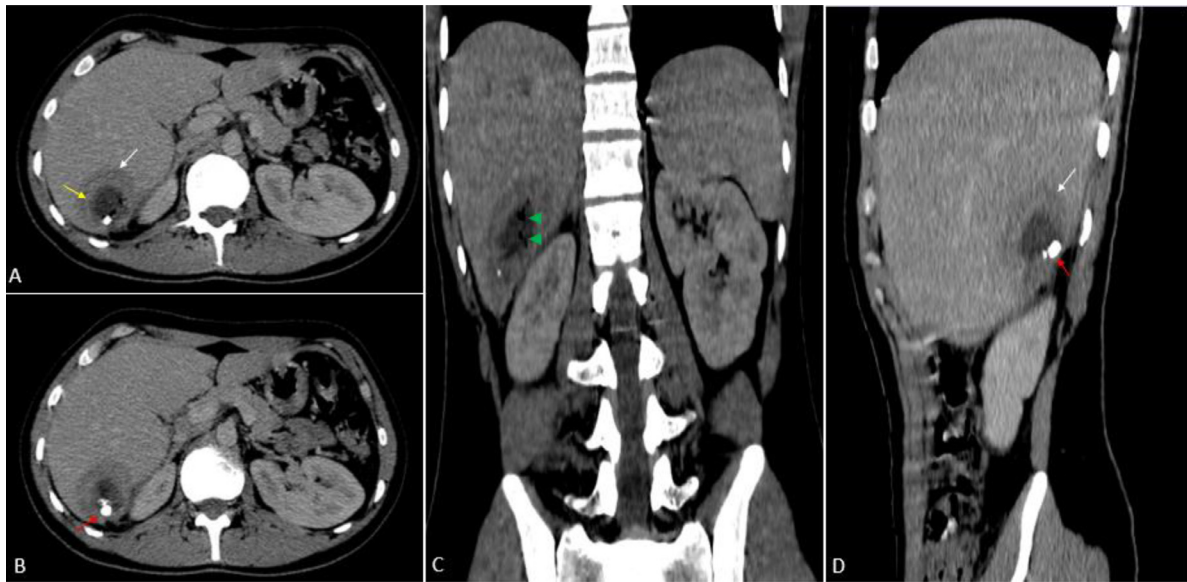
<sup>☆☆</sup> Competing Interests: The authors declare that they have no conflicts of interest.

\* Corresponding author.

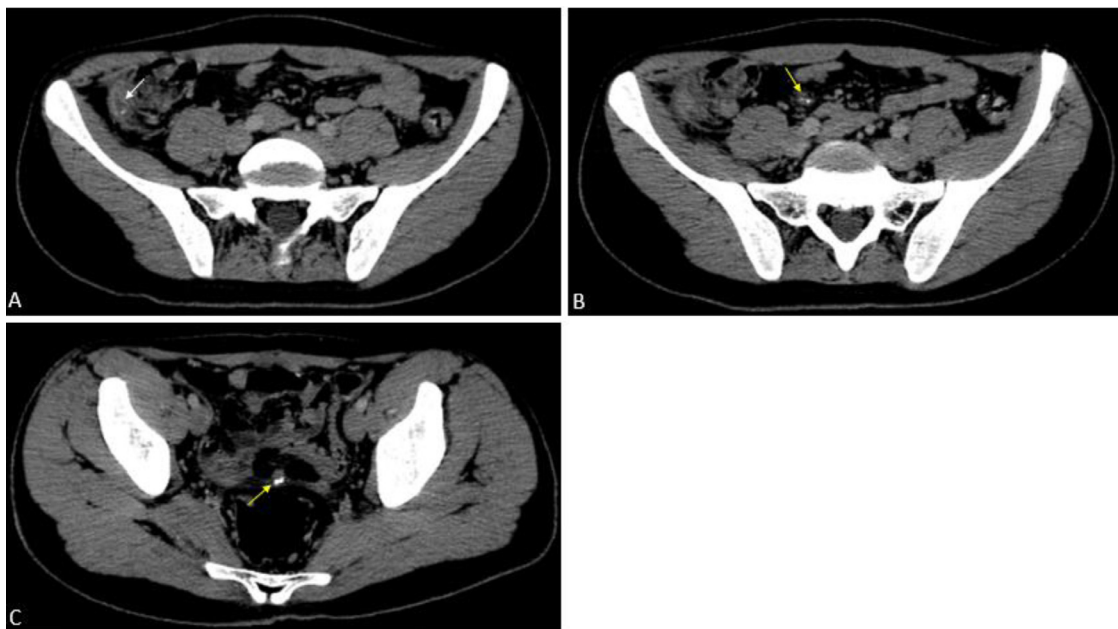
E-mail address: [boularabjihad@gmail.com](mailto:boularabjihad@gmail.com) (J. Boularab).

<https://doi.org/10.1016/j.radcr.2022.10.027>

1930-0433/© 2023 Published by Elsevier Inc. on behalf of University of Washington. This is an open access article under the CC BY-NC-ND license (<http://creativecommons.org/licenses/by-nc-nd/4.0/>)



**Fig. 1.** – Postcontrast abdominal CT in axial (A, B), coronal (C), and sagittal (D) sections demonstrating a well-defined collection of segment VI of the liver, with a thick enhanced wall (yellow arrows) and perilesional edema (white arrows), containing air bubbles (green head arrows) and stercoliths (red arrows).



**Fig. 2.** – Postcontrast abdominal CT in axial sections showing a small collection of the right iliac fossa containing a stercolith (green arrow), free intraperitoneal stercoliths within the Douglas Cul-de-sac and the right parieto-colonic gutter (yellow arrows).

### Case report

A 40-year-old with a medical history of hypertension under treatment and surgical history of laparoscopic appendectomy 8 months prior with no immediate postoperative complications, consulted for diffuse abdominal pain with a feeling of

heaviness of the right hypochondrium evolving for 15 days in a context of weight loss (2 kg) and fever. His vital signs included a pulse of 130 beats/min, blood pressure of 106/53 mmHg, respiratory rate of 18 breaths/min, oxygen saturation of 95% and body temperature of 38.3°C. Physical examination of the abdomen revealed an acute sensitivity of the right hypochondrium with focal tenderness.

Laboratory tests revealed leukocytosis with a white blood cell count of  $16.7 \times 10^9$  /L (Normal:  $4.5\text{--}11.0 \times 10^9$  /L) and C-reactive protein of 21 mg/dL (Normal: Less than 10 mg/L). An abdominal ultrasound showed a cystic lesion of 33 the hepatic segment VI, presenting as a hypoechoic heterogeneous collection with a thick wall. The diagnosis of liver abscess was evoked. A CT scan was performed confirming the diagnosis of abscess presenting as well-defined hypodense lesion of the segment IV of the liver, with marginal contrast enhancement realizing the “target sign”, the abscess contained a hyperdense millimetric lesions ( $>200\text{UH}$ ) corresponding to the retained stercolith and some air bubbles (Fig. 1). The CT also showed the existence of another minor collection in the right iliac fossa, as well as additional intraperitoneal stercolith in the right parieto-colonic gutter and the Douglas Cul-de-sac (Fig. 2).

The patient was treated with a surgical procedure: open laparotomy with drainage of the abscesses and retrieval of the stercoliths. Following a 10-day course of antibiotics with favorable outcome, the patient was discharged home.

## Discussion

The singularity of these abscesses arises from their sub and intrahepatic localization, their late onset, and treatment, which in our opinion must be unequivocal: surgical revision.

The subhepatic localization is explained by the fact that the stercolith is expelled towards this sloping space during the “abundant” lavage, and this become easier when the patient is placed in the Trendelenburg position. In our case, prolonged irritation of the liver surface by the direct contact with the stercolith is probably the mechanism of the abscess formation.

The risk of occurrence of this type of abscess is higher in gangrenous or perforated appendicitis since a stercolith is present in 50% of cases of appendicular perforation [3,4]. The delayed manifestation of these subhepatic abscesses is due to the fact that they reflect the late expression of the stercolith lost in the abdominal cavity. The prevalence of these abscesses caused by residual stercolith is likely to increase as the number of laparoscopic appendectomies rises. With the spread of laparoscopic cholecystectomy, the incidence of complications related to intra-abdominal loss of gallstones has grown [4]. The difficulty in exploring the declivity regions of the abdomen laparoscopically, particularly the subphrenic and subhepatic regions, explains the challenges in making an intraoperative diagnosis of loss of stercolith.

When it comes to imaging, ultrasound and in particular abdominal CT has an important role in this situation, by confirming the existence of the stercolith and locating it precisely, which facilitates and guides the laparoscopic exploration.

The stercolith appears in the form of a calcified concretion of the intestinal contents in the appendicular lumen generating a shadow cone posterior to the ultrasound.

From a therapeutic point of view, the particularity of this situation comes from the fact that percutaneous drainage of the abscess alone leads to failure. This is clearly shown in the observation of Stratern et al.; the patient had percutaneous drainage on 2 occasions with successive failures before a laparotomy which allowed a definitive treatment by drainage and extraction of the coprolite [2].

The prevention of this type of abscess requires the search for the stercolith as soon as possible, particularly when the surgeon is in front of a risky situation (perforated gangrenous appendix or stercolith seen on imaging). This search must be carried out before putting the patient in the Trendelenburg position and starting a stercolith lavage, which may drive the stercolith to areas that are difficult to explore by laparoscopy.

Finally, it is important to know how to look for the stercolith in the right parieto-colonic gutter and in the inter hepatodiaphragmatic region [2].

## Conclusion

The diagnostic utility of cross-section approaches has received the majority of attention in discussions concerning the usefulness of imaging in acute appendicitis. Little interest has been paid to the significance of showing the exact location of a stercolith in order to encourage and guide the surgeon for a more specific intraoperative search. Finally, the radiologist should be mindful of residual stercolith as a reason for the development of abscesses following appendectomy.

## Patient consent

Written informed consent for publication was obtained from patient.

## REFERENCES

- [1] Unen, E, Banza, M, Mukakala, A, Tamubango Kitoko, H, Mukonkole, T, Kibabu, J-G, et al. (2022). Appendicite aigue: Aspects diagnostiques et prise en charge coelioscopique versus laparotomie aux cliniques universitaires de Lubumbashi et hôpital militaire de la Ruashi. 1-09. 10.9790/0853-2102120109.
- [2] Rahili A, Habre J, Delotte J, Desprez B, Rampal P, Benchimol D. Coprolithe résiduel après appendicectomie coelioscopique. *Ann Chir* 2003;128(5):326–8 ISSN 0003-3944. doi:10.1016/S0003-3944(03)00095-6.
- [3] Katkhouda N, Friedlander MH, Grant SW, Achanta KK, Essani R, Paik P, et al. Intra-abdominal abscess rate after laparoscopic appendectomy. *Am J Sur* 2000;180:456–61.
- [4] Strathern DW, Jones BT. Retained fecalith after laparoscopic appendectomy. *Surg Endosc* 1999;13:287–9.