

Available online at www.sciencedirect.com

ScienceDirect

journal homepage: www.elsevier.com/locate/radcr

Case Report

Percutaneous transhepatic obliteration of a large portosystemic shunt associated with hepatic encephalopathy using a technique of n-butyl-2-cyanoacrylate injection inside hydrogel-coated coils: A case report ☆,☆☆

Yosuke Nozawa, MD^{a,*}, Koichi Masuda, MD^a, Tadashi Katayama, MD^b, Yuko Kobashi, MD, PhD^a, Koshi Ikeda, MD, PhD^a, Taiga Suzuki, MD^a, Takeshi Fukuda, MD, PhD^c

^a Department of Radiology, Tokyo Dental College Ichikawa General Hospital, 5-11-13 Sugano, Ichikawa-shi, Chiba 272-8513, Japan

^b Department of Gastroenterology, Tokyo Dental College Ichikawa General Hospital, 5-11-13 Sugano, Ichikawa-shi, Chiba 272-8513, Japan

^c Department of Radiology, Jikei University, Jikei University Hospital, 3-19-18 Nishishinbashi, Minato-ku, Tokyo 105-8471, Japan

ARTICLE INFO

Article history:

Received 31 August 2022

Accepted 11 September 2022

Available online 4 October 2022

Keywords:

Hepatic encephalopathy
Percutaneous transhepatic
obliteration
n-butyl-2-cyanoacrylate
Hydrogel-coated coil

ABSTRACT

Portosystemic shunts with cirrhosis may lead to hepatic encephalopathy (HE), which is often pharmacotherapy-resistant. We report a case of a 66-year-old female patient diagnosed with alcoholic cirrhosis and uncontrolled HE. She underwent percutaneous transhepatic obliteration (PTO) for treatment of a large portosystemic shunt from the left and right gastric veins to the azygos vein. We embolized the target veins using hydro-coated coils and filled them with n-butyl-2-cyanoacrylate (NBCA), leading to firm obstruction of the large portosystemic shunt without NBCA migration, thus reducing the number of coils required. The HE symptoms improved after PTO and could thereafter be controlled with conservative therapy. Our results showed that PTO using an NBCA injection inside hydrogel-coated coils for a large portosystemic shunt associated with HE is effective and safe.

© 2022 The Authors. Published by Elsevier Inc. on behalf of University of Washington.

This is an open access article under the CC BY-NC-ND license (<http://creativecommons.org/licenses/by-nc-nd/4.0/>)

☆ Competing Interests: This case report did not result from any specific grant funding agencies in the public, commercial, or not-for-profit sectors. None of the authors have industry relationships to report.

☆☆ Funding: This research did not receive any specific grant from funding agencies in the public, commercial, or not-for-profit sectors.

* Corresponding author.

E-mail address: nozawaivr@gmail.com (Y. Nozawa).

<https://doi.org/10.1016/j.radcr.2022.09.041>

1930-0433/© 2022 The Authors. Published by Elsevier Inc. on behalf of University of Washington. This is an open access article under the CC BY-NC-ND license (<http://creativecommons.org/licenses/by-nc-nd/4.0/>)

Introduction

Hepatic encephalopathy (HE) is a severe complication of cirrhosis. The prevalence of overt HE ranges between 30% and 45% [1]. HE is defined as brain dysfunction caused by liver insufficiency and/or portal-systemic blood shunting and is classified as following: type A, if it occurs in acute liver failure; type B, if there are portosystemic bypasses without intrinsic hepatocellular disease; and type C, the presence of cirrhosis and portal hypertension with portosystemic shunts [2,3].

The efficacy of balloon-occluded retrograde transvenous obliteration (BRTO) for treatment of portosystemic shunts in type C HE is well documented [4]. However, BRTO has several limitations in the case of absence of available drainer veins [5]. Herein, we report a case of a 66-year-old female patient who had HE due to a large portosystemic shunt from the left and right gastric veins to the azygos vein and underwent percutaneous transhepatic obliteration (PTO) using a hydrogel-coated coil filled with n-butyl-2-cyanoacrylate (NBCA).

Case report

A 66-year-old female patient presented with alcoholic cirrhosis (Child-Pugh score, 10C status) and hyperammonemia (maximum ammonia level up to 452 $\mu\text{g/dL}$ at presentation), suspected to be due to a large portosystemic shunt [6]. The patient also had symptoms of HE that corresponded to the stage 3 classification of the West Haven criteria [7], which were not sufficiently controlled by conventional medical treatment alone. Abdominal intervention for HE was requested by the physician. Computed tomography (CT) angiography revealed a large portosystemic shunt from the left and right gastric veins to the azygos vein. Owing to the severe tortuosity of the azygos vein as a drainer vein, an effective BRTO was considered to be very difficult. Therefore, we decided to perform a PTO via the anterior branch of the right portal vein instead. Esophageal varices were treated endoscopically.

After local anesthesia, an 8-Fr sheath was inserted into the anterior branch of the right portal vein under ultrasound guid-

ance. Pre-interventional portal venography demonstrated a large portosystemic shunt from the left and right gastric veins to the azygos vein and reflux portal vein flow due to portal hypertension (Fig. 1). We intended to embolize the proximal part of the left and right gastric veins, including the anastomosis points of these veins. The maximum diameter of the target vein to be embolized was 16.6 mm. In this PTO procedure, detachable coils (AZUR CX35 20-mm \sim 10-mm, Terumo, Tokyo, Japan and Target XXL 20-mm, Stryker, MI) were first used at the target vein under balloon occlusion (Selecon mp catheter II 20-mm, Terumo, Tokyo, Japan), and the inside of the coils was filled with 1:1 or 1:2 NBCA (Histoacryl, B. Braun, Hessen, Germany). The NBCA adhered to the coils without non-target embolization (Fig. 2). A total of 24 coils were used in this procedure. Post-interventional portal venography demonstrated a large decrease in the portosystemic shunt and normal portal vein re-flow (Fig. 3). The AZUR CX 35 series and NBCA were used for sheath tract embolization.

After PTO, the symptoms of HE improved from stage 3 to almost normal, according to the West Haven criteria [6]. Moreover, the ammonia level rapidly decreased before and after the intervention (from 148 $\mu\text{g/dL}$ to 32 $\mu\text{g/dL}$). The patient was also diagnosed with anemia caused by hemorrhagic ascites without extravasation on CT angiography and hepatic failure, which was treated using platelets, coagulants, and diuretics. Finally, the symptoms of HE were well controlled with the use of branched-chain amino acid preparations from the central venous port. The patient was discharged 97 days after PTO. During the follow-up period, which was 157 days, the symptoms of HE were also under control with conservative therapy alone.

Discussion

In various cases of HE, symptoms are controlled by conservative therapy. However, even if the state of consciousness is temporarily improved by conservative therapy, it is not uncommon for shunt blood flow to increase excessively, resulting in persistent hyperammonemia causing a change in mental status [1]. Therefore, in cases where it is difficult to perform

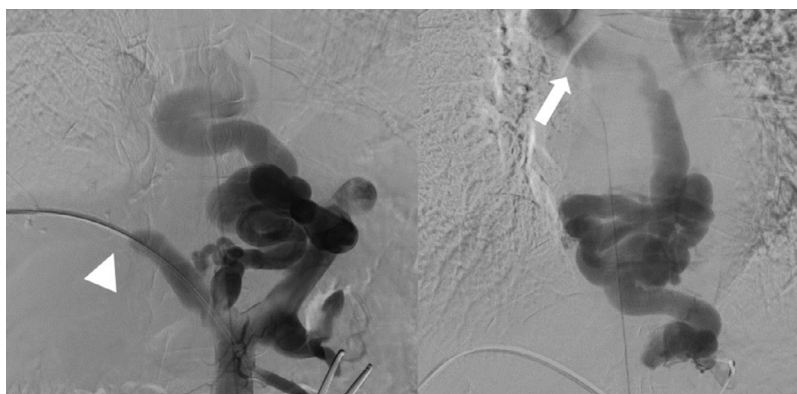


Fig. 1 – Preinterventional portal venography demonstrating a large portosystemic shunt from the left and right gastric veins to the azygos vein connecting to the superior vena cava (white arrow) and reflux portal vein flow due to portal hypertension (white arrow head).

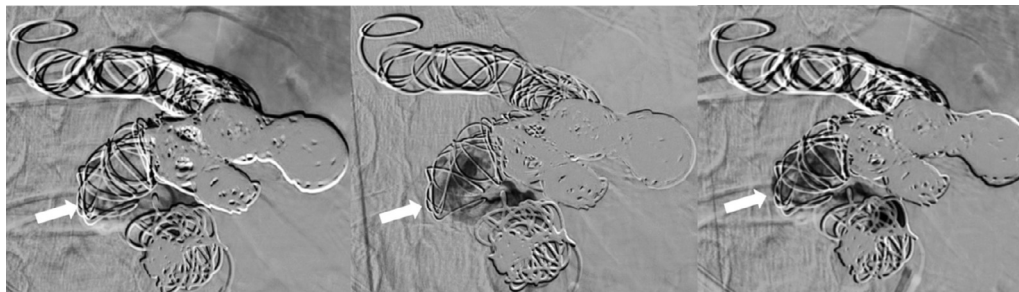


Fig. 2 – 1:2 n-butyl-2-cyanoacrylate (NBCA) surrounded by hydrogel-coated coils gradually spreading and adhering to the coils, avoiding non-target embolization (white arrow).

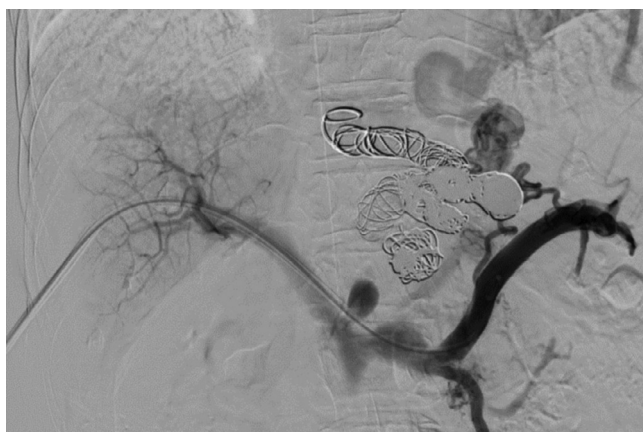

Fig. 3 – Postinterventional portal venography demonstrating a huge decrease in portosystemic shunt and normal portal vein re-flow.

an effective BRTO, PTO can be considered as a secondary treatment option for managing HE.

The findings of our study demonstrated that our new PTO method using an NBCA injection inside hydrogel-coated coils was adequate and effective for large portosystemic shunts associated with HE. Various types of embolic agents, such as bare coils, ethanol, ethanolamine oleate, and NBCA, are used in PTO [8]. Although liquid agents such as ethanol, ethanolamine oleate, and NBCA have high obstruction effect, embolization with a liquid agent alone is not suitable for large portosystemic shunts with high blood flow, given the risk of non-target embolization to other organs.

Ishikawa et al. utilized a hydrogel-coated coil to enhance the obstructive effect in a portosystemic shunt and demonstrated its superiority over embolization with bare coil alone in PTO and BRTO cases [3]. The advantage of a hydrogel-coated coil is that it can expand in volume, thus enhancing its obstruction effect [9,10]. In our case, we performed embolization of the target veins using hydro-coated coils under balloon occlusion and filled 1:1 or 1:2 NBCA inside the coils. This procedure could lead to more confirmed obstruction of a large portosystemic shunt without NBCA migration and reduce the

number of coils used. In addition, the hydrogel part of this coil may have a high affinity for NBCA.

A previous study has also reported improvement in hepatic function reserve after PTO in patients with HE and gastric varices with Child-Pugh scores of A, B, and C [11]. In contrast, hepatic failure developed in our patient leading to bleeding tendency and occlusion of the portosystemic shunt caused worsening of portal vein pressure, which resulted in hemorrhagic ascites that was treated with conservative therapy for approximately 3 months. These results might be owing to the use of a relatively large 8-Fr sheath to utilize a 20-mm balloon catheter and the lower hepatic function reserve before PTO.

In conclusion, PTO using NBCA injection inside hydrogel-coated coils for large portosystemic shunts associated with HE can be effective and safe and can reduce the number of coils used intraoperatively.

Ethical approval

All procedures performed in studies involving human participants were in accordance with the ethical standards of the institutional and/or national research committee and with the 1964 Helsinki declaration and its later amendments or comparable ethical standards. The Institutional Review Board approval was not required for the study because it was a case report.

Patient consent

Written informed consent was obtained from the patient for the publication of this report and any accompanying images.

REFERENCES

- [1] Rudler M, Weiss N, Bouzbib C, Thabut D. Diagnosis and management of hepatic encephalopathy. *Clin Liver Dis* 2021;25:393–417 [Epub 2021 March 11]. doi:10.1016/j.cld.2021.01.008.

- [2] Weissenborn K. Hepatic encephalopathy: definition, clinical grading and diagnostic principles. *Drugs* 2019;79(Suppl 1):5–9. doi:[10.1007/s40265-018-1018-z](https://doi.org/10.1007/s40265-018-1018-z).
- [3] Wright G, Jalan R. Management of hepatic encephalopathy in patients with cirrhosis. *Best Pract Res Clin Gastroenterol* 2007;21:95–110. doi:[10.1016/j.bpg.2006.07.009](https://doi.org/10.1016/j.bpg.2006.07.009).
- [4] Mukund A, Chalamarla LK, Singla N, Shashtry SM, Sarin SK. Intractable hepatic encephalopathy in cirrhotic patients: mid-term efficacy of balloon-occluded retrograde portosystemic shunt obliteration. *Eur Radiol* 2020;30(6):3462–72. doi:[10.1007/s00330-019-06644-4](https://doi.org/10.1007/s00330-019-06644-4).
- [5] Ishikawa T, Imai M, Endo S, Azumi M, Nozawa Y, Iwanaga A, et al. Effectiveness of different coils for endovascular coiling for intractable hepatic encephalopathy caused by a portosystemic shunt. *Ann Palliat Med* 2022;11:1954–60 [Epub 2022 January 14]. doi:[10.21037/apm-21-2594](https://doi.org/10.21037/apm-21-2594).
- [6] Child CG, Turcotte JG. Surgery and portal hypertension. *Major Probl Clin Surg* 1964;1:1–85.
- [7] Córdoba J. New assessment of hepatic encephalopathy. *J Hepatol* 2011;54:1030–40. doi:[10.1016/j.jhep.2010.11.015](https://doi.org/10.1016/j.jhep.2010.11.015).
- [8] Hirose S, Hasegawa N, Mori K, Endo M, Terasaki M, Ishige K, et al. Percutaneous transhepatic obliteration-related procedures for isolated gastric varices: Experience of three cases. *Clin J Gastroenterol* 2022;15:192–8. doi:[10.1007/s12328-021-01548-7](https://doi.org/10.1007/s12328-021-01548-7).
- [9] Baba K, Kondo M, Eitoku T, Shigemitsu Y, Hirai K, Otsuki S, et al. Vascular occlusion with 0.035-inch hydrogel expandable coils in congenital heart diseases and vascular anomalies. *J Cardiol* 2022;80:249–54 [Epub 2022 May 11]. doi:[10.1016/j.jjcc.2022.04.005](https://doi.org/10.1016/j.jjcc.2022.04.005).
- [10] Shimohira M, Kawai T, Hashizume T, Muto M, Kitase M, Shibamoto Y. Usefulness of hydrogel-coated coils in embolization of pulmonary arteriovenous malformations. *Cardiovasc Intervent Radiol* 2018;41:848–55. doi:[10.1007/s00270-018-1876-5](https://doi.org/10.1007/s00270-018-1876-5).
- [11] Ishikawa T, Imai M, Ko M, Sato H, Nozawa Y, Sano T, et al. Percutaneous transhepatic obliteration and percutaneous transhepatic sclerotherapy for intractable hepatic encephalopathy and gastric varices improves the hepatic function reserve. *Biomed Rep* 2017;6:99–102. doi:[10.3892/br.2016.811](https://doi.org/10.3892/br.2016.811).