

Available online at www.sciencedirect.com

ScienceDirect

journal homepage: www.elsevier.com/locate/radcr

Case Report

Spontaneous external jugular vein pseudoaneurysm: A rare cause of neck swelling[☆]

Badr Boutakioute, PhD^{a,*}, Meriam Benzalim, PhD^b, Anass Chehboun, MD^a,
Meriem Ouali, PhD^a, Najat Cherif Idrissi El Ganouni, PhD^a

^a Department of Radiology, Ar-Razi Hospital, Med VI University Hospital Center, Marrakech 40000, Morocco

^b Department of Radiology, Ibn Tofail Hospital, Med VI University Hospital Center, Marrakech 40000, Morocco

ARTICLE INFO

Article history:

Received 24 August 2022

Revised 31 August 2022

Accepted 7 September 2022

Available online 6 October 2022

Keywords:

External jugular vein

Pseudoaneurysm

Ultrasound sonography

CT angiography

ABSTRACT

Pseudoaneurysm of the external jugular vein is a relatively unusual cause of a neck mass caused by the low pressure venous system. Regardless of etiology, spontaneous pseudoaneurysms are extremely rare, and only few cases have been described in literature. They require surgery; however, most patients can be safely discharged with close follow-up with a vascular surgeon. This case demonstrates a 30-year-old man who presented with a non-tender, compressible, left-sided neck mass that enlarged with Valsalva, and intermittent paresthesias. Ultrasound confirmed a cystic mass of unknown etiology containing doppler flow suggesting the diagnosis of an external jugular vein pseudoaneurysm, confirmed by a CT angiography. The patient refused the surgery, and we agreed he was safe for discharge at that time and could follow up with vascular surgery as an outpatient.

© 2022 The Authors. Published by Elsevier Inc. on behalf of University of Washington.

This is an open access article under the CC BY-NC-ND license

(<http://creativecommons.org/licenses/by-nc-nd/4.0/>)

Introduction

Most aneurysms and pseudoaneurysms are located in arteries [1–3]. Due to the low blood pressure, real or false venous aneurysms are uncommon and typically iatrogenic [2–5]. As a result, 77% of venous aneurysms are found in the lower extremities [6].

In the internal jugular vein (IJV), aneurysms typically occur after interventional procedures [7,8]. Furthermore, external jugular vein pseudoaneurysms are even less com-

mon than internal jugular vein aneurysms, and only few isolated cases of spontaneous external jugular vein (EJV) pseudoaneurysm have been reported, making them an extremely rare entity [3,6,7]. An aneurysm is defined as a dilatation of all three layers of the vascular wall. The pseudoaneurysm is a tear through the outer layers of venous wall, the tunica adventitia and tunica media, with collection of blood and thrombus in the wall showed at histology [6,9,10].

Here, we describe and discuss the case of a spontaneous pseudoaneurysm of the right EJV in light of the literature.

[☆] Competing Interests: We wish to confirm that there are no known conflicts of interest associated with this publication and there has been no significant financial support for this work that could have influenced its outcome.

* Corresponding author.

E-mail address: badroutakioute@gmail.com (B. Boutakioute).

<https://doi.org/10.1016/j.radcr.2022.09.017>

1930-0433/© 2022 The Authors. Published by Elsevier Inc. on behalf of University of Washington. This is an open access article under the CC BY-NC-ND license (<http://creativecommons.org/licenses/by-nc-nd/4.0/>)

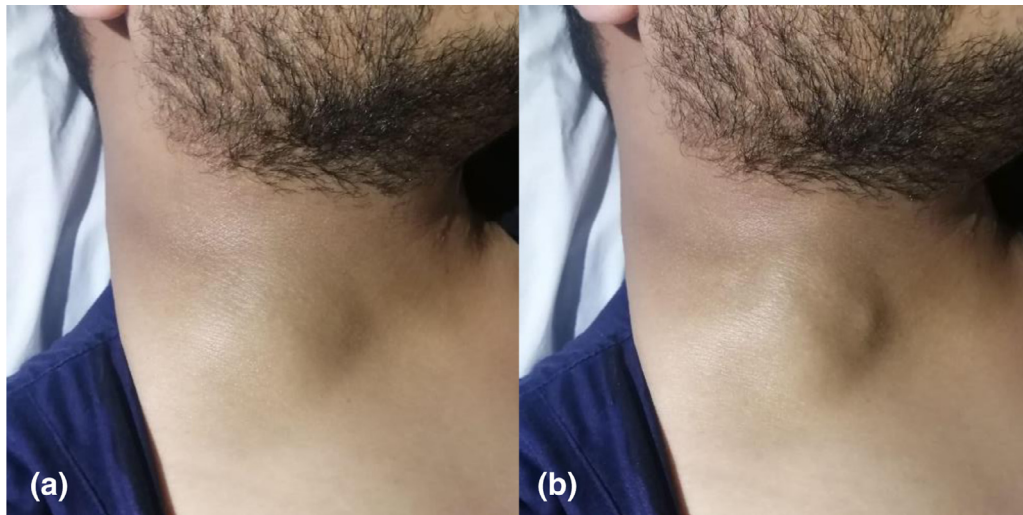

Fig. 1 – Four-centimeter right external jugular pseudoaneurysm as seen on physical exam before (a) and after Valsalva (b).

Case report

A healthy 30-year-old male presented to the emergency department complaining of a superficial mass in the right cervical region. He noticed that the mass present suddenly about 4 months prior to presentation which increased in size progressively. He had no history of trauma, surgery or neck manipulation; and no known personal or family history of connective tissue disease. The mass was painless and enlarged during Valsalva maneuvers.

On physical exam, he had a 4-centimeter (cm) soft, compressible, non-pulsatile mass that enlarged with Valsalva along the antero-lateral right cervical region (Fig. 1). The mass was soft and mobile. It did not move or change in size with respirations or swallowing.

We noted neither ecchymosis, nor skin discoloration, inflammation or surrounding lymphadenopathy. The patient's upper-extremity arterial pulsations were normal.

All of her laboratory findings were normal.

Ultrasonography revealed a compressible hypoechoic structure, 4.3 cm of great diameter, lying in the subcutaneous tissues between the platysma muscle and cervical fascia. It was connected to the EJV. Color Doppler ultrasonography (CDU) revealed an internal flow, with revealed alternatively positive and negative waveforms indicative of typical pseudoaneurysmal to-and-fro flow on spectral examination (Fig. 2).

Computed tomography (CT) of the neck with contrast showed a 1.7 cm x 1.4 cm x 2 cm pseudoaneurysm of the left external jugular vein (Fig. 3). The case was discussed with the vascular surgeon on call. The patient had no signs that the pseudoaneurysm was expanding, causing airway compromise, had active extravasation, or was causing emergent neurological involvement at that time. We suggested surgery, but the patient declined. Thus, we lacked histology information but had strong suspicions about a pseudoaneurysm based on the imaging characteristics. We agreed he was safe for dis-

charge at that time and could follow up with vascular surgery as an outpatient.

Discussion

The EJV is anatomically formed by the retromandibular vein and the posterior auricular vein. It passes under the sternocleidomastoid to eventually join the subclavian vein. Clinically, the superficial anatomic location of the external jugular vein predisposes it to traumatic and iatrogenic injury especially after use by central venous catheters. This is a major example of trauma to this low-pressure system leading to formation of EJV aneurysm [3].

The most typical presentation for aneurysm and pseudoaneurysm is a palpable, pulsatile mass that expands with Valsalva [1,10]. Pain, dysphagia, hoarseness, and neurological anomalies are some of the other symptoms. [1,4].

Doppler ultrasonography is a non-invasive imaging tool, and the first recommended exam in order to distinguish vascular from non-vascular causes. [7,11]. Ultrasound can show turbulent flow and dilation with 95% accuracy for pseudoaneurysm [1]. Grayscale depicts an anechoic structure and CDU reveals internal flow with the typical “yin-yang” appearance. Doppler waveforms typically demonstrate a to-and-fro flow in the pseudoaneurysm neck [12].

CT angiography, magnetic resonance imaging, and magnetic resonance venography are second-line modalities, can more accurately demonstrate size, extent, and connection to adjacent structures [4,5,7,11,13]. Additionally, CT with intravenous contrast may be a suitable imaging modality in cases where ultrasound or clinical uncertainty requires a CT without angiography.

Venous aneurysms are classified as primary (congenital) and secondary (acquired) [2,7,10]. Causes of primary venous aneurysms are not fully understood [9,14], while possible etiologies for secondary aneurysms within the venous sys-

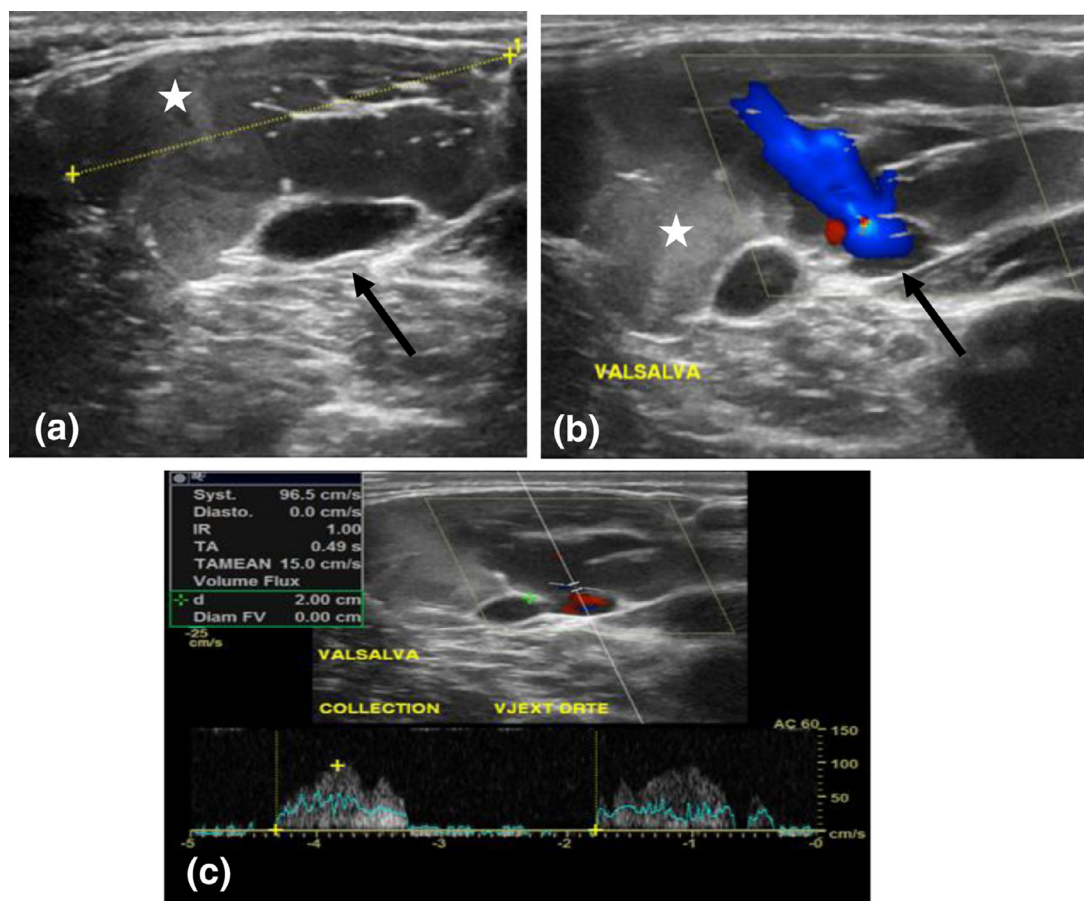


Fig. 2 – Color Doppler ultrasonography (a,b) reveals a wide-necked pseudoaneurysm of the right external jugular vein (Black arrow). The pseudoaneurysm sac is partially thrombosed (White star). Pulsed Doppler examination (c) of the neck of the pseudoaneurysm shows a typical to-and-fro waveform.

tem include thoracic outlet obstruction, trauma, chronic inflammation, degeneration, and increased venous pressure [2,7,11,15,16]. Highest significant risk factors for secondary venous aneurysms include recent trauma, cardiovascular disease, and age [3].

Venous aneurysms and pseudoaneurysms are a rare cause of neck masses [15,17]. The differential diagnosis includes lymphocele, cavernous hemangioma, hygroma, abscess, cyst, laryngocele, lymph node, tumor, thyroglossal cyst, and branchial cleft cyst [7,15]. Enlargement of the mass with valsalva or excursion is suspicious for laryngocele, aneurysm, or pseudoaneurysm [5,9].

Our patient had no past medical history and no evidence of trauma. And we postulate that, despite their exceptional rarity, spontaneous EJV aneurysms should be included as a differential diagnosis of the patients who are presenting with a painless, cystic mass of the lateral neck that has ultrasound findings of doppler flow.

Complications of jugular venous aneurysms and pseudoaneurysms are very rare, may include pulmonary embolism, thrombus formation or thrombophlebitis, rupture or compression of adjacent structures; and they are

more likely if the patient complains of pain or tenderness. [4,5,7,10,13]. At the time of this publication there were no reports in the literature of any of the above-mentioned complications from external jugular vein pseudoaneurysm. These complications are mostly seen in the lower extremities from popliteal and femoral aneurysms [6,10,16].

Venous aneurysms of the neck are often asymptomatic requiring no intervention and can be monitored [1,2,7]. Approximately 89% of iatrogenic pseudoaneurysms will heal spontaneously without intervention. Surgical is recommended to manage large aneurysms compressing nearby structures, potential for thrombus, cosmetic reasons, or presence of symptoms. [6,10].

Another alternative treatment is the use of the Ultrasound-guided compression of the pseudoaneurysm neck that will stop the blood flow, resulting in thrombosis within 40-45 minutes. For many years, ultrasound-guided compression of iatrogenic pseudoaneurysm was the principal alternative treatment method to surgery. However, percutaneous thrombin injection was described in 1997 [18], and soon became accepted as the standard treatment for femoral artery pseudoaneurysms [19].

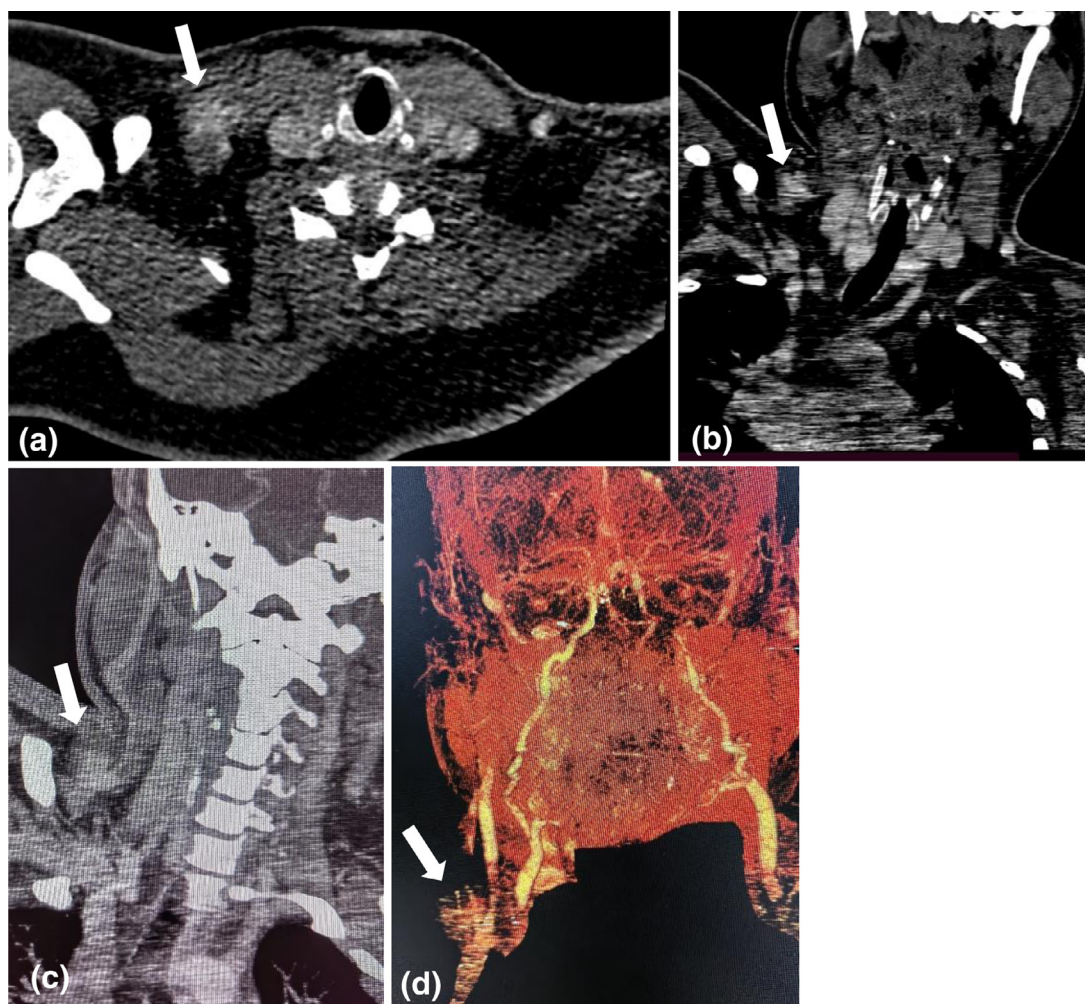


Fig. 3 – Computed tomography with contrast axial view (a), coronal (b), maximum intensity projection (MIP) reconstruction (c) and 3D reconstruction (d) of right external jugular venous pseudoaneurysm (White arrows).

Conclusion

Pseudoaneurysms of the external jugular vein are very uncommon entity with only few case reports published in the literature. This vascular anomaly is described as a pulseless mass that expands with valsalva and effort. In the asymptomatic patient, no complications have been described in the literature, and no intervention is recommended. Patients who are asymptomatic can be safely discharged with an outpatient referral to surgery for aesthetic excision.

Patient consent

We confirm that any aspect of the work covered in this manuscript that has involved human patients has been conducted with the ethical approval of all relevant bodies and that such approvals are acknowledged within the manuscript.

The consent to publish potentially identifying information, such as details or the case, was obtained from the patient.

REFERENCES

- [1] Abdel-Aty Y, Bellew M. Endovascular management of a refractory pseudoaneurysm of the sternocleidomastoid artery caused by attempted internal jugular central line placement with long term follow-up: a case report and review. *Case Rep Otolaryngol* 2018;2018:8324908.
- [2] Basbug HS, Bitargil M, Karakurt A, Özışık K. External jugular vein aneurysm in a young woman: An uncommon cause of neck mass. *Int J Cardiovasc Acad* 2016;2(1):16–18.
- [3] Chapman DR, Ho RE, Gangemi A. A case report of a rare, spontaneous external jugular vein aneurysm. *Int J Surg Case Rep* 2018;52:8–10.
- [4] Karapolat S, Erkut B, Unlu Y. Multiple aneurysms of the left external jugular vein. *Turk J Med Sci* 2005;35:43–5.
- [5] Kirmani S, Rashid M, Ali I, Badar F. External jugular vein aneurysm: a rare cause of neck swelling. *J Ultrasound Med* 2011;30(8):1156–66.
- [6] Lee HY, Lee W, Cho YK, Chung JW, Park JH. Superficial venous aneurysm. Reports of 3 cases and literature review. *J Ultrasound Med* 2006;25(6):771–6.
- [7] Grigorescu I, Dumitrascu DL, Manole S, Fodor D. Pseudoaneurysm of the external jugular vein

- communicating with the internal jugular vein. case report. *Med Ultrason* 2012;14(3):257–60.
- [8] Azghari A, Belmir H, Kharroubi A, Khaloufi SE, Idrissi RE, Lekehel B, et al. External jugular vein aneurysm: a rare cause of neck swelling. A report of three patients. *J Mal Vasc* 2011;36:395–8.
- [9] Ekim H, Ozen S. Primary venous aneurysm of the external jugular vein. *East J Med* 2002;7(1):24–5.
- [10] McCready RA, Bryant MA, Divelbiss JL, Chess BA. Subclavian venous aneurysm: case report and review of the literature. *J Vasc Surg* 2007;45(5):1080–2.
- [11] Mohanty D, Jain BK, Garg PK, Kim HS, Kim JJ, Park SD. External jugular vein aneurysm: case report. *J Nat Sci Biol Med* 2013;4(1):223–5.
- [12] Mahmoud MZ, Al-Saadi M, Abuderman A, Alzimami K, Alkhorayef M, Almagli B. To-and-fro” waveform in the diagnosis of arterial pseudoaneurysms. *World J Radiol* 2015;7:89–99.
- [13] Shah NM, Shah VS, Dalai PR, Mishra P. A pseudoaneurysm of the external jugular vein – a case report. *BMJ* 2015;7(2):52–4.
- [14] Swaika S, Basu S, Bhadra RC, Maitra S. Multiple venous aneurysms of neck. *J Indian Assoc Pediatr Surg* 2013;18(1):25–6.
- [15] Drakonaki EE, Symvoulakis EK, Fachouridi A, Kounalakis D, Tsafantakis E. External jugular vein aneurysm presenting as a cervical mass. *Int J Otolaryngol* 2011;2011:485293.
- [16] Regina G, Cardia G, Squeo MA, Lillo A, Latorre M, Odero A. Aneurysm of the internal jugular vein—a case report. *Vasc Surg* 1988;22(3):169–71.
- [17] Lucatelli P, Tommasino G, Guaccio G, Benvenuti A, Ricci C. External jugular vein spontaneous aneurysm, diagnosis, and treatment with video. *Ann Vasc Surg* 2017;41:282.e11–282.e13.
- [18] Liau CS, Ho FM, Chen MF, Lee YT. Treatment of iatrogenic femoral artery pseudoaneurysm with percutaneous thrombin injection. *J Vasc Surg* 1997;26:18–23.
- [19] Moller SM, Logason K, Karason S, Thorisson HM. Percutaneous thrombin injection of common carotid artery pseudoaneurysm without cerebral protection. *Texas Hear Inst J* 2012;39:696.