

Available online at www.sciencedirect.com

ScienceDirect

journal homepage: www.elsevier.com/locate/radcr

Case Report

Cavernous hemangioma of the orbit: Case report and a review of the literature [☆]

Ettabyaoui Ayoub, MD^{a,c,*}, Aassouani Farid, MD^a, Charifi Yahya, MD^a,
El Bouardi Nizar, PhD^a, Haloua Meryem, PhD^b, Lamrani Alaoui My Youssef, PhD^a,
Boubbou Meriem, PhD^b, Mustapha Maâroufi, PhD^a, Alami Badreiddine, PhD^a

^a Department of Radiology and Interventional Imaging, CHU Hassan II, FEZ, Sidi Mohammed Ben Abdellah University, Fes, Morocco

^b Department of Radiology Mother and Child and Interventional Imaging, CHU Hassan II, FEZ, Sidi Mohammed Ben Abdellah University, Fes, Morocco

^c Department of Radiology and Clinical Imaging, Faculty of Medicine and Pharmacy, University of Fez, BP. 1893; Km 2.200, Sidi Hrazem Road, Fes 30000, Morocco

ARTICLE INFO

Article history:

Received 20 July 2022

Revised 25 July 2022

Accepted 28 July 2022

Available online 27 August 2022

Keywords:

Cavernous hemangioma

Benign tumors

CT

Surgical approach

Orbitotomy

ABSTRACT

Intraorbital cavernous hemangiomas are the most common benign vascular tumors of the orbit in adults. The clinical presentation consists of a slowly progressive intraorbital mass syndrome, often causing late exophthalmos of varying grades. It may be accompanied by reduced visual acuity or ocular motility disorder. CT and MRI scans allow a precise diagnosis to be made in the vast majority of cases, while pathology confirms the diagnosis. Treatment is not always indicated, and when it is, it is exclusively surgical. The vital and functional prognosis is generally good, and the recurrence is almost exceptional. We report the case of a 49-year-old patient who presented with a decrease in visual acuity of his right eye caused by cavernous hemangioma of the orbit.

© 2022 Published by Elsevier Inc. on behalf of University of Washington.

This is an open access article under the CC BY-NC-ND license

(<http://creativecommons.org/licenses/by-nc-nd/4.0/>)

Introduction

Cavernous hemangioma of the orbit (CHO) is a rare vascular tumor, representing between 4.5% and 7.4% of all primary and secondary orbital tumors. Nevertheless, they are among the most frequent benign tumors of the orbit with a female predilection. The average age of onset of symptoms is between the fourth and fifth decade of life.

Histopathologic and imaging studies, especially magnetic resonance imaging (MRI), have recently given more insight into its pathogenesis and natural history. A proper diagnosis is crucial to selecting the best therapeutic approach. Treatment options have progressively modified to include less-invasive treatments, ranging from surgical to nonsurgical options.

CHO is a slow-growing tumor that has a lasting effect on visual function and ocular motility. These factors give this type of tumor a good vital and functional prognosis, despite

[☆] Competing Interests: All authors declare no conflict of interest.

* Corresponding author.

E-mail address: ettabyaoui@gmail.com (E. Ayoub).

<https://doi.org/10.1016/j.radcr.2022.07.101>

1930-0433/© 2022 Published by Elsevier Inc. on behalf of University of Washington. This is an open access article under the CC BY-NC-ND license (<http://creativecommons.org/licenses/by-nc-nd/4.0/>)

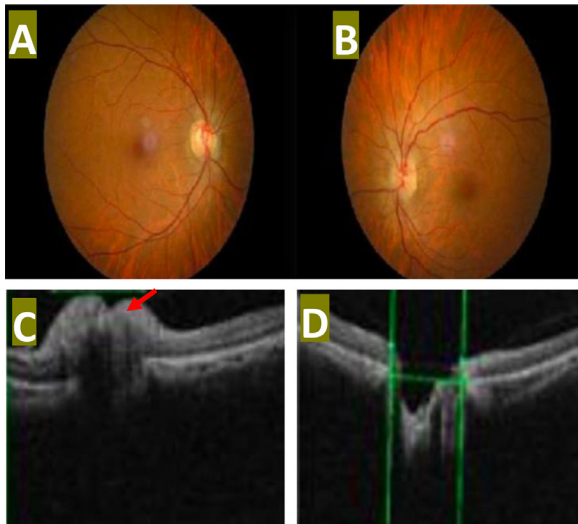


Fig. 1 – Retinography which shows in the right eye a loss of the excavation with blurring of the papillary edges and a venous tortuosity indicating a papillary edema (A), in contrast to the left eye (B). Optical coherence tomography (OCT) of the optic nerve head which shows a thickening at the level of the right optical fiber layer (C): red arrow, in contrast to the normal left eye (D).

its generally intraconical retrobulbar location. The aim of this case report is to review the clinical and para-clinical aspects of CHO in order to facilitate diagnosis, and also to define the place of the different surgical approaches to the orbit, and more specifically the external approach.

Case presentation

A 49-year-old man, without medical or surgical history, presented 6 months before his admission with a progressive decrease in visual acuity of the right eye with retro-orbital pain on the same side.

The best-corrected visual acuity (BCVA) was 8/10 in the right eye with the refraction of (+0.50) and 10/10 in the right eye with the refraction of (+0.75); ocular motility was preserved; the direct and consensual photo-motor reflex was preserved, and the fundus examination showed stage I papillary edema in the right eye.

We completed retinography and optical coherence tomography of the head of the optic nerve, which confirmed the diagnosis of papillary edema (Fig. 1). The rest of the ophthalmologic examination was unremarkable with no inflammatory signs, no exophthalmos, and ocular auscultation was without abnormality.

Orbital CT scan revealed an extra-conical tissue-like process of the right orbit in close contact with the lateral rectus muscle, and the eyeball taking heterogeneous contrast (Fig. 2). The patient underwent a complete resection of his tumor proceeding with a lateral approach to the orbit. The immediate postoperative course was simple, with the occurrence of eye-

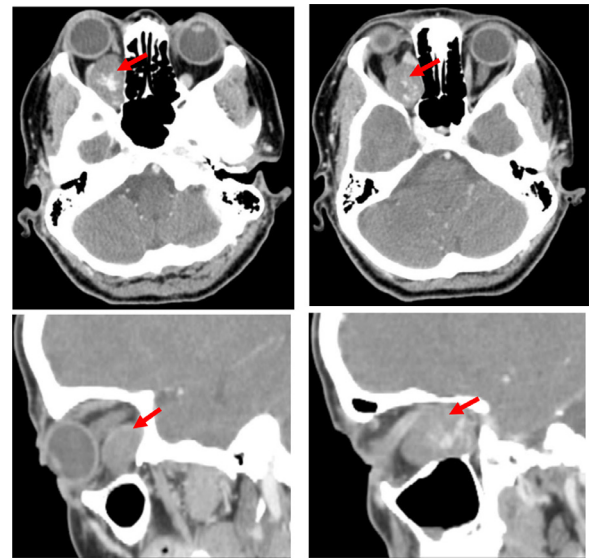


Fig. 2 – CT scan of the orbit showing a well-circumscribed right intraconical tissue process posterointernal in location (red arrow), with an intense enhancement and pushing back the optic nerve causing stage 2 exophthalmos.

lid ecchymosis and right chemosis completely regressing in a few days. Furthermore, the patient did not have postoperative ptosis, nerve damage, or other complications.

Discussion

CHO is the most common benign orbital lesion of adults and the third most common diagnosis after lymphoid tumors and inflammatory orbital syndrome. It is usually a solitary, unilateral condition, with preferential involvement of the left orbit according to the most extensive published series, although multiple and bilateral occurrences are described [1]. Although CHO is reported in infants with diffuse neonatal hemangiomatosis, lesions generally remain asymptomatic until adulthood, with the fourth and the fifth being the most affected decades [2]. About 60% of cases occur in women, and recent evidence seems to suggest there may be an influence of female sex hormones on the clinical course of CHO [3].

“Cavernous hemangioma” is the most common terminology used in the literature to refer to this orbital condition. Several studies have demonstrated that CHO should be more correctly defined as a venous malformation than as a neoplasm. For this reason, according to the International Society for the Study of Vascular Anomalies, CHO should be classified among low-flow non-distensible venous malformations. It consists of thrombosed and septated venous convolution, covered by a compact and strong fibrous capsule [4].

The preferential anatomic location of CHO is the middle third of the orbit, occurring more frequently within the intraconal space and leading to progressive axial proptosis, which is the most common sign and symptom of CHO (accounting for about 70% of cases) [5]. Exophthalmos is often progres-

sive, may or may not be axile depending on the anatomical location, non-pulsatile, and painless, except in the event of a complication (inflammatory, hemorrhagic, or thrombotic). The mode of discovery is sometimes fortuitous. Intra-conical tumors compress the posterior surface of the globe and lead to hyperopia. Compression of the optic nerve is exceptional, leading to a decrease in visual acuity with choroidal folds in the fundus, or even papillary edema like our patient.

Imaging contributes greatly to the diagnosis. On ultrasound, the cavernous hemangioma is visible as a homogeneous, hyper-echogenic, and well-defined mass. It shows large vascular spaces containing a low flow well evidenced by the color Doppler ultrasound. On computed tomography, the lesion is well defined, encapsulated, and hyperdense, increasing slightly after injection but less than the adjacent muscles. Magnetic resonance imaging should assess the possible compressive impact, especially on the optic nerve. The lesion is oval and well-defined. A typical CHO appears as a well-defined homogeneous mass showing isointensity or slight hypointensity in T1-weighted sequences and hyperintensity to muscles in T2-weighted sequences, which is strongly suggestive of the diagnosis. Contrast enhancement is also characteristic, and it is heterogeneous at the start and then becomes homogeneous over time (5 minutes at the latest) [6].

The incidental diagnosis of an orbital cavernoma does not necessarily mandate its removal. Surgical treatment is indicated only in symptomatic patients. The location of the cavernoma determines the choice of the surgical approach. While it is a common opinion that lesions located in the orbital apex have to be approached by a transcranial route, there is a debate in the literature about the best approach for tumors located anteriorly to the orbital apex. Generally, ophthalmic surgeons are more confident with the transconjunctival approach, which is considered the optimal and less invasive approach for lesions located anteriorly to the posterior edge of the ocular globe [7]. Some authors affirm that the transconjunctival approach is suitable for retrobulbar intraconal cavernomas if the anterior part of the tumor is found just behind the globe. In their opinion, the advantages of this approach over other techniques include no bone removal, no cutaneous incisions, shorter operation time, and lesser trauma to orbital structures [7].

Nevertheless, the basic approach for retrobulbar tumors located in the lateral aspect of the orbit is usually considered the lateral orbitotomy. The lateral approach was first described by Kroenlein, then modified by Berke [8]. Lesions located in the superomedial aspect of the orbit are usually approached by a transcranial route. Several microsurgical or endoscopic approaches have been reported in the literature to approach lesions located in the inferomedial aspects of the orbit [9]. In our case, the tumor was left infraorbital intraconal, located in retrobulbar space. The surgical approach that has been performed was a lateral orbitotomy without removal of the lateral orbital rim.

The most serious complication of orbital cavernomas surgery is blindness due to damage to the optic nerve. It can be related to direct damage, traction of the nerve, or a lesion of its vascular supply. The optic nerve decompression, particularly for tumors located in the orbital apex and with a tight relationship with the optic nerve, is useful to reduce the intraoperative

traction of the nerve during tumor dissection. The outcome in ocular motility depends on the accuracy of the tumor dissection and the total removal of the tumor. Palpebral ptosis and ocular movement impairment can result from overstretching or contusion of the extraocular muscles during tumor dissection [10].

In general, the potential factor that resulted in postoperative visual impairment was the difficulty of the tumor removal, adhesion to the optic nerve, periosteum, or the muscles. The tumor located at the apex or medial of the optic nerve was very likely to be difficult to remove, and consequently would be followed by postoperative visual impairment [10].

Conclusion

CHO is a common finding in adult patients with slow developing proptosis and other signs of an orbital mass. The correct diagnosis is made in most cases thanks to imaging techniques such as US, CT, and magnetic resonance imaging. Treatment is not always required but is usually indicated in the presence of clinical manifestations. Surgery is still the most used treatment for this condition. The availability of new endoscopic surgical approaches to the orbit could represent a valid alternative option for managing patients with CHO.

Patient consent

I, the author of the article, "Cavernous hemangioma of the orbit: Case report and a review of the literature," approve that the patient gives her consent for information to be published in *Radiology Case Reports*.

REFERENCES

- [1] Shields JA, Shields CL, Scartozzi R. Survey of 1264 Patients with orbital tumors and simulating lesions. The 2002 Montgomery Lecture, part 1. *Ophthalmology* 2004;111:997e1008.
- [2] Yan J, Wu Z. Cavernous hemangioma of the orbit: analysis of 214 cases. *Orbit* 2004;23:33e40.
- [3] Jayaram A, Lissner GS, Cohen LM, Karagianis AG. Potential correlation between menopausal status and the clinical course of orbital cavernous hemangiomas. *Ophthalmol Plast Reconstr Surg* 2015;31(3):187e90.
- [4] Rootman J, Heran MK, Graeb DA. Vascular malformations of the orbit: classification and the role of imaging in diagnosis and treatment strategies. *Ophthalmol Plast Reconstr Surg* 2014;30(2):91e104.
- [5] McNab AA, Selva D, Hardy TG, O'donnell B, et al. The anatomical location and laterality of orbital cavernous haemangiomas. *Orbit* 2014;33(5):359e62.
- [6] Dallaudiere B, Benayoun Y, Boncoeur-Martel M, Robert PY, Adenis JP, Maubon A, et al. Imaging features of cavernous hemangiomas of the orbit. *J Radiol* 2009;90(9):1039e45.
- [7] Kiratli H, Bulur B, Bilgiç S. Transconjunctival approach for retrobulbar intraconal orbital cavernous hemangiomas. Orbital surgeon's perspective. *Surg Neurol* 2005;64(1):71–4.

-
- [8] Scheuerle AF, Steiner HH, Kolling G, Kunze S, Aschoff A. Treatment and long-term outcome of patients with orbital cavernomas. *Am J Ophthalmol* 2004;138(2):237–44.
 - [9] Stamm A, Nogueira JF. Orbital cavernous hemangioma: transnasal endoscopic management. *Otolaryngol Head Neck Surg* 2009;141(6):794–5.
 - [10] Missori P, Tarantino R, Delfini R, Lunardi P, Cantore G. Surgical management of orbital cavernous angiomas: prognosis for visual function after removal. *Neurosurgery* 1994;35(1):34–8.