

Available online at [www.sciencedirect.com](http://www.sciencedirect.com)

ScienceDirect

journal homepage: [www.elsevier.com/locate/radcr](http://www.elsevier.com/locate/radcr)

## Case Report

# Transient portal venous gas in upper gastrointestinal bleeding: A case report <sup>☆</sup>

Sepideh Pourhajihosseini, MD

Department of Diagnostic Imaging, Gødstrup Hospital, Hospitalsparken 15, 7400 Herning, Jutland, Denmark

## ARTICLE INFO

## Article history:

Received 3 August 2022

Revised 11 August 2022

Accepted 14 August 2022

Available online 11 September 2022

## Keywords:

HPVG, hepatic portal venous gas

PVG, portal venous gas

CT, computed tomography

UGB, upper gastrointestinal bleeding

IBD, inflammatory bowel disease

## ABSTRACT

Portal venous gas (PVG) or hepatic portal venous gas (HPVG) is the accumulation of gas in the portal vein and its branches. HPVG may be considered as a nonspecific sign of a significant abdominal disease, ranging from potentially lethal diseases to benign conditions. Computed tomography (CT) can detect both the presence of gas and the underlying pathology. I report a 60-year-old male who presented to the emergency department with upper gastrointestinal bleeding and a high lactate level in the blood test. Because of the unknown etiology for the elevated lactate, a CT scan of the abdomen was taken, which showed that he developed intra- and extra-hepatic portal venous gas as well as in the portomesenteric-portosystemic collaterals without any signs of mesenteric ischemia. The patient was treated conservatively and the HPVG completely resolved after a few days. Overall, physicians must be aware that prognosis is related to the pathology itself and is not influenced by the presence of PVG. HPVG can be caused by several benign conditions that do not necessarily require urgent exploratory laparotomy.

© 2022 The Authors. Published by Elsevier Inc. on behalf of University of Washington.

This is an open access article under the CC BY-NC-ND license

(<http://creativecommons.org/licenses/by-nc-nd/4.0/>)

## Introduction

HPVG itself is not a surgical indication and the treatment depends mainly on the underlying disease [1]. Previously, HPVG has been most associated with an acute gastrointestinal catastrophe such as mesenteric ischemia with a high mortality rate. Presently, by the extensive use of advanced diagnostic imaging, HPVG has also been an incidental finding in many benign and non-life-threatening causes; therefore, HPVG cannot on its own be used as a prognostic indicator [2]. Plain radiography, computed tomography (CT) and ultrasound can demonstrate HPVG. Among these imaging modalities, CT is the most sensitive and specific for detecting HPVG and demonstrating

associated intra-abdominal disorders and coexisting abnormal air [3].

Cases in which HPVG is found without mesenteric ischemia can also get benefits from conservative treatment [2,4–6].

## Clinical case and imaging findings

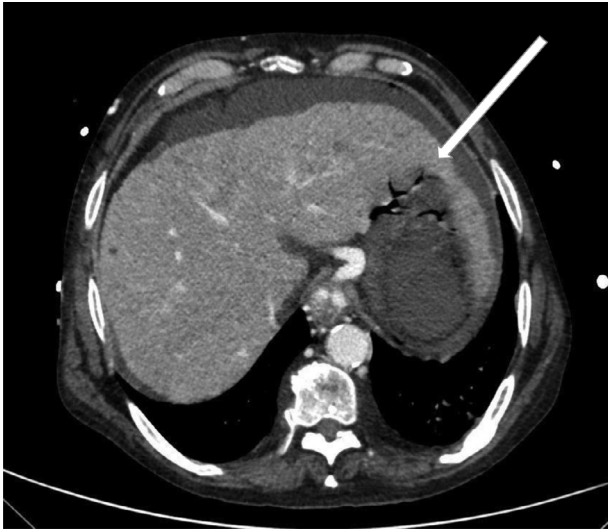A 60-year-old male patient known for alcoholic liver cirrhosis whom diagnosed with esophageal varices and partial thrombus in the portal vein in the former CT scan, was brought to the emergency department disoriented and delirious with the

<sup>☆</sup> Competing Interests: The authors declare that there is no conflict of interest.

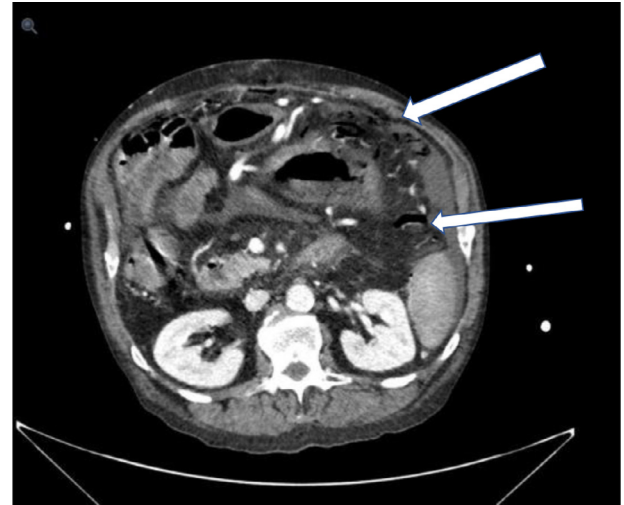
E-mail address: [sepide\\_pourhaji@yahoo.com](mailto:sepide_pourhaji@yahoo.com)

<https://doi.org/10.1016/j.radcr.2022.08.048>

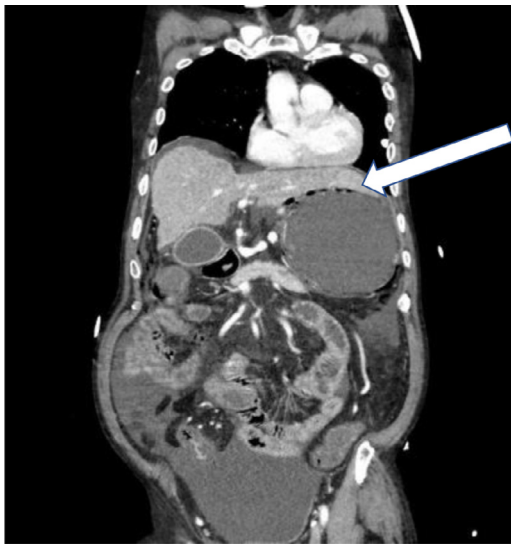1930-0433/© 2022 The Authors. Published by Elsevier Inc. on behalf of University of Washington. This is an open access article under the CC BY-NC-ND license (<http://creativecommons.org/licenses/by-nc-nd/4.0/>)



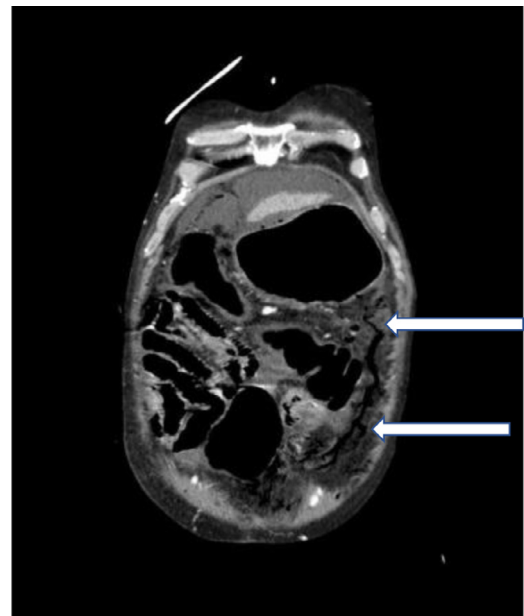
**Fig. 1 – Axial view of contrast-enhanced CT image of the upper abdomen shows intrahepatic portal venous gas (arrow).**



**Fig. 3 – Contrast-enhanced CT images of abdomen show the portomesentric collaterals (arrow) axial view.**



**Fig. 2 – Coronal view of contrast-enhanced CT image of the upper abdomen shows intrahepatic portal venous gas (arrow).**



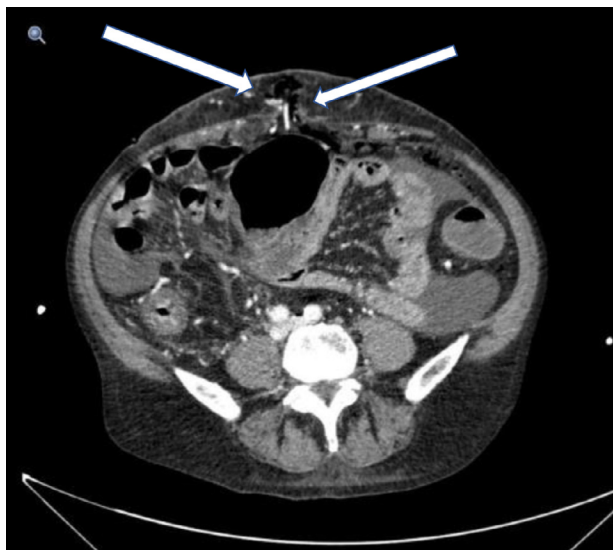
**Fig. 4 – Contrast-enhanced CT images of abdomen show the presence of gas in portomesentric collaterals (arrow) coronal view.**

presence of hematemesis. The patient was slightly hypotensive (blood pressure: 98/58 mmHg) and had a distended abdomen but did not present pain or signs of peritonitis. The blood test presented an elevated lactate [lactate:10,1 (reference interval:0,5-2,5)], which is why was suggested CT scan of the abdomen to rule out the mesenteric ischemia, despite absence of clinical suspicion.

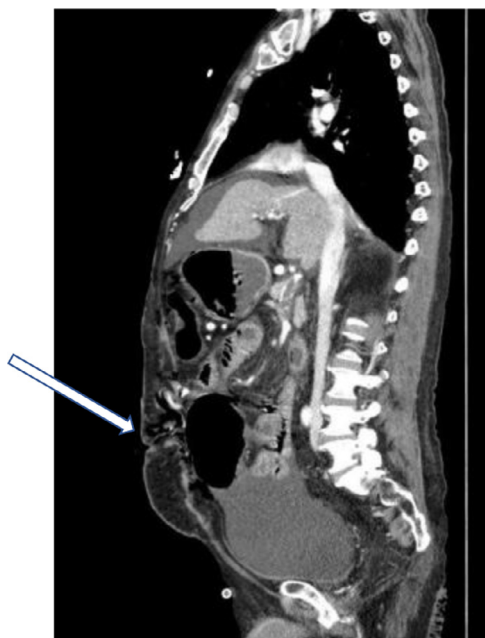CT scan showed ventricle retention, intra- and extra-hepatic portal venous gas (Figs. 1 and 2) as well as the esophageal varices and the portomesentric collaterals between bowel (Figs. 3 and 4) and cutaneous portosystemic collaterals (Figs. 5 and 6) without any bowel pneumatosis or free intraperitoneal air.

After a short time, the control blood test showed a normal lactate level; therefore, the patient treated conservative with intravenous fluids, blood transfusion and Terlipressin as well as decompression of the stomach through a nasogastric tube.

Gastroscopy showed large esophageal varices that were treated by elastic bandage and found portal hypertension gastropathy changes in the fundus of the stomach without any ulcers or signs for ischemia. The patient was stabilized and eventually discharged in a stable condition. After 3 days of his discharge, control CT scan showed total regression of air in the portal system.



**Fig. 5 – Contrast-enhanced CT images of abdomen show the presence of gas in portosystemic collaterals; Caput Medusae (arrow) axial view.**



**Fig. 6 – Contrast-enhanced CT images of abdomen show the presence of gas in portosystemic collaterals; Caput Medusae (arrow) sagittal view.**

## Discussion

Hepatic portal venous gas is a condition in which gas accumulates in the portal venous circulation. It may be associated with a wide range of conditions from lethal surgical pathologies to many benign etiologies which do not carry high mor-

talidity or morbidity risks [7]. HPVG was first described by Wolfe and Evens in 1955 associated in infants with necrotizing enterocolitis [8,9], it has since been described in numerous other clinical conditions including some severe etiologies such as mesenteric ischemia, intestinal obstruction, duodenal ulcer perforation, and necrotizing pancreatitis. However, currently, the increased use of more sensitive diagnostic imaging techniques (ultrasonography and CT) allows recognition of an increasing number of less morbid causes [7]; such as ileus, diverticulitis, enteritis, gastric distention, inflammatory bowel disease (IBD), sepsis, intra-abdominal abscess, hypotension post dialysis treatment, decompression sickness, abdominal trauma and iatrogenic causes from instrumentation and recent surgery [2] as well as some benign causes with unknown mechanisms include high-pressure ventilation, chronic obstructive pulmonary disorder (COPD), and high dose steroids [8].

The mechanism of the passage of the gas from the intestine into the mesenteric and then portal venous system is not fully understood. However, it is divided into 2 main pathophysiological theories. First, mechanical disruption may result in passage of the gas into the intestinal wall and eventually the portal system [7,8]. Alternatively, the invasion of the intestinal wall by gas forming bacteria may result in the production of gas within the intestinal wall and portal system. Both mechanisms probably play a role in the development and propagation of HPVG [2].

The diagnosis of HPVG is usually made by plain abdominal radiography, sonography, color Doppler flow imaging, or computed tomography (CT) scan. Although HPVG may be diagnosed by conventional radiography, detection is difficult and it can get easily overlooked.

Sonography coupled to Doppler is very sensitive for HPVG. However, its application is limited because of its high inter-operator variability and lack of availability [1]. The typical ultrasonographic features of HPVG are highly echogenic particles that flowing within the portal vein or the hepatic parenchyma, which are most apparent in the non-dependent part [10]. Color Doppler flow imaging shows hyperechogenic foci moving within the lumen of the portal vein, producing sharp bidirectional spikes superimposed on the normal monophasic portal vein wave pattern [1,8,10].

The CT scan has a high sensitivity for detection of HPVG and can detect the underlying pathology [1,3]. CT presents as branching lucencies in the liver, portal vein, and its tributaries. Typically, the gas in the liver extends to within 2 cm beneath the liver capsule. This peripheral gas distribution is related to the direction of blood flow into the liver. It is crucial to differentiate it from pneumobilia, which is centrally located because of the biliary anatomy and the direction of bile flow [1,8,11]. The presence of pneumatosis intestinalis is most highly associated with ischemia and necrotic bowel [2].

Recent studies show that the clinical status of the patient, including physical exam findings, vital signs, laboratory values, and comorbidities, rather than the CT findings alone, can better identify patients who would benefit from conservative treatment versus operative intervention, especially when the clinical status rapidly improves under medical therapy and with absence of surgical indication [2,4–6].

## Conclusion

Portal venous gas on CT is associated with various pathologies that do not necessarily ground surgical management. Clinical presentation should be correlated with the presence of HPVG and other associated CT findings to determine a wide range of benign etiologies that can be treated conservatively.

Our patient had a variety of potential causes of HPVG, including slightly low blood pressure, ventricle retention and upper gastrointestinal bleeding (UGB). Transient ischemia might be suspected because of the short period with elevated lactate. However, the hypotension and ventricle retention were not severe enough to justify transient mucosal ischemia therefor, esophageal variceal bleeding can be considered as the cause of portal system gas.

## Patient consent

Written informed consent was obtained from the patient for publication of this case report and any accompanying images. A copy of the written consent is available for review by the editor of this journal.

## REFERENCES

- [1] Abboud B, El Hachem J, Yazbeck T, Doumit C. Hepatic portal venous gas: physiopathology, etiology, prognosis and treatment. *World J Gastroenterol* 2009;15(29):3585–90. doi:10.3748/wjg.15.3585.
- [2] Schatz TP, Nassif MO, Farma JM. Extensive portal venous gas: Unlikely etiology and outcome. *Int J Surg Case Rep* 2015;8C:134–6. doi:10.1016/j.ijscr.2014.10.058.
- [3] Chan SC, Wan YL, Cheung YC, Ng SH, Wong AM, Ng KK. Computed tomography findings in fatal cases of enormous hepatic portal venous gas. *World J Gastroenterol* 2005;11(19):2953–5. doi:10.3748/wjg.v11.i19.2953.
- [4] Coulier B, Van den Broeck S, Coppens JP. Transient and rapidly resolving intrahepatic portal gas: CT findings. *JBR-BTR* 2008;91(5):214–16.
- [5] Piton G, Paquette B, Delabrousse E, Capellier G. Transient portal venous gas associated with reversible non-occlusive mesenteric ischemia: A case report. *Int J Surg Case Rep* 2017;37:76–8. doi:10.1016/j.ijscr.2017.05.041.
- [6] Zuwasti U, Shashidhar A, Haas C. A rare case of transient portal venous gas. *Radiol Case Rep* 2020;15(11):2053–5. doi:10.1016/j.radcr.2020.08.035.
- [7] Ginesu GC, Barmina M, Cossu ML, Feo CF, Fancellu A, Addis F, et al. Conservative approach to Hepatic Portal Venous Gas: A case report. *Int J Surg Case Rep* 2017;30:183–5. doi:10.1016/j.ijscr.2016.12.006.
- [8] D'Souza D, Sharma R. Portal venous gas. Reference article, Radiopaedia.org. (accessed on 06 Sep 2022). <https://doi.org/10.53347/rID-1913>.
- [9] Wolfe JN, Evans WA. Gas in the portal veins of the liver in infants; a roentgenographic demonstration with postmortem anatomical correlation. *Am J Roentgenol Radium Ther Nucl Med* 1955;74(3):486–8.
- [10] Pan HB, Huang JS, Yang TL, Liang HL. Hepatic portal venous gas in ultrasonogram—benign or noxious. *Ultrasound Med Biol* 2007;33(8):1179–83. doi:10.1016/j.ultrasmedbio.2007.01.014.
- [11] Monneuse O, Pilleul F, Barth X, Gruner L, Allaouchiche B, Valette PJ, et al. Portal venous gas detected on computed tomography in emergency situations: surgery is still necessary. *World J Surg* 2007;31(5):1065–71. doi:10.1007/s00268-006-0589-0.