

Available online at www.sciencedirect.com

ScienceDirect

journal homepage: www.elsevier.com/locate/radcr

Case Report

Metallic microbeads for hair extensions: Hidden dangers for magnetic resonance imaging[☆]

Ravish Kapoor, MD^{*}, Jihong Wang, PhD, Acsa M. Zavala, MD, Angela T. Truong, MD, Dam-Thuy Truong, MD

The University of Texas, MD Anderson Cancer Center, 1515 Holcombe Blvd., Houston, TX 77030, USA

ARTICLE INFO

Article history:

Received 1 June 2022

Revised 9 June 2022

Accepted 11 June 2022

Available online 6 July 2022

Keywords:

Thermal injury

Magnetic resonance imaging

Microbeads

ABSTRACT

Metallic foreign objects can cause various thermal injuries in patients undergoing magnetic resonance imaging (MRI). We present a case of a 33-year-old woman with numerous metallic microbeads on her head used for attaching hair extensions, who required MRI of her cervical spine under anesthesia. Due to the nature of how these microbeads were attached, as well as the quantity and configuration, these objects were determined to be a significant risk, especially for a patient requiring anesthesia for their scan. To our knowledge, this is the first report in literature of a patient presenting with such objects for MRI. Awareness of the implications of these microbeads on patient safety and recognizing the importance of a thorough safety screening process can enhance care for patients requiring MRI.

Published by Elsevier Inc. on behalf of University of Washington.

This is an open access article under the CC BY-NC-ND license

(<http://creativecommons.org/licenses/by-nc-nd/4.0/>)

Introduction

Thermal events are the most commonly reported serious injury in patients undergoing magnetic resonance imaging (MRI) [1]. A variety of cosmetic items have been associated with thermal injuries in patients undergoing MRI [2]. Metallic microbeads used for hair extensions are an increasingly popular trend that can potentially lead to such complications. We present a case of a patient with such microbeads scheduled for MRI under anesthesia. To our knowledge, this is the first report of metallic microbeads being encountered in a patient requiring MRI.

Case presentation

A 33-year-old woman with chronic pain and claustrophobia required MRI under anesthesia to evaluate for cervical-spine metastasis of her leiomyosarcoma. The MRI safety screening questionnaire revealed that she had hair extensions attached to her head via “microbeads,” but she was unaware if these microbeads were metallic. An MRI screening magnet did not identify ferromagnetism, but a metal wand detector did reveal that objects hidden deep within her hair were in fact metallic. The precise locations and quantity could not be determined, and since she was unable to remove the microbeads herself,

[☆] Competing Interests: The authors have declared that no competing interests exist.

^{*} Corresponding author.

E-mail address: rkapoor@mdanderson.org (R. Kapoor).

<https://doi.org/10.1016/j.radcr.2022.06.036>

1930-0433/Published by Elsevier Inc. on behalf of University of Washington. This is an open access article under the CC BY-NC-ND license (<http://creativecommons.org/licenses/by-nc-nd/4.0/>)

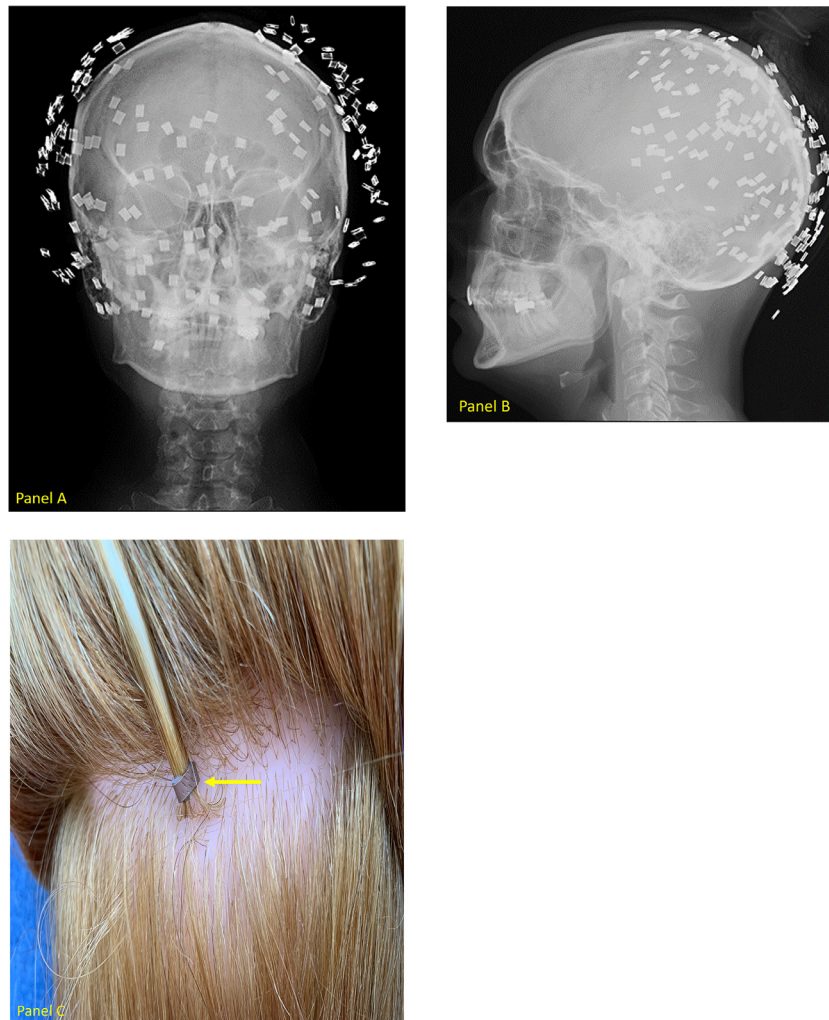


Fig. 1 – Coronal x-ray of flattened metallic microbeads (panel A), Sagittal x-ray of flattened metallic microbeads (panel B), Crimped metallic microbeads shown on mannequin (panel C).

an x-ray was requested by the attending radiologist to view object configuration. Coronal (Fig. 1-panel A) and sagittal (Fig. 1-panel B) x-ray views revealed numerous overlapping metallic microbeads that had been crimped flat (Fig. 1-panel C) close to her scalp. These microbeads had to be professionally removed by a hairdresser prior to her safely undergoing MRI. Therefore, she had to have her scan rescheduled to a later date.

Discussion

Metallic cosmetic items imbedded or attached to the patient during MRI scanning can lead to skin irritation, swelling, and even burns due to radiofrequency deposition [2]. These items can also cause significant artifact, rendering poor quality imaging. Microbeads, sometimes referred to as “micro-rings,” used to link artificial hair extensions to strands of the individual’s native hair close to the scalp make them hidden to the naked eye. They are made of an inner silicone layer and an outer colored metallic layer, allowing them to be tightly

crimped while blending in with the individual’s hair color. The combination of synthetic hair extensions, hair sprays/gels that may be used with them (all of which are often flammable) and overheating of metallic microbeads can potentially lead to burns by forming conductive loops [3]. This is especially true when these objects are within the zone of radiofrequency excitation [4], such as in our case where a patient with metallic objects all over her head was scheduled to undergo a cervical-spine MRI. Additionally, these metallic objects can be made of various ferromagnetic materials leading to the possibility of dislodgement.

Although sedation/general anesthesia is more frequently used in pediatric patients undergoing MRI, its use can help obtain quality images in certain adult patients who have trouble remaining still throughout the long MRI acquisition times due to pain, claustrophobia, and/or uncooperativeness [5]. The MRI screening process is even more important in patients who require sedation/anesthesia because the ability to sense injury from overheating can be pharmacologically masked [6,7].

Our patient was appropriately screened in Zone II and it was determined that she had objects on her body that

could pose a significant safety risk for undergoing MRI. If history/physical exam are inconclusive as part of the screening process, radiography can be utilized to further investigate foreign objects that may pose a potential risk to patients requiring MRI [2]. Due to how microbeads are attached to the patient, the quantity of how many microbeads are typically used, and the need for professional tools used by hairdressers to remove them, the patient had to have her scan rescheduled. This is important because such cancellations can impair efficient workflow, hence creating unnecessary downtimes for MRI personnel and even anesthesia staff if they are involved.

Conclusion

Increased awareness of the risks involved with metallic microbeads, their implications on workflow, and understanding the importance of the MRI safety screening process, especially in patients requiring sedation/anesthesia for their scans, can help prevent adverse events and improve patient care.

Patient consent

Written informed consent was obtained for this report.

REFERENCES

- [1] Delfino JG, Krainak DM, Flesher SA, Miller DL. MRI-related FDA adverse event reports: a 10-yr review. *Med Phys* 2019;46(12):5562–71 Epub 2019 Oct 8. PMID: 31419320. doi:[10.1002/mp.13768](https://doi.org/10.1002/mp.13768).
- [2] Kanal E, Barkovich AJ, Bell C, Borgstede JP, Bradley WG Jr, et al., Expert Panel on MR Safety ACR guidance document on MR safe practices: 2013. *J Magn Reson Imaging* 2013;37(3):501–30.
- [3] Dempsey MF, Condon B, Hadley DM. Investigation of the factors responsible for burns during MRI. *J Magn Reson Imaging* 2001;13(4):627–31 PMID: 11276109. doi:[10.1002/jmri.1088](https://doi.org/10.1002/jmri.1088).
- [4] Shellock FG. Radiofrequency energy-induced heating during MR procedures: a review. *J Magn Reson Imaging* 2000;12(1):30–6 PMID: 10931562. doi:[10.1002/1522-2586\(200007\)12:1<30::aid-jmri4>3.0.co;2-s](https://doi.org/10.1002/1522-2586(200007)12:1<30::aid-jmri4>3.0.co;2-s).
- [5] Murphy KJ, Brunberg JA. Adult claustrophobia, anxiety and sedation in MRI. *Magn Reson Imaging* 1997;15(1):51–4 PMID: 9084025. doi:[10.1016/s0730-725x\(96\)00351-7](https://doi.org/10.1016/s0730-725x(96)00351-7).
- [6] Jacob ZC, Tito MF, Dagum AB. MR imaging-related electrical thermal injury complicated by acute carpal tunnel and compartment syndrome: case report. *Radiology* 2010.
- [7] Practice advisory on anesthetic care for magnetic resonance imaging: an updated report by the American Society of Anesthesiologists task force on anesthetic care for magnetic resonance imaging. *Anesthesiology* 2015;122:495–520.