

Available online at www.sciencedirect.com

ScienceDirect

journal homepage: www.elsevier.com/locate/radcr

Case Report

Appendiceal mucocoele with pseudomyxoma peritonei mimicking ovarian tumor with peritoneal carcinomatosis[☆]

Chirihan Ayadi*, Amine Naggar, Hajar Andour, Fatima zahrae Chraa, Hounayda Jerquigue, Rachida Latib, Youssef Omor

Radiology Department, National Institute of Oncology Mohamed V University, Rabat, Morocco

ARTICLE INFO

Article history:

Received 22 March 2022

Revised 5 May 2022

Accepted 11 May 2022

Available online 18 June 2022

Keywords:

Mucocoele

Appendix

Pseudomyxoma peritonei

Mucinous cystadenocarcinoma

Imaging

ABSTRACT

Appendiceal mucocoele with unprompted pseudomyxoma peritonei is a rare malignant tumor, which is difficult to diagnose before surgery. We present a case of a 62-year-old woman, and subsequently discuss the clinical and imaging presentation of mucocoeles. Findings on CT scan suggested 2 diagnoses: appendiceal mucocoele with pseudomyxoma peritonei and malignant ovarian tumor with peritoneal carcinosis. MRI suggested the former diagnosis, showing a large tubular mass at the base of appendix with discontinuous wall, and no ovarian abnormality, which was confirmed by mini laparotomy and histological study of peritoneal thickened tissue. Treatment consisted of neoadjuvant chemotherapy, with a good response. This case shows the role of imaging in the preoperative diagnosis of appendicular mucocoeles; CT scan and MRI, which are useful tools in identifying undetermined lesions of the appendix.

© 2022 The Authors. Published by Elsevier Inc. on behalf of University of Washington.

This is an open access article under the CC BY-NC-ND license

(<http://creativecommons.org/licenses/by-nc-nd/4.0/>)

Mucocoele of the appendix was recognized as a pathological entity by Rokitsky in 1842 and was formally named by Feren in 1876 [1]. It is a rare condition, defined as a cystic dilation of the appendix after an intraluminal accumulation of translucent, gelatinous mucinous secretions which may affect totally or partially the appendix, more frequently the distal segment.

It represents 0.2%– to 0.3% of all appendicectomies, and in most cases (70%) they are confirmed by histopathology post operatively [2]. This disease presents a double problem: In one hand its differential diagnoses with acute appendicitis, with ovarian cyst, and with appendiceal plastron, and in the other

hand its malignant transformation into mucinous cystadenocarcinoma [3].

This report is about a case of mucocoele of the appendix with pseudomyxoma peritonei, and review of the literature.

Observation

A 62-year-old woman without significant history, presented with abdominal pain located in the right lower quadrant with progressive abdominal distension.

[☆] Competing Interests: The authors have declared that no competing interests exist.

* Corresponding author.

E-mail address: chirihane.ayadi@gmail.com (C. Ayadi).

<https://doi.org/10.1016/j.radcr.2022.05.028>

1930-0433/© 2022 The Authors. Published by Elsevier Inc. on behalf of University of Washington. This is an open access article under the CC BY-NC-ND license (<http://creativecommons.org/licenses/by-nc-nd/4.0/>)

Laboratory tests showed elevated tumor markers (ACE = 138.08 ng / ml, CA 125 = 306.60 U arb/ml, CA 19-9 = 527.85 U/ml). CT showed a cystic mass in the right lower quadrant, in contact with the caecum, containing curvilinear mural calcifications, and a pelvic cystic mass, it also showed nodular thickening of the peritoneal reflections with stranding and thickening of the omentum (omental cake), associated with scalloping of the liver surface (Fig. 1). Suggesting 2 main diagnoses; appendiceal mucocoele with pseudomyxoma peritonei and malignant ovarian tumor with peritoneal carcinomatosis.

Subsequently an MRI was performed, showing a cystic mass attached to the caecum, with a discontinuous wall, with curvilinear calcifications. On the other hand, the ovaries had no abnormality (Fig. 2). The more likely diagnosis was therefore an appendiceal mucocoele with pseudomyxoma peritonei.

A biopsy of the thickened peritoneal tissue was performed by a mini laparotomy, which confirmed the diagnosis of a mucinous cystadenocarcinoma of digestive origin. Appendix removal was not possible due to the presence of multiple adhesions and carcinomatosis nodules. The treatment consisted of neoadjuvant Folfox-based chemotherapy, with positive outcome.

Discussion

The appendiceal mucocoele was considered as a pathological entity by Rokitsky in 1842 and officially named by Feren in 1876. Appendiceal mucocoeles are uncommon entities from a variety of different pathological processes, of which only a small fraction is associated with the development of peritoneal pseudomyxoma [4].

Two convergent theories have been proposed to explain the disease [7].

Obstruction theory

Appendiceal mucocoeles are caused by the accumulation of mucus upstream of appendiceal lumen stenosis (cecal adenocarcinoma, appendix tumor).

Tumor theory

Tumors are the cause of hypersecretion of mucus in the appendix lumen [7].

The clinical flow of the disease does not have a specific picture. It often flows asymptotically, in about 50% of cases, it is discovered accidentally during radiographic and endoscopic examinations or at surgery [6]. Signs and symptoms, if present, include pain in the right lower quadrant, changes in bowel habits, anemia, hematochezia, and depending on the location of the appendix, other signs, such as hematuria, may be present. The most frightening complication is pseudomyxoma peritonei. Whether benign or malignant, treatment is dif-

ficult and prognosis uncertain: its 5-year survival rate is only 53%-75% [1].

The classification of extra-appendiceal disease is also problematic in the evaluation of appendiceal tumors. Surgeons and pathologists use the term “pseudomyxoma peritonei” to describe mucin in the abdomen. Unfortunately, different authors use this term to designate different histological findings. Some authors use the term pseudomyxoma peritonei to describe the accumulation of mucin in the abdominal cavity, whether or not it contains mucous epithelium, while some authors consider it to mean peritoneal carcinomatosis, other groups argue that a distinction should be made between the low-grade pattern of classic PP and true peritoneal carcinomatosis because these 2 entities are associated with a different prognosis and clinical significance [5].

The preoperative diagnosis of appendicular mucocoele is important to select an appropriate surgical approach to prevent peritoneal dissemination, prevent intraoperative and postoperative complications, and repeated surgery [8].

Ultrasonography is the first-line diagnostic method for patients with acute abdominal pain. It can be used to differentiate mucocoele from acute appendicitis. In the context of acute appendicitis, an appendix outer diameter threshold of 6 mm, and greater than 15 mm indicates the presence of a mucocoele with a sensitivity of 83% and a specificity of 92% [6]; it shows a cystic, encapsulated lesion of the right lower quadrant, firmly attached to the caecum [4], oblong or piriform with a large vertical axis, with sharp contours [7]. Internal variable echogenicity is related to mucus density. In some patients, multiple echogenic layers along the dilated appendix produce the appearance of ‘onion skin-like’ circles and are pathognomonic for mucocoele [4].

CT is considered to be the most accurate diagnostic method. It can be used to detect mucocoeles-specific signs with high accuracy [10]. A CT scan makes it possible to objectify the connection between the tumor and the cecum. The tumor is often round, well limited, and sometimes partitioned [7]. Cecal lumen greater than 1.3 cm with cystic dilatation and wall calcification [10]. The density of the contents can vary from that of liquid to that of soft tissues (from 10 to 45 UH) with parietal late and homogenous enhancement after injection of iodine [7].

Visceral scalloping, on the other hand, is a diagnostic sign and distinguishes mucinous from fluid ascites on CT. As mucin producing cells in pseudomyxoma peritonei are poorly adherent, the Douglas and/or retro vesical space, the right and left subphrenic spaces, and the surface of the liver and spleen are the commonest sites involved [4].

Dhage-Ivatury and Sugarbaker propose a simple yet thorough evaluation of these patients using the new algorithm. Appendectomy alone is the surgical treatment option for patients with benign mucocoeles with negative resection margins and no perforation. These patients do not require long-term follow-up [9]. Patients with perforated mucocoele, positive margins, positive cytology, and positive appendix lymph nodes should undergo right colectomy and/or cytoreductive surgery (CRS) and/or heated intraperitoneal chemotherapy (HIC) or early postoperative intraperitoneal chemotherapy (EPIC) [9].

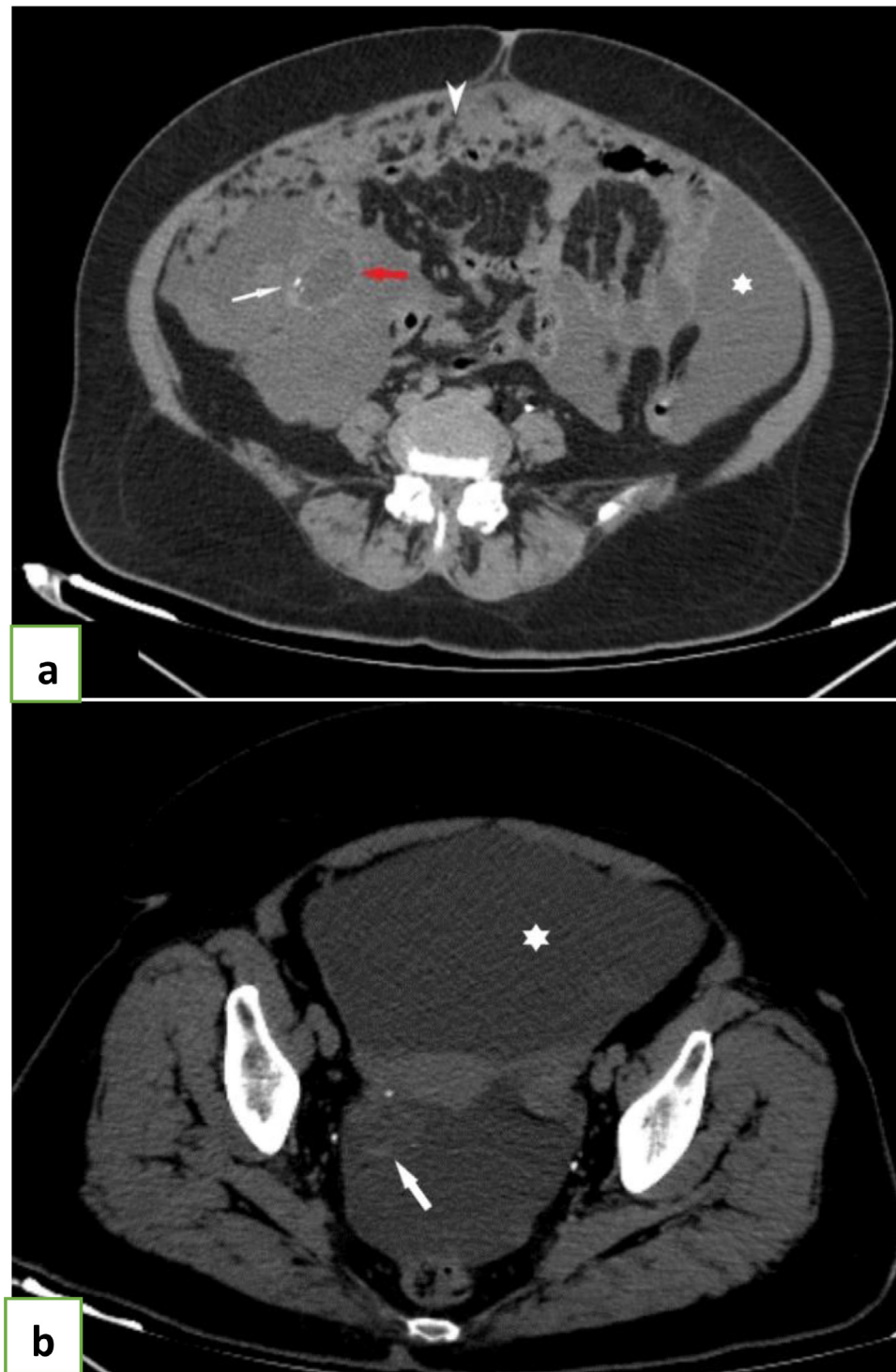

Fig. 1 – Abdominal post injection CT scan showing a cystic mass in the right lower quadrant, in contact with the caecum (red arrow) containing mural calcifications (with arrow) (A) and pelvic cystic mass (B) (large white arrow), CT also showed nodular and thickening of peritoneal reflections with stranding and thickening of the omentum (head arrow) and peritoneal effusion (Asterisk). (Color version of figure is available online.)

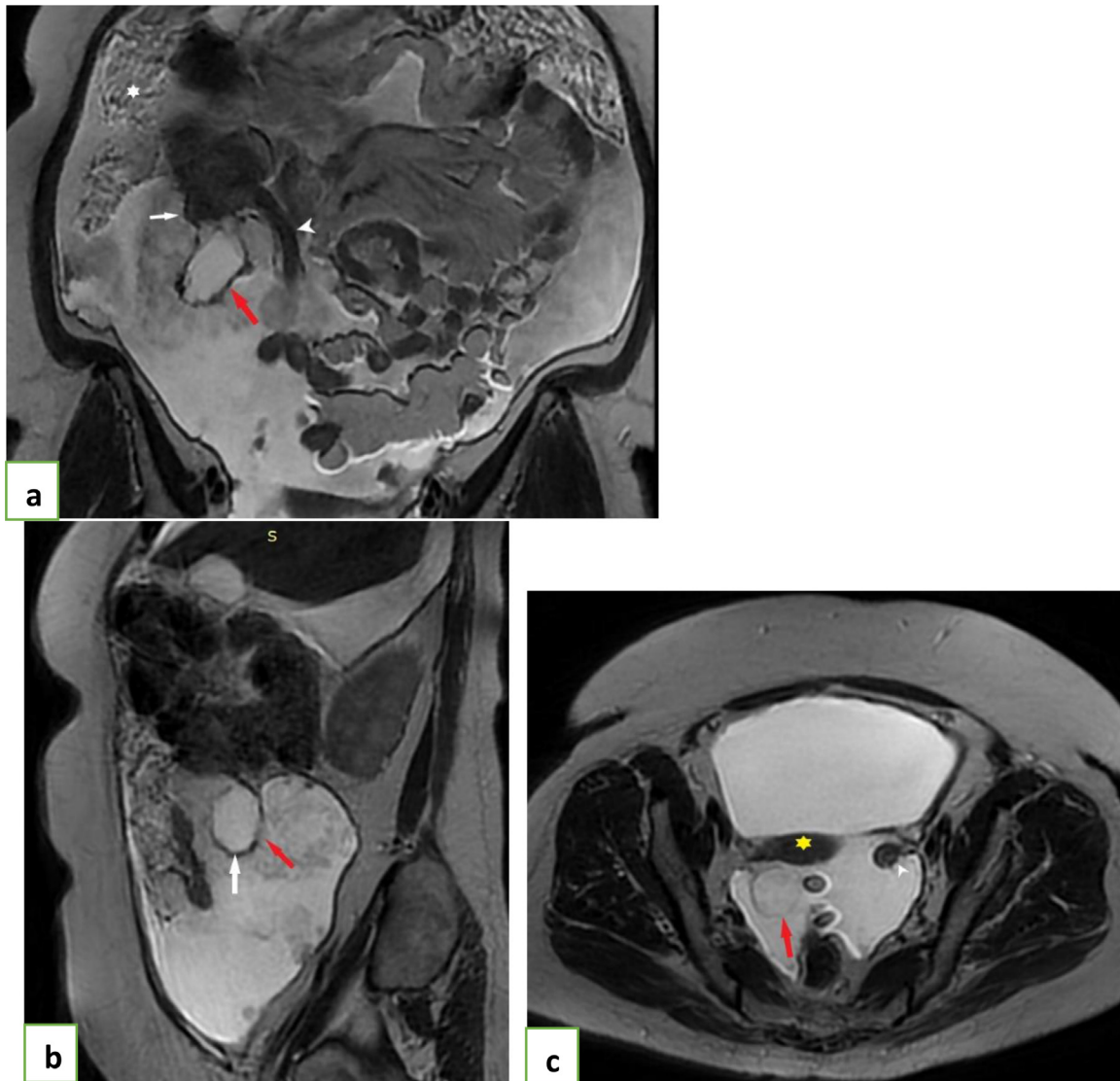


Fig. 2 – Abdominal MRI, T2 sequence, in the 3 planes; coronal (A), sagittal (B) and axial images (C) showing: A: A cystic mass (red arrow) attached to the caecum (white arrow), below the last ileal loop (head arrow). B: A discontinued wall (red arrow). C: A pelvic cystic mass (red arrow) with no ovarian abnormality (head arrow). (Color version of figure is available online.)

Conclusions

In conclusion, mucocoele of the appendix with pseudomyxoma peritonei is a rare disease and can present with confusing symptoms. Preoperative diagnosis greatly assists in determining appropriate management and minimizing both intraoperative and postoperative complications. Ultrasonography, and particularly CT, should be used extensively for this purpose, and sometimes abdominal MRI is a useful tool in identifying undetermined lesions of the appendix.

Patient consent

I confirm that patient has given his consent.

Supplementary materials

Supplementary material associated with this article can be found, in the online version, at doi:[10.1016/j.radcr.2022.05.028](https://doi.org/10.1016/j.radcr.2022.05.028).

REFERENCES

- [1] Jose Carlos de Rezende Pereira, Jose Carlos Vieira Trugilho, and Aliar Augusto Sarmat, Rio de Janeiro, Brazil. Mucocoele of the appendix. 2022. doi:[10.1016/S0039-6060\(03\)00321-0](https://doi.org/10.1016/S0039-6060(03)00321-0)
- [2] Delmaki, R., Benelkhaiat, B. FINECH Diagnostic and therapeutic aspect of appendicular mucocoeles in the visceral surgery department. CHU Mohamed VI (Retrospective study over 5 years), thesis. 2022.

- [3] L.N. Kouadio, K. Kouadio, T.H. Turquin. Appendicular mucocoele: a differential diagnosis to think about. *Médecine d’Afrique Noire*: 2000, 47.
- [4] Dixit A, Robertson JHP, Mudan SS, Akle C. Appendiceal mucocoeles and pseudomyxoma peritonei. *World J Gastroenterol* 2007;13(16):2381–4.
- [5] Zaza Demetrashvili, Mamuka Chkhaidze, Kakhi Khutsishvili, Gega Topchishvili, Tamar Javakhishvili, Irakli Pipia, et al. Mucocoele of the appendix: case report and review of literature. 2022. doi:10.9738/CC139.1.
- [6] Pai RK, Longacre TA. Appendiceal mucinous tumors and pseudomyxoma peritonei: histologic features, diagnostic problems, and proposed classification. *Adv Anat Pathol* 2005;12:291–311.
- [7] Higa E, Rosai J, Pizzimbono CA, Wise L. Mucosal hyperplasia, mucinous cystadenoma, and mucinous cystadenocarcinoma of the appendix. A re-evaluation of appendiceal “mucocoele”. *Cancer* 1973;32:1525–41.
- [8] Kemal Karakaya, Figen Barut, Ali Ugur Emre, Hamdi Bulent Ucan, Guldeniz Karadeniz Cakmak, Oktay Irkorucu, et al. Appendiceal mucocoele: case reports and review of current literature. 2022. doi:10.3748/wjg.14.2280.
- [9] Sugarbaker PH. Appendiceal epithelial neoplasms and pseudomyxoma peritonei, a distinct clinical entity with distinct treatments. In: *General Surgery. Principles and International Practice*. Research Gate: London-Limited: Springer; 2009. p. 885–93.
- [10] Ruiz-Tovar J, Teruel DG, Gastineires VM, Dehesa AS, Quindos PL, Molina EM. Mucocoele of the appendix. *World J Surg* 2007;31(3):542–8.