

Available online at [www.sciencedirect.com](http://www.sciencedirect.com)

ScienceDirect

journal homepage: [www.elsevier.com/locate/radcr](http://www.elsevier.com/locate/radcr)

## Case Report

## A rare case of fusiform basilar trunk aneurysm ☆

Nguyen-Thi To Tran, MD<sup>a,1</sup>, Tran Chi Cuong, MD, PhD<sup>b,1</sup>, Le Minh Thang, MD<sup>b,1</sup>,  
 Nguyen-Luu Giang, MD<sup>b</sup>, Ngo Minh Tuan, MD<sup>b</sup>, Nguyen-Dao Nhat Huy, MD<sup>b</sup>,  
 Duong Hoang Linh, MD<sup>b</sup>, Mai-Van Muong, MD<sup>b</sup>, Nguyen Minh Duc, MD<sup>c,\*</sup>

<sup>a</sup> Department of Surgery, Can Tho S.I.S General Hospital, Can Tho, Vietnam<sup>b</sup> Digital Subtraction Angiography Unit, Can Tho S.I.S General Hospital, Can Tho, Vietnam<sup>c</sup> Department of Radiology, Pham Ngoc Thach University of Medicine, Ho Chi Minh City, Vietnam

## ARTICLE INFO

## Article history:

Received 9 June 2022

Accepted 12 June 2022

Available online 4 July 2022

## Keywords:

Pediatric aneurysm

Basilar aneurysm

Stent-assisted coiling

Dual antiplatelet therapy

## ABSTRACT

Aneurysms in the posterior circulation and distal sites are more common among the pediatric population than among adults, with a male predominance. Symptoms of an aneurysm in the posterior circulation can include a stiff neck or severe headache due to a ruptured aneurysm, whereas an unruptured aneurysm can cause mass effects or neurological deficits. However, in children, the complete occlusion of the aneurysm while preserving the flow of the main artery can be difficult to achieve when attempting a stent-assisted coil embolization technique. A 25-month-old girl presented with left hemiparesis and was diagnosed with a basilar artery aneurysm 10 months prior, but she did not receive any specific treatment. No history of trauma and no significant familial history were recorded. Angiography showed a fusiform aneurysm on the basilar artery trunk, which was successfully occluded using stent-assisted coiling following dual antiplatelet therapy with clopidogrel and aspirin. She was discharged with the complete restoration of motor deficits.

© 2022 The Authors. Published by Elsevier Inc. on behalf of University of Washington.

This is an open access article under the CC BY-NC-ND license

(<http://creativecommons.org/licenses/by-nc-nd/4.0/>)

## Background

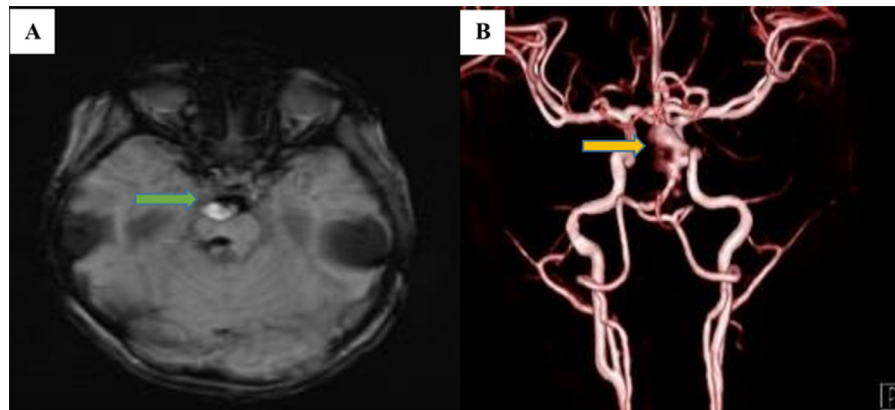
Unruptured basilar artery aneurysms in children are rare entities with a poor prognosis due to neurological deficits caused by a significant mass effect. The mortality rate due to aneurysmal rupture within the posterior circulation is 44.7%

[1]. Currently, endovascular occlusion is the standard treatment for cerebral aneurysms, replacing the surgical clamping of aneurysms, especially aneurysms with a fusiform shape [2]. We report the successful endovascular treatment of a pediatric fusiform aneurysm in the posterior circulation, preventing aneurysmal rupture.

☆ Competing Interests: The authors declare that there is no conflict of interest.

\* Corresponding author.

E-mail address: [bsnguyenminhduc@pnt.edu.vn](mailto:bsnguyenminhduc@pnt.edu.vn) (N.M. Duc).<sup>1</sup> These authors contributed equally to this article as co-first authors.



**Fig. 1 – The mural thrombosis in the aneurysm (green arrow - A) and the fusiform basilar aneurysm on cerebral magnetic resonance angiography (yellow arrow - B).**

### Case report

Our patient was a 25-month-old girl with focal neurological deficits, including left hemiparesis and peripheral facial nerve palsy, which were diagnosed 10 months prior when she presented at the hospital with vomiting and progressive hemiparesis with central facial palsy. Magnetic resonance imaging (MRI, 3 Tesla) revealed a fusiform basilar aneurysm measuring approximately 12 × 20 mm (Fig. 1). The patient was treated daily with 5 mg/kg aspirin (one 81 mg tablet) and 0.5 mg/kg clopidogrel (1 ml of a solution consisting of one 75 mg clopidogrel tablet dissolved in 10 ml warm) based on a weight of 15 kg to prepare her for stent placement.

Angiography identified a fusiform basilar trunk aneurysm sized 12 × 20 mm. The left vertebral artery was accessed using a Neuron MAX 0.088 (Penumbra, Inc.) co-axial system with a vertebral 5F diagnostic catheter (Merit Medical) and 0.035" wire (Terumo) to map the artery.

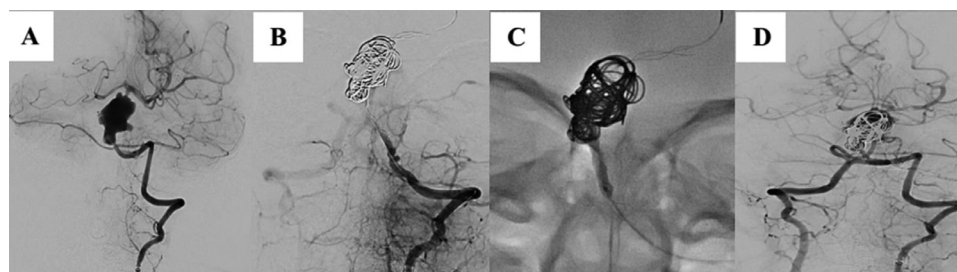
Using a double microcatheter technique, a Vasco+10MP (Balt) microcatheter with a Hybrid1214D (Balt) microwire was used to catheterize the aneurysm, and a Vasco+21 (Balt) microcatheter with a Hybrid 1214D (Balt) microwire was simultaneously passed through the aneurysm into the left posterior cerebral artery. LEO+ 3.5 × 35 mm and LEO+ 3.0 × 35 mm (Balt) stents were unsheathed across the aneurysm neck, and Barricade coils (Balt; 14 × 47; 12 × 40; 4 × 20) were placed via the Vasco+10MP catheter to slow the blood flow. Angiography was used to verify that the stents were occluded. A Vasco+10MP microcatheter was used with a Hybrid007D (Balt) microwire to perform the selective catheterization of the left posterior cerebral artery, after which the microcatheter was replaced with a balloon Helix 2.0 × 20 mm (cNovate) inflated to 6 atm, using a 300 cm exchange microwire (Chikai 300; Asahi Intecc). During the procedure, 2000 UI heparin was administered. After complete recanalization was achieved, a stent was used to cover the aneurysm and stabilize the coil embolization. The total procedural time was 120 minutes from femoral puncture (Fig. 2). After the procedure, a continuous infusion of 1500 UI heparin in 50 ml solution was administered at 5 ml/hour. The patient was discharged 6 days after the aneurysm occlusion, with symptom improvement relative to the time of admission.

### Discussion

An aneurysm is an abnormal arterial dilatation caused by focal hemodynamic stress, inflammation, and genetic factors. Intracranial aneurysms are relatively common, with a prevalence of approximately 4%. Among the pediatric population, aneurysms in the posterior circulation occur three times as often as in the adult population (21%), and basilar artery aneurysms represent 11.4% of all pediatric aneurysms [3]. Risk factors associated with the formation of pediatric aneurysms include aortic coarctation, polycystic renal disease, fibromuscular dysplasia, tuberous sclerosis, and systemic or genetic diseases (neurofibromatosis type 1, Marfan syndrome, Ehlers-Danlos syndrome) [4,5]. These risks contribute to the loss of the elastic layer of the artery wall, weakening the vessel wall and enhancing the impact of continuous intravascular pressure on the vessel lumen. The wave effect caused by the continuous impact of the aneurysm against adjacent cerebral structures causes parenchymal damage, explaining why neurological deficits often improve after intervention [6].

In this pediatric patient, endovascular treatment was chosen due to the challenge of treating large fusiform aneurysms in the posterior circulation [7]. Our goals were to both improve the patient's symptoms and prevent aneurysmal rupture. According to the literature, the treatment of this type of aneurysm with stent-assisted coiling is the most optimal approach [8,9]. Due to the high risk of pontine artery occlusion when treating long fusiform aneurysms in the basilar artery, flow diverter stents and simple coil embolization were not feasible treatment options.

Before the procedure, dual antiplatelet therapy (DAPT) was administered, although no standard guidelines exist regarding the use of DAPT in children. However, many case series have described the use of pediatric DAPT doses (a weight-based dose of clopidogrel ranging from 0.2 to 1 mg/kg/day) to achieve a sufficient therapeutic effect during stent placement [10–14]. Concomitant aspirin therapy was described in the range of 1–5 mg/kg/day [15]. This DAPT regimen was recommended to prevent thrombotic events associated with some types of heart disease [16].



**Fig. 2 – Cerebral angiography showing a fusiform basilar trunk aneurysm (A); stent occlusion (B); inflated balloon at the occluded site (C); and the complete recanalization and stable coil embolization (D).**

## Conclusion

We describe a case of a fusiform basilar trunk aneurysm resulting in neurological deficits. The use of stent-assisted coiling should be considered an effective option for the treatment of complicated aneurysms. However, the long-term risks and efficacy of stent-assisted coiling during child development require additional clarification through careful monitoring.

## Author contributions

Nguyen-Thi To Tran, Tran Chi Cuong, and Le Minh Thang contributed equally to this article as co-first authors and writing original draft. Tran Chi Cuong, Nguyen Luu Giang, Ngo Minh Tuan and Nguyen Dao Nhat Huy contributed to undergo embolization procedure, collect and interpret the imaging. Le Minh Thang and Nguyen Minh Duc made substantial contributions to collect patient data and clinical data analysis. All authors have read, revised and approved the final published version of the manuscript. All authors were responsible for submission of our study for publication.

## Statement of ethics

Ethical approval was not necessary for the preparation of this article.

## Patient consent

Written informed consent was obtained from the patient for publication of this case report and any accompanying images.

## Informed Consent

Informed consent for patient information to be published in this article was obtained.

## Data availability statement

All data generated or analyzed during this study are included in this article and/or its online supplementary material files. Further enquiries can be directed to the corresponding author.

## REFERENCES

- [1] Huang J, van Gelder JM. The probability of sudden death from rupture of intracranial aneurysms: a meta-analysis. *Neurosurgery* 2002;51(5):1101–5 discussion 1105–7 PMID: 12383354. doi:[10.1097/00006123-200211000-00001](https://doi.org/10.1097/00006123-200211000-00001).
- [2] Kan P, Mokin M, Puri AS, Wakhloo AK. Successful treatment of a giant pediatric fusiform basilar trunk aneurysm with surpass flow diverter. *J Neurointerv Surg* 2016;8(6):e23 Epub 2015 Jun 10. PMID: 26063795. doi:[10.1136/neurintsurg-2015-011718.rep](https://doi.org/10.1136/neurintsurg-2015-011718.rep).
- [3] Sorteberg A, Dahlberg D. Intracranial non-traumatic aneurysms in children and adolescents. *Curr Pediatr Rev* 2013;9(4):343–52 PMID: 24696670; PMCID: PMC3970571. doi:[10.2174/2211552811201000005](https://doi.org/10.2174/2211552811201000005).
- [4] Krings T, Geibprasert S, terBrugge KG. Pathomechanisms and treatment of pediatric aneurysms. *Childs Nerv Syst* 2010;26(10):1309–18 Epub 2009 Dec 24. PMID: 20033187. doi:[10.1007/s00381-009-1054-9](https://doi.org/10.1007/s00381-009-1054-9).
- [5] Editorial LP. From aneurysms to aneurysmal vasculopathies. *Interv Neuroradiol* 1999;5(2):105–8 Epub 2001 May 15. PMID: 20670499; PMCID: PMC4268675. doi:[10.1177/159101999900500201](https://doi.org/10.1177/159101999900500201).
- [6] Harrigan MR, Deveikis JP. *Handbook of Cerebrovascular Disease and Neurointerventional Technique*. Springer International Publishing; 2018. doi:[10.1007/978-3-319-66779-9](https://doi.org/10.1007/978-3-319-66779-9).
- [7] Hou K, Lv X, Yu J. Endovascular treatment of posterior cerebral artery trunk aneurysm: the status quo and dilemma. *Front Neurol* 2022;12:746525 PMID: 35069405; PMCID: PMC8778581. doi:[10.3389/fneur.2021.746525](https://doi.org/10.3389/fneur.2021.746525).
- [8] Takeshita T, Nagamine T, Ishihara K, Kaku Y. Stent-assisted coil embolization of a recurrent posterior cerebral artery aneurysm following surgical clipping. *Neuroradiol J* 2017;30(1):99–103 Epub 2016 Dec 8. PMID: 27903923; PMCID: PMC5564341. doi:[10.1177/1971400916678243](https://doi.org/10.1177/1971400916678243).
- [9] Miyamoto S, Yoshioka R, Yamada K, et al. Stent-assisted coil embolization for a pediatric distal posterior cerebral artery aneurysm: a case report and review. *Interdisciplinary Neurosurgery* 2022;29:101532. doi:[10.1016/j.inat.2022.101532](https://doi.org/10.1016/j.inat.2022.101532).
- [10] Jia L, Wang J, Zhang L, Zhang Y, You W, Yang X, et al. Pediatric patient with a giant vertebrobasilar dissecting aneurysm

- successfully treated with three pipeline embolization devices. *Front Neurol* 2020;11:633 PMID: 32719653; PMCID: PMC7347969. doi:[10.3389/fneur.2020.00633](https://doi.org/10.3389/fneur.2020.00633).
- [11] Navarro R, Brown BL, Beier A, Ranalli N, Aldana P, Hanel RA. Flow diversion for complex intracranial aneurysms in young children. *J Neurosurg Pediatr* 2015;15(3):276–81 Epub 2015 Jan 2. PMID: 25555114. doi:[10.3171/2014.9.PEDS14333](https://doi.org/10.3171/2014.9.PEDS14333).
- [12] Barburoglu M, Arat A. Flow diverters in the treatment of pediatric cerebrovascular diseases. *AJNR Am J Neuroradiol* 2017;38(1):113–18 Epub 2016 Oct 20. PMID: 27765738; PMCID: PMC7963647. doi:[10.3174/ajnr.A4959](https://doi.org/10.3174/ajnr.A4959).
- [13] Wang J, Zhang Y, Lv M, Yang X, Tian Z, Liu J, et al. Application of the pipeline embolization device for giant vertebrobasilar dissecting aneurysms in pediatric patients. *Front Neurol* 2019;10:179 Erratum in: *Front Neurol*. 2019 Aug 22;10:862. PMID: 30915016; PMCID: PMC6421298. doi:[10.3389/fneur.2019.00179](https://doi.org/10.3389/fneur.2019.00179).
- [14] Mallett P, O'Reilly ST, Rennie I, Shanmuganathan M, Thompson AJ. Rare case of basilar artery aneurysm in a young child. *BMJ Case Rep* 2020;13(4):e233875 PMID: 32332044; PMCID: PMC7202718. doi:[10.1136/bcr-2019-233875](https://doi.org/10.1136/bcr-2019-233875).
- [15] Monagle P, Chan AKC, Goldenberg NA, Ichord RN, Journeycake JM, Nowak-Göttl U, et al. Antithrombotic therapy in neonates and children: antithrombotic therapy and prevention of thrombosis, 9th ed: American College of Chest Physicians Evidence-Based Clinical Practice Guidelines. *Chest* 2012;141(2):e737S–e801S SupplErratum in: *Chest*. 2014 Dec;146(6):1694. Dosage error in article text. Erratum in: *Chest*. 2014 Nov;146(5):1422. PMID: 22315277; PMCID: PMC3278066. doi:[10.1378/chest.11-2308](https://doi.org/10.1378/chest.11-2308).
- [16] Li JS, Yow E, Berezny KY, Bokesch PM, Takahashi M, Graham TP Jr, et al. Dosing of clopidogrel for platelet inhibition in infants and young children: primary results of the Platelet Inhibition in Children On cLOpidogrel (PICOLO) trial. *Circulation* 2008;117(4):553–9 Epub 2008 Jan 14. PMID: 18195173. doi:[10.1161/CIRCULATIONAHA.107.715821](https://doi.org/10.1161/CIRCULATIONAHA.107.715821).