

Available online at www.sciencedirect.com

ScienceDirect

journal homepage: www.elsevier.com/locate/radcr

Case Report

Bilateral occipital arteries arising from the thyrocervical trunks (ascending cervical artery-occipital artery anastomosis) diagnosed by magnetic resonance angiography[☆]

Akira Uchino, MD, PhD^{a,*}, Shoichiro Ishihara, MD, PhD^b^a Department of Radiology, Saitama Sekishinkai Hospital, 2-37-20 Irumagawa Sayama, Saitama 350-1305, Japan^b Department of Neuroendovascular Therapy, Saitama Sekishinkai Hospital, 2-37-20 Irumagawa Sayama, Saitama 350-1305, Japan

ARTICLE INFO

Article history:

Received 25 March 2022

Revised 4 April 2022

Accepted 5 April 2022

Available online 5 May 2022

Keywords:

Arterial variation

External carotid artery

Magnetic resonance angiography

Occipital artery

Subclavian artery

Thyrocervical trunk

ABSTRACT

We herein report a case of bilateral occipital arteries (OAs) arising from the thyrocervical trunks (TCTs). The patient was a 34-year-old woman with suspected basilar artery aneurysm underwent magnetic resonance (MR) angiography of the head and neck region using a 3-Tesla scanner. Cranial MR angiography revealed no aneurysm. Cervical MR angiography showed bilateral OAs arising from the TCTs. The extremely hyperplastic ascending cervical artery (ACA) arose from the transverse cervical artery, and continued to the OA, bilaterally. The OA usually arises from the proximal external carotid artery and runs posterosuperiorly; rarely, it arises from the internal carotid artery or the vertebral artery. The variation in our patient is regarded as bilateral ACA-OA anastomosis. Only one case of the unilateral type of this variation has been reported, having been diagnosed during dissection. Before cervical arterial intervention or head and neck surgery, identification of OA variation is important. During the interpretation of cervical MR angiography findings, careful observation of the origin and course of the OA is required.

© 2022 The Authors. Published by Elsevier Inc. on behalf of University of Washington.

This is an open access article under the CC BY-NC-ND license

(<http://creativecommons.org/licenses/by-nc-nd/4.0/>)

Introduction

The thyrocervical trunk (TCT) usually has 3 branches: the inferior thyroid artery, the ascending cervical artery (ACA), and the transverse cervical artery. The ACA mainly arises from the

proximal segment of the inferior thyroid artery [1]. Branching variations of the TCT are not rare. The internal thoracic artery rarely arises from the TCT [2]. Extremely rarely, the vertebral artery (VA) arises from the TCT [3].

The occipital artery (OA) rarely arises from the internal carotid artery (ICA) and VA [4–7]. We herein report a case of

[☆] Competing interests: We declare that we have no conflict of interest.

* Corresponding author.

E-mail address: auchino0528@gmail.com (A. Uchino).<https://doi.org/10.1016/j.radcr.2022.04.010>1930-0433/© 2022 The Authors. Published by Elsevier Inc. on behalf of University of Washington. This is an open access article under the CC BY-NC-ND license (<http://creativecommons.org/licenses/by-nc-nd/4.0/>)

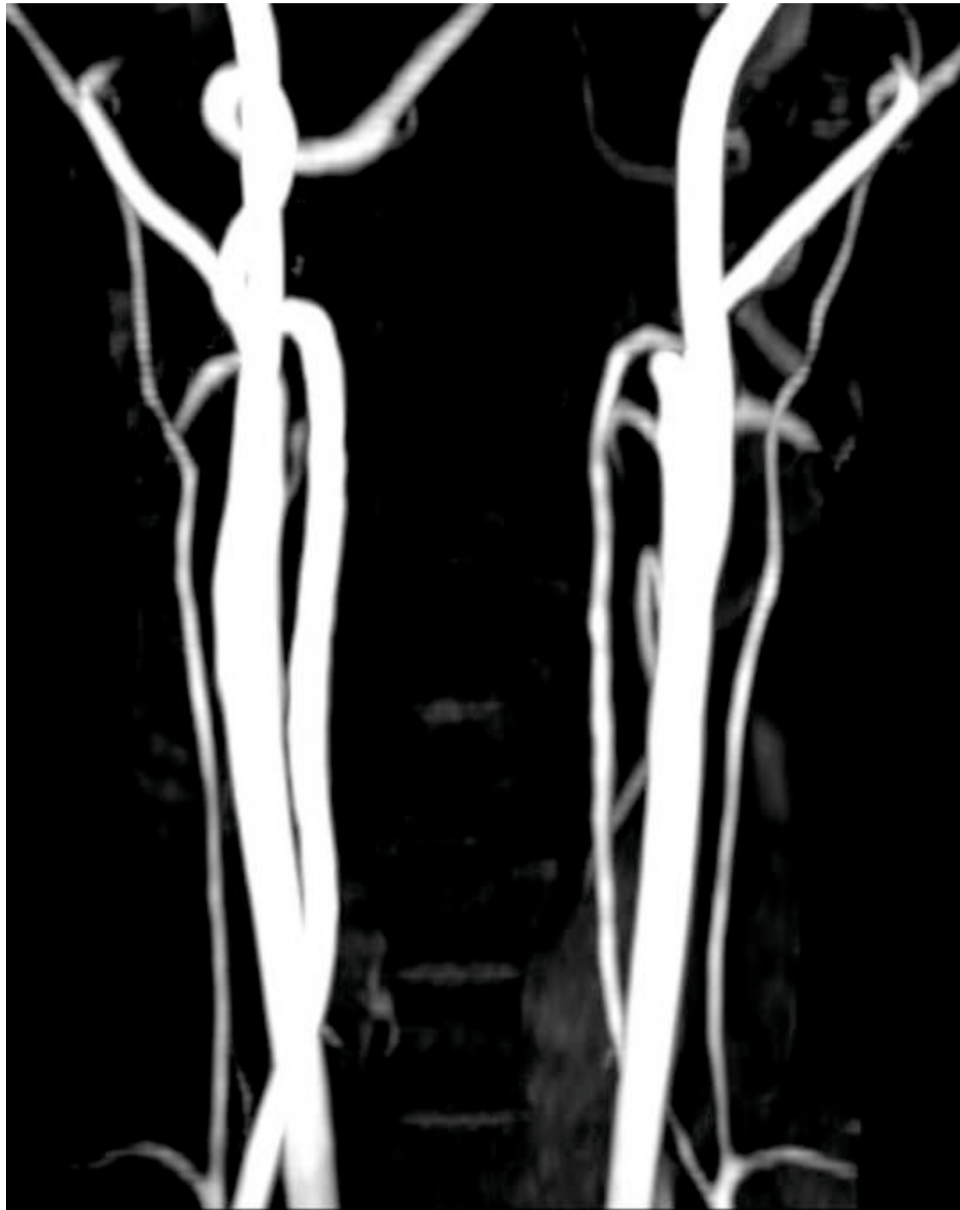

Fig. 1 – Maximum-intensity-projection images of anteroposterior (A) and left lateral (B) projections of magnetic resonance angiography of the neck show bilateral occipital arteries arising from the thyrocervical trunks. The extremely hyperplastic ascending cervical arteries arise from the proximal segment of the transverse cervical arteries, and continue to the occipital arteries, bilaterally (arrows).

bilateral OAs arising from the TCTs. This variation is regarded as bilateral ACA-OA anastomosis. Only one case of the unilateral type of this variation has been reported previously; in that case, the variation was found during dissection [8].

Case report

A 34-year-old woman with suspected basilar artery aneurysm underwent cranial magnetic resonance (MR) imaging, and

cervical and cranial MR angiography using a 3-Tesla scanner (Magnetom Skyra, Siemens Healthineers, Erlangen, Germany). MR angiography was obtained using a standard three-dimensional time-of-flight technique. The imaging parameters of the neck were as follows: flip angle, 15°; repetition time, 20.0 sec; echo time, 3.7 sec; and slice thickness, 1.2 mm.

Cranial MR imaging showed no abnormality. Cranial MR angiography revealed no aneurysm. Early bifurcated right superior cerebellar artery with tortuosity at its origin mimics an aneurysm (not shown). Cervical MR angiography showed bi-



Fig. 1 – Continued

lateral OAs arising from the TCTs. The extremely hyperplastic ACAs arose from the transverse cervical arteries, not from the inferior thyroid artery, and continued to the OAs (Fig. 1). A schematic illustration of the normal anatomy and that of our patient is shown in Figure 2.

Discussion

The OA is one of the major branches of the proximal external carotid artery (ECA). The OA rarely arises from the cervical ICA, the origin of the ICA, the carotid bifurcation, and the VA [4–7]. Using MR angiography, the prevalence of anomalous origin of

the OA was reported to be 0.21%, with a right-side predominance [5]. The normal OA runs posterosuperiorly and mainly supplies the extracranial structures of the occipital region. It is well known that there is a cervical arterial collateral network between the OA, VA, and the deep cervical artery, which arises from the costocervical trunk, which is the branch next to the TCT of the subclavian artery (SA) [9]. In the case of occlusion of the proximal OA, the distal OA may be supplied by the deep cervical artery and/or VA. The OAs of our patient arose from the TCTs, not the costocervical trunks. Therefore, these were not formed as cervical arterial collateral networks.

The branching order from the SA is as follows: VA, internal thoracic artery, TCT, and costocervical trunk. The TCT is divided into two branches: the inferior thyroid artery and

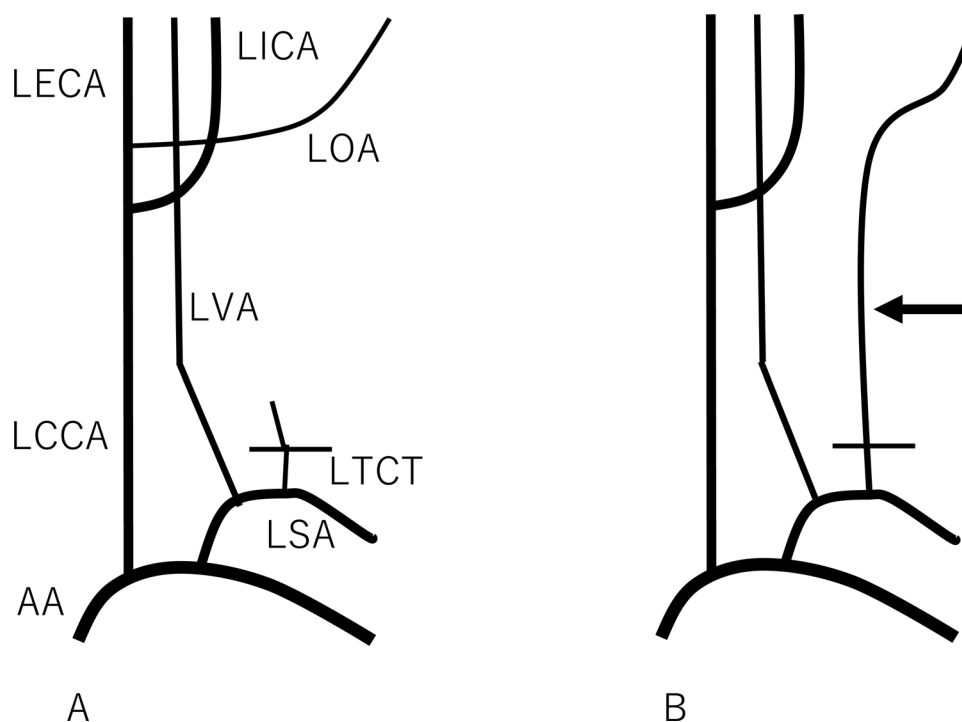


Fig. 2 – A schematic illustration of the left cervical arterial anatomy: in a normal patient (A) and in our patient (B). The arrow in B indicates an anomalous artery. AA: aortic arch, LCCA: left common carotid artery, LECA: left external carotid artery, LICA: left internal carotid artery, LOA: left occipital artery, LSA: left subclavian artery, LTCT: left thyrocervical trunk, LVA: left vertebral artery.

the transverse cervical artery. The third branch of the TCT is the ACA, which usually arises from the inferior thyroid artery [1]. However, branching variations of the TCT are not rare. In our patient, the ACA arose from the proximal segment of the transverse cervical artery, not from the inferior thyroid artery. Furthermore, the ACAs were extremely hyperplastic and continued to the OAs, bilaterally. Thus, the OAs arose from the TCTs. To the best of our knowledge, only one case describing the unilateral type of this variation has been reported; in that case, the variation was found during dissection [8]. According to Tubbs et al. [8], Lasjaunias mentioned, many years ago, that the OA may branch from the ACA. This report describes the first case in which the bilateral type of this variation was identified. It also represents the first time that this variation was initially diagnosed by medical imaging. However, the clinical significance of this extremely rare variation is limited. The internal thoracic artery rarely arises from the TCT [4]. This type of variation is clinically important during myocardial revascularization surgery. Extremely rarely, the VA arises from the TCT [3].

Embryologically, the ECA is a sprout from the ventral surface of the third aortic arch. Branches of the ECA begin as a capillary network with which vascular buds from the neighboring arteries become connected. The proximal segment of the SA, and hence the TCT, is derived from the fourth aortic arch. The carotid duct, which is the dorsal aorta between the entrance of the third and fourth aortic arches and which is normally obliterated, may explain the persistence of a connection between a branch of the SA and the ECA [8]. The prox-

imal segment of the OA, which is regarded as a remnant of the primitive proatlantal artery [4], is thought to have abnormally regressed during the early gestational period. The ACA, not the deep cervical artery, acted as a collateral channel to the distal OA for an unknown reason.

Conclusions

We encountered a case of bilateral OAs arising from the TCTs during the interpretation of cervical MR angiography. This variation is regarded as ACA-OA anastomosis. Only one case of the unilateral type of this variation has been reported, in case that was diagnosed during dissection.

Patients consent

Informed consent was obtained from the patient for publication of the Case Report.

REFERENCES

- [1] Lischka MF, Krammer EB, Rath T, Riedl M, Ellböck E. The human thyrocervical trunk: configuration and variability reinvestigated. *Anat Embryol (Berl)* 1982;163:389–401.

-
- [2] Paraskevas G, Natsis K, Tzika M, Ioannidis O, Kitsoulis P. Abnormal origin of internal thoracic artery from the thyrocervical trunk: surgical considerations. *J cardiothorac Surg* 2012;7:63. doi:10.1186/1749-8090-7-63.
- [3] Strub WM, Leach JL, Tomsick TA. Left vertebral artery origin from the thyrocervical trunk: a unique vascular variant. *AJNR Am J Neuroradiol* 2006;27:1155–6.
- [4] Lasjaunias P, Theron J, Moret J. The occipital artery. Anatomy–normal arteriographic aspect–embryological significance. *Neuroradiol* 1978; 15:31–7.
- [5] Uchino A, Saito N, Mizukoshi W, Okada Y. Anomalous origin of the occipital artery diagnosed by magnetic resonance angiography. *Neuroradiol* 2011;53:853–7. doi:10.1007/s00234-010-0825-z.
- [6] Uchino A, Saito N. Occipital artery arising from the cervical internal carotid artery at the level of the C2 vertebral body: three cases detected utilizing magnetic resonance angiography. *Surg Radiol Anat* 2020;42:831–4. doi:10.1007/s00276-020-02460-4.
- [7] Demirbas AT, Demirtas I, Topcu FS, Karasu S, Ayyildiz B. A rare case report: bilateral occipital artery arising from the vertebral artery. *Surg Radiol Anat* 2021;43:1901–4. doi:10.1007/s00276-021-02842-2.
- [8] Tubbs RS, Salter G, Oakes WJ. Continuation of the ascending cervical artery as the occipital artery in man. *Anat Sci Int* 2004;79:43–5.
- [9] Uchino A. Cervical arterial collateral network. *AJNR Am J Neuroradiol* 2006;27:1161.