

Available online at www.sciencedirect.com

ScienceDirect

journal homepage: www.elsevier.com/locate/radcr

Case Report

Dropped Gallstone Presenting as Recurrent Abdominal Wall Abscess☆

Kaushik Kumar, MD^{a,*}, Christopher J. Haas, MD, PhD^{b,c}^a MedStar Health Internal Medicine Residency Program, Baltimore, MD, USA^b MedStar Health, Department of Internal Medicine, Baltimore, MD, USA^c Georgetown University School of Medicine, Washington, DC, USA

ARTICLE INFO

Article history:

Received 2 March 2022

Revised 11 March 2022

Accepted 12 March 2022

Available online 8 April 2022

Keywords:

Dropped gallstone

Retained gallstone

Recurrent abdominal abscess

Laparoscopic cholecystectomy

Open laparotomy

Magnetic resonance imaging

ABSTRACT

Dropped gallstones are a known complication of laparoscopic cholecystectomy. Rarely, dropped stones may be embedded within the potential intraperitoneal spaces or abdominal wall, mimicking metastatic implants, tuberculosis, peritoneal loose body, actinomycosis, and primary tumors, which when coupled with the fact that most bile stones are radiolucent, leads to diagnostic challenges. Here, we report a case of abdominal wall abscess due to a dropped stone that presented over 15 years after laparoscopic cholecystectomy. An 86-year-old male with laparoscopic cholecystectomy for management of acute cholecystitis complicated by post-cholecystectomy choledocholithiasis over 15 years back presented to the emergency department with intermittent, asymmetric abdominal “bulging” and a reported 16-pound weight loss of 3 months duration. He remained hemodynamically stable and physical examination demonstrated approximately 9 cm × 7 cm, nontender and slightly fluctuant mass appreciable on the right lateral abdominal wall extending to the right flank. Laboratory revealed leukocytosis and elevated lactic acid. Abdominal ultrasound and abdominal computed tomography demonstrated a 10.6 × 7 × 16 cm cystic mass with echogenic debris adjacent to the anterior segment of the right hepatic lobe. The patient presented multiple times with re-accumulation. A drain was subsequently placed and antibiotic therapy initiated with subsequent resolution. Follow-up magnetic resonance imaging revealed a punctate calcification within the abscess pocket. Retained stones should be considered in the differentials of patients presenting with abdominal discomfort and abdominal “masses.” The clinical suspicion must remain high secondary to the potential temporally prolonged presentation, indolent nature of inflammation, and unusual sites of physical manifestations.

© 2022 The Authors. Published by Elsevier Inc. on behalf of University of Washington.

This is an open access article under the CC BY-NC-ND license

(<http://creativecommons.org/licenses/by-nc-nd/4.0/>)

☆ Competing Interest: The authors have declared that no competing interests exist.

* Corresponding author at: Kaushik Kumar, MD, MedStar Health Internal Medicine Residency, 201 E University Pkwy, Baltimore, MD 21218

E-mail address: kaushik.kumar@medstar.net (K. Kumar).<https://doi.org/10.1016/j.radcr.2022.03.044>1930-0433/© 2022 The Authors. Published by Elsevier Inc. on behalf of University of Washington. This is an open access article under the CC BY-NC-ND license (<http://creativecommons.org/licenses/by-nc-nd/4.0/>)

Introduction

While all dropped gallstones occur in the context of gallbladder perforation, secondary to either instrumentation from cholecystectomy or due to rupture of friable mucosa due to inflammation, this complication only occurs in 2%–19% of cases [5–7]. An analysis of 8 studies showed that the incidence of lost or dropped stones is approximately 2%, with secondary complications occurring in only 8.5% of this subset of cases [7]. Patients may present months to years after the original procedure or inciting episode with nonspecific symptoms of colicky abdominal pain, abdominal wall swelling, anorexia, nausea, and fatigue, as secondary manifestations of intra-abdominal abscess, peritonitis, small bowel obstruction, small bowel fistula, and a bowel perforation [1,3,4,6]. Rarely, dropped stones may be embedded within the potential intraperitoneal spaces or abdominal wall, mimicking metastatic implants, tuberculosis, peritoneal loose body, actinomyces, and primary tumors, which when coupled with the fact that most bile stones are radiolucent, leads to diagnostic challenges [2,8,9]. Here, we report a case of abdominal wall abscess due to a dropped stone that presented over 15 years after laparoscopic cholecystectomy and subsequent endoscopic retrograde cholangiopancreatography for management of acute cholecystitis complicated by post-cholecystectomy choledocholithiasis.

Case presentation

An 86-year-old male presented to the emergency department with intermittent, asymmetric abdominal “bulging” and a reported 16-pound weight loss of 3 months duration. The patient reported usual health until approximately 3 months prior, at which time he noted intermittent right lower quadrant abdominal swelling with occasional erythema and discomfort upon palpation. His symptoms were associated with infrequent episodes of nausea, non-bloody, non-bilious

emesis, and non-bloody loose stools that routinely followed the episodes of emesis. He denied fevers or chills, night sweats, diaphoresis, trauma, exposures, or recent travel. His appetite was relatively poorer over these 3 months with early satiety and relative anorexia, but no specific post-prandial abdominal pain. Medical history was notable for hypertension, hyperlipidemia, non-insulin-dependent diabetes mellitus, and laparoscopic cholecystectomy with subsequent endoscopic retrograde cholangiopancreatography for management of acute cholecystitis complicated by post-cholecystectomy choledocholithiasis over 15 years prior. Due to ongoing symptoms, the patient originally presented to his primary physician who ordered a contrast-enhanced computed tomography (CT) scan of the abdomen and pelvis which demonstrated a large fluid collection in the right upper quadrant lateral to the liver with irregular thickened wall as well as a second thick-walled loculated fluid collection localized in the right paracolic gutter lateral to the right colon (Fig. 1), for which he was referred to our hospital.

In the emergency department, the patient was hemodynamically stable. The physical examination demonstrated approximately 9 cm × 7 cm mass appreciable on the right lateral abdominal wall extending to the right flank. The site was nontender to palpation and slightly fluctuant with no tenderness in costovertebral angle or other abdominal quadrants. The overlying skin was erythematous with no pus or drainage. Laboratory investigations revealed leukocytosis (15.2 k/ μ L, range 4.0–10.8 k/ μ L) with neutrophilic predominance (80.1%, range 43.0%–75.0%), mild normocytic anemia (12.2 gm/dL; MCV 92.3 fL), pseudo-hyponatremia in the setting of his elevated glucose, and an elevated lactic acid (4.7 mmol/L, range 0.7–2.0 mmol/L) that subsequently normalized following crystalloid administration. The remainder of the comprehensive metabolic panel and coagulation profile remained within normal limits and blood cultures were drawn. Diagnostic imaging included the reviewed CT and an ultrasound ordered in the emergency department that demonstrated a 10.6 cm × 7 cm × 16 cm cystic mass with echogenic debris adjacent to the anterior segment of the right hepatic lobe. The patient was initiated on ceftriaxone/metronidazole and

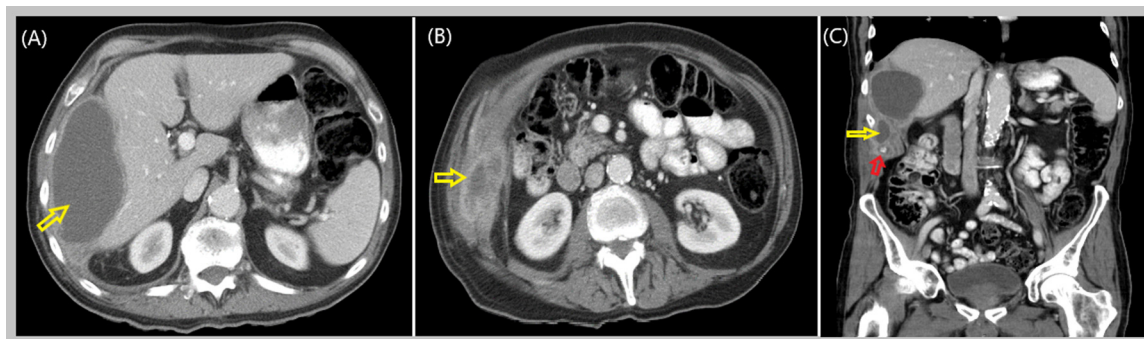


Fig. 1 – Abdominal wall fluid accumulation (abdominal CT). Very large fluid accumulation (yellow arrow in [A] and [B]) in the right upper quadrant lateral to the liver, measuring 12 × 6 × 9 cm, with an irregularly thickened wall as seen on Contrast-enhanced computed tomography. A second thick-walled loculation of fluid extends more inferiorly and laterally to the mid kidney level (yellow arrow in [C]). The second thick-walled collection measures approximately 6 × 4 cm and is located in the right paracolic gutter, lateral to the right colon containing a small focal indeterminate calcification (red arrow in [C]) with no presence of air or gas within the fluid (Color version of figure is available online).

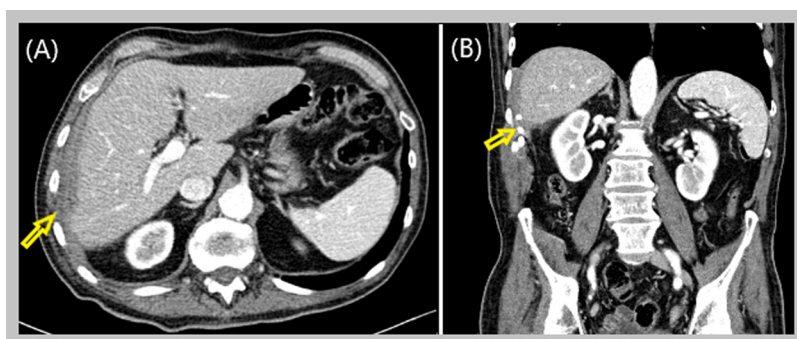


Fig. 2 – CT abdomen (resolved) resolution of right lateral abdominal wall fluid collection. Right lateral abdominal drain in place without significant fluid collection (yellow arrow [B]) (Color version of figure is available online).

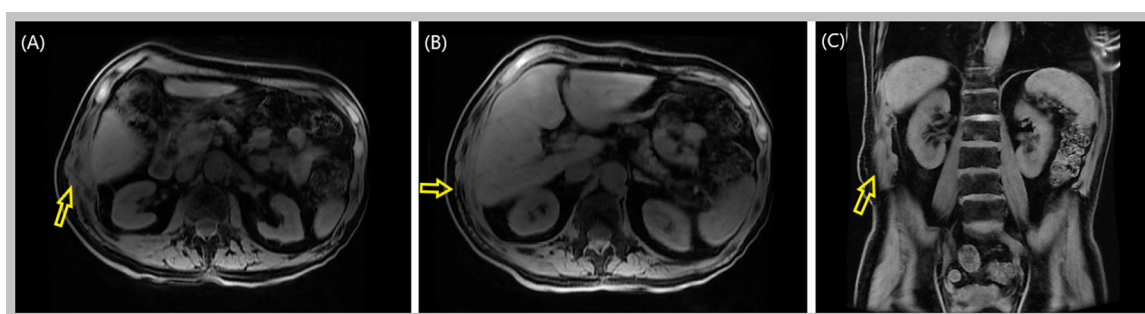


Fig. 3 – Magnetic resonance imaging. Interval appearing surgical drain crossing the right lateral abdominal wall (yellow arrow in [A]) with previously seen perihepatic abscess essentially resolved with only trace curvilinear hemorrhagic fluid in the perihepatic space and minimal curvilinear fluid. Also visualized is mild soft-tissue edema in the right lateral abdominal wall, however, almost resolved compared to the prior images (Color version of figure is available online).

Interventional Radiology was consulted with the aspiration of 300 mL of purulent appearing fluid. Blood cultures and aspirate culture remained negative and the patient was discharged with follow-up with Interventional Radiology and Colorectal Surgery, off antibiotic therapy. Subsequently, aspirate culture demonstrated positivity for *Klebsiella pneumoniae*, however in the setting of clinical stability and only scant growth, antibiotics were deferred.

Two weeks later, the patient presented with recurrent symptoms of swelling and nausea and was found to have recurrent fluid accumulation for which an ultrasound-guided intraperitoneal drainage catheter was placed. Drainage cultures continued to demonstrate scant growth of *Klebsiella pneumoniae* for which he was initiated on oral Ciprofloxacin with symptom resolution. Follow-up CT, 1 month later, demonstrated resolution of the right lateral abdominal wall fluid collection, and the catheter was removed (Fig. 2). Unfortunately, 10 days after catheter removal, the patient represented with recurrent abdominal swelling and imaging once again demonstrating recurrent abscess accumulation. A 12-French drainage catheter was placed into the right perihepatic abscess and cultures once again speciated *Klebsiella pneumoniae*. He was discharged with the drainage catheter in place and on oral ciprofloxacin with plans to follow up with colorectal surgery following outpatient magnetic resonance imaging

(MRI). MRI was obtained 2 weeks later and demonstrated marked improvement of the right perihepatic intraperitoneal abscess, residual peritoneal thickening with muscular enhancement, and a punctate T2 hyperintense focus in the abdominal wall musculature, suggestive of calcification. The patient continued to drain up to 15 mL of thick, purulent fluid daily and he was placed on Trimethoprim-sulfamethoxazole given *Klebsiella* sensitivity and seeming failure of the prior antibiotic regimen. Repeat MRI 1 month later demonstrated complete abscess resolution with mild soft tissue edema and no abdominal adenopathy (Fig. 3).

Discussion

Most individuals with dropped gallstones are asymptomatic; however, severe symptoms and complications develop in approximately 1%-3% of asymptomatic or mildly symptomatic patients annually [1]. Symptoms, as in our patients' case, are usually vague—abdominal pain, abdominal wall tenderness, nausea, vomiting, and weight loss—and may mimic malignancy [10–12]. The presentation is unusual given that the temporal relationship between the dropped stone and presentation of symptoms predominantly ranges from 3 to 36 months; [13] our patient presented over 15 years after laparoscopic

cholecystectomy. Furthermore, our patient experienced recurrent intraabdominal fluid collection despite initial adequate drainage which was closely associated with the recurrence of his symptoms. Intriguingly, in a retrospective study of 3686 patients who underwent laparoscopic cholecystectomy, 254 (6.9%) patients experienced dropped gallstones, and in up to 2.4% of total laparoscopic cholecystectomy cases, spilled gallstones remained unretrieved [14].

Ultrasound and contrast-enhanced Computed Tomography remain the best diagnostic tools to identify the size and anatomical relationships to adjacent organs. However, since most gallstones are radiolucent with low calcium content, direct visualization remains technically challenging. This is further complicated by the development of chronic inflammation, which may lead to calcification, further obscuring stone identification on diagnostic imaging [15–17], as in our patient's case. The majority of dropped gallstones are infected (80%–90% of stones are colonized by *E. coli* and *K. pneumoniae*) and are walled off by the initial local inflammatory reaction and the momentum [13,18]. An inflammatory response is expected however, it is interesting to note that the presentation of the dropped stone, in this case, was delayed by 15 years from the inciting laparoscopic cholecystectomy.

Retained stone extraction depends on the site, extent, and patient's fitness for surgery. Superficial abscesses can be evacuated percutaneously, whereas deeper abscesses may require electrohydraulic lithotripsy and flexible endoscopy [19]. Deep-seated abscesses and larger stones may also require an exploratory approach [19,20]. Abscesses due to dropped gallstones are notorious for re-accumulation despite complete percutaneous drainage, with the gallstone acting as a nidus of infection [21]. Larger stones (>1 cm) may be fragmented by ultrasonic lithotripsy and rigid endoscopy. On review of literature, laparoscopic extraction is recommended when percutaneous techniques fail or are unsuitable. Post-operatively, antibiotics are often recommended, and the presence of unretrieved gallstones should be documented in the patient's chart and information relayed to the patient and primary care. In a series of 22 patients with documented dropped gallstone longitudinally evaluated for a median of 121 months postoperatively, no important clinical or CT abnormalities were noted [20,22].

Conclusion

The diagnosis of abdominal abscess due to dropped gallstone is rare and their presentation may occur months to years after initial cholecystectomy due to their clinically indolent nature. It is also important to note that dropped stones may contribute to significant morbidity due to their recurrent nature. In most cases, dropped stones remain a diagnostic challenge as it is often not detailed in the operative notes. Nevertheless, dropped gallstones should always be considered in the differentials for recurrent abdominal abscess in a patient with a surgical history of cholecystectomy, particularly laparoscopic cholecystectomy. Clinical presentation with vague and non-specific symptoms without any obvious cause underscores the need for a broad differential and careful history. The man-

agement of dropped gallstones includes antibiotics, abscess drainage, and attempts to remove stones definitively. Stone retrieval is often warranted, yet given the radiolucent nature of most stones, timely removal remains a clinical challenge.

Disclosure

Informed consent was obtained for the case report, images, and publication.

Patient consent

Consent for publication has been obtained and the individual who is being reported on is aware of the possible consequences of that reporting.

REFERENCES

- [1] Ologun GO, Lovely R, Sultany M, Aman M. Retained gallstone presenting as large intra-abdominal mass four years after laparoscopic cholecystectomy. *Cureus* 2018.
- [2] Capolupo GT, Mascianà G, Carannante F, Caricato M. Spilled gallstones simulating peritoneal carcinomatosis: a case report and literature review. *Intl J Surg Case Rep* 2018;48.
- [3] Awwad A, Mulholland K, Clements B. Abdominal abscess due to retained gallstones 5 years after laparoscopic cholecystectomy. *BMJ Case Rep* 2010.
- [4] Sato S, Inoue A, Ota S, Furukawa A, Miyagawa Y, Wakamiya M, et al. Foreign-body granulomas and abscesses caused by dropped gallstones after cholecystectomy: Four cases diagnosed with multimodality imaging. *Radiol Case Rep* 2020;15.
- [5] Singh K, Wang ML, Ofori E, Widmann W, Alemi A, Nakaska M. Gallstone abscess as a result of dropped gallstones during laparoscopic cholecystectomy. *Intl J Surg Case Rep* 2012;3.
- [6] Murphy S, Hebert J, Leavitt B. A complicated abscess from a dropped gallstone. *J Surg Case Rep* 2019;2019.
- [7] Zehetner J, Shamiyeh A, Wayand W. Lost gallstones in laparoscopic cholecystectomy: all possible complications. *Am J Surg* 2007;193.
- [8] Karabulut N, Tavasli B, Kiroğlu Y. Intra-abdominal spilled gallstones simulating peritoneal metastasis: CT and MR imaging features (2008: 1b). *Eur Radiol* 2008;18.
- [9] Ramia JM, Mansilla A, Villar J, Muffak K, Garrote D, Ferron JA. Retroperitoneal actinomycosis due to dropped gallstones. *Surg Endoscopy* 2004.
- [10] Garaud S, Stolz A. Dropped gallstones mimicking peritoneal metastasis: a case report. *Radiol Case Rep* 2018;13.
- [11] Atri M, Bonifacio A, Ryan M, Pilleul FL, Hanbidge A, Clark J, et al. Dropped gallstones post laparoscopic cholecystectomy mimicking peritoneal seeding: CT and ultrasound features. *J Comput Assisted Tomogr* 2002;26.
- [12] Sathesh-Kumar T. Spilled gall stones during laparoscopic cholecystectomy: a review of the literature. *Postgraduate Med J* 2004;80.
- [13] Woodfield JC, Rodgers M, Windsor JA. Peritoneal gallstones following laparoscopic cholecystectomy: incidence, complications, and management. *Surg Endoscopy* 2004;18.

-
- [14] Diez J, Arozamena C, Gutierrez L, Bracco J, Mon A, Almeyra RS, et al. Lost stones during laparoscopic cholecystectomy. *HPB Surg* 1998;11.
- [15] Jamil Y, Reading DN. Learning from the radiological findings of dropped gall stone and/or appendicolith (its complication and management strategy). *BJR Case Rep* 2019;5.
- [16] Choi JY, Kim MJ, Park MS, Kim JH, Lim JS, Oh YT, et al. Imaging findings of biliary and nonbiliary complications following laparoscopic surgery. *Eur Radiol* 2006.
- [17] Nooghabi AJ, Hassanpour M, Jangjoo A. Consequences of lost gallstones during laparoscopic cholecystectomy: a review article. *Surg Laparoscopy Endoscopy Percutaneous Tech* 2016.
- [18] Horton M, Florence MG. Unusual abscess patterns following dropped gallstones during laparoscopic cholecystectomy. *Am J Surg* 1998;175.
- [19] Trerotola SO, Lillemoe KD, Malloy PC, Osterman FA. Percutaneous removal of “dropped” gallstones after laparoscopic cholecystectomy. *Radiology* 1993;188.
- [20] Ramamurthy NK, Rudralingam V, Martin DF, Galloway SW, Sukumar SA. Out of sight but kept in mind: complications and imitations of dropped gallstones. *Am J Roentgenol* 2013;200.
- [21] Nayak L, Menias CO, Gayer G. Dropped gallstones: Spectrum of imaging findings, complications and diagnostic pitfalls. *British J Radiol* 2013.
- [22] Manukyan MN, Demirkalem P, Gulluoglu BM, Tuney D, Yegen C, Yalin R, et al. Retained abdominal gallstones during laparoscopic cholecystectomy. *Am J Surg* 2005;189.