



Case Report

Successful immunomodulation in kidney transplant recipients with cytokine release syndrome after coronavirus disease

Daiji Takamoto,^{1,†} Hajime Sasaki,^{1,†}  Hiroshi Kataoka,² Fumihiro Kodama,³ Haruka Higuchi,¹ Tetsuo Hirano,¹ Yusuke Takada,¹ Shigeru Harada,¹ Hiroshi Harada¹  and Hiroshi Tanaka^{1,4}

Department of ¹Kidney Transplant Surgery, ²Rheumatology and Clinical Immunology, ³Infectious Diseases, and ⁴Urology, Sapporo City General Hospital, Sapporo, Japan

Abbreviations & Acronyms

COVID-19 = coronavirus disease 2019

CRP = C-reactive protein

CRS = cytokine release syndrome

CT = computed tomography

DEX = dexamethasone

EVR = everolimus

FPV = favipiravir

GGO = ground-glass opacities

IL-6 = interleukin-6

LDH = lactate dehydrogenase

MMF = mycophenolate mofetil

MP = methylprednisolone

mPSL = methylprednisolone

PCR = polymerase chain reaction

SARS-CoV-2 = severe acute respiratory syndrome coronavirus 2

SOT = solid organ transplant

TAC = tacrolimus

TCZ = tocilizumab

Introduction: Patients with coronavirus disease, especially solid organ transplant recipients, are more susceptible to developing cytokine release syndrome than those with other viral infections. However, currently, treatment methods for such patients have not been established. Here, we describe two cases of successful immunomodulation in Japanese kidney transplant recipients with cytokine release syndrome following coronavirus disease.

Case presentation: Two patients who had been receiving long-term immunosuppressant therapy developed coronavirus disease-associated pneumonia caused by cytokine release syndrome, following immunosuppressant dosage reduction. However, they recovered immediately after administration of tocilizumab with or without dexamethasone.

Conclusion: The immunosuppressant dosage should be reduced to restore host immunity; however, immunomodulation should be considered in cases of suspected cytokine release syndrome.

Key words: COVID-19, cytokine release syndrome, dexamethasone, kidney transplant recipient, tocilizumab.

Correspondence: Hajime Sasaki M.D., Ph.D., Kita 11-jo, Nishi 13-chome, Chuo-ku, Sapporo 060-8604, Japan. Email: hajimes1207@hotmail.com

How to cite this article: Takamoto D, Sasaki H, Kataoka H *et al.* Successful immunomodulation in kidney transplant recipients with cytokine release syndrome after coronavirus disease. *IJU Case Rep.* 2022; 5: 373–377.

This is an open access article under the terms of the Creative Commons Attribution-NonCommercial License, which permits use, distribution and reproduction in any medium, provided the original work is properly cited and is not used for commercial purposes.

Received 8 January 2022; accepted 26 May 2022.

Online publication 24 June 2022

†These authors contributed equally to the manuscript.

Keynote message

We report the cases of two kidney transplant recipients with coronavirus disease who developed cytokine release syndrome upon reduction of immunosuppressive therapy; both recovered following administration of tocilizumab with or without dexamethasone.

Introduction

Treatment of COVID-19 in SOT recipients is complicated and remains unestablished. COVID-19 patients, especially transplant recipients, are more susceptible to CRS than those with other viral infections.¹ Here, we report the cases of two COVID-19 patients who underwent renal transplantation and developed CRS after the immunosuppressive therapy dosage was reduced. The patients' conditions improved after administration of suitable immunomodulatory agents.

Case presentation

Case 1

A 60-year-old man who had undergone ABO-compatible kidney transplantation for kidney failure due to chronic glomerular nephritis 7 years earlier was admitted to our hospital with high-grade fever. To avoid steroid-related complications, immunosuppressive therapy was administered without mPSL using TAC, MMF, and EVR. His CRP level was elevated to 7.74 mg/dL, and CT showed pulmonary ground-glass shadows in both lung fields, leading to a suspected COVID-19 diagnosis. Although he had no positive contact history, the PCR test result was positive for SARS-CoV-2. He was diagnosed with mild COVID-19, as his

peripheral oxygen saturation was 94%, and he was not dyspneic. Based on treatment guidance for COVID-19 in SOT recipients, the MMF dose was immediately reduced from 1000 to 500 mg/day; however, TAC 2.5 mg/day and EVR 1 mg/day were continued. FPV, initiated at 3600 mg/day on day 1, was continued at 1600 mg/day from day 2. On day 6, TAC was reduced to 1 mg/day because CT demonstrated worsening pneumonia (Fig. 1a); his CRP level increased to 30.87 mg/dL, and fever did not improve on day 7. CRS caused high-grade inflammation; hence, we decided to administer TCZ (8 mg/kg body weight). Moreover, elevated LDH and D-dimer levels were observed, whereas no bacterial or other viral pneumonia was detected, supporting a diagnosis of CRS. Corticosteroids were not administered because this case occurred before the Japanese Clinical Practice Guidelines for Management of Sepsis and Septic Shock 2020 strongly recommended the administration of corticosteroids in moderate and severe COVID-19 patients. The following day, the patient's fever rapidly improved, and his CRP level decreased to 11.49 mg/dL. Subsequently, his CRP level improved to 1.74 mg/dL, and he was discharged on day 13 (Fig. 2a).

Case 2

A 50-year-old woman who had undergone cadaveric kidney transplant for kidney failure due to focal segmental glomerulosclerosis 9 years earlier was admitted to our hospital. Her son, who lived with her, tested positive for COVID-19; thus, she underwent a SARS-CoV-2 PCR test despite displaying no symptoms and also tested positive. CT showed mild

COVID-19-associated pneumonia. To prevent the original disease from recurring, the patient was administered TAC, MMF, EVR, and mPSL. She had no specific symptoms until day 7; hence, she was followed up without reducing the immunosuppression therapy dosage. On day 8, she developed high-grade fever, and by day 12, her CRP level had increased to 6.41 mg/dL. She presented with COVID-19-associated pneumonia symptoms, and the MMF dose was immediately reduced from 750 to 250 mg/day; however, TAC, EVR, and mPSL were continued. On day 14, CT showed worsening pneumonia (Fig. 1b), and intranasal oxygen was administered. Moreover, elevated CRP (8.13 mg/dL) and elevated LDH and D-dimer levels were observed; however, no bacterial or other viral pneumonia was noted. CRS caused high-grade inflammation despite administration of mPSL as an anti-inflammatory agent; thus, we decided to administer TCZ (8 mg/kg body weight) and DEX (6.6 mg/day) on day 17. The patient's fever rapidly improved the following day; her SpO₂ level was within normal limits without needing further oxygen support, and the CRP level decreased to 1.86 mg/dL (Fig. 2b). Unlike in case 1, CRS may have occurred before MMF reduction in case 2, as high-grade fever and increased CRP levels were observed. Reducing MMF in the late stages following SARS-CoV-2 infection may have exacerbated the CRS. Finally, anti-SARS-CoV-2 antibodies were observed in the patient; however, they were not detected before MMF reduction. Therefore, we believe that reducing the immunosuppressive regimen affects the restoration of host immunity. The immunosuppressive maintenance protocol in these cases was almost similar to that in a previously reported case.²

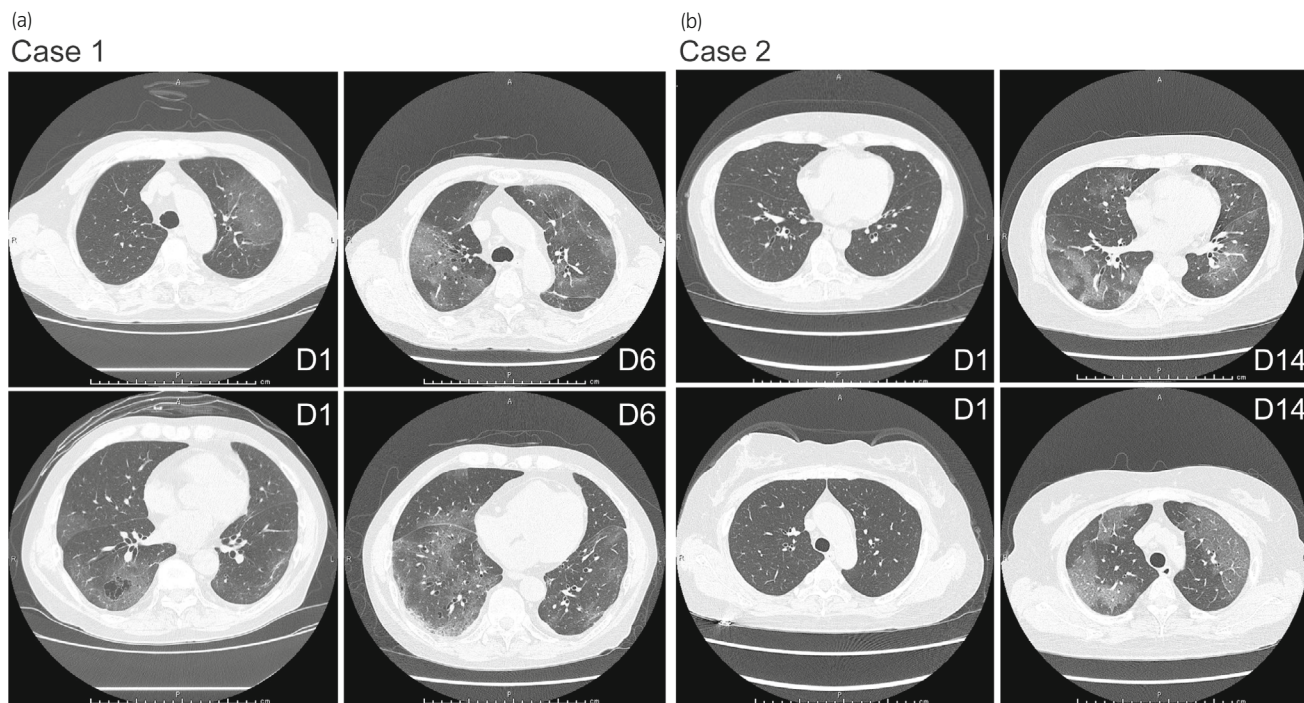


Fig. 1 Chest CT images. (a) In case 1, CT obtained on day 1 after admission shows left upper lobe and peripheral GGOs. Follow-up chest CT images obtained on day 6 after admission show worsening of pneumonia in the lower lung fields. (b) In case 2, CT images obtained on day 1 after admission show almost no findings of pneumonia. Follow-up chest CT images obtained on day 14 after admission show worsening of pneumonia in the lower lung fields.

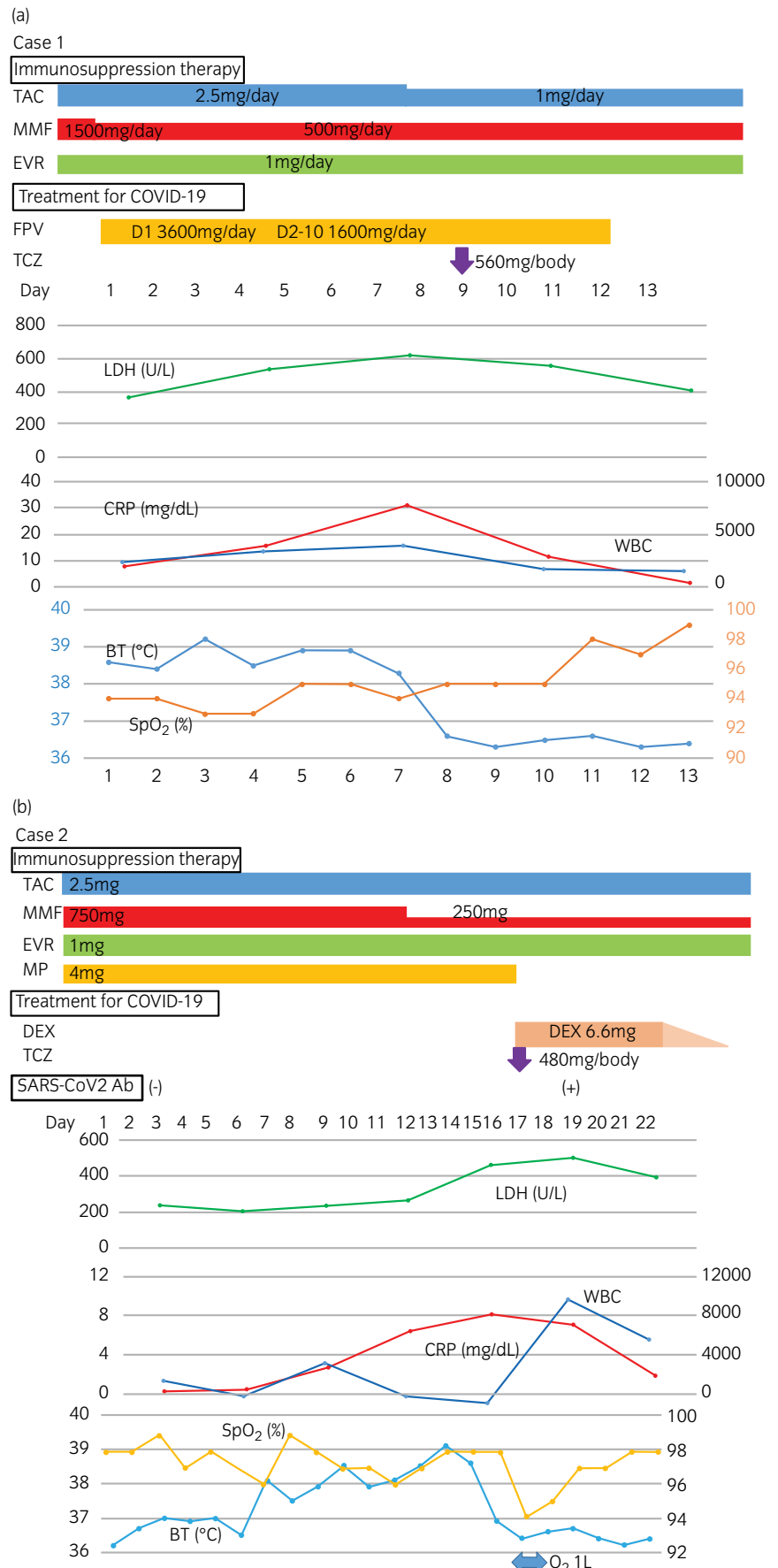


Fig. 2 Clinical course in case 1 and case 2. (a) Clinical course in case 1. (b) Clinical course in case 2.

Discussion

In the early stages following SARS-CoV-2 infection, high immunosuppression can impair adequate induction of specific immunity, resulting in lack of viral-load control. However, in the latter stages of the disease, immunosuppressive medications are beneficial in suppressing pro-inflammatory processes.³ There are concerns that additional immunosuppressive drug withdrawal may exacerbate the hyper-inflammatory response and CRS, a consequence of the imbalance in the host response, comprising low interferon expression and high pro-inflammatory cytokine expression,⁴ that may occur in the late stages of COVID-19. Although remdesivir is the antiviral drug of choice against COVID-19,⁵ treating symptomatic COVID-19 in kidney transplant recipients with chronic kidney disease with this drug appears challenging. Therefore, progressive decrease in immunosuppression depending on the clinical severity may be appropriate² for the patient to acquire immunity against COVID-19. Given that IL-6 is elevated in patients with COVID-19, several studies^{6,7} have investigated whether inhibiting IL-6 by blocking the IL-6 receptor with TCZ could have beneficial effects. A case-control study of 117 recipients in the United States showed that TCZ alone was not linked to decreased mortality.⁸ However, in hospitalized patients with severe COVID-19 who are hypoxic and have a high CRP level, current evidence favors the use of combined TCZ and corticosteroids to reduce mortality.^{9,10} We defined CRS in SOT recipients as follows: high fever, inflammatory markers (such as LDH and D-dimer), and elevated CRP levels after reduction of immunosuppressive therapy and after other types of infectious pneumonia were excluded.¹¹ According to current clinical question and answer from the American Society of Transplantation, cell cycle inhibitors should be reduced or discontinued in the early phases of COVID-19. However, we recommend that immunomodulation treatment be provided upon CRS diagnosis in cases such as ours without testing for specific markers, such as IL-6, as such may impede a timely diagnosis.

An advantage of our study is that we showed that CRS can be detected in an immunocompromised host without testing for specific inflammatory molecules. However, the limitation is that we considered only two cases, using limited immunomodulatory agents.

The question arises whether immunosuppressive therapy should be discontinued in more severe cases. For such cases, we believe that complete discontinuation of calcineurin inhibitors and/or mammalian target of rapamycin inhibitors in addition to MMF should be avoided and that steroid administration should be continued because complete discontinuation of immunosuppressive agents can precipitate or exacerbate CRS and cause acute rejection of the kidney graft. Larger, randomized studies are required to identify agents that have a positive impact on CRS in SOT recipients post-COVID-19.

Conclusion

We reported two cases of CRS, post-COVID-19, in kidney transplant recipients managed with TCZ with or without

DEX. We recommend that the dose of immunosuppression therapy be reduced to ensure acquisition of host immunity; however, immunomodulation should be promptly considered if CRS occurs or is exacerbated after reduced immunosuppression.

Acknowledgment

We thank Editage for editing the draft of this manuscript.

Author contributions

Daiji Takamoto: Conceptualization; data curation; investigation; visualization; writing – original draft. Hajime Sasaki: Conceptualization; data curation; investigation; validation; visualization; writing – original draft; writing – review and editing. Hiroshi Kataoka: Conceptualization; data curation; investigation; methodology; validation; writing – review and editing. Fumihiro Kodama: Conceptualization; data curation; investigation; methodology; writing – review and editing. Haruka Higuchi: Conceptualization; data curation; investigation; writing – review and editing. Tetsuo Hirano: Conceptualization; data curation; investigation. Yusuke Takada: Conceptualization; data curation; investigation. Shigeru Harada: Conceptualization; data curation; investigation. Hiroshi Harada: Supervision; writing – review and editing. Hiroshi Tanaka: Conceptualization; data curation; investigation; supervision.

Conflict of interest

The authors declare no conflict of interest.

Approval of the research protocol by an Institutional Reviewer Board

The protocol for this research project has been approved by the Ethics Committee of Sapporo City General Hospital (approval no. R03-060-878).

Informed consent

Informed consent was obtained from the patients for publication of this case report.

Registry and the registration no. of the study/trial

Not applicable.

References

- 1 Fajgenbaum DC, June CH. Cytokine storm. *N. Engl. J. Med.* 2020; **383**: 2255–73.
- 2 Endo T, Ishimura T, Nishioka S, Yokoyama N, Ogawa S, Fujisawa M. No influence of everolimus on mycophenolic acid area under the concentration-time curve: limited sampling strategy for mycophenolic acid in Japanese kidney transplant recipients treated with tacrolimus, mycophenolate mofetil, steroid, and everolimus. *Transplant. Proc.* 2022; **54**: 286–92.

- 3 Danziger-Isakov L, Blumberg EA, Manuel O, Sester M. Impact of COVID-19 in solid organ transplant recipients. *Am. J. Transplant.* 2021; **21**: 925–37.
- 4 Blanco-Melo D, Nilsson-Payant BE, Liu WC *et al.* Imbalanced host response to SARS-CoV-2 drives development of COVID-19. *Cell* 2020; **181**: 1036–45.e9.
- 5 McCreary EK, Angus DC. Efficacy of remdesivir in COVID-19. *JAMA* 2020; **324**: 1041–2.
- 6 Xu X, Han M, Li T *et al.* Effective treatment of severe COVID-19 patients with tocilizumab. *Proc. Natl. Acad. Sci. USA* 2020; **117**: 10970–5.
- 7 Biran N, Ip A, Ahn J *et al.* Tocilizumab among patients with COVID-19 in the intensive care unit: a multicentre observational study. *Lancet Rheumatol.* 2020; **2**: e603–12.
- 8 Pereira MR, Aversa MM, Farr MA *et al.* Tocilizumab for severe COVID-19 in solid organ transplant recipients: a matched cohort study. *Am. J. Transplant.* 2020; **20**: 3198–205.
- 9 RECOVERY Collaborative Group. Tocilizumab in patients admitted to hospital with COVID-19 (RECOVERY): a randomised, controlled, open-label, platform trial. *Lancet* 2021; **397**: 1637–45.
- 10 Kataoka H, Kodama F, Tomita T *et al.* Immediate amelioration of severe respiratory distress in Sjogren's syndrome with COVID-19 treated with a single dose of off-label tocilizumab. *Intern. Med.* 2021; **60**: 639–43.
- 11 Preeti M, Urvish P, Deep M *et al.* Biomarkers and outcomes of COVID-19 hospitalisations: systematic review and meta-analysis. *BMJ Evid. Based Med.* 2021; **26**: 107–8.