


Case Report

Extramedullary plasmacytoma of the ureter

Shuhei Okada,  Yasushi Ichimura and Masahiro Inuma 

Department of Urology, Mito Medical Center, Higashiibaraki-gun, Ibaraki-ken, Japan

Abbreviations & Acronyms

AMY = amylase
 CT = computed tomography
 EAU = European Association of Urology
 EMP = extramedullary plasmacytoma
 Ig = immunoglobulin
 SBP = solitary bone plasmacytoma
 T-BIL = total bilirubin
 UC = urothelial carcinoma
 UTUC = upper tract urothelial carcinoma

Correspondence: Masahiro Inuma, M.D., Department of Urology, Mito Medical Center, 280 Sakuranosato, Ibaraki-machi, Higashiibaraki-gun, Ibaraki-ken 311-3193, Japan. Email: iinuma.masahiro.nv@mail.hosp.go.jp

How to cite this article: Okada S, Ichimura Y, Inuma M. Extramedullary plasmacytoma of the ureter. *IJU Case Rep.* 2022; 5: 19–22.

This is an open access article under the terms of the Creative Commons Attribution-NonCommercial-NoDerivs License, which permits use and distribution in any medium, provided the original work is properly cited, the use is non-commercial and no modifications or adaptations are made.

Received 26 July 2021;
 accepted 30 August 2021.
 Online publication 16 September 2021

Introduction: We report a rare case of an extramedullary plasmacytoma of the ureter.

Case presentation: A 77-year-old man was referred to our hospital because of left hydronephrosis. Computed tomography showed a tumor in the left ureter, and tumor invasion into the periureteric fat was suspected. Urine cytology showed atypical cells whose nuclei were hyperchromatic (class IIIb). The left ureteral tumor was diagnosed as urothelial carcinoma (cT3N0M0) preoperatively. Subsequently, we performed laparoscopic radical nephroureterectomy with bladder cuff excision. The tumor was pathologically diagnosed as a plasmacytoma. Postoperative positron emission tomography did not reveal abnormal uptake, and bone marrow aspiration findings were normal. Consequently, the left ureter tumor was diagnosed as an extramedullary plasmacytoma of the ureter.

Conclusion: Extramedullary plasmacytoma commonly occurs in the upper respiratory tract or upper gastrointestinal tract. Extramedullary plasmacytoma of the ureter is rare. This is only the fourth reported case of extramedullary plasmacytoma of the ureter.

Key words: extramedullary plasmacytoma, hydronephrosis, tumor, ureter, urothelial carcinoma.

Keynote message

The ureter is a rare location for an EMP. Therefore, preoperative diagnosis is challenging. To the best of our knowledge, this is only the fourth reported case of EMP of the ureter.

Introduction

Solitary plasmacytoma is defined as a localized mass of neoplastic monoclonal plasma cells. EMP arises from soft tissue throughout the body. An EMP often occurs in the upper respiratory or gastrointestinal tract, accounting for approximately 80% of cases.¹ The ureter is a rare location for an EMP. Here, we report a case of a primary EMP of the ureter.

Case presentation

A 77-year-old man who presented with abdominal pain was referred to our hospital because an ultrasound sonogram revealed left hydronephrosis. The patient's height was 165.5 cm and his body weight was 55.45 kg. The patient's medical history included constipation, hyperuricemia, benign prostatic hyperplasia, auditory disturbance, and lower back pain. The patient's regular medications included elobixibat hydrate, febuxostat, silodosin, loxoprofen sodium hydrate, and senna. Regarding family history, the patient's father died of lung cancer and his mother died of unknown causes. The patient had smoked 20 cigarettes per day for 10 years. CT revealed a tumor in the left ureter with a diameter of approximately 2.5 cm (Fig. 1). Tumor invasion into the periureteric fat was suspected. Distant metastasis and regional node involvement were not found on CT. Urine cytology showed atypical cells whose nuclei were hyperchromatic (class IIIb). UC was suspected. The left ureteral tumor was diagnosed as UC (cT3N0M0) preoperatively.

An increased level of creatinine was observed (1.96 mg/dL). Laboratory findings are shown in Table 1. This renal impairment was partly due to atrophy of the right kidney. Segmental ureterectomy was considered to be challenging because the diameter of the left ureteral tumor was approximately 2.5 cm and tumor invasion into the periureteric fat was suspected. Subsequently, we performed laparoscopic radical nephroureterectomy with bladder cuff excision.

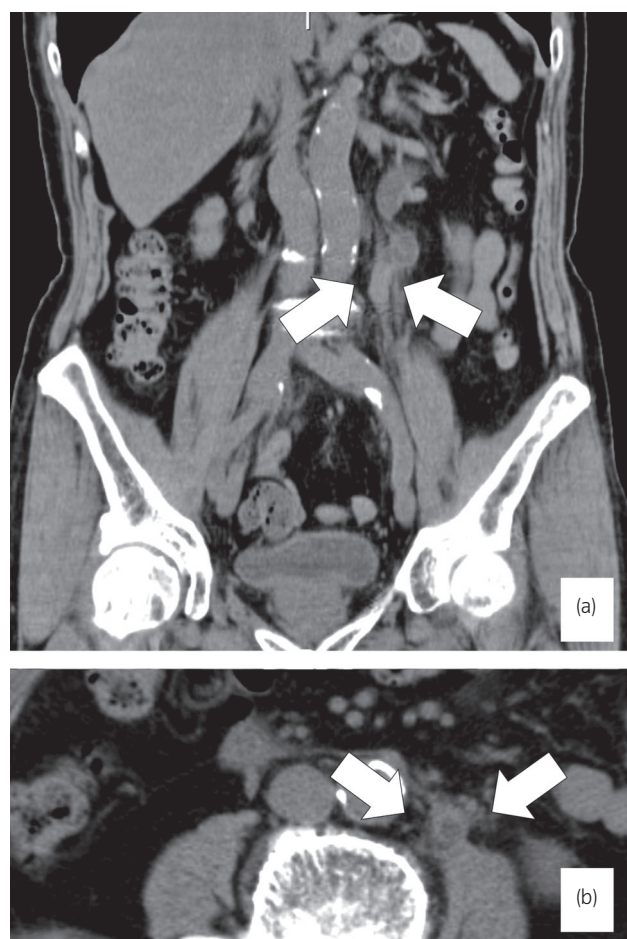


Fig. 1 Abdominal CT image showing a left ureteral mass (arrows) causing hydronephrosis. (a) Coronal view. (b) Axial view.

Table 1 Laboratory findings

TP	7.4	g/dL	WBC	5200	/μL
ALB	4.1	g/dL	RBC	4.12×10^6	/μL
AST	14	U/L	Hb	12.1	g/dL
ALT	8	U/L	Ht	36.5	%
ALP	281	U/L	MCV	88.6	fL
LDH	179	U/L	MCH	29.4	pg
T-BIL	0.5	mg/dL	MCHC	33.2	g/dL
BUN	26.1	mg/dL	PLT	256×10^3	/μL
CRE	1.96	mg/dL	PT	13.8	sec
UA	6.4	mg/dL	PT(INR)	1.05	
AMY	48	IU/L	APTT	38.5	sec
Na	140	mmol/L			
K	4.8	mmol/L			
Cl	108	mmol/L			
Ca	9.0	mg/dL			
CRP	0.49	mg/dL			

Although the serum creatinine level increased to 3.75 mg/dL after surgery, hemodialysis was not required. He was discharged on postoperative day 13. Macroscopically, a solid tumor (20 × 15 mm) was observed in the middle of the left ureter. Histopathological findings revealed inflammatory cell

infiltration and atypical cells, which included numerous eosinophil granules (Fig. 2). No UC component was observed in the tumor. Immunohistochemical staining revealed that atypical cells were positive for CD138 and CD79a, characteristic markers of B cells or plasma cells. In addition, we detected light chain restriction (Igκ > Igγ). Therefore, the left ureter tumor was pathologically diagnosed as a plasmacytoma.

After the diagnosis of EMP, the patient was referred to a hematologist. A postoperative positron emission tomography scan did not show abnormal uptake, and bone marrow aspiration findings were normal. No monoclonal protein was detected in the patient's blood and urine. Therefore, we diagnosed the left ureter tumor as a primary EMP of the ureter. The patient survived without renal replacement therapy and showed no evidence of multiple myeloma, local recurrence, or distant metastasis until 22 months after surgery.

Discussion

Solitary plasmacytoma is defined as a localized mass of neoplastic monoclonal plasma cells. SBP is characterized by a sole lesion of bone. EMP arises from soft tissue throughout the body.¹ The International Myeloma Working Group defines EMP using the following criteria: (i) a tumor comprising of monoclonal plasma cells in a single extramedullary site, (ii) no lesion in the whole-body bone, (iii) no lesion in the bone marrow, (iv) no involvement of organs, and (v) no monoclonal Ig in serum or urine.² Since our patient met the above criteria, the left ureter tumor was diagnosed as a primary EMP of the ureter. An EMP usually occurs in the upper respiratory or gastrointestinal tract, accounting for approximately 80% of cases.³ The ureter is a rare location for an EMP. To the best of our knowledge, this is only the fourth reported case of EMP of the ureter (Table 2). Compared with EMP, SBP has a significantly higher risk for progression to multiple myeloma than EMP. Therefore, SBP has poor prognosis in comparison with EMP. Symptoms of EMP vary depending on the tumor occurrence site. Alexiou *et al.*⁴ reported approximately 65% of EMP had no recurrence and did not progress to multiple myeloma after treatment. Younger age was reported as a good independent prognostic factor.⁵ In contrast, anaplastic type plasmacytoma, a higher histologic grade, and a high level of angiogenesis were reported as poor prognostic factors.^{6,7} Solitary plasmacytoma is highly radiosensitive. It has been reported that a local control rate of 94% was achieved by doses over 40 Gy.⁸ Radiotherapy should encompass the primary tumor with a margin of at least 2 cm.⁹ Adjuvant chemotherapy might be considered for the tumor larger than 5 cm and/or of a high histological grade.

Complete resection of EMP is considered equivalent to radiotherapy. Since EMP is a highly radiosensitive tumor, postoperative radiotherapy is recommended for patients with inadequate surgical margins or local recurrence. Our case was diagnosed as a UC before surgery. As the diameter of the left ureteral tumor was approximately 2.5 cm and tumor invasion into the periureteric fat was suspected, segmental ureteral resection was considered challenging; therefore, we performed laparoscopic radical nephroureterectomy with bladder cuff excision. Although Landsmann *et al.*¹⁰ reported segmental ureter resection and ureterocystostomy for an EMP of the

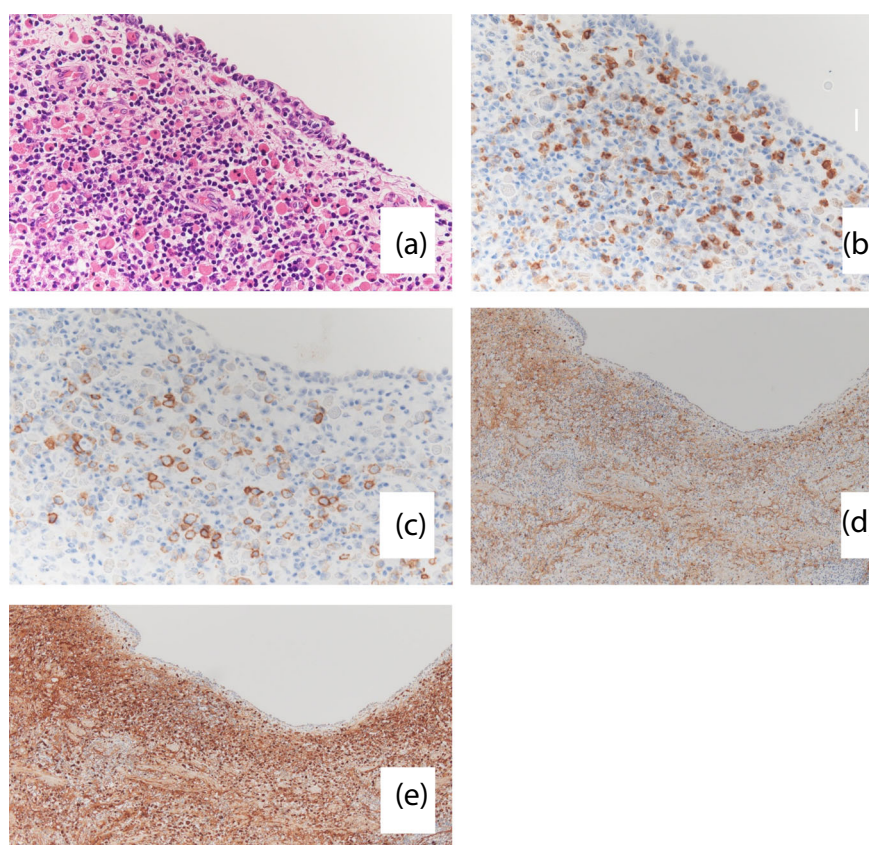


Fig. 2 Hematoxylin and eosin staining showing (a) inflammatory cell infiltration and atypical cells, which include numerous eosinophil granules, and tumor cells positive for (b) CD79a, (c) CD138, (d) Igλ, and (e) Igκ. Staining is more pronounced for Igκ than for Igλ (light chain restriction). Magnification, $\times 100$.

Table 2 Clinical features of reported cases of EMP of the ureter

Case number	1	2	3	4
Authors	Landsmann S	Klein T	Nagai T	Okada S
Year	2009	2010	2016	2021
Age	80	82	45	77
Sex	Female	Female	Male	Male
Chief complaint	Renal colic	Hematuria	Hematuria	Abdominal pain
Preoperative ureteroscopy	Not mentioned	Not performed	Not performed	Not performed
Preoperative diagnosis	Not mentioned	Not mentioned	UC (cT2N0M0)	UC (cT3N0M0)
Treatment	Segmental ureterectomy	Nephro-ureterectomy (open)	Nephro-ureterectomy (laparoscopic)	Nephro-ureterectomy (laparoscopic)
Follow-up (months)	Not mentioned	Not mentioned	5	22
Postoperative dialysis	Not required	Not required	Not required	Not required
Outcome	No evidence of disease	No evidence of disease	No evidence of disease	No evidence of disease

ureter, Klein *et al.*¹¹ and Nagai *et al.*³ reported that radical nephroureterectomy with bladder cuff excision was performed because UC was suspected before surgery.

The EAU guidelines on upper UTUC define high-risk UTUC by the following criteria: (i) multifocal disease, (ii) tumor size ≥ 2 cm, (iii) high-grade cytology, (iv) high-grade ureterorenoscopy biopsy, (v) local invasion on CT, (vi) hydronephrosis, (vii) previous radical cystectomy for high-grade bladder cancer, and (viii) variant histology. Our case met three of these high-risk UTUC criteria: tumor size

≥ 2 cm, local invasion on CT, and hydronephrosis. Per the EAU guidelines on UTUC, radical nephroureterectomy is the standard treatment for high-risk UTUC in the middle or proximal ureter. Therefore, we performed laparoscopic radical nephroureterectomy. Indeed, without a biopsy of the ureteral tumor, preoperative diagnosis of an EMP of the ureter is almost impossible. The differential diagnoses for ureteral tumors include UC, EMP, neuroendocrine tumor, metastatic tumor, paraganglioma, fibroepithelial polyp, and inflammatory myofibroblastic tumor. Among these tumors, EMP is a highly

radiosensitive tumor.^{12–16} If we had preoperatively diagnosed the ureteral tumor as EMP, we would have been able to choose radiotherapy instead of nephroureterectomy. We did not perform diagnostic ureteroscopy because we considered the left ureteral tumor as a high-risk UTUC before surgery. In addition, the use of diagnostic ureteroscopy has been associated with a higher risk of developing bladder recurrence after radical nephroureterectomy.^{17,18} The possibility of cancer dissemination has also been reported.^{18–20} Segmental ureteral resection is considered as another treatment option.²¹ In segmental ureteral resection for the tumor in the middle or proximal ureter, when end-to-end anastomosis of the ureter is challenging, an ileal-ureteral substitution is required, which is technically challenging and more invasive.

In our case, the tumor size was ≥ 2 cm and tumor invasion into the periureteric fat was suspected on preoperative CT. Segmental ureteral resection was considered challenging. Therefore, we performed laparoscopic radical nephroureterectomy. However, if we had preoperatively diagnosed the ureteral tumor as EMP, we would have been able to choose radiotherapy instead of nephroureterectomy.

Conclusion

We report a rare case of a primary EMP of the ureter. The patient survived without recurrence after laparoscopic radical nephroureterectomy.

Conflict of interest

The authors declare no conflict of interest.

Approval of the research protocol by an Institutional Reviewer Board

Not applicable.

Informed consent

Informed consent for publication was obtained from the patient.

Registry and the Registration No. of the study/trial

Not applicable.

References

- Kilciksiz S, Karakoyun-Celik O, Agaoglu FY, Haydaroglu A. A review for solitary plasmacytoma of bone and extramedullary plasmacytoma. *Sci. World J.* 2012; **2012**: 895765.
- International Myeloma Working Group. Criteria for the classification of monoclonal gammopathies, multiple myeloma and related disorders: a report of the International Myeloma Working Group. *Br. J. Haematol.* 2003; **121**: 749–57.
- Nagai T, Okamura T, Taki Y *et al.* Extramedullary plasmacytoma of the ureter in an HIV-positive patient. *Int. Cancer Conf. J.* 2017; **6**: 171–4.
- Alexiou C, Kau RJ, Dietzfelbinger H *et al.* Extramedullary plasmacytoma: tumor occurrence and therapeutic concepts. *Cancer* 1999; **85**: 2305–14.
- Kilciksiz S, Celik OK, Pak Y *et al.* Clinical and prognostic features of plasmacytomas: a multicenter study of Turkish Oncology Group-Sarcoma Working Party. *Am. J. Hematol.* 2008; **83**: 702–7.
- Kumar S, Fonseca R, Dispenzieri A *et al.* Prognostic value of angiogenesis in solitary bone plasmacytoma. *Blood* 2003; **101**: 1715–7.
- Susnerwala SS, Shanks JH, Banerjee SS, Scarffe JH, Farrington WT, Slevin NJ. Extramedullary plasmacytoma of the head and neck region: clinicopathological correlation in 25 cases. *Br. J. Cancer* 1997; **75**: 921–7.
- Mendenhall CM, Thar TL, Million RR. Solitary plasmacytoma of bone and soft tissue. *Int. J. Radiat. Oncol. Biol. Phys.* 1980; **6**: 1497–501.
- Soutar R, Lucraft H, Jackson G *et al.* Guidelines on the diagnosis and management of solitary plasmacytoma of bone and solitary extramedullary plasmacytoma. *Clin. Oncol.* 2004; **2004**: 405–13.
- Landsmann S, Todorov J, Streiber U, Seitz G, Weingartner K. Plasmacytoma of the ureter – a rare cause of hydronephrosis: case report and review of the literature. *Aktuelle Urol.* 2009; **40**: 175–8.
- Klein T, Holz A, Neid M, Hinkel A, Noldus J. The first description of an extramedullary plasmacytoma of the ureter. *Urol. Int.* 2010; **84**: 122–4.
- Li F, Guo H, Qiu H *et al.* Ureteral inflammatory myofibroblastic tumor: a case report and literature review. *Medicine* 2018; **97**: e13177.
- Wang Z, Yang J *et al.* Primary retroperitoneal paraganglioma mimicking a ureteral tumor: a case report and literature review. *Postgrad. Med.* 2020; **132**: 657–61.
- Hu J, Deng J, Guo J, Fu B. Ureteral involvement by metastatic malignant disease. *Clin. Exp. Metastasis* 2019; **36**: 499–509.
- Wang H, Ma C, Jie W *et al.* Clinicopathologic features of the ureteral neuroendocrine tumors. *Pathol. Res. Pract.* 2020; **216**: 152788.
- Gupta M, Roy S, Wann C *et al.* Giant fibroepithelial polyp of the ureter. *BMJ Case Rep.* 2017; **2017**: bcr2016218999.
- Marchioni M, Primiceri G, Cindolo L *et al.* Impact of diagnostic ureteroscopy on intravesical recurrence in patients undergoing radical nephroureterectomy for upper tract urothelial cancer: a systematic review and meta-analysis. *BJU Int.* 2017; **120**: 313–9.
- Guo RQ, Hong P, Xiong GY *et al.* Impact of ureteroscopy before radical nephroureterectomy for upper tract urothelial carcinomas on oncological outcomes: a meta-analysis. *BJU Int.* 2018; **121**: 184–93.
- Hendin BN, Strem SB, Levin HS, Klein EA, Novick AC. Impact of diagnostic ureteroscopy on long-term survival in patients with upper tract transitional cell carcinoma. *J. Urol.* 1999; **161**: 783–5.
- Territo A, Gallioli A, Meneghetti I *et al.* Diagnostic ureteroscopy for upper tract urothelial carcinoma: friend or foe? *Arab. J. Urol.* 2021; **19**: 46–58.
- Ou YC, Hu CY, Cheng HL, Yang WH. Long-term outcomes of total ureterectomy with ileal-ureteral substitution treatment for ureteral cancer: a single-center experience. *BMC Urol.* 2018; **18**: 73.