


ORIGINAL RESEARCH

Posterior auricular artery as a novel anatomic landmark for identification of the facial nerve: A clinical study

Muyuan Liu MD¹  | Litian Tong MD² | Manbin Xu MD¹ | Xiang Xu MD² |
Haipeng Guo MD¹ | Shaowei Xu MD¹ | Hanwei Peng MD¹¹Department of Head and Neck, Cancer Hospital of Shantou University Medical College, Shantou, China²Department of Anesthesiology, Cancer Hospital of Shantou University Medical College, Shantou, China

Correspondence

Muyuan Liu and Hanwei Peng, Department of Head and Neck, Cancer Hospital of Shantou University Medical College, Shantou, Guangdong 515000, China.
Email: muyuan-1981@163.com and penghanwei@126.com

Funding information

Medical Science Foundation of Guangdong Province, China, Grant/Award Number: A2019424; Science and Technology Project of Shantou, Guangdong Province, China, Grant/Award Number: 180723154011142

Abstract

Background: In our previous cadaveric study, we highlighted the posterior auricular artery (PAA) as a potential landmark for early identification of facial nerve (FN) when performing parotidectomy. However, further clinical study is critically needed before this landmark could be applied in clinical practice.**Methods:** For 31 patients enrolled, we tried to identify the FN by the guide of the PAA during parotidectomy. Additionally, the FN function was evaluated during follow-up.**Results:** PAA could be exposed in 28 out of 31 (90.3%) patients during parotidectomy. Moreover, the FN trunk could be identified by the guide of the PAA in all these 28 patients with identifiable PAA. Furthermore, no iatrogenic FN damage happened in this study and the transient FN dysfunction rate was 5.7%.**Conclusion:** The PAA is an ideal landmark for early identification of the FN trunk when performing parotidectomy.

KEYWORDS

anatomic landmarks, facial nerve, parotid neoplasms, posterior auricular artery, posterior auricular nerve

1 | INTRODUCTION

Parotid tumors make up 80% of all salivary gland tumors.¹ With respect to the treatment, parotidectomy is the first choice.^{2,3} Facial nerve (FN) iatrogenic injury is a common and serious complication during parotidectomy. Unfortunately, 65% rate of temporary FN dysfunction and 4%–7% rate of permanent facial paralysis have been reported after parotidectomy.^{4–9} Thus, in order to avoid iatrogenic damage to the FN, it is very important to localize the FN early with the help of some practical anatomic landmarks. FN dissection can be classified into two types: retrograde and anterograde. For retrograde dissection, the peripheral ramus of the FN is exposed first and then

traced to the main trunk of FN. Conversely, for anterograde dissection, the FN trunk is identified first and then traced to its peripheral branches. Both retrograde dissection and anterograde dissection of FN require reliable anatomic landmarks.

Anatomic landmarks for positioning the FN during parotidectomy have previously been described, such as the external auditory canal, some small rami of the FN, the posterior belly of the digastric muscle, the parotid-mastoid fascia, the tympanomastoid suture, the stylomastoid artery, the retromandibular vein, Borle's triangle, and so on.^{10–20} However, due to their complex anatomy, small size or deep location, most of these structures are difficult to locate during parotid surgery. Thus, further research is needed to identify additional anatomic structures in FN.

The posterior auricular nerve (PAN) is a small ramus of FN. It originates from the FN below the stylomastoid foramen and then courses

Muyuan Liu and Litian Tong contributed equally to this study.

This is an open access article under the terms of the [Creative Commons Attribution-NonCommercial-NoDerivs](https://creativecommons.org/licenses/by-nc-nd/4.0/) License, which permits use and distribution in any medium, provided the original work is properly cited, the use is non-commercial and no modifications or adaptations are made.

© 2022 The Authors. *Laryngoscope Investigative Otolaryngology* published by Wiley Periodicals LLC on behalf of The Triological Society.

TABLE 1 Facial Nerve Grading System 2.0

Grade I	Normal function in all areas
Grade II	<i>Mild dysfunction</i> Gross: slight weakness noticeable on close inspection; may have very slight synkinesis At rest: normal symmetry and tone <i>Motion</i> Forehead: moderate to good function Eye: complete closure with minimum effort Mouth: slight asymmetry
Grade III	<i>Moderate dysfunction</i> Gross: obvious but not disfiguring difference between two sides; noticeable but not severe synkinesis, contracture, and/or hemifacial spasm At rest: normal symmetry and tone <i>Motion</i> Forehead: slight to moderate movement Eye: complete closure with effort Mouth: slightly weak with maximum effort
Grade IV	<i>Moderately severe dysfunction</i> Gross: obvious weakness and/or disfiguring asymmetry At rest: normal symmetry and tone <i>Motion</i> Forehead: none Eye: incomplete closure Mouth: asymmetric with maximum effort
Grade V	<i>Severe dysfunction</i> Gross: only barely perceptible motion At rest: asymmetry <i>Motion</i> Forehead: none Eye: incomplete closure Mouth: slight movement
Grade VI	<i>Total paralysis: no movement</i>

TABLE 2 Patient characteristics and summarization of FN identification by the guide of PAA and PAN

Parameters	Case, n (%)
Age, median (Range)	48 (21–73) years
Sex	
Male	17 (54.8%)
Female	14 (45.2%)
Tumor type	
Pleomorphic adenoma	21 (67.7%)
Parotid cancer	8 (25.8%)
Warthin tumor	2 (6.5%)
Surgery type	
Primary parotidectomy	26 (83.9%)
Revision parotidectomy	5 (16.1%)
Exposure of PAA and/or PAN	
None	3 (9.7%)
Both	7 (22.6%)
PAA Only	21 (67.7%)
PAN Only	0 (0.0%)
Identification of FN by the guide of PAA and/or PAN	
None	3 (9.7%)
By tracing both PAA and PAN	7 (22.6%)
By tracing PAA	16 (51.6%)
Estimate the location of FN by the direction of PAA	5 (16.1%)

Abbreviations: FN, facial nerve; PAA, posterior auricular artery; PAN, posterior auricular nerve.

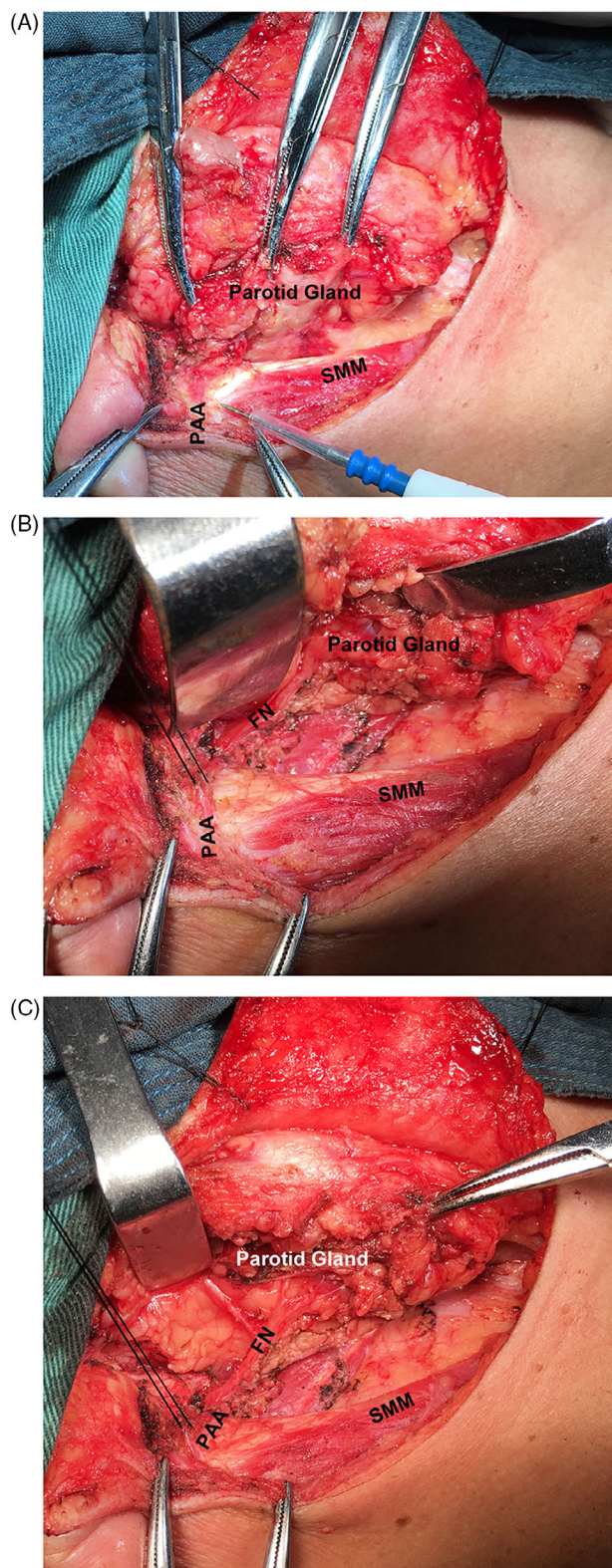


FIGURE 1 A representative case shows that PAA was identified first and then FN trunk was identified by tracing out the PAA toward the stylomastoid foramen and the FN trunk was found to be cross with the PAA inferior to the stylomastoid foramen. FN, facial nerve; PAA, posterior auricular artery; SMM, sternocleidomastoid muscle

between the auricle and mastoid tip. However, it is not feasible to use PAN as an anatomic landmark for early identification of the FN trunk due to its small size and similar color with the surrounding tissue. The

posterior auricular artery (PAA) is a small branch of the external carotid artery and always accompanies the PAN. Additionally, the PAA is pulsatile, has a larger diameter, and has distinguishing color

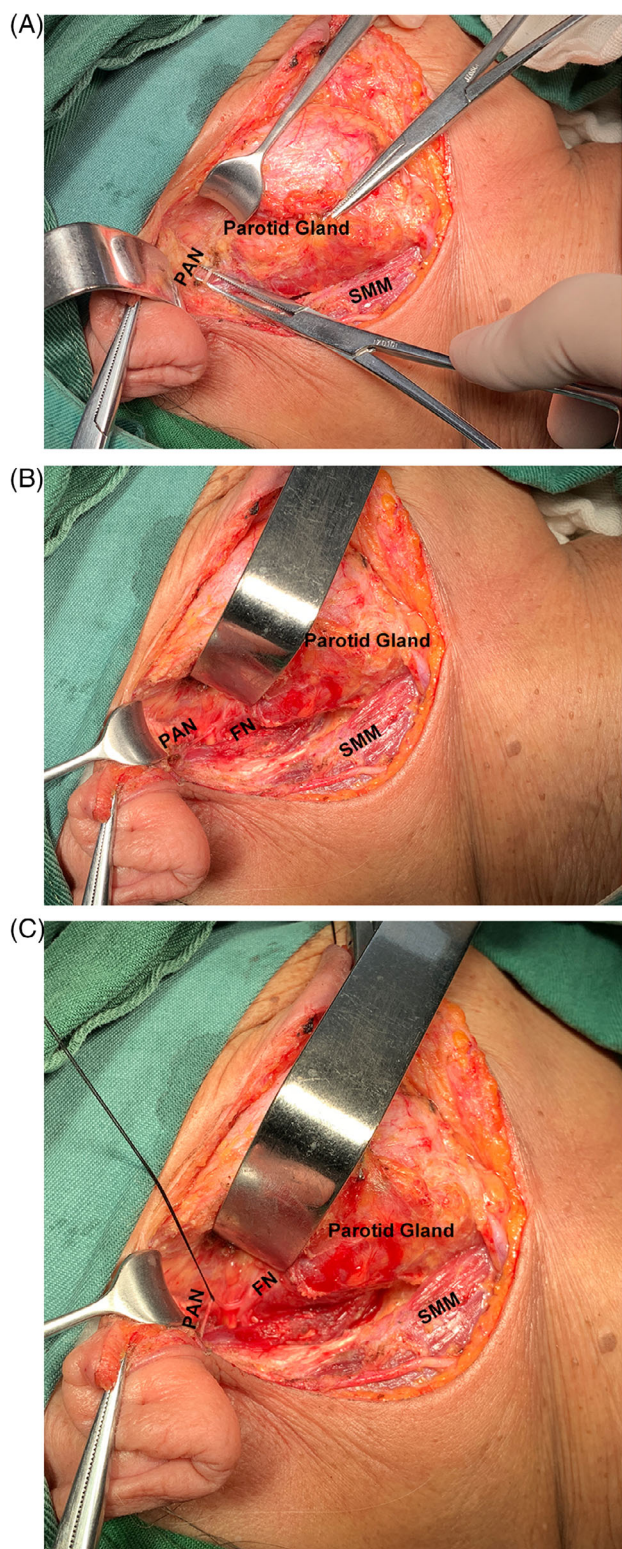


FIGURE 2 A representative case shows that PAN was identified first and followed by the FN trunk identification by tracing the PAN to its origin. FN, facial nerve; PAN, posterior auricular nerve; SMM, sternocleidomastoid muscle

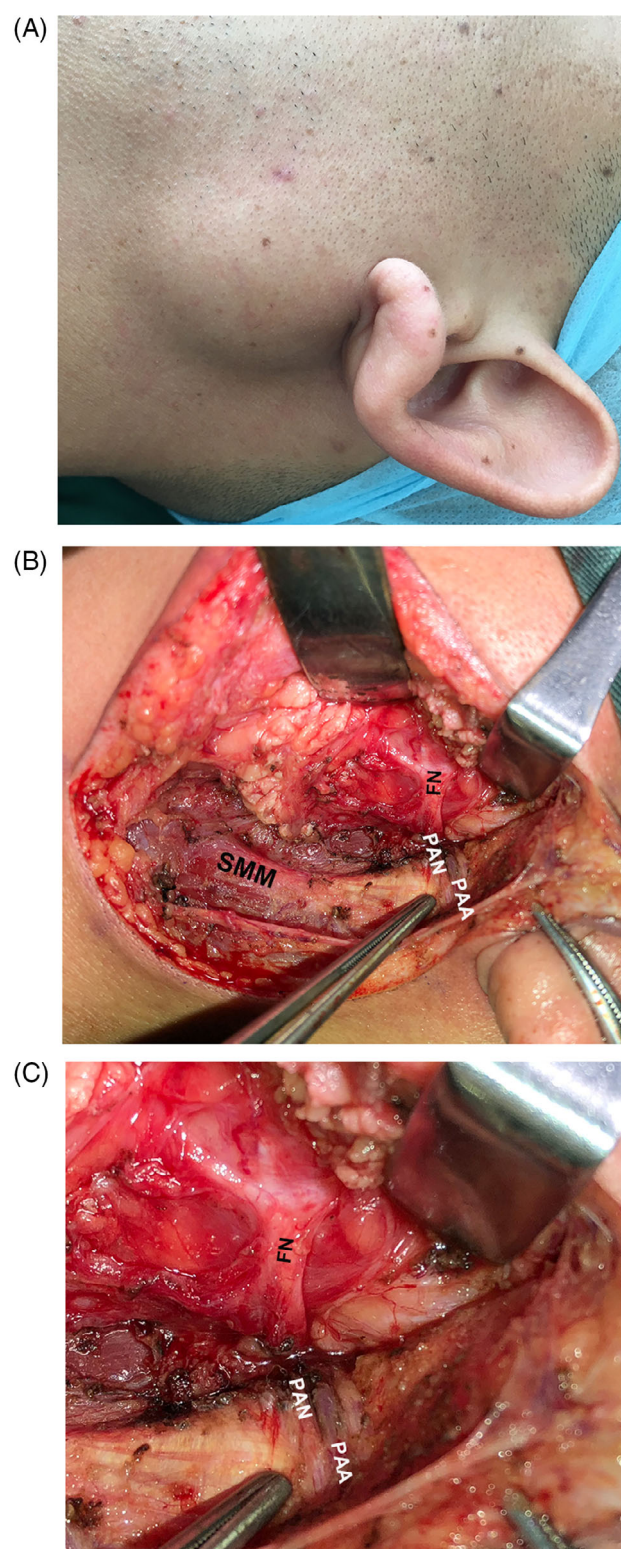


FIGURE 3 A representative case shows that both PAA and PAN were identified and then FN trunk was identified by tracing these two anatomic landmarks. FN, facial nerve; PAA, posterior auricular artery; PAN, posterior auricular nerve; SMM, sternocleidomastoid muscle

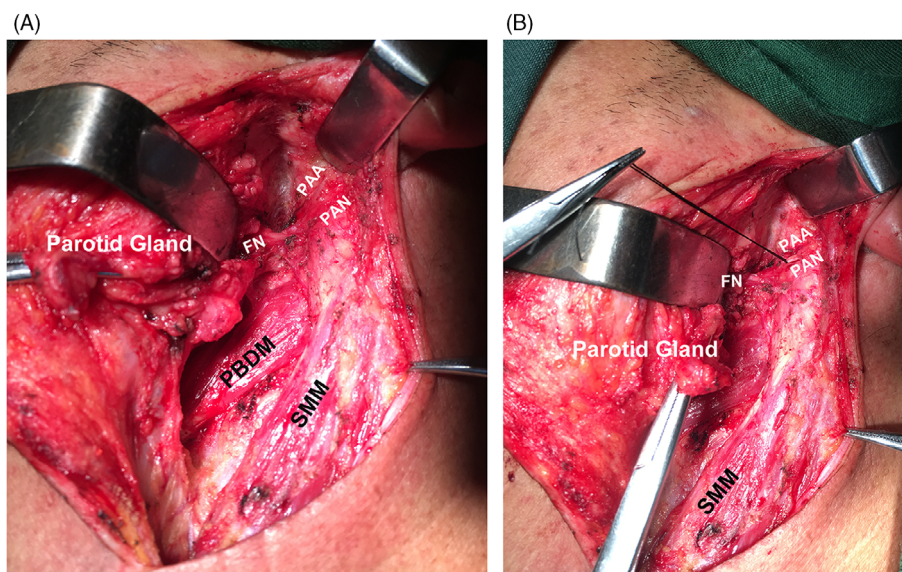


FIGURE 4 A representative case shows the relationship between FN and PAA, PAN. FN, facial nerve; PAA, posterior auricular artery; PAN, posterior auricular nerve; PBDM, posterior belly of digastric muscle; SMM, sternocleidomastoid muscle

characteristics when compared to the PAN. Thus, it seems theoretically feasible to use the PAA as a potential practical anatomic landmark for FN identification during parotidectomy.

In our previous cadaveric study,²¹ we demonstrated that the PAA could be used as a new anatomic landmark during parotidectomy to enable early detection of FNs. By tracking the PAA medially, we were able to identify the FN trunk. However, our cadaveric study only provided anatomic evidence to support the potential clinical application of the PAA as an anatomic landmark for FN trunk when performing a parotid surgery. Further related clinical research is critically needed before this landmark could be applied in clinical practice.

The current clinical research was conducted to evaluate the clinical utility of the PAA for FN early identification during parotidectomy, and its impact in postoperative FN function.

2 | MATERIALS AND METHODS

2.1 | Patients

All patients underwent parotidectomy in Cancer Hospital of Shantou University Medical College between July 1, 2019 and June 30, 2020 were invited to participate in this study, and finally a total of 31 parotid tumor patients were enrolled. Ethical approval was given by the medical ethics committee of Cancer Hospital of Shantou University Medical College (Ethical Approval Number: 201850).

2.2 | Surgical procedure

The surgical procedure is similar to the dissection protocol in our previous cadaveric study.²¹ A standard parotidectomy incision (S-shaped) begins in the preauricular skin crease and then curves gently around the lobule of the ear turning posteriorly toward the mastoid process. It then follows an upper neck skin crease. Subsequently, a skin flap is

elevated. After that, the PAA coursing over the surface of mastoid process is exposed. While dissection continues, we try to expose the FN trunk by tracing the PAA medially. Sometimes, accidental injury or bleeding of the PAA may make it difficult to trace the PAA to the cross of PAA and FN trunk during operation. In this instance, we try to estimate the possible location of the FN trunk according to the direction of the PAA. During parotidectomy, the relationship between the FN trunk and the PAA is illustrated with high-definition photographs.

2.3 | FN function evaluation

All patients enrolled in this study were followed up for at least 6 months. The FN function was evaluated during follow-up according to the Facial Nerve Grading System 2.0 (Table 1).^{22,23}

3 | RESULTS

3.1 | Patients

A total of 14 female and 17 male patients were included in the study. The median age was 48 years (range: 21–73 years). Of the 31 patients included, 21 were pleomorphic adenoma of parotid gland patients, 8 were parotid cancer patients, and 2 were Warthin tumor patients. Moreover, among 31 patients, 26 patients had a primary parotidectomy and 5 patients underwent a revision parotidectomy. Clinicopathological features of patients enrolled are shown in Table 2.

3.2 | PAA was an ideal anatomic landmark for early identification of the FN

In this study, we tried to identify PAA at the very beginning of operation. Among the 31 patients enrolled, PAA could be identified in 28

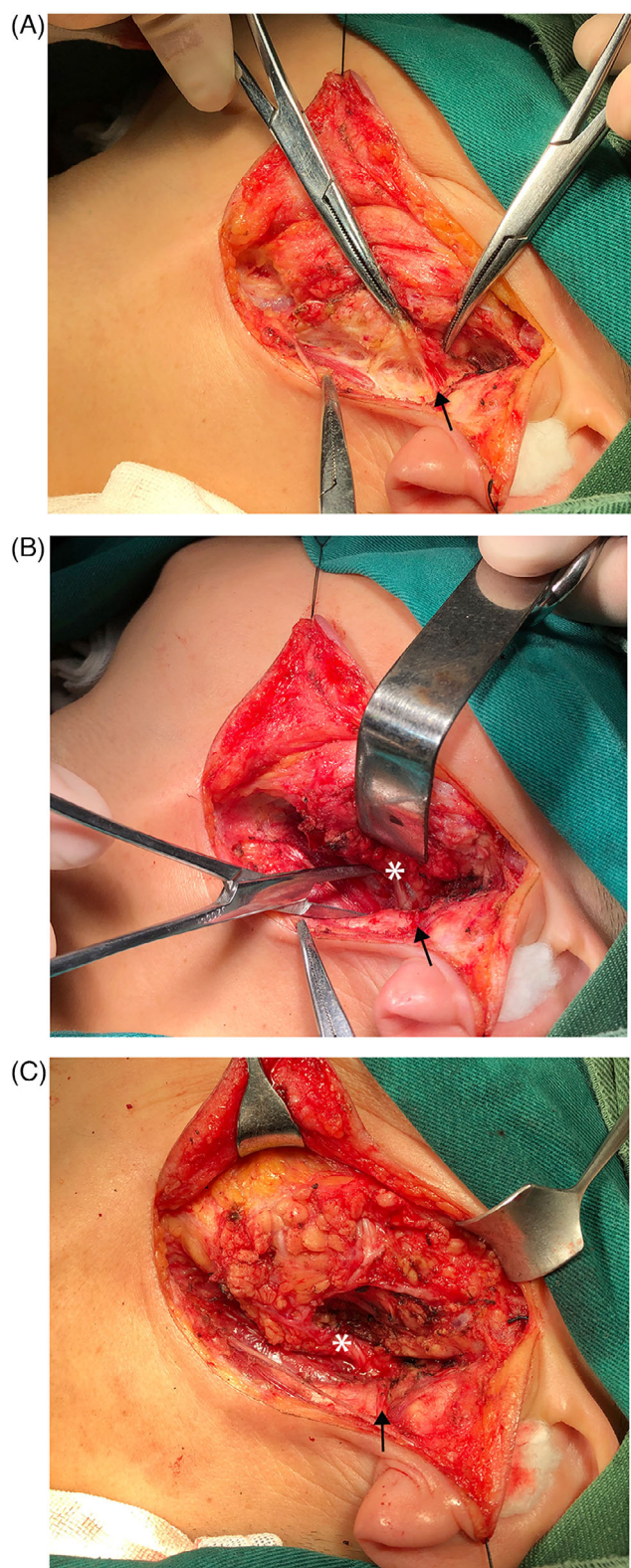


FIGURE 5 A representative case shows that PAA was identified first and then FN trunk was estimated by the direction of the PAA. FN, facial nerve; PAA, posterior auricular artery; White asterisk, facial nerve; Black arrow, posterior auricular artery.

(90.3%) patients during parotidectomy, and the FN trunk was able to be identified directly or indirectly by the guide of the PAA in all these 28 patients with identifiable PAA. In 23 of 28 patients, the FN was

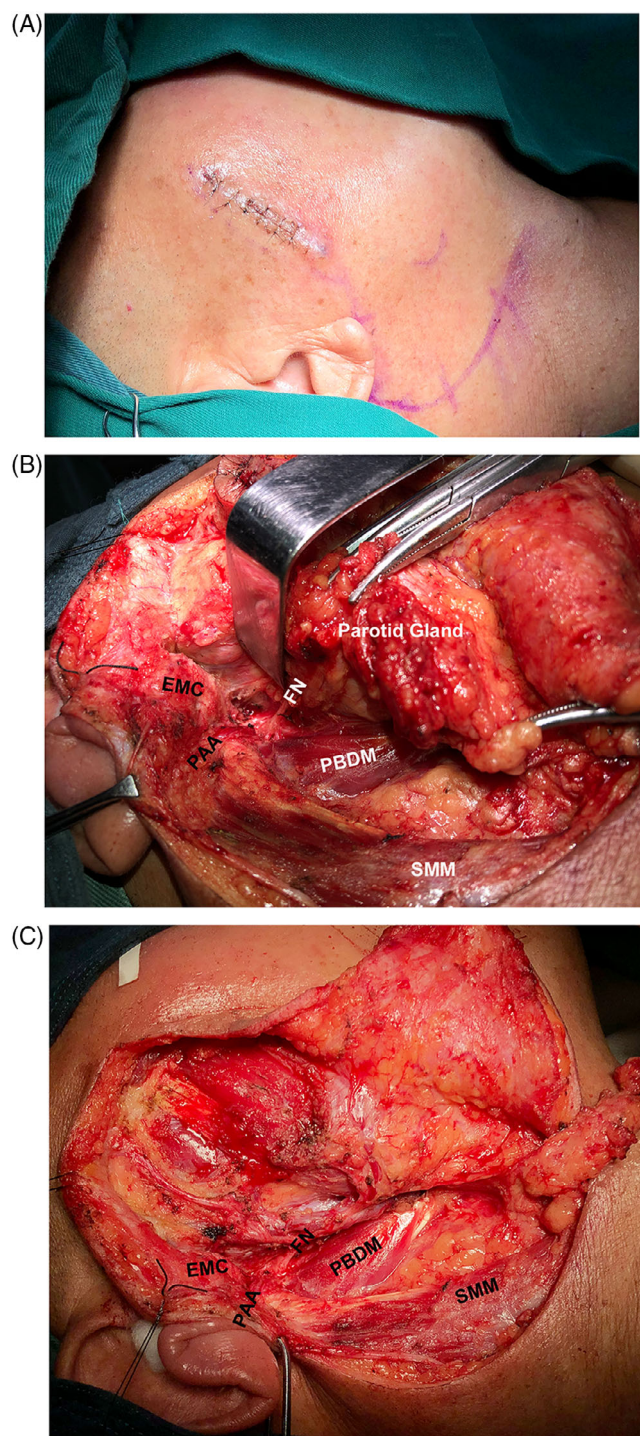


FIGURE 6 A representative case shows that PAA and PAN were used as anatomic landmarks for identification of FN trunk in revision parotidectomy. EMC, external meatal cartilage; FN, facial nerve; MP, mastoid process; PAA, posterior auricular artery; PAN, posterior auricular nerve; PBDM, posterior belly of digastric muscle; SMM, sternocleidomastoid muscle

directly exposed by tracing the PAA to the cross of PAA and the FN trunk, or by tracing the PAN to its origin if the PAN was identifiable (Figures 1–3). The PAA runs always toward the main trunk of the FN, crossing it inferior to the stylomastoid foramen (Figure 4). In another 5 out of these 28 patients with identifiable PAA, we failed to trace

out the PAA to the cross of the FN trunk and the PAA because of accidental injury or bleeding of the PAA. However, we were able to precisely locate the FN trunk by following the direction of the PAA (Figure 5). Additionally, in four out of five revision parotidectomy cases, FN could be exposed by the guide of PAA or PAN (Figure 6). No iatrogenic FN damage happened in our study. The results were summarized in Table 2.

3.3 | FN function evaluation after parotidectomy

The patients enrolled in our study were followed up after operation and the FN function was evaluated (using the House–Brackmann grading system).^{22,23} Finally, only two (5.7%) patients had transient FN dysfunction and recovered fully during follow-up. One (2.9%) patient who underwent revision parotidectomy had permanent FN paralysis (H-B Grading III) because the buccal and marginal mandibular branches were invaded by tumor and had to be removed during operation.

4 | DISCUSSION

In our previous cadaveric study,²¹ we demonstrated PAA was a potential ideal anatomic landmark for FN early identification when performing parotidectomy. Further clinical research is however urgently needed before this landmark could be applied in clinical practice. Hence, we conducted the present clinical study to assess the potential clinical utility of the PAA as a practical anatomical structure for FN identification when performing parotid surgery, and its impact in postoperative FN function. Our results showed that PAA could be exposed in 28 out of 31 (90.3%) patients during parotidectomy. Moreover, the FN trunk could be exposed by the guide of PAA in all these 28 patients with identifiable PAA. Furthermore, no iatrogenic FN damage happened in this study and the transient FN dysfunction rate was 5.7%. Our results supported that PAA was an effective and safe anatomic landmark for clinical application during parotidectomy.

Different from cadaveric anatomic dissection, tracing the PAA during parotidectomy sometimes will lead to bleeding and we have to coagulate or even remove part of this artery before the exposure of the FN. In this case, we may fail to trace the PAA to the cross of the FN and PAA. However, we could determine the exact location of the FN trunk according to the PAA direction, because the PAA is always coursing in a straight line on the surface of mastoid and pointing precisely to the FN trunk. Additionally, PAN, if identifiable during parotidectomy, could be used instead of PAA for FN identification to avoid the problem of bleeding. Regrettably, the identification rate of PAN is only 22.6% (7 out of 31) during parotidectomy.

Identification of the FN is more difficult in revision parotidectomy due to significant anatomic distortion, and practical anatomic landmarks are critically needed. In this study, four out of five revision parotidectomy patients had the FN trunk exposed by tracing the PAA. However, we must keep in mind that PAA and PAN could be used as

potential anatomic landmarks in revision parotidectomy only when the normal anatomy of the mastoid area has not been disrupted in the primary parotid surgery.

Another limitation should be considered while reviewing our results. In this clinical study, it appears that the PAA is a good landmark for anterograde dissection. However, it is not suitable for patients with large parotid masses near the trunk of the FN.

5 | CONCLUSION

Our findings demonstrate that the FN trunk could be localized and exposed by tracing the PAA medially or the PAN to its origin. PAA is an ideal anatomic landmark for identifying the FN trunk when performing parotid surgery.

FUNDING INFORMATION

This project was supported by the Medical Science Foundation of Guangdong Province, China (Grant No. A2019424) and the Science and Technology Project of Shantou, Guangdong Province, China (Grant No. 180723154011142).

CONFLICT OF INTEREST

The authors declare that they have no conflicts of interest to this work.

ORCID

Muyuan Liu  <https://orcid.org/0000-0001-5064-1373>

REFERENCES

1. Bussu F, Rigante M, Giglia V, et al. Clinical history, prognostic factors, and management of facial nerve in malignant tumors of the parotid gland. *Clin Exp Otorhinolaryngol*. 2014;7(2):126-132.
2. Psychogios G, Bohr C, Constantinidis J, et al. Review of surgical techniques and guide for decision making in the treatment of benign parotid tumors. *Eur Arch Otorhinolaryngol*. 2021;278(1):15-29.
3. Ali NS, Nawaz A, Rajput S, Ikram M. Parotidectomy: a review of 112 patients treated at a teaching hospital in Pakistan. *Asian Pac J Cancer Prev*. 2010;11(4):1111-1113.
4. Upton DC, McNamar JP, Connor NP, Harari PM, Hartig GK. Parotidectomy: ten-year review of 237 cases at a single institution. *Otolaryngol Head Neck Surg*. 2007;136(5):788-792.
5. Sood AJ, Houlton JJ, Nguyen SA, Gillespie MB. Facial nerve monitoring during parotidectomy: a systematic review and meta-analysis. *Otolaryngol Head Neck Surg*. 2015;152(4):631-637.
6. Laccourreye H, Laccourreye O, Cauchois R, Jouffre V, Menard M, Brasnu D. Total conservative parotidectomy for primary benign pleomorphic adenoma of the parotid gland: a 25-year experience with 229 patients. *Laryngoscope*. 1994;104(12):1487-1494.
7. Ji YD, Donoff RB, Peacock ZS, Carlson ER. Surgical landmarks to locating the Main trunk of the facial nerve in parotid surgery: a systematic review. *J Oral Maxillofac Surg*. 2018;76(2):438-443.
8. Grosheva M, Klusmann JP, Grimminger C, et al. Electromyographic facial nerve monitoring during parotidectomy for benign lesions does not improve the outcome of postoperative facial nerve function: a prospective two-center trial. *Laryngoscope*. 2009;119(12):2299-2305.
9. Dulguerov P, Marchal F, Lehmann W. Postparotidectomy facial nerve paralysis: possible etiologic factors and results with routine facial nerve monitoring. *Laryngoscope*. 1999;109(5):754-762.

10. Lawson HH. Value of the tympanomastoid fissure in the exposure of the facial nerve. *Br J Surg*. 1988;75(4):309.
11. Furnas DW. Landmarks for the trunk and the temporofacial division of the facial nerve. *Br J Surg*. 1965;52:694-696.
12. Micucci SB, Cheng SS, Song T, Rasgon B. The role of the parotid-mastoid fascia in identification of the facial nerve trunk during parotidectomy. *Ear Nose Throat J*. 2021;100(7):504-508.
13. O'Brien JX, Rozen WM, Ting JW, Leung M. A simplified landmark for the facial nerve trunk in parotidectomy: the sternocleidomastoid origin. *J Plast Reconstr Aesthet Surg*. 2012;65(6):832-833.
14. Tayebi Meybodi A, Borba Moreira L, Lawton MT, Preul MC. Anatomical assessment of the digastric branch of the facial nerve as a landmark to localize the extratemporal facial nerve trunk. *Surg Radiol Anat*. 2019;41(6):657-662.
15. Mahmood VH. Buccal branch as a guide for superficial parotidectomy. *J Craniofac Surg*. 2012;23(5):e447-e449.
16. Kanatas AN, McCaul JA. Use of digastric branch of the facial nerve for identification of the facial nerve itself in parotidectomy: technical note. *Br J Oral Maxillofac Surg*. 2011;49(6):493-494.
17. Upile T, Jerjes W, Nouraei SA, et al. The stylomastoid artery as an anatomical landmark to the facial nerve during parotid surgery: a clinico-anatomic study. *World J Surg Oncol*. 2009;7:71.
18. Toure G, Vacher C. Relations of the facial nerve with the retromandibular vein: anatomic study of 132 parotid glands. *Surg Radiol Anat*. 2010;32(10):957-961.
19. Borle RM, Jadhav A, Bhola N, Hingnikar P, Gaikwad P. Borle's triangle: a reliable anatomical landmark for ease of identification of facial nerve trunk during parotidectomy. *J Oral Biol Craniofac Res*. 2019;9(1):33-36.
20. Yilmazer R, Baskadem Yilmazer A, Hoffer ME, Eshraghi AA, Telischi FF, Angeli SI. A new technique to find the facial nerve and recess by using the short process of the incus and the spine of Henle as landmarks: incus-spine angle. *Acta Otolaryngol*. 2018;138(11):1051-1056.
21. Liu M, Wang SJ, Benet A, Meybodi AT, Tabani H, Ei-Sayed IH. Posterior auricular artery as a novel anatomic landmark for identification of the facial nerve: a cadaveric study. *Head Neck*. 2018;40(7):1461-1465.
22. House JW, Brackmann DE. Facial nerve grading system. *Otolaryngol Head Neck Surg*. 1985;93(2):146-147.
23. Reitzen SD, Babb JS, Lalwani AK. Significance and reliability of the House-Brackmann grading system for regional facial nerve function. *Otolaryngol Head Neck Surg*. 2009;140(2):154-158.

How to cite this article: Liu M, Tong L, Xu M, et al. Posterior auricular artery as a novel anatomic landmark for identification of the facial nerve: A clinical study. *Laryngoscope Investigative Otolaryngology*. 2022;7(5):1441-1447. doi:[10.1002/lio2.894](https://doi.org/10.1002/lio2.894)