


ORIGINAL ARTICLE

Reproductive Medicine and Biology

WILEY

Accumulation of fibrosis and altered perifollicular stromal differentiation in vitrified-thawed human ovarian tissue xenografted to nude mice.

Michio Kitajima^{1,2}  | Naoko Murakami² | Yuriko Kitajima² | Itsuki Kajimura² | Asako Matsumura² | Kanako Matsumoto² | Ayumi Harada² | Kiyonori Miura^{1,2}

¹Department of Obstetrics and Gynecology, Nagasaki University Graduate School of Biomedical Sciences, Nagasaki, Japan

²Department of Obstetrics and Gynecology, Nagasaki University Hospital, Nagasaki, Japan

Correspondence

Michio Kitajima, 1-7-1 Sakamoto, Nagasaki 852-8501, Japan.

Email: m-kita@nagasaki-u.ac.jp

Funding information

Japan Society for the Promotion of Sciences, Grant/Award Number: 16K20197 and 18K09294

Abstract

Purpose: Ovarian tissue cryopreservation and its auto-transplantation is promising technique in fertility preservation. Longevity of grafted tissue is limited though mechanism of follicle reduction is not fully understood. We evaluated histological alteration of vitrified-thawed ovarian tissue that grafted to nude mice.

Materials and Methods: Human ovarian tissue was cryopreserved by vitrification. After thawing, they were grafted to mesentery of nude mice. Twelve weeks after transplantation, the implants were removed and histologically examined. The presence of follicles, the degree of fibrosis, and TUNEL staining in surrounding cortex were evaluated. The stromal expressions of alpha-smooth muscle actin (aSMA) were determined.

Results: Normal ovarian cortex was decreased, and fibrotic area were significantly increased after grafting. The distributions of developmental stage of follicles shifted toward activation of follicular growth. Stromal TUNEL staining was increased in frozen/thawed tissue. The expression of aSMA were found in perifollicular stroma of growing follicles, which were decreased in grafted tissue associated with reduction of cortical stroma.

Conclusions: Fibrosis, reduced cortical stroma, and activation of dormant follicles were concomitantly observed in grafted ovarian cortex, which may relate to limited longevity. Perifollicular aSMA expression can be regarded as a marker of the competence of cortical stroma that regulate follicular development.

KEYWORDS

alpha-smooth muscle actin, fibrosis, follicular growth, ovarian cortical stroma, ovarian tissue cryopreservation

This is an open access article under the terms of the Creative Commons Attribution-NonCommercial-NoDerivs License, which permits use and distribution in any medium, provided the original work is properly cited, the use is non-commercial and no modifications or adaptations are made.

© 2022 The Authors. *Reproductive Medicine and Biology* published by John Wiley & Sons Australia, Ltd on behalf of Japan Society for Reproductive Medicine.

1 | INTRODUCTION

Ovarian tissue cryopreservation (OTC) is valuable clinical methods for fertility preservation in women at the risk of premature ovarian failure.¹ When women had OTC wish childbearing, auto-transplantation of cryopreserved ovarian tissue to pelvic cavity can be carried out to restore their fertility, and the efficacy of this method have been confirmed over 130 live births as of June 2017 and probably more than 200 in 2020 since first successful case was reported in 2004.^{2,3}

The procedures relating to OTC and the following auto-transplantation can damage the harvested ovarian tissue. The longevity of transplanted ovarian tissue was reported to be limited.⁴ Although the procedures related to freezing and thawing can affect the dormancy of primordial follicles, large amounts of primordial follicles may disappear after the auto-transplantation of frozen-thawed ovarian tissue, which may adversely affect therapeutic goals of OTC.⁵ Since the frozen-thawed ovarian tissue may transplant onto the residual ovary or pelvic peritoneal pocket near-by without vascular channels, ischemia and reperfusion tissue injury may directly affect the fate of dormant primordial follicles in ovarian cortex.⁴ However, the exact mechanism of exhaustion of primordial follicles in these situations had not been clearly elucidated.

Nude mouse model using frozen-thawed human ovarian tissue have been utilized to research the efficacy of OTC.⁶ Accelerated recruitment of primordial follicle were found in implanted ovarian tissue, which might be one of the causes of diminished ovarian reserve in women had auto-transplantation.⁷ These are hypothesized as "burn-out phenomenon", which also found in the ovary of women had gonadotoxic chemotherapy and the women with endometriosis.^{8–10} However, the detailed molecular mechanism of these phenomena is not well understood.

Fibrosis is an early hallmark of the aging ovarian stroma, and this altered microenvironment may contribute to the age-associated decline in gamete quality.¹¹ On the other hand, fibrotic changes of ovarian cortex may be the results of freezing and thawing of the tissue, ischemia and reperfusion tissue injury and local inflammation and they may be correlated with each other. Fibrosis of ovarian cortex may affect the function of stromal cells in ovarian cortex, which participate in the maintenance of the dormancy of primordial follicles, nourishing and making the optimal niche for growing follicles. However, the information regarding the functional capability of ovarian stroma surrounding resting and growing follicles is limited.

Vitrification has been introduced to embryo and oocytes cryopreservation and getting its popularity in clinical applications with simplified methods and superior survival rate.¹² In OTC, slow freezing using programmed freezing apparatus has been perceived as standard method.¹³ The vitrification of ovarian tissue is also applied to OTC though its efficacy is still the matter of debate owing to its limited clinical experiences.^{14–16} The information based on fundamental experiments using vitrification method may be needed.

In this study, we aimed to investigate the degree of fibrosis and the status of perifollicular stromal cells in vitrified-thawed human ovarian tissue transplanted to the peritoneal cavity of nude mouse. We also

compared the staining intensity of alpha-SMA, which is a marker of perifollicular stromal cells (outer thecal layer), in ovarian cortex before and after the freezing and after the xenografting to nude mouse.

2 | MATERIALS AND METHODS

2.1 | Ovarian tissue collection

After obtaining written informed consent, the portion of ovary was biopsied from six women with stage I uterine cancer, who was going to receive radical surgery including bilateral oophorectomy. The sampling of ovarian cortex was accomplished before the ligation of ovarian vessels. The ovarian cortex was incised with cold scissors and immediately put into medium at 4°C then the tissue was transported to laboratory from operating room on ice. The ovarian tissue was trimmed into 5 × 5 × 1 mm pieces and cryopreserved using vitrification kit (Ova Cryo Kit Type M, VT-301S, Kitazato Corporation) according to the manufacturer's protocol. Frozen ovarian tissue was stored in liquid nitrogen tank in freezing device (Ova Cryo Device Type M, ODT, Kitazato Corporation). A portion of biopsied ovarian tissue was fixed in Bouin's solution and embedded on paraffin block for following histological analysis (Fresh cortical tissue). Use of human ovarian tissue for this study was approved by the Institutional Review Board of the Nagasaki University Hospital and Institute of Laboratory Animals (No. 11092632 and No. 1710121414–3).

2.2 | Thawing and transplantation

Fourteen immunodeficient nude mice (BALB/c-nu, Charls River Japan) were purchased and acclimated under the constant environment. Frozen ovarian tissue was thawed with thawing kit (Ova Thawing Kit Type M, VT-302S, Kitazato Corporation, Shizuoka, Japan) according to the manufacturer's protocol. Then, thawed ovarian tissue was trimmed into 2 × 2 × 1 mm pieces. These pieces of ovarian cortical tissue were transplanted on the mesenterial or uterine vessels of peritoneal cavity of nude mice (3–4 pieces per mouse) keeping distance from each other using woven adhesion barriers (Interseed®, Ethicon, Johnson and Johnson, Tokyo) moistured with normal saline. A portion of frozen-thawed ovarian tissue was fixed in Bouin's solution and embedded in paraffin block for following histological analysis (Frozen-thawed cortical tissue). Twelve weeks later, nude mice were laparotomized and transplanted site were examined, and tissue nodules were excised. Harvested lesions were fixed in Bouin's solution and embedded on paraffin block for following histological analysis (Grafted cortical tissue).

2.3 | Tissue sample evaluation

Approximately forty to fifty consecutive sections at five micrometer thickness were made and hematoxylin and eosin (H.E.) staining were

performed every twenty micrometers, then ten consecutive stained sections were selected to determine presence of ovarian cortical tissue and follicles in excised tissue. In these specimens, the presence of ovarian cortical stroma that harbor dormant and early follicles was determined.¹⁷

Masson-Trichrome staining with aniline blue (Muto Pure Chemicals, Tokyo) were performed in adjacent sections. In another adjacent sections, the expressions of alpha-smooth muscle actin (aSMA) were detected by immunohistochemistry according to the methods previously reported with some modification.¹⁰ Briefly, 5- μ m sections were deparaffinized and rehydrated. Endogenous peroxidase activity was quenched by immersing in 0.3% H₂O₂ in methanol for 30 mins. After washing three times in PBS, the sections were incubated with blocking agent for nonspecific binding (Protein Block Serum-Free, X0909, DAKO) for 10 mins. They were then incubated with mouse monoclonal antibody (clone 1A4, 1:100 dilution, DAKO) overnight at 4°C in a moist chamber. After washing three times in PBS with 0.075% Brij 35 (Sigma) for 5 minutes each time, the sections were incubated with a cocktail of peroxidase-labeled polymer conjugated to goat anti-mouse or anti-rabbit immunoglobulins (EnVision, K1491, DAKO) for 30 mins at room temperature, and washed as previously described. Specific immunoreactivity was visualized by 3,30-diaminobenzidine tetrahydrochloride (DAB) and H₂O₂. The sections were counterstained with Mayer's hematoxylin, dehydrated, and coverslipped for analysis.

Fibrosis in cortical tissue was identified as filamentous (fiber-like, subtle fibrosis) and/or stratified hypocellular (paint-like, dense fibrosis) features in H.E. as well as Masson-Trichrome staining.¹⁰ In cortical tissue with follicles, the developmental stage of follicles are classified according to the strict criteria of Gougeon and Chainy¹⁸ as: (1) primordial follicles in which oocytes are surrounded only by flattened GCs; (2) transitional follicles in which oocytes are surrounded by a mixture of cuboidal and flattened GCs; (3) primary follicles in which oocytes are surrounded by a single layer of cuboidal GCs; and (4) secondary follicles in which oocytes are surrounded by two to three layers of cuboidal GCs, and (5) antral follicles in which fluid pooling area is evident.

TUNEL staining was performed to detect apoptotic cells in tissue specimens using commercially available kit (In situ apoptosis detection kit, Takara Bio, Tokyo, Japan) according to the manufacturer's protocol with some modifications. Briefly, 5- μ m sections were deparaffinized and rehydrated. The sections were treated with Proteinase K (10 μ g/mL) for 15 minutes in 37°C. After washing three times in PBS, endogenous peroxidase activity was quenched by immersing in 0.3% H₂O₂ in methanol for 15 minutes. Then, after washing three times in PBS, the sections were incubated with reaction mixture (TdT enzyme 5 μ L + Labeling Safe Buffer 45 μ L) in a humidified chamber for 60 minutes at 37°C. After washing three times in PBS, the sections were incubated with anti-FITC HRP conjugate for 30 mins at 37°C. After washing three times in PBS with 0.075% Brij 35 (Sigma) for 5 mins each time, specific immunoreactivity was visualized by DAB and H₂O₂. The sections were counterstained with 3% Methyl green, dehydrated, and coverslipped for analysis. Rat breast

tissue was used for positive control and the sections treated with Labelling Safe Buffer alone was served as negative control. Intense nuclear staining was judged as positive.

2.4 | Image analysis

Microscopic images were captured using image analysis software (cell Sens, standard ver. 2.3). The area of ovarian cortex were determined delineating the contour of ovarian tissue. In Masson-trichrome staining, blue color-stained area was determined in captured digital images as fibrotic changes and percentage to whole ovarian cortical area were calculated. Perifollicular aSMA staining were compared according to the developmental stage of the follicles and the phase of the experimental procedures. Staining of aSMA was scored based on staining intensity and perifollicular distributions, i.e., 0: no staining, 1: weak subtle staining in monolayer, 2: intense monolayer or sparse multilayer, and 3: intense multilayer staining.

2.5 | Statistical analysis

The statistical analysis of continuous variables was calculated by unpaired student's t-test and categorical variables were analyzed by chi-square test and Fisher's exact test. All statistical analysis was performed with computer software (JMP Pro 14.0.0, SAS institute Japan, Tokyo). *p* value under 0.05 was considered as statistical significance.

3 | RESULTS

The mean age of women who provided ovarian cortical tissue was 30.7 \pm 3.0 years old (range 27–36). Six fresh biopsied cortical tissues and corresponding six frozen-thawed cortical tissue were submitted to histological analysis. While we grafted 48 cortical pieces onto 14 nude mice, histological analysis revealed that 33 grafted nodules were with intact human ovarian tissue structure. Whereas cortical-specific stroma was present all specimen from fresh and frozen-thawed cortical tissue, the presence of cortical-specific stroma was found only in 40% of specimens in grafted cortical tissue. Filamentous fiber-like subtle fibrosis is present in two from fresh and five from frozen-thawed cortical tissue and stratified hypocellular paint-like dense fibrosis was not present in these specimens. In grafted tissue, all specimens showed various degrees of fibrosis, and 30 (91%) specimens were diagnosed as having dense fibrosis. (Table 1).

The fibrosis was further identified by blue colored appearances by Masson-Trichrome staining (Figure 1). To assess the degree of fibrosis subjectively, we performed computer-assisted image analysis of Masson-Trichrome staining. These area comparisons revealed that grafted tissue showed significantly larger area of fibrosis (*p* < 0.001, unpaired student's t-test). We did not find statistically significant

difference between fresh and frozen-thawed cortical tissue in terms of occupied fibrotic area in ovarian cortex (Figure 2).

In two representative sections of each histological specimens, 62, 45, and 52 follicles were identified in fresh ($n = 6$), frozen-thawed ($n = 4$), and grafted ovarian cortical tissue ($n = 7$), respectively. The

TABLE 1 The characteristics of histological features of ovarian cortex

	Fresh $n = 6$	Frozen-thawed $n = 6$	Grafted $n = 33$
Presence of cortical stroma	6 (100%)	6 (100%)	13 (39%)
Presence of fibrosis*	2 (33%)	5 (83%)	33 (100%)
Subtle	2	5	3
Dense	0	0	30
Presence of follicles**	6 (100%)	5 (83%)	7 (21%)
Primordial†	5 (83%)	5 (83%)	2 (6%)
Growing†	2 (33%)	0	7 (21%)

*including subtle fibrosis. Subtle fibrosis was identified as filamentous (fiber-like), dense fibrosis was identified as stratified hypocellular (paint-like) features in H.E. as well as Masson-Trichrome staining.

**counting include follicles that shows granulosa cell only.

†counting only follicles with visible oocyte structures.

developmental stage of these follicles were determined by morphological criteria of Gougeon and Chainy. In fresh ovarian tissue, nests of primordial follicles were dominantly identified. On the contrary, in frozen-thawed tissue, we could not detect the presence of follicles in one specimen. In addition, only morphologically atretic follicles were identified in one specimen. In grafted ovarian tissue, the presence of follicles was confirmed in only seven specimen (21%) (Table 1).

When we compared fibrotic area in cortical tissue according to the presence of follicles in specimens, fibrotic area was significantly larger in grafted tissue without follicles comparing to those of grafted tissue harbor follicles. We did not find significant difference in fibrotic area in frozen-thawed tissue according to the presence of follicles (Figure 3).

When we compare the distributions of developmental stages of follicles, we found significantly lower distributions of primordial follicles and higher distributions of growing follicles in grafted ovarian cortex comparing to those of fresh and frozen-thawed tissue ($p < 0.001$, Fisher's exact test). We did not find significant difference in these distributions between fresh and frozen-thawed ovarian tissue (Figure 4).

In TUNEL staining, we seldom find intense nuclear staining in fresh ovarian tissue. In frozen-thawed tissue, although intense nuclear staining was absent, stromal staining intensity was diffusely

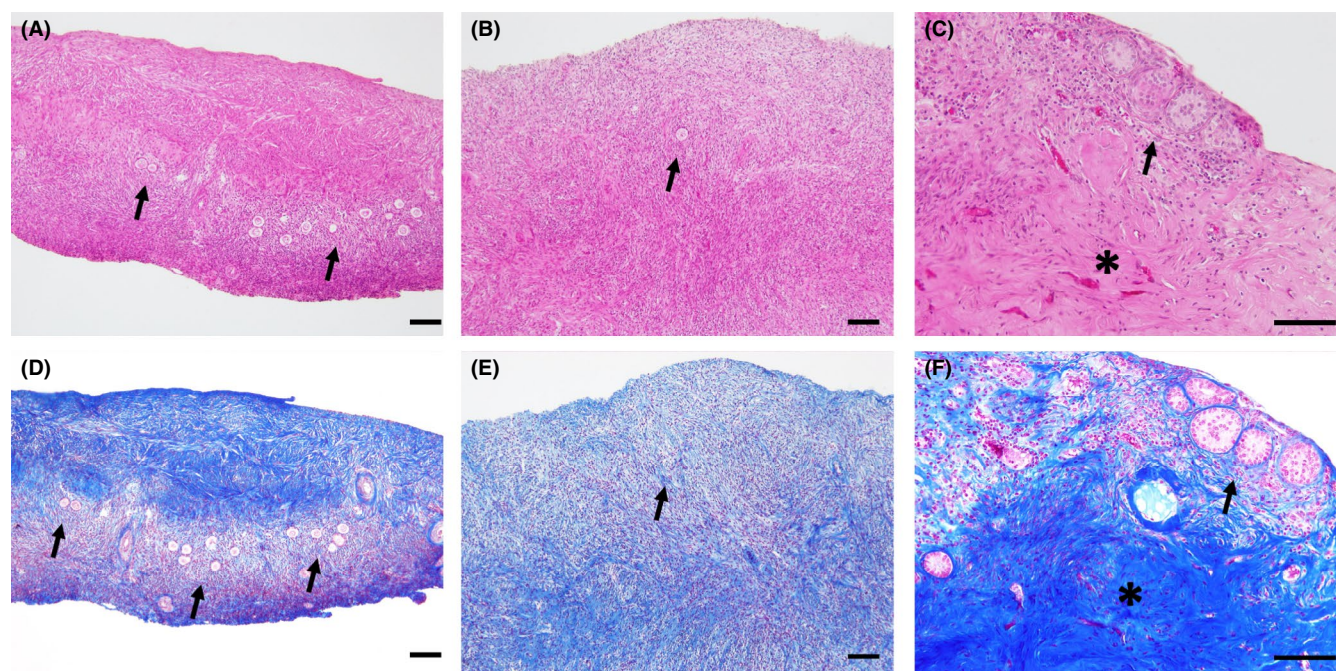


FIGURE 1 Histological appearance of human ovarian cortical tissue before and after cryopreservation and transplantation. Representative photomicrograph of ovarian cortical tissue of fresh cortical tissue that fixed just after biopsy (A and D), frozen by vitrification and thawed cortical tissue (B and E) and harvested cortical tissue 12 weeks after grafting (C and F). Fresh cortical tissue composed of superficial ovarian epithelium, tunica albuginea, cortical-specific stroma that harbor the nest of primordial follicles (black arrow), and transitional zone to ovarian medulla in stratified fashion (A). Masson-trichrome staining revealed moderately fibrotic feature of tunica albuginea (D). Stroma surrounding the nest of primordial follicles showed minimum fibrosis (D). Frozen-thawed cortical tissue with primordial follicle (black arrow) showed filamentous fibrotic stroma (B) that also confirmed by Masson-trichrome staining (E). In grafted cortical tissue, the nest of survived follicles was found (black arrow) with irregular stroma. Beneath the stroma, dense paint-like deposit of fibrosis is apparent (*) (C) that also confirmed by Masson-trichrome staining (F). Bar = 100 μ m

FIGURE 2 Degree of fibrosis in ovarian cortical tissue. The graph depicts the degree of fibrosis measured by the area of blue colored staining per cortical tissue. In grafted cortical tissue, fibrotic area is significantly increased comparing to those of fresh and frozen-thawed cortical tissue ($p < 0.001$, unpaired student's t-test). Statistical significance was not observed between fresh and frozen-thawed cortical tissue. Boxes represent the distance (interquartile range) between the first (25%) and third (75%) quartiles, and horizontal lines in the boxes represent median values. Blue horizontal line represents mean value and gray colored square box represent 95% confidence interval. Each dot represents exact value of individual case

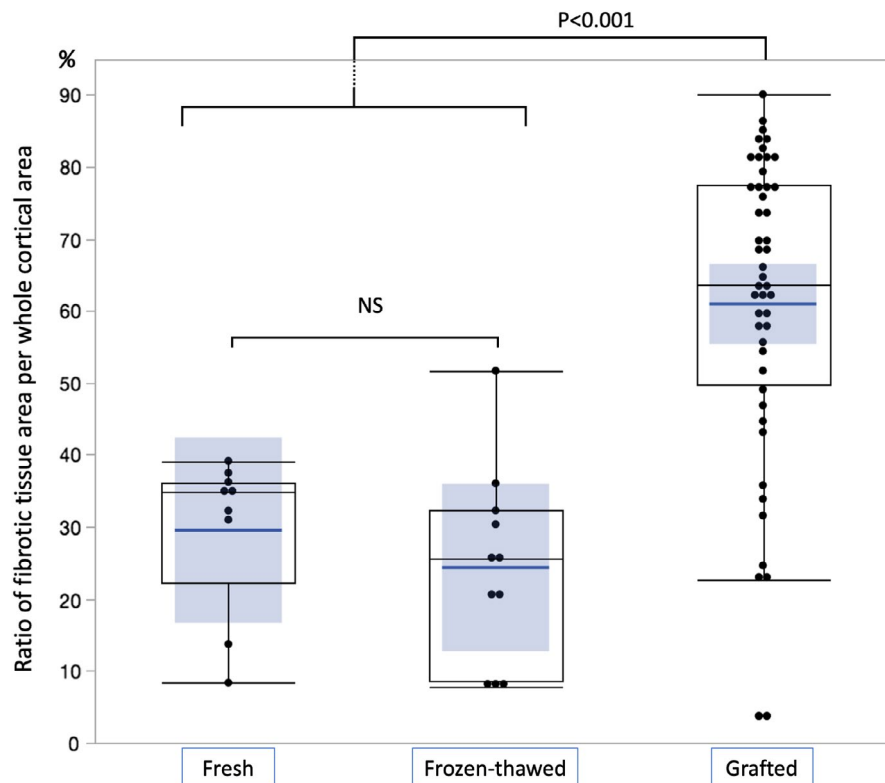
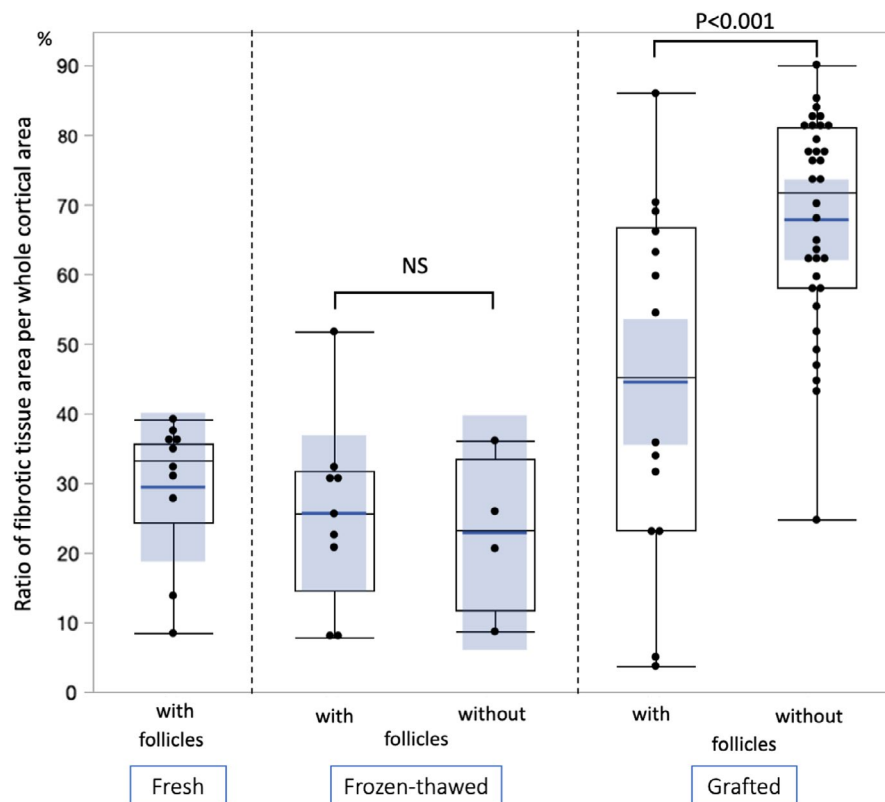


FIGURE 3 Difference in degree of fibrosis according to the presence of follicles in specimens. The graph compared the degree of fibrosis according to the presence of follicles in specimens. In grafted cortical tissue, specimens that contains follicles showed significantly larger fibrotic area comparing to those of specimens without follicles ($p < 0.001$, unpaired student's t-test). Statistical significance was not observed between specimens with and without follicles in frozen-thawed cortical tissue. In fresh tissue, all specimens contain follicles, and no comparison was performed. Boxes represent the distance (interquartile range) between the first (25%) and third (75%) quartiles, and horizontal lines in the boxes represent median values. Blue horizontal line represents mean value and gray colored square box represent 95% confidence interval. Each dot represents exact value of individual sample



increased. On the contrary, stromal staining was not increased in grafted tissue (Figure 5).

Immunohistochemistry for aSMA revealed distinct vascular wall smooth muscle cell staining irrespective of histological domain and/or experimental interventions (frozen-thawing or grafting).

In addition to vascular staining, we found perifollicular staining of aSMA in growing preantral and antral follicles in fresh cortical tissue (Figure 6D and E). On the contrary, we found decreased aSMA expressions in perifollicular area of secondary to early antral follicles in grafted cortical tissue (Figure 6E and G). When we analyze

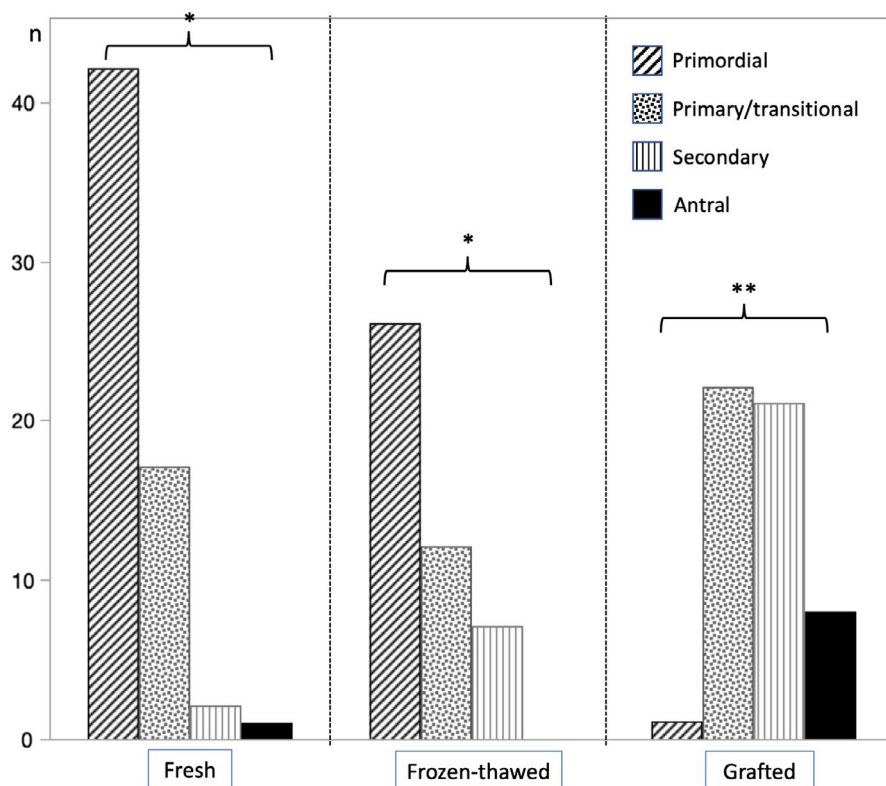


FIGURE 4 Distributions of developmental stage of follicles present in ovarian cortical tissue. The graph indicates the distributions of developmental stage of ovarian follicles according to the experimental interventions. In fresh and frozen-thawed cortical tissue, primordial follicle-dominant distributions are similar (*). These distributions shifted toward activated follicular growth that decrease in primordial stage and increase in the stage of primary thereafter in grafted ovarian cortical tissue (**) ($p < 0.001$, Fisher's exact test). Bar with oblique line indicates primordial follicles, Bar with dots indicates primary and transitional follicles, Bar with vertical line indicates secondary follicles, and black bar indicates antral follicles

staining score of stromal aSMA, these scores surrounding secondary follicles present in grafted tissue was significantly lower than those of frozen-thawed tissue (Figure 7, $*p = 0.0006$, unpaired student's *t*-test). As only one antral follicle was presented in fresh ovarian tissue and there were no antral follicles in frozen-thawed tissue, we could not perform statistical comparison of staining score of antral follicles. aSMA expressions were absent in stroma surrounding primordial follicles (Figure 6A and B); however, some specimens obtained after frozen-thawing or grafting showed increased aSMA staining surrounding primordial follicles (Figure 6C) though we did not find statistical significance in staining score between two groups (Figure 7).

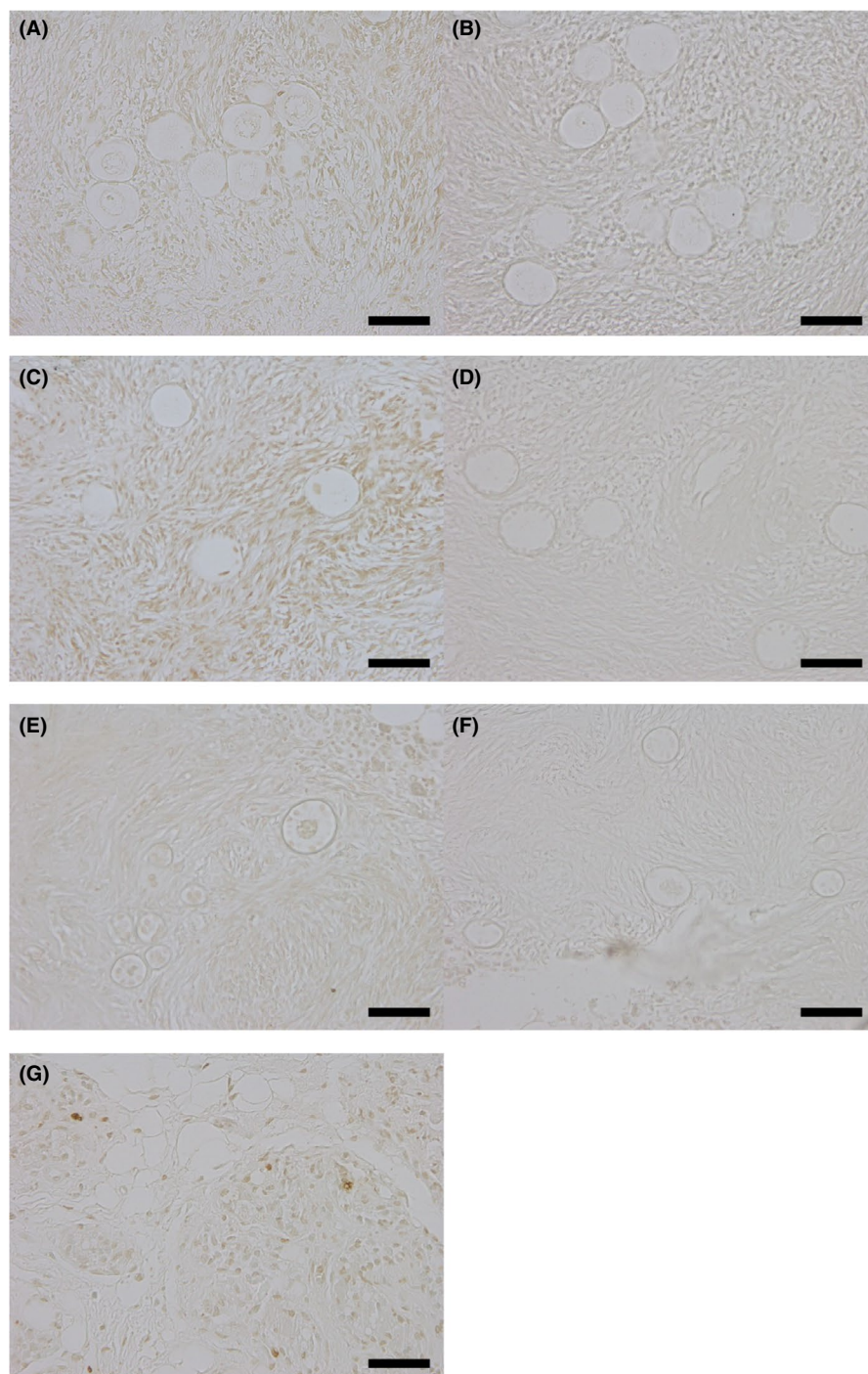
4 | DISCUSSION

Ovarian tissue cryopreservation (OTC) had been introduced to fertility preservation for women at the risk of premature ovarian insufficiency.¹ The American society for reproductive medicine (ASRM) had been issued committees opinion recently that commented these procedures cannot be considered as experimental anymore.¹⁹ OTC is becoming popular procedures though the utilization of frozen-stored ovarian tissue by auto-transplantation is limited. In addition, it has been argued that ovarian follicles in grafted ovarian tissue is exhausted and the longevity of ovarian functions of grafted tissue may be limited.^{4,5} Since the frozen-thawed ovarian tissue may transplant on to the residual ovary or pelvic peritoneal pocket near-by without vascular channels, ischemia and reperfusion tissue injury

may directly affect the fate of dormant primordial follicles in ovarian cortex.

Fibrosis may be the hallmark of aged (damaged) ovarian cortex.¹¹ The ovaries actively show morphological variability to maintain their functions through follicular growth to ovulation and corpus luteum formation, which are accompanied by vasculogenesis and tissue remodeling.²⁰ Along with these events, fibrotic changes in ovarian cortical stroma may be accumulated (deposited). Ovarian fibrosis is also evident in women had gonadotoxic chemotherapy and women with endometriosis,^{8–10} which are the risk of diminished ovarian reserve. On the other hand, pro-fibrotic conditions may be present in women with ovulatory dysfunctions, such as PCOS.²¹ Androgen induced ovarian fibrosis was reported in rodent PCOS models.²² Ovarian fibrosis may be associated with different types of ovarian dysfunctions that affect follicular growth. In this study, 12weeks after xenografting of human ovarian tissue, fibrosis is significantly increased comparing to those of frozen-thawed tissue. In addition, in grafted tissue, the proportion of growing follicle is increased, and primordial follicle is significantly decreased comparing to those of fresh and frozen-thawed cortical tissue, which were agree with previous reports.⁷ Cortical fibrosis may be the consequences of ischemia and focal inflammation after grafting. Normal cortical stroma with primordial follicles might have been replaced by fibrotic deposit. From our present study, as stromal TUNEL staining was increased after freezing and thawing in some tissue, fibrotic change after grafting might also be resulted from tissue damage by freezing and thawing procedures though we did not find increase in fibrotic area at the time of tissue thawing. It is possible that stress of freezing

FIGURE 5 Results of TUNEL staining. Representative photomicrograph of TUNEL staining of ovarian cortical tissue that contain dormant and growing early follicles and surrounding cortical stroma. (A) TUNEL staining of fresh ovarian cortex and (B) corresponding negative control section. (C) TUNEL staining of frozen/thawed ovarian cortex and (D) corresponding negative control section. Perifollicular stromal TUNEL staining is increased comparing to negative control. (E) TUNEL staining grafted ovarian cortical tissue and (F) corresponding negative control sections. (G) rat breast tissue was used for positive control, which showed spots of intense nuclear staining



and thawing in some ovarian pieces might enhanced fibrogenesis after grafting. To maintain the dormancy of primordial follicles, tissue rigidity constituted by cells and extracellular matrix (ECM) surrounding the nest of follicles in ovarian cortex are playing important roles.²³ Mechanical destructions of ovarian tissue may result in activation of primordial follicles, interacting hippo/AKT pathways.²⁴ Dissociations of surrounding stroma maintaining dormancy might activate primordial follicles and affect the distributions of developmental stages of follicles in the cortex. Stromal components surrounding follicular nests may be involved in the maintenance of follicular growth.

In this study, we evaluated the expression pattern of aSMA in ovarian cortical stroma. It is well known that aSMA is dominantly expressed in vascular smooth muscle cells. In addition, in normal ovarian tissue, its expressions were intensely found in the theca externa, focally identified in cortex medulla, and unstained in the theca internal layer.²⁵ These perifollicular aSMA immunoreactions increased during folliculogenesis, going from a thin positive layer around secondary follicles to a strong diffuse stain in mature follicles.²⁵ Cortical stromal cells may participate in follicular structure forming outer thecal layer and microvasculature by fibroblastic mesenchymal cell transition. The expression of aSMA is also considered as a marker of

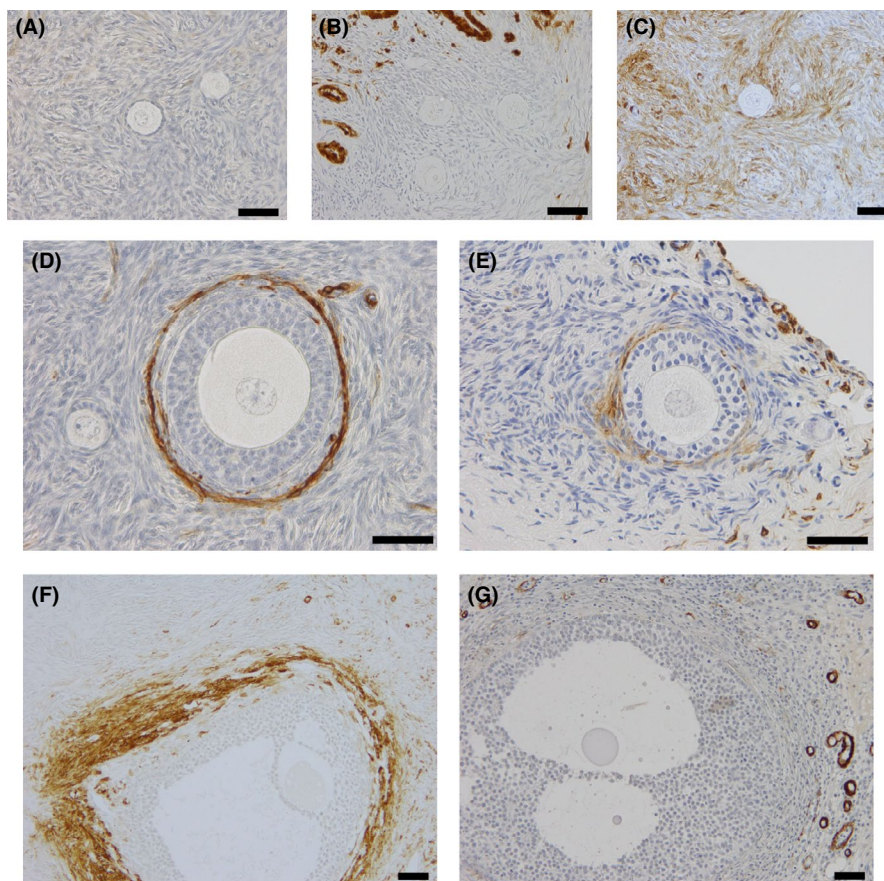


FIGURE 6 Expression and localization of alpha-smooth muscle actin in perifollicular ovarian stroma. Representative photomicrograph of perifollicular immunostaining of alpha-smooth muscle actin (aSMA) in ovarian cortical tissue. The expression of aSMA in stroma surrounding primordial follicles is absent (A, fresh cortical tissue; B, frozen-thawed cortical tissue) though some primordial follicles are present in aSMA positive stroma, which shows non-perifollicular distributions (C, frozen-thawed cortical tissue). The perifollicular expression of aSMA is apparent in preantral secondary follicle derived from fresh cortical tissue (D) and these expressions are also confirmed but decreased in perifollicular region of secondary follicle derived from grafted cortical tissue (E). The perifollicular expression of aSMA is continuously apparent in early antral follicle derived from fresh cortical tissue (F) and these expressions are decreased in perifollicular region of similar stage follicle derived from grafted cortical tissue (E). Bar = 100 μ m

fibroblast to myofibroblast transdifferentiation of ovarian connective tissue.²⁶ In this study, we observed reduction of perifollicular aSMA expressions in grafted tissue comparing to those of fresh or frozen-thawed ovarian cortical tissues. These results may indicate that altered regulation of stromal cell differentiation surrounding growing follicles in grafted tissue, which may affect proper growth of follicles. The results of assisted reproductive technique used in women with transplanted ovaries were reported to be compromised.²⁷ Alteration of follicular growth may be involved in decreased reproductive performance in women had auto-transplantation.

In grafted tissue, the distribution of growing follicle was increased, and primordial follicle is significantly decreased. These observations can be viewed as enhanced activation of follicles.²⁸ Invasive procedures of OTC and transplantation may cause atresia of growing follicles and decline in local AMH levels. Since AMH may act to maintain dormancy of primordial follicles, transient decline in growing follicles and local AMH levels by vitrification and grafting can result in activation of primordial follicles. Enhanced recruitment may recover the number of growing follicles and may result in

increased local AMH levels. On the other hand, fibrotic changes in stroma after grafting may not support appropriate follicular growth, which may result in atresia. We assume that the balance between activation of dormant follicles and atresia of growing follicles may be important to maintain ovarian reserve in grafted ovarian tissue. In mouse study, aged ovaries showed fibrosis and growth arrest at secondary stage,²⁹ which is contrary to our present study. As we mentioned formerly, ovarian fibrosis is associated with varieties of dysregulations of folliculogenesis. We speculate that severe inflammation caused by OTC and tissue grafting may cause follicle activation and atresia rather than developmental arrest of follicles.

To examine the efficacy of freezing and grafting methods in fertility preservation, xenotransplantation model using nude mice had been utilized.⁶ In xenotransplantation model using primate and non-primate animals, the efficacy of OTC utilizing slow freezing using programmed freezer had been widely evaluated. In oocyte and embryo cryopreservation, vitrification is widely applied in clinical practice. Vitrification is getting popular in cryopreservation methods in the field of assisted reproductive technology.¹² In OTC, vitrification is

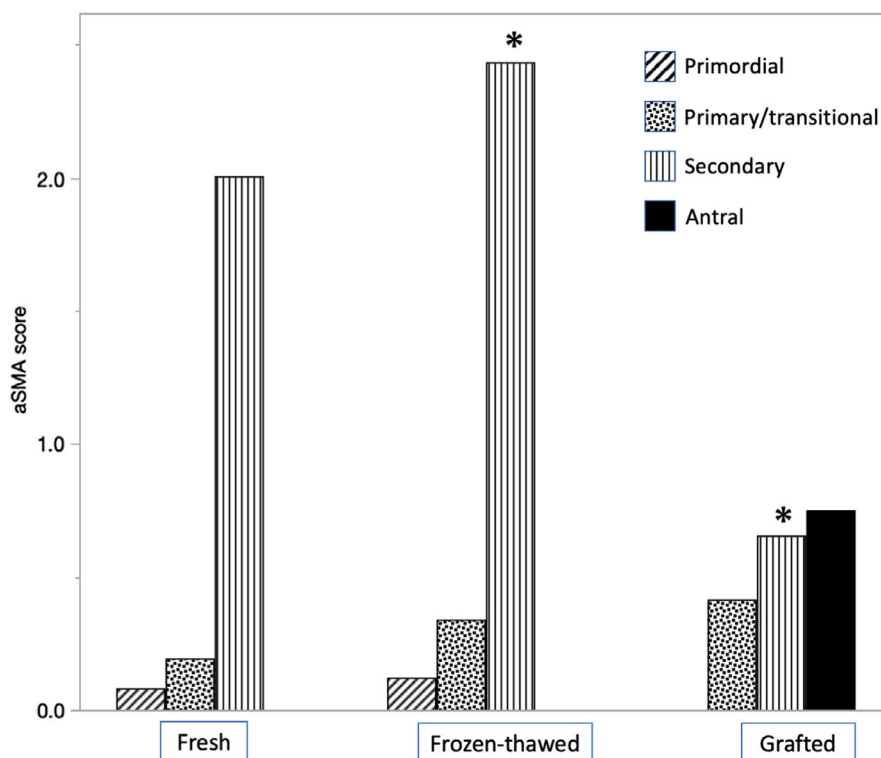


FIGURE 7 Comparison of aSMA immunostaining score. Perifollicular stromal aSMA immunostaining score of primordial follicles was low and not significantly different between fresh and frozen-thawed ovarian tissue. As only one primordial follicle was presented in grafted ovarian tissue, statistical comparison cannot be performed in this group. Perifollicular aSMA immunostaining score of primary/transitional follicles was neither significantly different among three groups. Perifollicular aSMA immunostaining score of secondary follicles presented in grafted ovarian tissue was significantly lower than those of frozen-thawed ovarian tissue (* $p = 0.0006$, unpaired student's *t*-test). As only one antral follicle was presented in fresh ovarian tissue and there were no antral follicles in frozen-thawed tissue, statistical comparison of staining score of antral follicles cannot be performed

still considered as research setting methods according to the guidelines of ESHRE.¹⁵ Several previous reports have been compared vitrification to slow freezing using xenografting models with inconclusive results.^{30–32} In this study, we collected ovarian tissue 12 weeks after grafting to confirm follicular growth from primordial stage. From our present study, although we could obtain follicular growth beyond antral stage after vitrification and grafting, freezing and thawing procedures may affect the viability of ovarian tissue after grafting. Latent damage and dysregulations of stromal cells surrounding follicles after freezing and thawing cannot be ruled out. In addition, the causal relationship between fibrosis and diminished ovarian reserve could not be confirmed in this study and further research may be needed.

Limited numbers of cortical grafts that harbor follicles to evaluate the status of follicles and surrounding stroma may be the limitation of our study. Low survival rate and the heterogeneity of human ovarian cortex may be an inherent nature of human ovarian tissue transplantation in this study setting. Although the freezing and thawing and avascular grafting may be the cause of severe fibrosis and altered follicular growth, definite conclusions cannot be drawn from present study. Further clinical and laboratory investigation may be warranted to improve our techniques and deepen our understanding of the physiology of human ovaries.

In conclusion, vitrified-thawed human ovarian cortical tissue grafted to nude mice resulted marked fibrosis and concomitant reduction of cortex specific stroma accompanied by altered follicular growth. Perifollicular expression of aSMA surrounding growing follicle also reduced in grafted tissue. These histological features may indicate that OTC by vitrification and transplantation by avascular grafting can cause stromal fibrosis that may be related to limited longevity of transplanted ovarian tissue.

ACKNOWLEDGEMENT

This research was supported in part by the Grants-in-Aid for Scientific Research (grant no. 18K09294 and 16K20197 to M.K. and N.M.) from Japan Society for the Promotion of Sciences.

CONFLICT OF INTEREST

The authors declare that they have no conflict of interests.

HUMAN RIGHTS STATEMENTS AND INFORMED CONSENT

All procedures followed were in accordance with the ethical standards of the responsible committee on human experimentation (institutional and national) and with the Helsinki Declarations of 1964

and its later amendments. Informed consent was obtained from all patients for being included in the study.

APPROVAL BY ETHICS COMMITTEE

This study was approved by Nagasaki University Hospital Clinical Research Ethics Committee and Ethical Committee of Institute of Laboratory Animals.

CLINICAL TRIAL REGISTRY

This study was not a clinical trial.

ORCID

Michio Kitajima  <https://orcid.org/0000-0002-2661-9034>

REFERENCES

- Donnez J, Dolmans MM. Fertility Preservation in Women. *N Engl J Med*. 2017;26(377):1657-1665. doi:10.1056/NEJMra1614676
- Dolmans MM, Falcone T, Patrizio P. Importance of patient selection to analyze in vitro fertilization outcome with transplanted cryopreserved ovarian tissue. *Fertil Steril*. 2020;114:279-280. doi:10.1016/j.fertnstert.2020.04.050
- Donnez J, Dolmans MM, Demylle D, et al. Livebirth after orthotopic transplantation of cryopreserved ovarian tissue. *Lancet*. 2004;364:1405-1410. doi:10.1016/S0140-6736(04)17222-X
- Jensen AK, Kristensen SG, Macklon KT, et al. Outcomes of transplantations of cryopreserved ovarian tissue to 41 women in Denmark. *Hum Reprod*. 2015;30:2838-2845. doi:10.1093/humrep/dev230
- Roness H, Meirow D. FERTILITY PRESERVATION: follicle reserve loss in ovarian tissue transplantation. *Reproduction*. 2019;158:F35-F44. doi:10.1530/REP-19-0097
- Dolmans MM, Martinez-Madrid B, Gadisseux E, et al. Short-term transplantation of isolated human ovarian follicles and cortical tissue into nude mice. *Reproduction*. 2007;134:253-262. doi:10.1530/REP-07-0131
- Amorim CA, David A, Dolmans MM, Camboni A, Donnez J, Van Langendonck A. Impact of freezing and thawing of human ovarian tissue on follicular growth after long-term xenotransplantation. *J Assist Reprod Genet*. 2011;28:1157-1165. doi:10.1007/s10815-011-9672-z
- Meirow D, Dor J, Kaufman B, et al. Cortical fibrosis and blood-vessels damage in human ovaries exposed to chemotherapy. Potential mechanisms of ovarian injury. *Hum Reprod*. 2007;22:1626-1633. doi:10.1093/humrep/dem027
- Shai D, Aviel-Ronen S, Spector I, et al. Ovaries of patients recently treated with alkylating agent chemotherapy indicate the presence of acute follicle activation, elucidating its role among other proposed mechanisms of follicle loss. *Fertil Steril*. 2021;115:1239-1249. doi:10.1016/j.fertnstert.2020.11.040
- Kitajima M, Dolmans MM, Donnez O, Masuzaki H, Soares M, Donnez J. Enhanced follicular recruitment and atresia in cortex derived from ovaries with endometriomas. *Fertil Steril*. 2014;101:1031-1037. doi:10.1016/j.fertnstert.2013.12.049
- Briley SM, Jasti S, McCracken JM, et al. Reproductive age-associated fibrosis in the stroma of the mammalian ovary. *Reproduction*. 2016;152:245-260. doi:10.1530/REP-16-0129
- Rienzi L, Gracia C, Maggilli R, et al. Oocyte, embryo and blastocyst cryopreservation in ART: systematic review and meta-analysis comparing slow-freezing versus vitrification to produce evidence for the development of global guidance. *Hum Reprod Update*. 2017;23:139-155. doi:10.1093/humupd/dmw038
- Rivas Leonel EC, Lucci CM, Amorim CA. Cryopreservation of human ovarian tissue: a review. *Transfus Med Hemother*. 2019;46:173-181. doi:10.1159/000499054
- Shi Q, Xie Y, Wang Y, Li S. Vitrification versus slow freezing for human ovarian tissue cryopreservation: a systematic review and meta-analysis. *Sci Rep*. 2017;7:8538. doi:10.1038/s41598-017-09005-7
- ESHRE Guideline Group on Female Fertility Preservation, Anderson RA, Amant F, Braat D, et al. ESHRE guideline: female fertility preservation. *Hum Reprod Open*. 2020;2020(4):hoaa052. doi:10.1093/hropen/hoaa052. eCollection 2020
- Suzuki N, Yoshioka N, Takae S, et al. Successful fertility preservation following ovarian tissue vitrification in patients with primary ovarian insufficiency. *Hum Reprod*. 2015;30:608-615. doi:10.1093/humrep/deu353
- Kitajima M, Defrère S, Dolmans MM, et al. Endometriomas as a possible cause of reduced ovarian reserve in women with endometriosis. *Fertil Steril*. 2011;96:685-691. doi:10.1016/j.fertnstert.2011.06.064
- Gougeon A, Chainy GB. Morphometric studies of small follicles in ovaries of women at different ages. *J Reprod Fertil*. 1987;81:433-442. doi:10.1530/jrf.0.0810433
- Practice Committee of the American Society for Reproductive Medicine. Fertility preservation in patients undergoing gonadotoxic therapy or gonadectomy: a committee opinion. *Fertil Steril*. 2019;112:1022-1033. doi:10.1016/j.fertnstert.2019.09.013
- Feng Y, Tamadon A, Hsueh AJW. Imaging the ovary. *Reprod Biomed Online*. 2018;36:584-593. doi:10.1016/j.rbmo.2018.02.006
- Gomes VA, Vieira CS, Jacob-Ferreira AL, et al. Imbalanced circulating matrix metalloproteinases in polycystic ovary syndrome. *Mol Cell Biochem*. 2011;353:251-257. doi:10.1007/s11010-011-0793-6
- Zhang X, Zhang C, Shen S, et al. Dehydroepiandrosterone induces ovarian and uterine hyperfibrosis in female rats. *Hum Reprod*. 2013;28:3074-3085. doi:10.1093/humrep/det341
- Woodruff TK, Shea LD. A new hypothesis regarding ovarian follicle development: ovarian rigidity as a regulator of selection and health. *J Assist Reprod Genet*. 2011;28:3-6. doi:10.1007/s10815-010-9478-4
- Kawamura K, Ishizuka B, Hsueh AJW. Drug-free in-vitro activation of follicles for infertility treatment in poor ovarian response patients with decreased ovarian reserve. *Reprod Biomed Online*. 2020;40:245-253. doi:10.1016/j.rbmo.2019.09.007
- Santini D, Ceccarelli C, Leone O, et al. Smooth muscle differentiation in normal human ovaries, ovarian stromal hyperplasia and ovarian granulosa-stromal cells tumors. *Mod Pathol*. 1995;8:25-30. doi:10.1016/0893-6080(94)00059-u
- Ding D, Wang X, Chen Y, Benagiano G, Liu X, Guo SW. Evidence in support for the progressive nature of ovarian endometriomas. *J Clin Endocrinol Metab*. 2020;105:dga189. doi:10.1210/clinem/dga189
- Andersen ST, Pors SE, Poulsen LC, et al. Ovarian stimulation and assisted reproductive technology outcomes in women transplanted with cryopreserved ovarian tissue: a systematic review. *Fertil Steril*. 2019;112:908-921. doi:10.1016/j.fertnstert.2019.07.008
- Gavish Z, Peer G, Roness H, Cohen Y, Meirow D. Follicle activation and 'burn-out' contribute to post-transplantation follicle loss in ovarian tissue grafts: the effect of graft thickness. *Hum Reprod*. 2014;29:989-996. doi:10.1093/humrep/deu015
- Umehara T, Richards JS, Shimada M. The stromal fibrosis in aging ovary. *Aging (Albany NY)*. 2018;10:9-10. doi:10.18632/aging.101370
- Lee S, Ryu KJ, Kim B, Kang D, Kim YY, Kim T. Comparison between slow freezing and vitrification for human ovarian tissue cryopreservation and xenotransplantation. *Int J Mol Sci*. 2019;20:3346. doi:10.3390/ijms20133346

31. Wall MA, Padmanabhan V, Shikanov A. Hormonal stimulation of human ovarian xenografts in mice: studying folliculogenesis, activation, and oocyte maturation. *Endocrinology*. 2020;161:bqaa194. doi:10.1210/endocr/bqaa194
32. Kometas M, Christman GM, Kramer J, Rhoton-Vlasak A. Methods of ovarian tissue cryopreservation: is vitrification superior to slow freezing?-ovarian tissue freezing methods. *Reprod Sci*. ;28(12):3291-3302. doi:10.1007/s43032-021-00591-6. Online ahead of print.

How to cite this article: Kitajima M, Murakami N, Kitajima Y, et al. Accumulation of fibrosis and altered perfollicular stromal differentiation in vitrified-thawed human ovarian tissue xenografted to nude mice.. *Reprod Med Biol*. 2022;21:e12451. doi:[10.1002/rmb2.12451](https://doi.org/10.1002/rmb2.12451)