

Treatment results of nondamaging retinal laser therapy in diabetic macular edema

Burcu P. Gültekin 

Ther Adv Ophthalmol

2022, Vol. 14: 1–7

DOI: 10.1177/
25158414211063284

© The Author(s), 2022.
Article reuse guidelines:
sagepub.com/journals-
permissions

Abstract

Background: Subthreshold nondamaging retinal laser therapy (NRT) provides a greater safety profile than conventional laser methods, but more data is needed on the efficacy and safety of subthreshold NRT in diabetic macular edema.

Purpose: To evaluate the efficacy and safety of NRT for the treatment of clinically significant macular edema (CSME) that is partially responsive or resistant to intravitreal anti-vascular endothelial growth factor (anti-VEGF) treatment.

Methods: This was a retrospective case series study. Fifty eyes of 38 diabetic patients with CSME previously treated with at least 6-monthly intravitreal bevacizumab injections with/without intravitreal Ozurdex therapy were evaluated. The patients received 577-nm yellow wavelength laser therapy with PASCAL laser system (Topcon Medical Laser Systems, Santa Clara, CA, USA). Best-corrected visual acuity (BCVA) and central subfield thickness (CST) were evaluated before and 1, 3, 6, 12 and 24 months after laser treatment.

Results: Baseline mean CST was $368.06 \pm 86.9 \mu\text{m}$. The mean CST values at the 1-, 3-, 6-, 12-, and 24-month visits were 336.93 ± 79.8 , 352.40 ± 113.5 , 336.36 ± 109.3 , $325.10 \pm 104 \mu\text{m}$, and $310.08 \pm 84.7 \mu\text{m}$, respectively. The mean CST decreased significantly at the first ($p = 0.002$) and second year visits ($p < 0.001$) when compared with pretreatment values. Although visual acuity was improved at the first year compared with baseline, this difference was not statistically significant ($p = 0.03$). There was no significant difference in visual acuities between pretreatment and posttreatment visits. During 24-month follow-up, while 37 eyes were treated with [mean: 5.7 ± 3.4 (1–14)] intravitreal anti-VEGF injections, 3 eyes were administered single-dose intravitreal steroids. Additional intravitreal injections were not required in 10 (20%) eyes.

Conclusion: NRT is effective by itself or in combination with anti-VEGF agents in diabetic macular edema that is partially responsive or resistant to previous intravitreal injections. The role in treating this disorder should be assessed in more detail with prospective controlled studies.

Keywords: anti-vascular endothelial growth factor, diabetic macular edema, nondamaging laser therapy

Received: 4 April 2021; revised manuscript accepted: 10 November 2021.

Introduction

Diabetic macular edema (DME) is the most significant cause of impaired vision in the working-age population.¹ The disorder has been reported in up to 29% in patients with a diabetes duration of 20 years or longer.² Focal laser photocoagulation of leaking microaneurysms increases the chance of visual improvement and reduces the incidence of persistent macular edema, according to the results reported by the Early Treatment

Diabetic Retinopathy Study (ETDRS).³ ETDRS has shown that laser photocoagulation can reduce the visual acuity loss in clinically significant macular edema by 57% during 3 years of follow-up.⁴

The intravitreal administration of anti-vascular endothelial growth factor (anti-VEGF) agents has been shown to be an effective treatment modality for DME.^{5,6} However, the frequent injection requirement is associated with side effects.

Correspondence to:
Burcu P. Gültekin
Department of
Ophthalmology, Ministry
of Health Ankara City
Hospital, 06800 Ankara,
Turkey.
drburcupolat@gmail.com

Frequent long-term injections may result in widening of the foveal avascular zone and decreased visual acuity.⁷ DME may persist or recur despite repeated injections and can result in various risks including endophthalmitis. This treatment method is also expensive.^{8–10} Moreover, combination therapy may reduce the intensity of the laser burns with the effect of the antiangiogenic drugs drying the macula.¹¹ Laser photocoagulation is still needed in addition to anti-VEGF therapy in the treatment of macular edema. The above findings indicate an important continuing role of laser photocoagulation in DME treatment.

Retinal treatment with a standard laser using thermal energy may have adverse effects such as decreased visual fields, color vision, and visual acuity, and the development of scotoma. In addition, the size of the laser burn increases by 16% every year for up to 4 years.¹² Pattern scanning laser (PASCAL) provides subthreshold therapy using low energy and short pulses while alleviating DME and reducing side effects.¹³ Using non-damaging laser technology, it is possible to induce biochemical stimulation of the retina without creating thermal tissue damage during treatment.¹⁴

Advances in new laser systems provide several therapeutic advantages. Nondamaging retinal laser therapy (NRT) has been developed for the treatment of macular disorders including DME, chronic central serous chorioretinopathy, and retinal vein occlusions. This treatment modality allows multiple treatments when required by reducing the destruction of the photoreceptors near the fovea. This desired effect is provided by selective stimulation of the retinal pigment epithelium (RPE).^{15,16}

In this study, we aimed to evaluate the efficacy and safety of NRT (PASCAL Synthesis, Topcon Medical Laser Systems, Santa Clara, CA, USA) for the treatment of clinically significant diabetic macular edema (CSME) refractory to at least 6-monthly intravitreal anti-VEGF injections with/without intravitreal steroids.

Methods

The medical records of 38 patients (16 men and 22 women) treated for clinically significant DME between March 2018 and April 2020 were reviewed. Patients who had diabetes mellitus type 2 and related macular edema were included.

All participants underwent a detailed ophthalmic examination at baseline, follow-up visits at 1, 3, 6, 12, and 24 months. Nondamaging laser therapy was applied to patients who had macular edema with a mean central subfield thickness (CST) of $>300\ \mu\text{m}$ and had received previous at least 6-monthly intravitreal bevacizumab injections. Two eyes were also received intravitreal Ozurdex (Allergan Inc., Irvine, CA, USA) therapy. NRT was performed using 577-nm yellow wavelength laser system (PASCAL Synthesis, Topcon Medical Laser Systems). Laser power was adjusted relative to visible titration using Endpoint Management (EpM) algorithm at 30% of the titration energy. Cases with retinal vein occlusion, previous vitrectomy, epiretinal membrane, or other retinal disorders were excluded.

All patients underwent complete ophthalmic examination including measurement of Snellen best-corrected visual acuity (BCVA), intraocular pressure, slit lamp biomicroscopy and fundus examination with a 90-D lens, color fundus photography, and spectral domain optical coherence tomography (OCT) imaging (Cirrus, Carl Zeiss Meditec, Dublin, CA, USA). The power was determined via establishing the threshold energy by creating a barely visible burn at a nonedematous area inside the vascular arcades using the lowest possible energy. The NRT algorithm was performed with following titration. This algorithm uses 30% of the determined threshold power with a duration of 15 ms in a continuous mode, $200\ \mu\text{m}$ spot size with a spacing of 0.25 spot. Laser was applied in a grid pattern from the center of the fovea for 360° covering both the thickened and nonthickened retina. Treatment was performed using the round macular pattern with $r_{in} = 700\ \mu\text{m}$ excluding the fovea with landmarks on. The area centralis lens was used for the treatment. Patients were followed at monthly intervals for 3 months without any additional treatment. Retreatment was administered after 3 months as further laser if CST is $\geq 300\ \mu\text{m}$ or BCVA decreases >5 letters. Pharmacological treatment was performed with more severe edema. Laser treatment was applied if the visual acuity was not less than 20/400 or 1.3 logMAR.

Statistical analysis was performed using the SPSS v18 software (SPSS Inc., Chicago, IL, USA). Data distribution for normality was assessed using the Kolmogorov–Smirnov test. According to the data distribution, the Friedman test was used for comparing the groups in terms of

macular thickness and visual acuity. A p value of <0.003 after Bonferroni correction was considered statistically significant.

Results

The study subjects included 16 (42.1%) males and 22 (57.9%) females with a mean age of 63.7 ± 8.2 (42–80) years (Table 1).

The baseline mean CST was $368.06 \pm 86.9 \mu\text{m}$. The mean CST values at the 1-, 3-, 6-, 12-, and 24-month visits were 336.93 ± 79.8 , 352.40 ± 113.5 , 336.36 ± 109.3 , $325.10 \pm 104 \mu\text{m}$, and $310.08 \pm 84.7 \mu\text{m}$, respectively. There was no statistically significant difference between the CSTs before and after laser treatment at the first month ($p = 0.08$), third month ($p = 0.36$), and sixth month ($p = 0.04$). However, there was a significant decrease in CST at the first year ($p = 0.002$) and second year ($p < 0.001$) (Figure 1). Improvement by over 20% of CST was observed in 7 eyes (14%) at month 3, in 12 eyes (24%) at month 6, in 15 eyes (30%) at the first year, and in 22 eyes (44%) second year.

Mean BCVA value was 0.51 ± 0.38 logMAR before laser therapy. Mean visual acuity values at the 1-, 3-, 6-, 12-month visits were 0.55 ± 0.35 ,

Table 1. Baseline characteristics.

Variable	
Gender, no. of patients (%)	
Male	16 (42.1)
Female	22 (57.9)
Age, (mean \pm SD) [range, year]	63.7 ± 8.2 [42–80]
Retinopathy severity, no. of eyes (%)	
Mild NPDR	7 (14)
Moderate NPDR	28 (56)
PDR	15 (30)
SD, standard deviation; NPDR, non-proliferative diabetic retinopathy; PDR, proliferative diabetic retinopathy.	

0.52 ± 0.33 , 0.50 ± 0.34 , and 0.47 ± 0.35 logMAR, respectively. The mean BCVA at the 24-month visit was 0.57 ± 0.38 logMAR. Improvement by 2 or more lines occurred in 6 eyes (12%) and by 0–2 lines in 10 eyes (20%), while there was a decrease of 0–2 lines in 23 eyes (46%) and more than 2 lines in 2 eyes (4%). At the end of follow-up, 16 eyes (32%) had better and 9 eyes (18%) stabilized visual outcomes. The

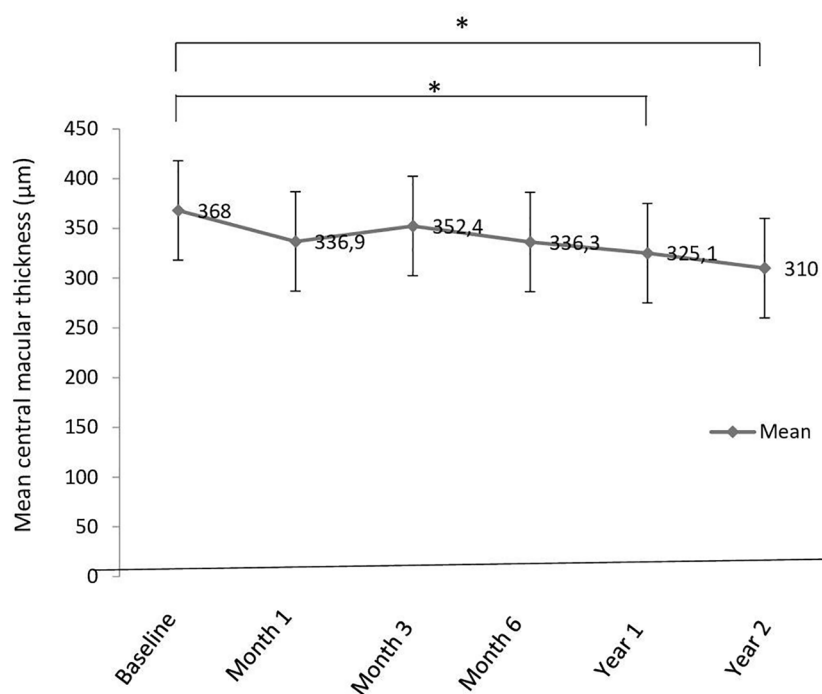


Figure 1. Mean central macular thickness (CMT) (μm) at baseline and follow-up period. Mean CMT was significantly decreased at the first year ($p = 0.002$) and second year ($p < 0.001$) compared with baseline.

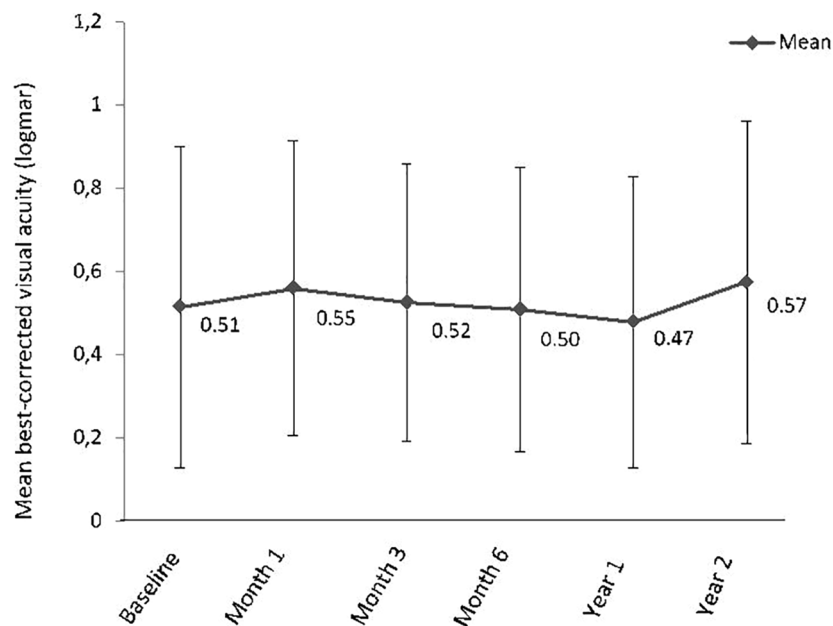


Figure 2. Mean best-corrected visual acuity (logMAR) at baseline and follow-ups.

p values for the statistical difference from the baseline BCVA were 0.14, 0.78, 0.86, 0.03, and 0.11 at months 1, 3, 6, 12, and the final follow-up, respectively (Figure 2). Although visual acuity was improved at the first year compared with baseline, this difference was not statistically significant (*p* = 0.03). Visual acuity changes were not found significantly different between the first visit and last outcomes.

Additional intravitreal injections were required at the 3-month in 4 eyes (12%), 6-month in 8 eyes (16%), 1-year in 11 eyes (22%), and 24-month follow-up in 40 eyes (80%) as anti-VEGF injections. No additional intravitreal injections were needed during the follow-up period in 10 (20%) eyes (Table 2).

NRT was administered in a grid pattern (Figure 3). The laser treatment was conducted once in 19 eyes (38%), twice in 15 eyes (30%), and thrice in 16 eyes (32%), according to the improvement

in DME. A mean number of 2.5 ± 0.52 (2–3) NRT sessions were performed in 10 eyes without additional intravitreal injection therapy. The interval between two sessions was 3 months.

Fundus autofluorescence (FAF) images were evaluated before and after the laser treatment. The test spots were detected as hyporeflective spots on the images. There were no laser spots detected in the macular region.

None of the patients had adverse events of laser photocoagulation such as laser scars or any macular complication.

Discussion

The laser therapy with the 577-nm yellow wavelength affects both melanin and oxyhemoglobin and is absorbed minimally by macular xanthophylls.¹⁶ The advantages of the longer wavelength of the yellow laser have been reported in many studies. These

Table 2. Follow-up period after laser treatment.

	Baseline	3 months	6 months	12 months	24 months
BCVA (mean, logMAR)	0.51	0.52	0.50	0.47	0.57
CMT (mean, μm)	368	352	336	325	310
BCVA, best-corrected visual acuity; CMT, central macular thickness. Further treatment (no. of eyes) 4/50 (12%) 8/50 (16%) 11/50 (22%) 40/50 (80%)					




Figure 3. Nondamaging retinal therapy with Endpoint Management. Red dots indicate the landmarks (100% energy, optional); yellow dots represent the area to be treated at 30% energy.

advantages include less scattering on the ocular tissues and deeper penetration into the vascular and pigmented tissues.^{17,18} The Diabetic Retinopathy Clinical Research Network¹⁹ has reported no advantage or anatomical difference for green or yellow wavelength.

NRT is a treatment modality that uses EpM titration protocol for optimizing the therapeutic effect of the laser at the subvisible levels. In developed retinal thermal models, it has been shown that thermal denaturation of tissue appeared for pulse durations exceeding 50 μ s. This temperature-dependent chemical reaction defines cellular responses, such as heat-shock protein expression, and is emerging by the reduction in concentration of the critical molecular components. The temperature-dependent reaction rate is represented by the Arrhenius equation that is parameterized by an activation energy and assumes the absence of cellular repair during hyperthermia. The total effect of this process is described by the integral of the denaturation rate over the duration of hyperthermia. Different levels of Arrhenius integral correspond to different clinical grades of retinal lesions. Arrhenius integral of $\Omega = 1$ is corresponding to the damage threshold of RPE. EpM protocol allows titration of the laser energy for treatment in every patient based on the test (titration) lesions. The linear steps in pulse energy produce a barely visible burn at a particular duration. We performed the laser treatment at 30% of the titrated energy,

which was the level established as the highest non-damaging setting in previous studies. Treatment was applied with 0.25-spot diameter spacing between the laser spots to maximize the therapeutic response as described before.^{15,20–23}

NRT promotes RPE repair by increasing metabolism. The visual function may therefore be preserved with less damage to the retinal nerve fiber layer (RNFL).²⁴ We found better visual outcomes in 32% and stabilization in 18% of eyes at the 24-month follow-up. The reason could be less inflammatory reaction and retinal damage in the RNFL, as described in previous studies.^{22,23}

A randomized controlled study comparing threshold and subthreshold laser applied at 50% of the titrated energy has found decreased macular edema in both groups but with no statistically significant difference. However, a significant decrease of the CST at the 3- and 6-month follow-up was reported with the subthreshold laser.²⁵ We similarly detected a significant decrease in CST at the 1- and 2-year visits. Hamada *et al.*²⁶ reported 10 eyes with DME treated using EpM in the PASCAL system. They observed a significant decrease in mean CST but no significant change in the mean BCVA at 6 months. The mean retinal sensitivity also did not differ significantly from the baseline. In contrast to our study, they suggested that their protocol using 50% EpM energy may have caused mild damage to the RPE as indicated by the FAF changes.

A retrospective study compared a group of 19 eyes with DME treated with micropulse laser to a matched control group treated with ranibizumab injections without micropulse laser revealed that addition of subthreshold laser may cause to a significant reduction in the burden of anti-VEGF injections.²⁷ Inagaki *et al.*²⁸ compared 577- and 810-nm micropulse laser photocoagulation combined with direct photocoagulation to microaneurysms in DME. They reported reduced additional laser or pharmacological treatment rate and maintained visual acuity in both of the groups within 12 months. In addition, lower power was required with 577-nm laser apparatus.

There was a significant decrease in CST at the first and second year compared with the baseline. However, the additional intravitreal injection therapy may also have contributed to the decrease in CST in these cases. Although additional intravitreal injections were not applied in 10 eyes (20%) by the end of the follow-up, NRT was applied with a mean number of 2.5 ± 0.52 (2-3) in these eyes. Our findings may indicate reduced need for intravitreal injections in these cases, providing an important advantage in the follow-up period, although there was not a control group.

Previous data have shown that barely visible burns have an effect at the level of the IS/OS and apical RPE.¹³ The spatial localization of fundus autofluorescence changes were confirmed with OCT and correlated with laser-burn-tissue interactions over 3 months.²¹ Therefore, retreatment was applied after 3 months. As anti-VEGF therapy and NRT achieve their effects through different pathways, using NRT may provide more efficacy by itself or in combination with anti-VEGF agents in DME.

We applied laser therapy to the macula multiple times when needed according to the DME improvement. This indicates that the improvement observed with NRT may actually diminish over time. However, retreatment was safe and effective and no retinal damage was observed during follow-up. Lavinsky *et al.*²² have reported that retreatment results were even better than with the initial laser application in some cases. This effect has been suggested due to the less retinal edema during retreatment session after the first application.

The limitations of the present study include the relatively small sample size and the absence of a

control group. In addition, confounding factors such as duration of diabetes, how well the diabetes was controlled, of diabetes, and hypertension may have contributed to the different therapeutic responses in diabetic cases.

In conclusion, laser photocoagulation using NRT may be effective in the treatment of DME that is partially responsive or resistant to previous intravitreal injections. However, the efficacy and reliability should be evaluated in more detail with prospective controlled studies.

Author contribution

Dr.Burcu Polat Gültekin: Conceptualization; Data curation; Writing-original draft; Revisions & editing.

Conflict of interest statement

The author declared no potential conflicts of interest with respect to the research, authorship, and/or publication of this article.

Funding

The author received no financial support for the research, authorship, and/or publication of this article.

Ethical approval

This study was approved by the institutional review board of Ankara Numune Training and Research Hospital (E-17-1204, 31.01.2018). All patients provided written informed consent. The study adhered to the tenets of the Declaration of Helsinki.

ORCID iD

Burcu P. Gültekin  <https://orcid.org/0000-0001-9121-3041>

References

1. Kim EJ, Lin WV, Rodriguez SM, *et al.* Treatment of diabetic macular edema. *Curr Diab Rep* 2019; 19: 1–10.
2. Klein R, Klein BE, Moss SE, *et al.* The Wisconsin epidemiologic study of diabetic retinopathy. IV. Diabetic macular edema. *Ophthalmology* 1984; 91: 1464–1474.
3. Early photocoagulation for diabetic retinopathy. ETDRS report number 9. *Ophthalmology* 1991; 98: 766–785.
4. Photocoagulation for diabetic macular edema. Early Treatment Diabetic Retinopathy Study

- report number 1. *Arch Ophthalmol* 1985; 103: 1796–1806.
5. Erol N, Gursay H, Kimyon S, *et al.* Vision, retinal thickness, and foveal avascular zone size after intravitreal bevacizumab for diabetic macular edema. *Adv Ther* 2012; 29: 359–369.
 6. Minami Y, Nagaoka T, Ishibazawa A, *et al.* Short-term effects of intravitreal ranibizumab therapy on diabetic macular edema. *BMC Ophthalmol* 2017; 17: 28.
 7. Tolentino M. Systemic and ocular safety of intravitreal anti-VEGF therapies for ocular neovascular disease. *Surv Ophthalmol* 2011; 56: 95–113.
 8. Pozarowska D and Pozarowski P. The era of anti-vascular endothelial growth factor (VEGF) drugs in ophthalmology, VEGF and anti-VEGF therapy. *Cent Eur J Immunol* 2016; 41: 311–316.
 9. Gregori NZ, Flynn HW Jr, Schwartz SG, *et al.* Current infectious endophthalmitis rates after intravitreal injections of anti-vascular endothelial growth factor agents and outcomes of treatment. *Ophthalmic Surg Lasers Imaging Retina* 2015; 46: 643–648.
 10. van Asten F, Michels CTJ, Hoyng CB, *et al.* The cost-effectiveness of bevacizumab, ranibizumab and aflibercept for the treatment of age-related macular degeneration – a cost-effectiveness analysis from a societal perspective. *PLoS ONE* 2018; 13: e0197670.
 11. Distefano LN, Garcia-Arumi J, Martinez-Castillo M, *et al.* Combination of anti-VEGF and laser photocoagulation for diabetic macular edema: a review. *J Ophthalmol* 2017; 2017: 2407037.
 12. Xie X, Liu Q and Paulus YM. Novel retinal laser therapies. *Int J Ophthalmic Res* 2018; 41272–41281.
 13. Muqit MM, Gray JC, Marcellino GR, *et al.* Barely visible 10-millisecond pascal laser photocoagulation for diabetic macular edema: observations of clinical effect and burn localization. *Am J Ophthalmol* 2010; 149: 979–986.
 14. Yun SH and Adelman RA. Recent developments in laser treatment of diabetic retinopathy. *Middle East Afr J Ophthalmol* 2015; 22: 157–163.
 15. Sramek C, Mackanos M, Spitler R, *et al.* Non-damaging retinal phototherapy: dynamic range of heat shock protein expression. *Invest Ophthalmol Vis Sci* 2011; 52: 1780–1787.
 16. Yadav NK, Jayadev C, Rajendran A, *et al.* Recent developments in retinal lasers and delivery systems. *Indian J Ophthalmol* 2014; 62: 50–54.
 17. Lock JH and Fong KC. An update on retinal laser therapy. *Clin Exp Optom* 2011; 94: 43–51.
 18. Sramek CK, Leung LS, Paulus YM, *et al.* Therapeutic window of retinal photocoagulation with green (532-nm) and yellow (577-nm) lasers. *Ophthalmic Surg Lasers Imaging* 2012; 43: 341–347.
 19. Bressler SB, Almukhtar T, Aiello LP, *et al.* For the diabetic retinopathy clinical research network. Green or yellow laser treatment for diabetic macular edema: exploratory assessment within the diabetic retinopathy clinical research network. *Retina* 2013; 33: 2080–2088.
 20. Blumenkranz MS, Yellachich D, Andersen DE, *et al.* Semiautomated patterned scanning laser for retinal photocoagulation. *Retina* 2006; 26: 370–376.
 21. Muqit MM, Henson DB, Young LB, *et al.* Laser tissue interactions. *Ophthalmology* 2010; 117: 2039.
 22. Lavinsky D, Wang J, Huie P, *et al.* Nondamaging retinal laser therapy: rationale and applications to the macula. *Invest Ophthalmol Vis Sci* 2016; 57: 2488–2500.
 23. Lavinsky D, Sramek C, Wang J, *et al.* Subvisible retinal laser therapy; titration algorithm and tissue response. *Retina* 2014; 34: 87–97.
 24. Luttrull JK and Dorin G. Subthreshold diode micropulse laser photocoagulation (SDM) as invisible retinal phototherapy for diabetic macular edema: a review. *Curr Diab Rev* 2012; 8: 274–284.
 25. Pei-Pei W, Shi-Zhou H, Zhen T, *et al.* Randomised clinical trial evaluating best-corrected visual acuity and central macular thickness after 532-nm subthreshold laser grid photocoagulation treatment in diabetic macular oedema. *Eye* 2015; 29: 313–321.
 26. Hamada M, Ohkoshi K, Inagaki K, *et al.* Subthreshold photocoagulation using endpoint management in the PASCAL® System for diffuse diabetic macular edema. *J Ophthalmol* 2018; 2018: 7465794.
 27. Moisseiev E, Abbassi S, Thinda S, *et al.* Subthreshold micropulse laser reduces anti-VEGF injection burden in patients with diabetic macular edema. *Eur J Ophthalmol* 2018; 28: 68–73.
 28. Inagaki K, Ohkoshi K, Ohde S, *et al.* Comparative efficacy of pure yellow (577-nm) and 810-nm subthreshold micropulse laser photocoagulation combined with yellow (561–577-nm) direct photocoagulation for diabetic macular edema. *Jpn J Ophthalmol* 2015; 59: 21–28.