

# Laryngeal Actinomycosis Presenting as Foreign Body

Brian A. Walker, MD<sup>1</sup> , and Mark E. Gerber, MD<sup>2</sup>

## Keywords

foreign body, actinomycosis, larynx, bronchoscopy

Received September 24, 2021; accepted December 9, 2021.

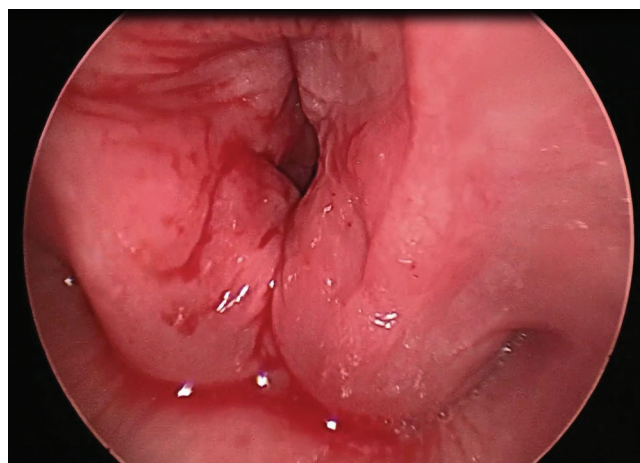
Actinomycosis is a filamentous anaerobic bacillus most classically presenting as a mandibular infection following dental trauma.<sup>1</sup> More rarely, it can cause infection throughout the larynx and pharynx among patients who are immunosuppressed.<sup>2</sup> Laryngeal actinomycosis has been reported to mimic other diagnoses, such as laryngeal carcinoma or foreign body of the lower airway.<sup>3</sup> We describe an episode of chicken bone aspiration, followed by the development of pharyngitis and intermittent acute respiratory distress due to actinomycosis of the larynx in an immunocompromised host.

This study was deemed exempt by the Mayo Clinic Institutional Review Board.

## Case Report

A 23-year-old man with a history of trisomy 21, acute lymphoblastic leukemia, and chimeric antigen receptor T-cell therapy presented with acute onset of intermittent severe respiratory distress, consisting of transient stridor, difficulty tolerating secretions, tripodding, and oxygen desaturation, which occurred every few hours without identifiable trigger. Treatment consisting of medication, oxygen, and nasal intermittent positive pressure ventilation did not alter the course of these episodes, and the patient would spontaneously improve and return to baseline. He was admitted to the pediatric intensive care unit, and the otorhinolaryngology department was consulted.

His caregiver reported an episode of choking while eating bone-in chicken approximately 2 weeks prior to presentation. The patient endorsed mild pharyngitis until the day of admission, when he developed acute onset of stridor with respiratory distress refractory to medical therapy. At the time of bedside examination, the patient was resting comfortably on room air with moderate inspiratory stridor and no acute distress. Flexible laryngoscopy showed an erythematous larynx with a ball-valving, solid-appearing white lesion at the level of the left laryngeal ventricle (**Figure 1**). The patient was



**Figure 1.** Inflamed supraglottis and glottis.

urgently transferred to the operating room for rigid bronchoscopy and removal of foreign body.

In the operating room, the mass required significant traction to extricate. On gross examination, it appeared to be consistent with possible chicken cartilage aspiration (**Figure 2**). Pathology demonstrated hyaline cartilage rimmed with bacterial colonies consistent with actinomycosis, but the origin of the specimen could not be verified as human tissue or poultry. Given that significant traction was required to remove the specimen, it was suspected that the “foreign body” may represent autologous cartilage. Three-dimensional computed tomography was performed and demonstrated a possible defect of a small inferior portion of the calcified thyroid cartilage on the left. The patient’s respiratory distress was instantly alleviated following his procedure, and his pharyngitis improved with prolonged penicillin treatment. At 11 months

<sup>1</sup>Department of Otorhinolaryngology, The Mayo Clinic in Arizona, Phoenix, Arizona, USA

<sup>2</sup>Department of Otorhinolaryngology, Phoenix Children’s Hospital, Phoenix, Arizona, USA

## Corresponding Author:

Brian A. Walker, MD, Department of Otorhinolaryngology, The Mayo Clinic in Arizona, 5777 E Mayo Blvd, Phoenix, AZ 85054, USA.  
Email: Walker.brian@mayo.edu





**Figure 2.** Foreign body specimen.

postoperatively, flexible nasopharyngoscopy demonstrated resolution of the initial findings without airway obstruction.

## Discussion

Actinomycosis is a commensal organism of the human alimentary tract that most commonly effects the cervicofacial region among patients who are chronically ill. Laryngeal actinomycosis has been reported to mimic other diagnoses, such as laryngeal carcinoma or foreign body.<sup>1</sup> We report an episode of potential chicken bone aspiration, followed by pharyngitis and intermittent acute respiratory distress due to actinomycosis of the larynx in an immunocompromised host.

An association between aspiration and actinomycosis of the airway has previously been demonstrated. The most commonly documented aspirated foreign bodies that cause endobronchial actinomycosis are fish and chicken bones.<sup>4,5</sup> There are yet other reports of laryngeal actinomycosis that was suspected to be secondary to aspirated corn.<sup>2</sup>

In this case, the patient presented with smoldering pharyngitis that evolved into acute respiratory distress and stridor. The most common symptoms of actinomycosis of the larynx include dysphonia, dysphagia, pharyngitis, and weight loss with symptoms ranging from days to months, including a rare case lasting for greater than a year.<sup>2,4</sup>

It is rare for laryngeal actinomycosis to present with respiratory distress requiring emergent airway management.<sup>3</sup>

However, it is important to maintain actinomycosis on the differential when evaluating chronic infection, foreign body, or mass of the airway. In most reported cases, patients have been treated with prolonged penicillin to good effect.<sup>2</sup>

After reviewing the relevant literature alongside the course and outcome in our patient, we concluded that the patient's "foreign body" was most likely autologous cartilage from the inferior aspect of the ipsilateral thyroid cartilage, which had been eroded by laryngeal actinomycosis that had been seeded by his initial aspiration event. Over the intervening 2 weeks, the infection spread to the adjacent soft tissues and cartilage, resulting in exposure and malformation of the cartilage and then sudden-onset dynamic airway obstruction. Most important, the patient's symptoms improved with retrieval of the obstruction and prolonged penicillin treatment.

## Author Contributions

**Brian A. Walker**, acquisition of data, literature review, manuscript preparation, editing, final approval; **Mark E. Gerber**, concept, photographs, critical revision of the manuscript, final approval


## Disclosures

**Competing interests:** None.

**Sponsorships:** None.

**Funding source:** None.

## ORCID iD

Brian A. Walker  <https://orcid.org/0000-0002-5734-4889>

## References

1. Patel S, Jaworek AJ, Patel V, Duckworth LV, Sawhney R, Chheda NN. Laryngeal actinomycosis in an immunocompromised patient. *J Voice*. 2014;28(6):838-840.
2. Googe B, Kowalczyk D, Geisinger K, Schweinfurth J. Laryngeal actinomycosis: a case report and systematic review of 32 cases in the literature. *HSOA Journal of Otolaryngology Head and Neck Surgery*. Published online April 13, 2016. doi:10.24966/OHNS-010X/100006
3. Brandenburg JH, Finch WW, Kirkham WR. Actinomycosis of the larynx and pharynx. *Otolaryngology*. 1977;86:739-742.
4. Ocal Z, Ozdogan S, Caglayan B, Salepci B, Tuzlali P. Endobronchial actinomycosis caused by occult foreign body aspiration. *Ann Saudi Med*. 2003;24(3):210-212.
5. Mingrone H, Perrone R, La Rosa S, Schtirbu R, Lutzky L. Primary bronchial actinomycosis and foreign body. Article in Spanish. *Medicina (B Aires)*. 1995;55:337-340.