

Bedside provocation and liberation maneuvers in patients with benign paroxysmal positional vertigo

Dominik Straumann¹  and Thomas Brandt²

Abstract

In the majority of cases, benign paroxysmal positional vertigo (BPPV) originates from the posterior or horizontal semicircular canals. If performed correctly, the maneuvers that diagnose or treat canalolithiasis or cupulolithiasis are highly effective. This article describes the provocation (i.e. diagnostic) and liberation (i.e. therapeutic) maneuvers to be applied in patients with BPPV. The step-by-step descriptions of the maneuvers are supplemented by practical recommendations.

Keywords

Vertigo, neuro-otology, clinical

Introduction

Most patients with benign paroxysmal positional vertigo (BPPV) can be treated successfully with the appropriate liberation maneuver for an affected semicircular canal. Therefore, every patient with dizziness or imbalance, even in the absence of typical complaints of BPPV, should undergo provocation maneuvers to detect BPPV due to canalolithiasis or cupulolithiasis.

Provocation maneuvers

We suggest performing two provocation maneuvers on each side: The Dix-Hallpike maneuver and the supine-roll maneuver. If all maneuvers are negative, they should be repeated at least once during the same visit. After all, it is not rare that positional vertigo and nystagmus is only elicited with the second execution of a specific provocation maneuver.

Dix–Hallpike maneuver

This provocation maneuver detects canalolithiasis of the posterior semicircular canal.¹ The head of the sitting patient is rotated along the yaw plane 45° to the right or left. The patient is then guided from the sitting position to the head-hanging position, while the head is kept in the previous yaw position relative to the trunk (Figure 1, row 1). Typically, in

the presence of a posterior canalolithiasis ipsilateral to the head yaw position, nystagmus occurs after a few seconds, is upbeat, lasts a few seconds (no more than 60 s), and shows both a vertical and a torsional component. A positional nystagmus beating downward, with or without a torsional component, may be central (unmasked cerebellar downbeat nystagmus) or due to contralateral anterior canalolithiasis. Expressed in space-fixed coordinates, upbeat nystagmus in the head-hanging position is geotropic, that is, directed toward the earth, and downbeat nystagmus is apogeotropic.

Supine-roll maneuver

This provocation maneuver detects a canalolithiasis or cupulolithiasis of a horizontal semicircular canal.^{3,4} The patient is asked to lie in the supine position whereby the headboard is raised by about 20–30°. Then, the head is quickly rotated along its yaw plane into the right-ear-down or left-ear-down

¹ Department of Neurology, University Hospital Zurich and University of Zurich, Zurich, Switzerland

² Institute of Clinical Neurosciences, University Hospital Munich Großhadern, Ludwig-Maximilians-University Munich, Munich, Germany

Corresponding author:

Dominik Straumann, Department of Neurology, University Hospital Zurich and University of Zurich, Zurich, Switzerland.

Email: Dominik.Straumann@usz.ch



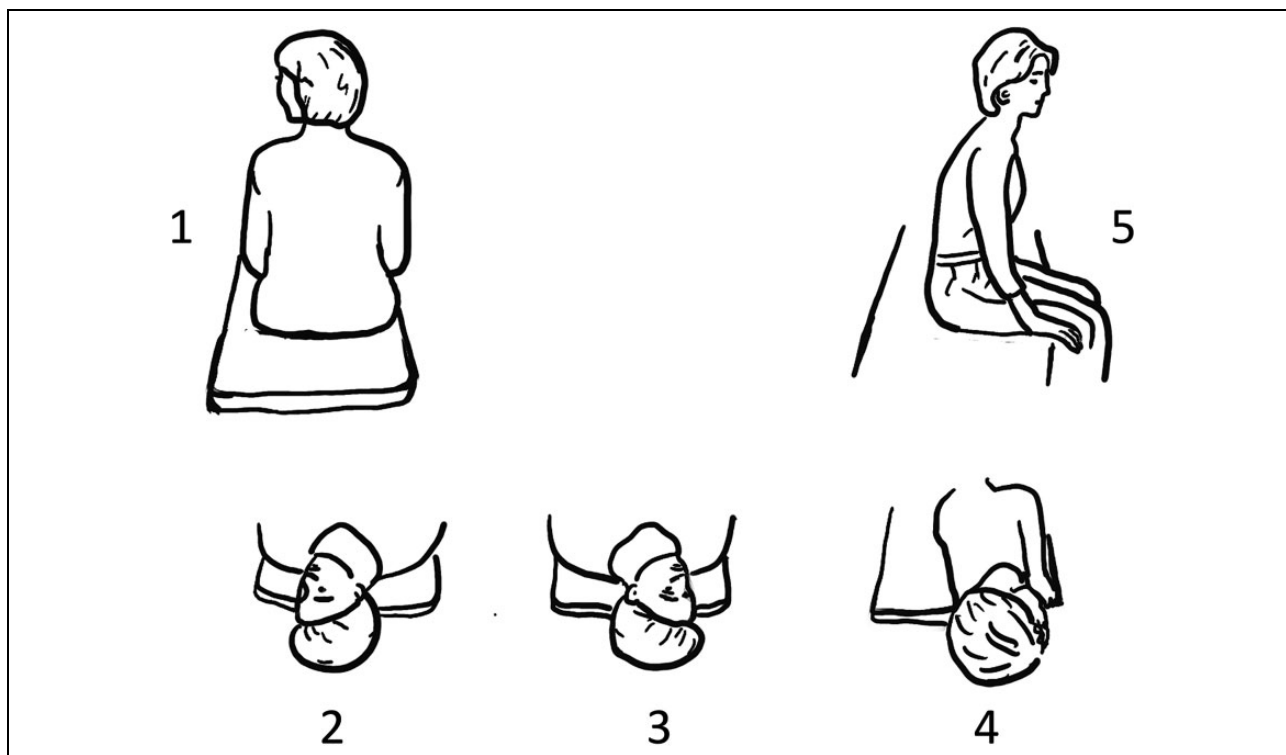


Figure 1. Schematic drawing of the Epley liberation maneuver in a patient with typical benign paroxysmal positioning vertigo caused by posterior canalolithiasis on the left side (adapted from Brandt et al.).² The first movement (from position 1 to position 2) corresponds to the Dix-Hallpike provocation maneuver for the left side.

position (or as far as neck yaw mobility allows). This head rotation is a roll movement expressed in space-fixed coordinates, hence the term supine-roll maneuver. In case of a horizontal canalolithiasis or cupulolithiasis, horizontal nystagmus, usually with a torsional component, occurs. Thereby the nystagmus beats either geotropically or apogeotropically in both ear-down positions, that is, the nystagmus changes its direction relative to the head depending on the head roll position. Many times, horizontal positional nystagmus appears without latency. An apogeotropic pattern together with persistence of nystagmus points to a cupulolithiasis.⁵

Liberation maneuvers

If a provocation maneuver elicits positional vertigo and nystagmus, we continue with the appropriate liberation maneuver and skip the pending provocations maneuvers. Multiple liberation maneuvers have been described for canalolithiasis or cupulolithiasis of every semicircular canal.⁶ For practical purposes, neurologists not specialized in neuro-otology can concentrate on liberation maneuvers for the posterior and horizontal semicircular canals, since the anterior semicircular canal is only rarely affected.⁷ The rationale for every liberation maneuver is to remove detritus out of the affected semicircular canal, thereby taking into account that one of the two exits of every semicircular canal is blocked by a cupula.

To liberate the posterior semicircular canals from detritus, both the Epley maneuver and the Sémont maneuver are widely used and similarly effective. To liberate the horizontal semicircular canals from detritus, both the Gufoni maneuver and the Lempert maneuver are presently in vogue.

Epley maneuver

This liberation maneuver (Figure 1) removes detritus from the posterior semicircular canal.⁸ The head is rotated from the Dix-Hallpike head-hanging position (Figure 1, position 2), in which positional vertigo and nystagmus occurred, by two steps of 90° to the other side (Figure 1, positions 3 and 4). To enable the second head rotation, the body is rolled to the side position. Finally, the patient is brought to the sitting position whereby the head keeps its previous 45° yaw position (Figure 1, position 5). Only when the patient sits upright, the head may return to the neutral position. In all four Epley positions, the head is kept still for at least 30 s or as long as the nystagmus lasts.

Sémont maneuver

This liberation maneuver (Figure 2) also removes detritus from the posterior semicircular canal.⁹ Contrary to the Epley maneuver, the Sémont maneuver cannot be performed as a continuation of a positive Dix-Hallpike

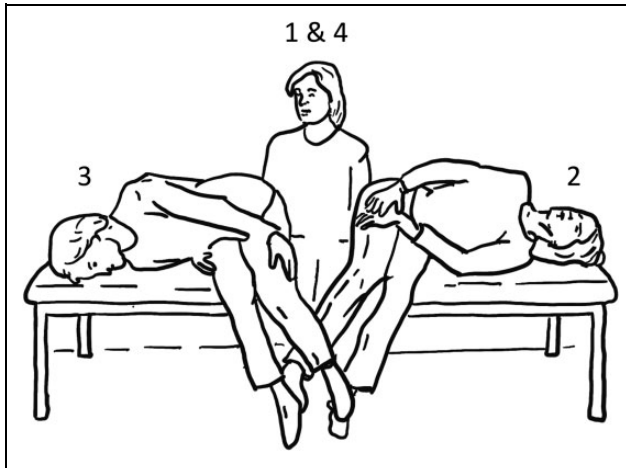


Figure 2. Schematic drawing of the Sémont liberation maneuver in a patient with typical benign paroxysmal positioning vertigo caused by posterior canalolithiasis on the left side (adapted from Brandt et al.²).

provocation maneuver. Rather, the patient is seated on the side of the examination table (Figure 2, position 1) and then rotates the head along the yaw plane 45° to the unaffected side. The patient is then guided to lie down on the affected side but keeping the previous yaw position of the head (Figure 2, position 2). For better therapeutic success, the head should hang below the horizontal by at least 20° .¹⁰ After resting in this side position for 1–2 min, the patient is brought to lie on the unaffected side by rotating the trunk along its roll plane by 220° , bypassing the upright position, whereby the previous 45° yaw position of the head is being maintained (Figure 2, position 3). The velocity of this trunk movement may not be critical, but the head, which is now obliquely pointing down, better hangs below the horizontal again by at least 20° .¹⁰ After 1–2 min in this side position, the patient is moved to the initial upright sitting position, in which the head is rotated back to its neutral position (Figure 2, position 4).

Gufoni maneuver

This liberation maneuver removes detritus from the horizontal semicircular canal.¹¹ There are two versions of the Gufoni liberation maneuver: one for the geotropic variant (Figure 3) and one for the apogeotropic variant (Figure 4) of horizontal BPPV. In both versions, the patient is seated upright on the side of the examination table (Figures 3 and 4, position 1) and is first brought to the side position, at which there was less horizontal positional nystagmus during the supine-roll provocation maneuver (Figures 3 and 4, position 2). In case of the geotropic variant, this is the side of the unaffected ear; in case of the apogeotropic variant, this is the side of the affected ear. After 20 s in this side position, the head is rotated in the yaw plane 45° down (Figure 3, position 3) for the geotropic variant¹² or 45°

up (Figure 4, position 3) for the apogeotropic variant.¹³ After 1–2 min in this position, the patient is brought back to the sitting position, in which the head may rotate back to the neutral position (Figures 3 and 4, position 4). In some cases, the Gufoni head-up liberation maneuver converts the apogeotropic variant of horizontal BPPV into the geotropic variant. If this occurs, one should perform the Gufoni head-down liberation maneuver to the other side during the same visit.

Lempert maneuver

This liberation maneuver also removes detritus from the horizontal semicircular canal in case of a geotropic variant.¹⁴ The patient is rolled from the supine position by 270° in the direction at which there was less horizontal positional nystagmus during the supine-roll provocation maneuver, which is the side of the unaffected ear. Rotations are in steps of 90° . At each position, the patient rests for 30–60 s. From the last position, which is the affected side, the patient is brought up to the sitting position. The Lempert liberation maneuver is also called barbecue maneuver for its similarity to rotations on the grill. Rolling the patients in 90° steps by 450° or more in the direction of the unaffected ear maybe more effective than by 270° only.^{15,16} In some cases, the Lempert liberation maneuver by 270° or by 450° may also be successful for the apogeotropic variant of BPPV whereby the body is again rolled in the direction at which there was less horizontal positional nystagmus during the supine-roll provocation maneuver (personal observation).

Comments on the liberation maneuvers

- Vibration of the mastoid bone on the affected side before and during liberation maneuvers may facilitate the movement of the detritus within a semicircular canal.¹⁷ Alternatively, mastoid percussion (fingers, reflex hammer) can be applied. Rapid head shaking in the sitting position (e.g. 3 Hz for 15 s, head pitched forward by about 30°) may substitute the Gufoni liberation maneuver for the apogeotropic variant of horizontal BPPV.¹⁸ Prolonged lying on the unaffected ear has shown to be a valid alternative for the treatment of the geotropic variant of horizontal BPPV.¹⁹
- Bilateral BPPV is difficult to treat during a single visit, because a liberation maneuver on one side may undo the previous liberation maneuver on the other side. We therefore suggest treating one side only during the first visit and the other side one day later.
- Immediately after a successful liberation maneuver, patients may sometimes experience a falling sensation, which is possibly due to detritus falling on the utricular membrane.²⁰ Imbalance for hours or even

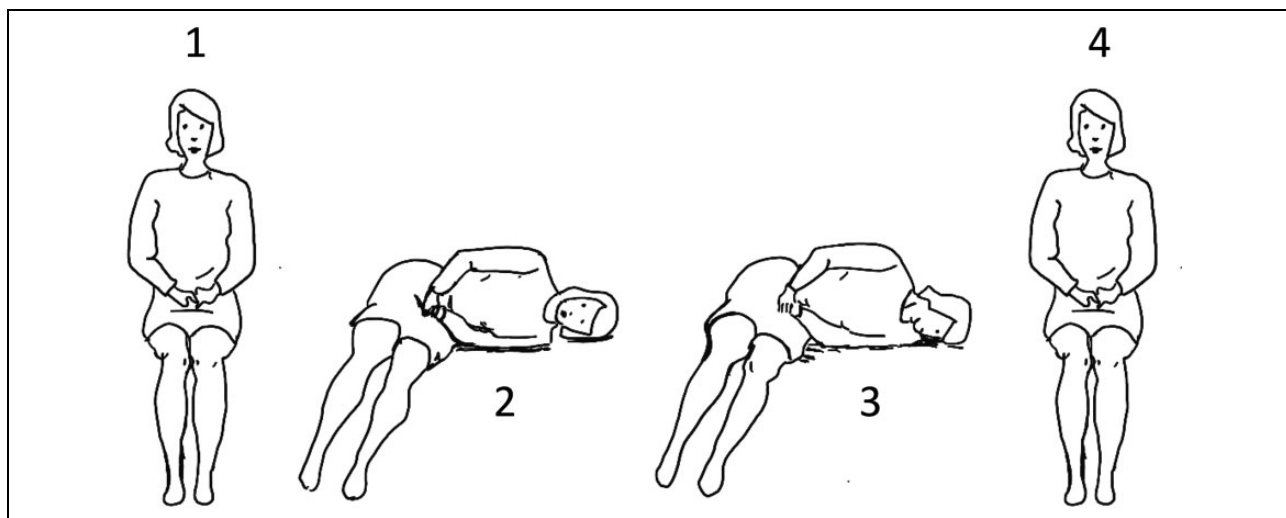


Figure 3. Schematic drawing of the Gufoni liberation maneuver for treating the geotropic variant of horizontal semicircular canal BPPV (adapted from Casani et al.,¹² which is modified from Gufoni et al.¹¹). The patient is brought to the side position (i.e. the side of the unaffected ear), in which the patient had less positional nystagmus (position 2). From there the head is rotated 45° downward (position 3).

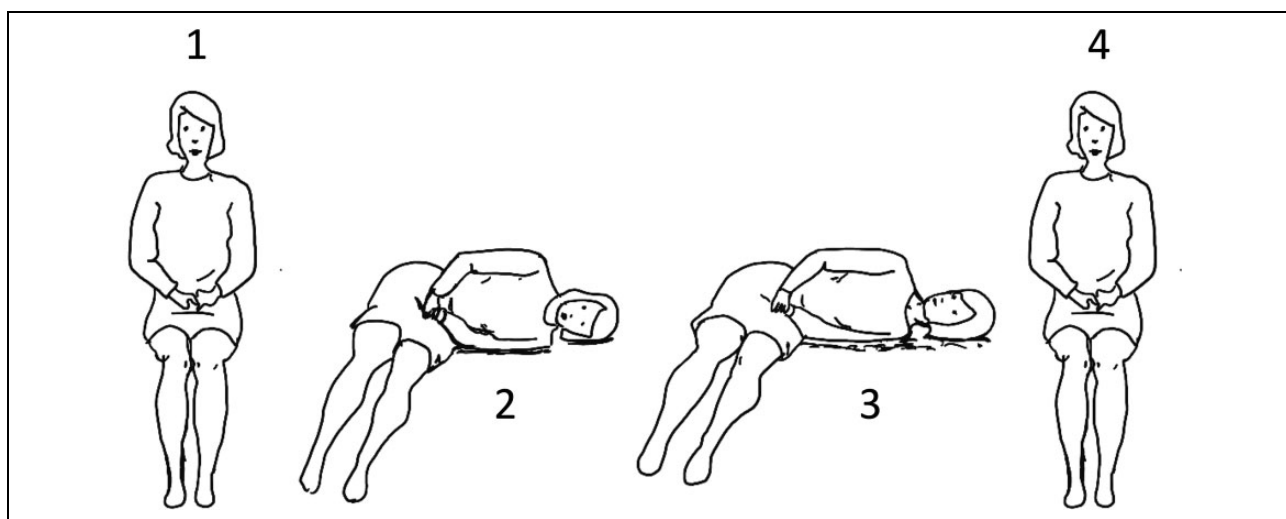


Figure 4. Schematic drawing of the Gufoni liberation maneuver for treating the apogeotropic variant of horizontal semicircular canal BPPV (adapted from Casani et al.¹²). The patient is brought to the side position (i.e. the side of the affected ear), in which the patient had less positional nystagmus (position 2). From there the head is rotated 45° upward (position 3).

days after a successful liberation maneuver is common.²¹

- The success of a liberation maneuver may be confirmed by repetition of the corresponding provocation maneuver, provided the patient is not too much nauseated. If positional vertigo and nystagmus persists, the liberation maneuver should be repeated during the same or at a follow-up visit. If the liberation maneuvers remain unsuccessful over a period of 2 weeks, we recommend ordering cranial MRI to exclude a central cause of positional vertigo.
- After a successful liberation maneuver, the patient should avoid high-acceleration head movements

(e.g. jogging, jumping) and head positions below the horizontal (e.g. dentist, mechanic) for 3 days. This minimizes the risk of a BPPV recurrence.

- Whether a follow-up visit after a successful liberation maneuver is needed should be decided for each patient individually. Many times, a feedback by phone 3 days later will do, since the success rate of liberation maneuvers is very high.
- Provocation and liberation maneuvers in frail patients with BPPV cannot be performed at the bedside in the proper way due to stiffness, pain, and angst. These patients are best diagnosed and treated on two-axis turntables.


Declaration of conflicting interests

The authors declared no potential conflicts of interest with respect to the research, authorship, and/or publication of this article.

Funding

The authors received no financial support for the research, authorship, and/or publication of this article.

ORCID iD

Dominik Straumann  <https://orcid.org/0000-0002-5349-7650>

References

- Dix MR and Hallpike CS. The pathology, symptomatology and diagnosis of certain common disorders of the vestibular system. *Ann Otol Rhinol Laryngol* 1952; 61: 987–1016.
- Brandt T, Steddin S and Daroff RB. Therapy for benign paroxysmal positioning vertigo, revisited. *Neurology* 1994; 44: 796–800.
- McClure JA. Horizontal canal BPV. *J Otolaryngol* 1985; 14: 30–35.
- Pagnini P, Nuti D and Vannucchi P. Benign paroxysmal vertigo of the horizontal canal. *ORL J Otorhinolaryngol Relat Spec* 1989; 51: 161–170.
- Baloh RW, Yue Q, Jacobson KM, et al. Persistent direction-changing positional nystagmus: another variant of benign positional nystagmus? *Neurology* 1995; 45: 1297–1301.
- Brandt T, Dieterich M and Strupp M. *Vertigo and dizziness: common complaints*. London: Springer, 2013.
- Korres S, Balatsouras DG, Kaberos A, et al. Occurrence of semicircular canal involvement in benign paroxysmal positional vertigo. *Otol Neurotol* 2002; 23: 926–932.
- Epley JM. The canalith repositioning procedure: for treatment of benign paroxysmal positional vertigo. *Otolaryngol Head Neck Surg* 1992; 107: 399–404.
- Sémont A, Freyss G and Vitte E. Curing the BPPV with a liberatory maneuver. *Adv Otorhinolaryngol* 1988; 42: 290–293.
- Obrist D, Nienhaus A, Zamaro E, et al. Determinants for a successful Sémont maneuver: an in vitro study with a semicircular canal model. *Front Neurol* 2016; 7: 150.
- Gufoni M, Mastrosimone L and Di Nasso F. Trattamento con manovra di riposizionamento per la canalolitiasi orizzontale. *Acta Otorhinolaryngol Ital* 1998; 18: 363–367.
- Casani AP, Vannucci G, Fattori B, et al. The treatment of horizontal canal positional vertigo: our experience in 66 cases. *Laryngoscope* 2002; 112: 172–178.
- Ciniglio Appiani G, Catania G, Gagliardi M, et al. Repositioning maneuver for the treatment of the apogeotropic variant of horizontal canal benign paroxysmal positional vertigo. *Otol Neurotol* 2005; 26: 257–260.
- Lempert T. Horizontal benign positional vertigo. *Neurology* 1994; 44: 2213–2214.
- Waespe W. Der gutartige paroxysmale Lagerungsschwindel und –nystagmus des horizontalen Bogengangs. *Schweiz Med Wochenschr* 1997; 127: 287–295.
- Fife TD. Recognition and management of horizontal canal benign positional vertigo. *Am J Otol* 1998; 19: 345–351.
- Epley JM. Human experience with canalith repositioning maneuvers. *Ann N Y Acad Sci* 2001; 942: 179–191.
- Kim J-S, Oh S-Y, Lee S-H, et al. Randomized clinical trial for apogeotropic horizontal canal benign paroxysmal positional vertigo. *Neurology* 2012; 78: 159–166.
- Vannucchi P, Giannoni B and Pagnini P. Treatment of horizontal semicircular canal benign paroxysmal positional vertigo. *J Vestib Res* 1997; 7: 1–6.
- Uneri A. Falling sensation in patients who undergo the Epley maneuver: a retrospective study. *Ear Nose Throat J* 2005; 84(82): 84–85.
- Seok JI, Lee HM, Yoo JH, et al. Residual dizziness after successful repositioning treatment in patients with benign paroxysmal positional vertigo. *J Clin Neurol* 2008; 4: 107–110.