

## LONG-TERM RESULTS OF REHABILITATIVE MANAGEMENT WITH EXTRACORPOREAL SHOCKWAVE THERAPY IN ROTATOR CUFF DISEASE WITH PARTIAL TEARS

R. SAGGINI<sup>1</sup>, V. COCO<sup>2</sup>, L. DI PANCRAZIO<sup>3</sup>, M. MEGNA<sup>4</sup>, P. IODICE<sup>1</sup> and R.G. BELLOMO<sup>3</sup>

<sup>1</sup>Department of Neuroscience and Imaging, "G. d'Annunzio" University, Chieti, Italy; <sup>2</sup>Degree Course in Physiotherapy, University of Catania, Catania, Italy; <sup>3</sup>Department of Medicine and Science of Aging "G. d'Annunzio" University, Chieti, Italy; <sup>4</sup>Department of Neurological and Psychiatric Sciences, University of Bari "Aldo Moro", Bari, Italy

*Received March 7, 2012 – Accepted July 18, 2012*

The purpose of this study is to evaluate the effects of rehabilitative approach using MJS and dynamic antigravity postural system (SPAD) with extracorporeal shockwave therapy (ESWT) on rotator cuff syndrome associated tendon supraspinatus and infraspinatus medium tear (1-3 cm) of the tendons. In the last few years, ESWT has been proposed as an elective treatment in somatic diseases with encouraging short-term results. For this study the authors enrolled 108 patients who underwent 3 treatments with ESWT associated with 24 rehabilitation sessions over 3 weeks. Outcome measures were the VAS for pain and the Constant Murley Scale. The outcomes were measured pre-training, post-training and at 2, 4, 6 month follow-ups. Additional follow-up evaluation sessions were performed every year for 5 years by a telephone interview to evaluate changes in pain and function and the efficacy of treatment. Our study shows that the therapeutic efficacy of rehabilitative approach with ESWT in the rotator cuff syndrome with medium tears persists over time and significantly improves the patient's quality of life. The results obtained are certainly to be attributed to the biological mechanisms that ESWT are able to engage in tissues of the rotator cuff. The results seen at the conclusion of the treatment were maintained over the following years, thanks to the use of MJS and SPAD. In our opinion a conservative treatment with extracorporeal shock-wave (ESW), dynamic antigravity postural system (SPAD) and multi joint system (MJS) should be considered as an alternative and effective treatment for rotator cuff syndromes with medium tears.

Clinical use of shock waves was first applied in therapy for renal stones, where it was casually noted to have an effect on the iliac bone with primary osteocyte damage, followed by osteoblastic stimulation (1). Consequently, extracorporeal shock wave therapy (ESWT) was introduced for the treatment of the nonunion of bones with positive results documented by several papers (2).

At present, shock wave therapy is widely applied in the treatment of musculoskeletal disorders, such as the nonunion of long bone fractures, calcifying tendonitis of the shoulder, lateral epicondylitis of the elbow and proximal plantar fasciitis; in addition, the success rate of the application ranges from 65% to 91% (3).

Shock waves could promote growth and

*Key words: extracorporeal shock waves therapy, rotator cuff disease, pain, rehabilitation*

Mailing address: Prof. Raoul Saggini,  
Department of Physical Medicine and Rehabilitation,  
"G. d'Annunzio" University,  
Viale Abruzzo 322,  
66013 Chieti, Italy  
Tel.: +39 0871587107 Fax: +39 3358339950  
e-mail: saggini@unich.it

1721-727X (2012)

Copyright © by BIOLIFE, s.a.s.

This publication and/or article is for individual use only and may not be further reproduced without written permission from the copyright holder.

Unauthorized reproduction may result in financial and other penalties

**DISCLOSURE: ALL AUTHORS REPORT NO CONFLICTS OF INTEREST RELEVANT TO THIS ARTICLE.**

differentiation of bone marrow stromal cells toward osteoprogenitors (4). Moreover, ESW induces positive effects on proliferation in primary human cancellous osteoblasts (5) and in collagen type 1 expression in osteoblast-like cells (6).

Tamma et al. (7). demonstrated activation of the cyclin E2/ CDK2 complex, which is essential for cell proliferation, because it regulates the G1-S transition and found an increase of RUNX2 RNA expression 24 h after ESW stimulation, indicating that ESW positively affects osteoblast activity and extracellular matrix secretion. Osteocalcin, a late marker of osteoblast differentiation, was also increased 72 h after ESW treatment.

Extracorporeal shock waves cause stimulation of tissue healing, reduction of calcification and inhibition of pain receptors or denervation to achieve pain relief (8, 9).

Researchers have shown that the local delivery of shock wave therapy stimulates the early expression of angiogenesis-related growth factors, including endothelial nitric oxide synthase, vascular endothelial growth factor and proliferating cell nuclear antigen. As such, it results in new vessel in-growth that improves blood supply, increases cell proliferation and accelerates tissue regeneration and healing (3, 10).

Moretti et al. found that ESW application downregulate the intracellular levels of TNF- $\alpha$  and IL-10 by chondrocytes (11). Mariotto et al. describe the possible molecular mechanism that triggers the anti-inflammatory action of ESW, focusing on the possibility that ESW may modulate endogenous nitric oxide (NO) production either under normal or inflammatory conditions. Data on the rapid enhancement of endothelial NO synthase (eNOS) activity in ESW-treated cells suggest that increased NO levels and the subsequent suppression of NF- $\kappa$ B activation may account, at least in part, for the clinically beneficial action on tissue inflammation (12).

In the last few years, extracorporeal shockwave therapy (ESWT) has been proposed as an elective somatic disease treatment with encouraging short-term results in reducing pain and improving function in patients.

The upper limbs have various functions relative to daily and work activities, that can be carried out

thanks to a considerable range of movements of the shoulder joints, at a cost to their intrinsic stability (13).

Shoulder complaints are among the most common peripheral complications. Incidences of shoulder problems vary between 7 and 25 cases per thousand visits to the general practitioner (13, 14). The prevalence in adults under 70 varies between 7 and 27%, while in over 70's the prevalence is between 13.2 and 26% (15).

Shoulder pain syndrome is caused by the functional impairment of the rotator cuff, long head of the biceps and bursa. The impact of the tendon sheath and subacromial bursa, when the shoulder is raised, increases pain and contributes towards making these long-term conditions (16).

Rotator cuff syndrome is classified by our group in three stages (Neer modified classification) (16):

- the 1<sup>st</sup> stage is characterized by an edema and tendonitis;
- the 2<sup>nd</sup> stage is characterized by fibrosis and tendonitis with tears less than 3 cm: episodes of inflammation, fibrotization and thickening of the bursa;
- the 3<sup>rd</sup> stage is characterized by total or partial tears larger than 3 cm of the rotator cuff and the brachial biceps.

Diagnosis is made through a clinical examination and the use of such tools as X-rays, echography and NMR.

In the literature, the success rate described of non-operative management varies from 33% to 92% (17, 18) and especially in 75% of 53 patients at an average follow up longer than 7 years. Particularly, those with less than 6 months of pain and in 62% of 60 patients with documented rotator cuff tears at 2-year follow up (19) and 70% of 136 patients at an average 1.5 year follow up have good results (20).

The treatment for rotator cuff syndrome with symptoms less than 1 year and tears less than 1 cm is fundamentally conservative: FANS, cortisone-based infiltration and ice to alleviate the pain, electroanalgesia (TENS), kinesitherapy to restore the compromised mobility of the joint and strengthen the musculature, therapies using energy such as ultrasound, lasers, hyperthermia and shock waves. In the case of lack of response to the conservative therapy, arthroscopic surgery is proposed (21, 22).

In a previous study we demonstrated that treatment with shock waves can bring a significant improvement to the algic picture and the functionality of the shoulder, always in association with a correct and constant physiotherapy (23-26).

The aim of this study is to evaluate changes in pain and function at long-term (follow up 5 years) after a rehabilitation program consisting of focused ESWT, associated with the increase of R.O.M. articulate and a postural rebalancing in patients suffering from rotator cuff disease with partial tears (stage 1 or 2).

## MATERIALS AND METHODS

In this study 108 patients were enrolled (64 males, 44 females; mean age 55 years) affected by rotator cuff disease (I and II stage), diagnosed by clinical examination and instrumental investigations (108 patients underwent radiography and ultrasound, 96 patients MRI), as shown in Fig. 1.

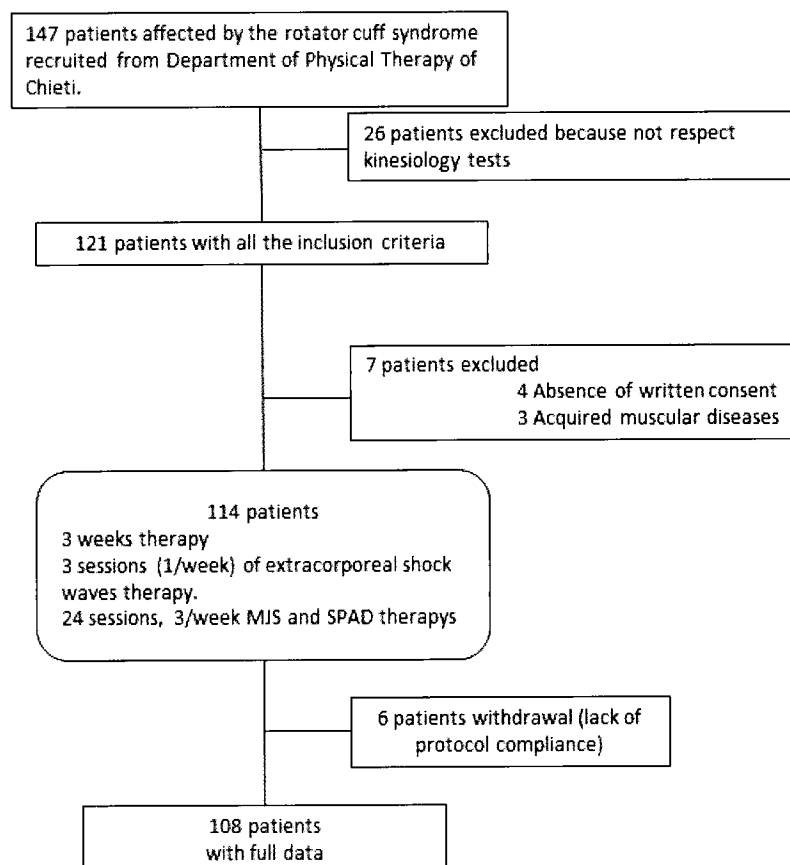
Inclusion criteria included patients with pain from

6 weeks to 24 months (13 medium time) and with VAS score greater than 4 at the first evaluation, aged between 18 and 70, a two out of three kinesiologic test such as Jobe, Lift-off and the Neer positive test, unwillingness to undergo surgery and recalcitrant to medical treatment and physical therapy for over 60 days.

Patients treated with 3 sessions (1/week) of extracorporeal shock waves, associated with the increase of R.O.M. articulate with a postural rebalancing (24 sessions, 3/week).

All the subjects were appraised before the treatment, at the end of the shock wave therapy (three weeks), and at 2 months, 4 months and 6 months after the end of treatment by a clinical examination with VAS (Visual Analogue Scale) and Constant – Murley Scale (the CMS is a standardized simple clinical method of assessing shoulder function and has a maximum score of 100 points). Before the treatment and at the end of each year, from 2005 to 2009, we interviewed the patients by telephone to evaluate changes in pain and function and the efficacy of treatment.

We carried out a telephone interview with a sample of 108 patients who completed the rehabilitation program



**Fig. 1.** Flowchart of study.

**Table I.** *The interview questions.*

| INTERVIEW QUESTIONS                                                                                                  |
|----------------------------------------------------------------------------------------------------------------------|
| Pain level: What was the level of your pain from 1 to 10 before therapy and today (level 10: the inability to move)? |
| Do you think therapy ESWT has been effective?                                                                        |
| Do you feel pain today?                                                                                              |
| How long did the total well-being after therapy last before the recurrence of pain?                                  |
| Do you think that the reappearance of pain is linked to an obvious cause (work, sports, lifestyle, etc ...)?         |
| Have you undergone other medical therapies over time, after ESWT?                                                    |
| Have you undergone other physical therapies over time, after ESWT?                                                   |

with ESWT during 2005 and were controlled until 2009 through interview questions.

An Electrohydraulic Spark Gap device was used for the shockwaves with therapeutic waves at 5 mm focal depth, medium strength power was used at 0.132 mJ/mm<sup>2</sup> and 600 waves were administered per sitting. In no case was a local anaesthetic used (25, 26).

The Multi Joint System valuatinal-rehabilitative system of the shoulder formed of a multi-joint anthropomorphic arm that, guided by the patient, can move freely in a three-dimensional space. It is used to obtain a good motor control in all the joint zone of the shoulder with an optimization of scapular positioning and contemporarily developing ever-increasing strength of the anterior serratus, rhomboid, latissimus dorsi, trapezius and deltoid with different movement schemes (27).

A dynamic antigravity postural system (SPAD) is made by a conveyor belt, surmounted by a lifting structure, which forces the patient to walk in a straight line on a treadmill; the patient is suspended through a mechanical antigravity vertical traction system; a pneumatic suspension system, including a self-leveling system, which allows to follow the patient center of gravity during its vertical excursions and a second mechanical lateral traction system which allows to stabilize the pelvis. The SPAD includes four anterior mobile arms which act on the rotation components of scapulohumeral and pelvic girdles and on antero-superior iliac spines; and two posterior blocking systems located on the back of the patient at the vertebral level T3-T4 and on sacral apex. It is used to obtain an optimization of the global body posture, particularly for the shoulder complex

and in particular for the scapular position (28).

The rehabilitative approach is an integral and necessary part of the conservative treatment, which has the following aims:

- To reduce to a minimum pain and swelling
- To reduce inflammation
- To increase cellularity on the biological healing time
- To regain shoulder and muscle function and to increase the dynamic control of scapulohumeral girdles related to the body's posture.

All the patients followed rehabilitation treatment in four phases. The first phase (0-2 weeks) aimed at avoiding stiffness, reduction of pain, and restoring a correct scapula-thoracic and glenohumeral relationship. Initially, passive exercises were carried out in anteposition, not exceeding 80° and of abduction on the scapula of 30°-70°, external rotation in anteposition of 30° and ROM between 0° and 60°; internal rotation and adduction were avoided; 2 sessions of shockwaves are performed.

In the second phase (3-4 weeks) the patients were involved more in their own recovery, with a cautious beginning of internal rotation, abduction up to 90° and activities using dynamic antigravity postural system (SPAD); 1 session of shockwaves was performed.

In the third phase (4-6 weeks) a progressive increase of the work load was carried out with complete strengthening of the shoulder muscles and proprioceptive re-education, and a therapy with the proprioceptive Multi Joint System to recuperate the mobility and muscle strength of the shoulder and to increase the body and shoulder posture

with SPAD.

The fourth phase (6-8 weeks) of advanced recovery had as aims: functional recovery of normal daily activities, and mobility of joint equal to the controlateral; active muscle strengthening of the rotator cuff and deltoid; sport specific exercises or practical work; complete functional recovery of the body using SPAD and the force of the shoulder reaches at least 80% of the controlateral using MJS.

The processing of the reported data was carried out by the Student's *t*-test. A value of  $p \leq 0.05$  was considered statistically significant.

## RESULTS

The results of the VAS show a reduction in pain at the end of treatment and at follow-up of 4 and 6 months and the value of Constant-Murley Scale demonstrates a significant increase of shoulder function. The score increases from 42 (T0) to 88 at the end of the treatment protocol (T2).

No clinically significant adverse effects (including neurologic disorders, tendon rupture, infection, bone edema, or muscle hematoma) were observed in any

of the patients during the early 6 months of clinical control.

Patients dissatisfied with treatment of the final follow-up at 5 years were 15% of the total group.

## DISCUSSION

Shoulder pain is a common problem, for which conservative therapy is sometimes ineffective (29, 30). The disorder of the shoulder leads to pain, particularly nocturnal discomfort, in about 50% of patients and frequently to a considerable restriction of range of motion and to a limitation of function. Frequently, initial treatment modalities for the disease are aimed primarily at symptoms, focusing on adequate analgesia with nonsteroidal anti-inflammatory drugs (NSAIDs) or local infiltration of crystalline steroidal suspensions, biding time until the symptoms are alleviated. When conservative therapy has not been effective in relieving pain and other symptoms, extracorporeal shock-wave therapy (ESWT) has been used, yielding results such as relief of pain and improved function (2, 31). Many authors

**Table II.** *VAS and Constant Murley Results.*

|                                      | <b>T0</b> | <b>T1 (3 weeks)</b> | <b>T2 (2 months)</b> | <b>T3 (4 months)</b> | <b>T4 (6 months)</b> |
|--------------------------------------|-----------|---------------------|----------------------|----------------------|----------------------|
| <b>VAS</b>                           | 7         | 1.8                 | 1.4                  | 1.4                  | 1.5                  |
| <b>CONSTANT MURLEY SCALE (score)</b> | 42        | 78                  | 88                   | 92                   | 92                   |

**Table III.** *Pain level, trend of pain and drugs reduction consumption.*

|                                                             | <b>T0</b> | <b>T5 (1 year, 2005)</b> | <b>T6 (2 year, 2006)</b> | <b>T7 (3 year, 2007)</b> | <b>T8 (4 year, 2008)</b> | <b>T9 (5 year, 2009)</b> |
|-------------------------------------------------------------|-----------|--------------------------|--------------------------|--------------------------|--------------------------|--------------------------|
| <b>PAIN LEVEL</b>                                           | 8         | 2                        | 2                        | 2                        | 3                        | 3                        |
| <b>TREND OF PAIN (percentage of patients with pain)</b>     |           | 7%                       | 11%                      | 14%                      | 16%                      | 20%                      |
| <b>DRUGS REDUCTION CONSUMPTION (percentage of patients)</b> |           | 60.1%                    | 45.3%                    | 30.5%                    | 10.1%                    | 8.3%                     |

have reported good results in calcifying tendinitis of the shoulder with low and high energy (32). Excellent results have also been reported by Rompe et al. in the treatment of epicondylitis (33), and good results were obtained by Cosentino et al. in the treatment of calcaneal enthesophytosis (34). Only in resistant cases are further, more invasive steps considered, with surgery being the ultimate step (31).

Currently, the exact mechanisms of the therapeutic effects of shock wave therapy on shoulder calcification remain uncertain. The hypothesis is that increasing pressure within the therapeutic focus causes fragmentation and cavitation inside the amorphous calcification, leading to disorganization and disintegration of the deposits (35). Steinbach et al. confirm the hypothesis that resorption of the calcific deposits is normally induced by a cellular mechanism and not through direct physical disintegration (36).

Berta et al. (37) confirm that ESWT treatment promotes and improves the repair process through accelerated timing of RNA expression for TGF- $\beta$ 1, collagen I and collagen III (relative to untreated fibroblasts). The results, in line with previous reports using a rat model (38) and a rabbit model (39) and also on human tendon ailments (40) support the efficacy of clinical application of ESW in different types of tendonopathies and tendon injuries.

Our study shows that the therapeutic efficacy of rehabilitative approach using ESWT in the rotator cuff syndrome persists over time and significantly improves patients' quality of life, in fact in the literature at 3 year follow-up 30% of patients treated with rehabilitative approach undergo surgery.

The results obtained are certainly to be attributed to the biological mechanisms that ESWT are able to engage in tissues of the rotator cuff. The results seen at the conclusion of the treatment were maintained over the following years, thanks to the use of MJS and SPAD.

MJS helps to obtain a better control of motor movements with an increase in proprioception and improved sensitivity. The structure of the system is equipped with a dense network of electronic sensors interfaced to an electronic processor and allows the real-time detection of all movements of the shoulder, thus permitting an increase of shoulder joint motion in a multi-dimensional axial-type range.

The Dynamic Antigravitational Postural System is a system of relief of the body weight. It is composed of a conveyor belt, surmounted by a lifting structure, which forces the patient to walk in a straight line on a treadmill, able to work at very low speed (0.01 Km/h) and allowing small speed increases. The patient is suspended through a mechanical antigravity vertical traction system, a pneumatic suspension system, including a self-leveling system, which allows to follow the patient center of gravity during its vertical excursions and a second mechanical lateral traction system which allows to stabilize the pelvis. The SPAD includes four anterior mobile arms which act on the rotation components of scapula-homeral and pelvic girdles and on antero-superior iliac spines; and two posterior blocking systems located on the back of the patient at the T3-T4 vertebral level and on sacral apex. The system works with a dual action: mechanical, allowing neuromotor retraining with cortico-subcortical forms of learning to acquire new body pattern in a balance that minimizes the energy consumption needed to maintain posture, and proprioceptive, acting maintaining the adaptations induced in time relative to walking. The SPAD treatment corrected the asymmetry of the two hemisomata and modified asymmetric adaptations of gait, using a vertical movement of the center of gravity of the subject.

In our opinion a conservative and integrated treatment with Extracorporeal Shock Wave (ESW), (physical energy to address regenerative tissue), Dynamic Antigravity Postural System (SPAD) and Multi Joint System (MJS) should be considered as an alternative and effective treatment for rotator cuff syndromes with medium tears.

## REFERENCES

1. Graff J, Pastor J, Funke PJ, Mach P, Senge T. Extracorporeal shock wave lithotripsy for ureteral stones: A retrospective analysis of 417 cases. *J Urol* 1988; 139:513-16.
2. Rompe JD, Zoellner J, Nafe B. Shock wave therapy versus conventional surgery in the treatment of calcifying tendinitis of the shoulder. *Clin Orthop Relat Res* 2001; 387:72-82.
3. Wang CJ. An overview of shock wave therapy in

- musculoskeletal disorders. *Chang Gung Med J* 2003; 26:220-32.
4. Wang FS, Yang KD, Chen RF, Wang CJ, Sheen-Chen SM. Extracorporeal shock wave promotes growth and differentiation of bone-marrow stromal cells toward osteoprogenitors associated with induction of TGF-beta1. *J Bone Joint Surg Br* 2002; 84:457-61.
  5. Hofmann A, Ritz U, Hessmann MH, Alini M, Rommens PM, Rompe J. Extracorporeal shock wave-mediated changes in proliferation, differentiation, and gene expression of human osteoblasts. *J Trauma Inj Infect Crit Care* 2008; 65:1402-10.
  6. Martini L, Giavaresi G, Fini M, Torricelli P, De Pretto M, Schaden W, Giardino R. Effect of extracorporeal shock wave therapy on osteoblastlike cells. *Clin Orthop Relat Res* 2003; 413:269-80.
  7. Tamma R, Dell'Indice S, Notarnicola A, Moretti L, Patella S, Patella V, Zallone A, Moretti B. Extracorporeal shock waves stimulate osteoblast activities. *Ultrasound in Med Biol* 2009; (35)12:2093-100.
  8. Grasel RP, Schweitzer ME, Kovalovich AM, Karasick D, Wapner K, Hecht P, Wander D. MR imaging of plantar fasciitis: edema, tears, and occult marrow abnormalities correlated with outcome. *Am J Roentgenol* 1999; 173:699-701.
  9. Rompe JD, Hopf C, Nafe B, Burger R. Low-energy extracorporeal shock wave therapy for painful heel: a prospective controlled single-blind study. *J Orthop Trauma Surg* 1996; 115:75-79.
  10. Haupt G. Use of extracorporeal shock waves in the treatment of pseudarthrosis, tendinopathy and other orthopedic diseases. *J Urol* 1997; 158(1):4-11.
  11. Moretti B, Iannone F, Notarnicola A, Lapadula G, Moretti L, Patella V, Garofalo R. Extracorporeal shock waves down-regulate the expression of interleukin-10 and tumor necrosis factor-alpha in osteoarthritic chondrocytes. *BMC Musculoskelet Disord* 2008; 31:9-16.
  12. Mariotto S, Carcereri De Prati A, Cavalieri E, Amelio E, Marlinghaus E, Suzuki H. Extracorporeal shock wave therapy in inflammatory diseases: molecular mechanism that triggers anti-inflammatory action. *Curr Med Chem* 2009; 16:2366-72.
  13. Cardoso de Souza M, Trajano JR, Jones A, Lombardi JJ, Natour J. Progressive resistance training in patients with shoulder impingement syndrome: literature review. *Reumatismo* 2009; 61:84-89.
  14. Van der Windt DA, Koes BW, De Jong BA, Bouter LM. Shoulder disorders in general practice: incidence, patient, characteristics and management. *Ann Rheum Dis* 1995; 54:959-64.
  15. Luime JJ, Koes BW, Hendriksen IJM. Prevalence and incidence of shoulder pain in the general population, a systematic review. *Scan J Rheum* 2004; 33:73-81.
  16. Neer CS II. Impingement lesions. *Clin Orthop* 1983; 173:70-77.
  17. Bokor DJ, Mawkins RJ, Huckell GH, Angelo RL, Schickendaur MS. Results of non operative management of full-thickness tears of the rotator cuff. *Clin Orthop Relat Res* 1993:103-10.
  18. Blair B, Rokito AS, Cuomo F, Jarolem K, Zuckerman JD. Efficacy of injections of corticosteroids for subacromial impingement syndrome. *J Bone Joint Surg Ann* 1996; 78:1685-9.
  19. Wirth MA, Basamania C, Rockwood CA. Non operative management of full-thickness tears of the rotator cuff. *Orthop Clin North Am* 1997; 28:59-67.
  20. Bartolozzi A, Andreychik D, Ahmad S. Determinants of outcome in the treatment of rotator cuff disease. *Clin Orthop Relat Res* 1994; 308:90-97.
  21. Green S, Buchbinder R, Glazier R, Forbes A. Interventions for shoulder pain (Cochrane Review). In: *Cochrane Library*. Issue 1, Update software, 2004. Philadelphia Panel. *Phys Ther* 2001; 81:1719-30.
  22. Beandreill J, Dhemain M, Condane H, et al. Clinical practice guidelines for the surgical management of rotator cuff tears in adult. *Orthop Traumatol Surg Res* 2010;96:175-179.
  23. Buselli P, Saggini R. Efficacia della terapia con onde d'urto nel trattamento della tendinopatia calcifica della cuffia dei rotatori. *MR Giornale Italiano di Medicina Riabilitativa* 2000; 14(S):552-3.
  24. Saggini R, Iodice P, Cancelli F, Romano V, Di Bonaventura V, Coco V, Bellomo RG. Therapeutic rehabilitative approach in the painful shoulder syndrome with partial tear and calcifying tendinitis of rotator cuff: retrospective analysis. *Europa Medicophysica* 2006; 42:75-78.
  25. Buselli P, Coco V, Notarnicola A, Messina S, Saggini R, Tafuri S, Moretti L, Moretti B. Shock waves in the treatment of post-traumatic myositis ossificans.

- Ultrasound Med Biol 2010; 6:397-409.
26. Saggini R, Figus A, Troccola A, Coco V, Saggini A, Scuderi N. Extracorporeal shock wave therapy for management of chronic ulcers in the lower extremities. *Ultrasound Med Biol* 2008; 34:1261-71.
  27. Saggini R, Cavezza T, Di Pancrazio L, Piscella V, Saladino G, Zuccaro MC, Bellomo RG. Treatment of lesions of the rotator cuff. *J Biol Regul Homeost Agents* 2010; 24(4):453-9.
  28. Saggini R, Cancelli F, Di Bonaventura V, Bellomo R.G, Pezzatini A, Carniel R. Efficacy of two microgravitational protocols to treat chronic low back pain associated with discal lesions: a randomized controller trial. *Eur Med Phys* 2004; 40:311-6.
  29. Rupp S, Seil R, Kohn D. Tendinosis calcarea of the rotator cuff. *Orthopade* 2000; 29:852-67.
  30. Uhthoff HK, Loehr JF. Calcifying tendinitis. In *The Shoulder*. CA Rockwood, FA Matsen, ed. WB Saunders Co. Philadelphia, 1998; p. 989-1008.
  31. Perlick L, Luring C, Bathis H, Perlick C, Kraft C, Diedrich O. Efficacy of extracorporeal shock-wave treatment for calcific tendinitis of the shoulder: experimental and clinical results. *J Orthop Sci* 2003; 8:777-83.
  32. Cosentino R, De Stefano R, Selvi E, Frati E, Manca S, Frediani B, Marcolongo R. Extracorporeal shock wave therapy for chronic calcific tendinitis of the shoulder: single blind study. *Ann Rheum Dis* 2003; 62:248-50.
  33. Rompe JD, Hope C, Kullmer K, Heine J, Burger R. Analgesic effect of extracorporeal shock wave therapy on chronic tennis elbow. *J Bone Joint Surg Br* 1996; 78:233-7.
  34. Cosentino R, Falsetti P, Manca S, et al. Efficacy of extracorporeal shock wave therapy on the treatment of calcaneal enthesophytosis. *Ann Rheum Dis* 2001; 60:1064-7.
  35. Perlick L, Luring C, Bathis H, et al. Efficacy of extracorporeal shock-wave treatment for calcific tendinitis of the shoulder: experimental and clinical results. *J Orthop Sci* 2003; 8:777-83.
  36. Steinbach P, Hofstadter H, Nicolai H, et al. *In vitro* investigations on cellular damage induced by high energy shock wave. *Ultrasound Med Biol* 1992; 18:691-9.
  37. Berta L, Fazzari A, Ficco AM, Maurici Enrica P, Catalano MG, Frairia R. Extracorporeal shock waves enhance normal fibroblast proliferation *in vitro* and activate mRNA expression for TGF- $\beta$ 1 and for collagen types I and III. *Acta Orthopaedica* 2009; 80(5):612-17.
  38. Orhan Z, Ozturan K, Guven A, Cam K. The effect of extracorporeal shock waves on a rat model of injury to tendo Achillis. A histological and biochemical study. *J Bone Joint Surg (Br)* 2004; 86(4):613-8.
  39. Wang L, Qin L, Cheung WH, Yang H, Wong WN, Chan KM, Leung KS. Extracorporeal shock wave therapy in treatment of delayed bone-tendon healing. *Am J Sports Med* 2008; 36(2):340-7.
  40. Rompe JD, Furia J, Weil L, Maffulli N. Shock wave therapy for chronic plantar fasciopathy. *Br Med Bull* 2007; 81-82:183-208.