

CASE REPORT



## Minimally invasive endoscopic treatment of chronic otitis media with facial nerve palsy- A case report and literature review

Dipesh Shakya<sup>a</sup>  and Ajit Nepal<sup>b</sup>

<sup>a</sup>Department of Otorhinolaryngology, Civil Service Hospital, Minbhawan, Nepal; <sup>b</sup>Department of Otorhinolaryngology, School of Medicine, Patan Academy of Health Sciences, Lagankhel, Nepal

### ABSTRACT

Facial nerve palsy is an uncommon yet significant complication of chronic otitis media (COM) which can lead to a permanent cosmetic defect. It is common in cholesteatomatous chronic otitis media. Treatment options include antibiotics, steroids, and surgery. Facial nerve decompression is chiefly performed using a microscope *via* a postaural approach. It requires mastoidectomy and atticotomy to gain access to the anterior epitympanum and anterior end of the tympanic facial nerve. Here, we present a case of a 40-year-old woman with bilateral chronic otitis media presented with sudden onset of Grade V left facial nerve palsy. On examination, the left ear had cholesteatomatous like debris, granulation, and discharge. Total endoscopic transcanal type III tympanoplasty and facial nerve decompression were done. She had full recovery post-surgery. The endoscope avoided the postaural incision, decreased morbidity, and provided faster recovery.

### ARTICLE HISTORY

Received 18 May 2021  
Revised 13 July 2021  
Accepted 23 September 2021

### KEYWORDS

Endoscope; chronic otitis media; facial nerve palsy; minimally invasive

### Introduction

Facial nerve paralysis is one of the uncommon but important complications of chronic otitis media (COM). Its prevalence was reported to be 1%–2.3% in the pre-antibiotic era which has gradually decreased with the introduction of antibiotics; nevertheless, it is still seen in developing nations [1]. If left untreated or not managed on time, the paralysis can cause permanent physical deformity. Facial paralysis impairs facial movement, which results in unappealing deformation of expressions such as smiling. Thus, facial paralysis markedly affects a person's quality of life, social life and can lead to serious psychological damage [2]. Early surgical eradication is the most viable way to overcome paralysis [3]. Surgical interventions include microscopic mastoidectomy *via* postaural approach, canal wall down or up technique, along with facial nerve decompression [1]. Recently endoscope has been introduced in the field of otology that has changed the management of the surgery. Most otologists are accepting endoscopic ear surgery mainly because of the minimally invasive approach [4]. Most articles on endoscopic facial nerve decompression were published for traumatic facial nerve

palsy. We did not find any articles on endoscopic facial nerve decompression for chronic otitis media. Here we present the first case report on the total transcanal endoscopic management of a non-cholesteatomatous COM with facial nerve palsy.

### Case report

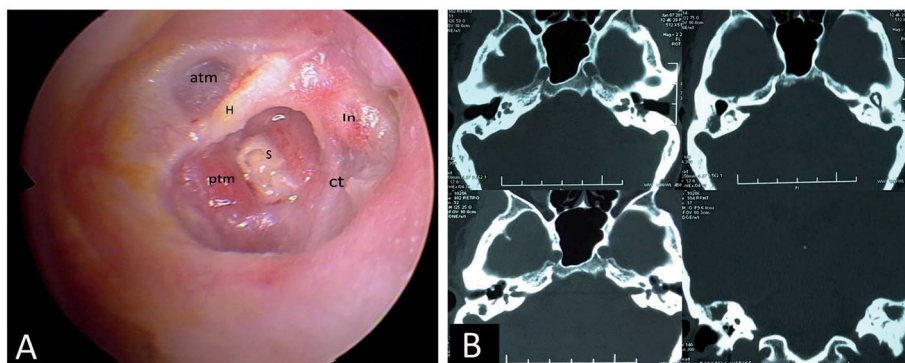
A 40-year-old woman was our regular patient who had history of bilateral ear discharge for more than 10 years. She was diagnosed with bilateral chronic otitis media. She was initially scheduled for right tympanomastoidectomy. As our hospital is a government tertiary hospital with huge patient turnover and a long list of surgeries, she received her surgery date after nine months.

However, she presented to our hospital five months before her scheduled surgery date, complaining of sudden onset of left facial palsy of two days duration along with left ear discharge. She had no history of upper respiratory tract infection, fever, vertigo, or trauma. She had no new complaint regarding the right ear. On examination of the left ear, she had cholesteatomatous like debris, discharge and granulations over posterior tympanic membrane (Figure

**CONTACT** Dipesh Shakya  [dipeshent@yahoo.com](mailto:dipeshent@yahoo.com)  Department of Otorhinolaryngology, Civil Service Hospital, Minbhawan, Nepal

© 2021 The Author(s). Published by Informa UK Limited, trading as Taylor & Francis Group.

This is an Open Access article distributed under the terms of the Creative Commons Attribution License (<http://creativecommons.org/licenses/by/4.0/>), which permits unrestricted use, distribution, and reproduction in any medium, provided the original work is properly cited.



**Figure 1.** A. Preoperative endoscopic evaluation. B. HRCT scan of Temporal Bone- axial and coronal view. Abbreviations: H: Handle of malleus; ptm: posterior tympanic membrane retracted; atm: anterior tympanic membrane healed; s: necrosed stapes; ct: chorda tympani; In: incus with the necrosed long and lenticular process.

1(A)). She had slight asymmetry of the face at rest, incomplete closure of the left eye, and asymmetry of the mouth at maximum effort. The paresis of the facial nerve was classified as House–Brackmann Grade V. Her pure tone audiometry showed moderate conductive hearing loss. CT scan of the temporal bone on the left ear revealed soft tissue density at the tympanic and mastoid cavity, suspected cholesteatoma along with suspicious facial nerve dehiscence at the horizontal part of the facial nerve (Figure 1(B)). However, her previous scan had revealed an intact fallopian canal. The patient was admitted, intravenous antibiotic ceftriaxone 1 gm/day was given along with oral steroid prednisolone 1 mg/kg/day. Due to suspected cholesteatoma in radiological imaging, she underwent immediate surgery.

**Surgical Procedure** (Figures 2 and 3 and video)

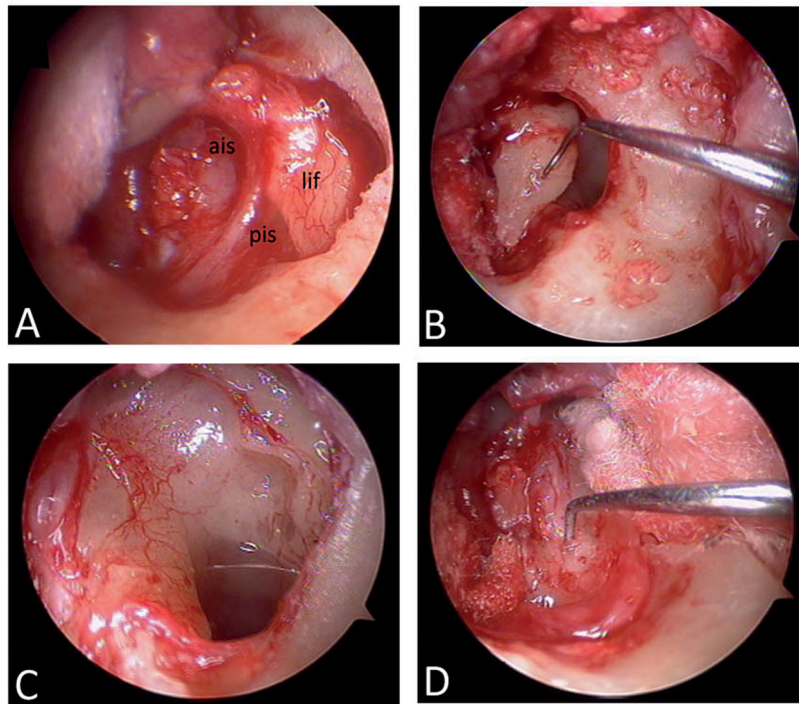
The surgery was performed under hypotensive general anesthesia with a head elevation of 15°–30° to decrease venous congestion *via* an endoscopic approach. Total endoscopic transcanal surgery was performed using 0° and 30°, rigid endoscopes, 4 mm, and 18 cm length. The canal incision was given at 10 and 5 o'clock superiorly and inferiorly, respectively. The tympanomeatal flap was elevated from the posterior canal wall and the annulus. Bone curetting and drilling were done at the attic and posterosuperior canal wall to remove the lateral wall of the scutum to expose the attic and ossicles. The long and lenticular process of incus and part of the malleus handle was necrosed and diseased. Incus was removed. The bony canal wall was further removed postero-superiorly to expose aditus ad antrum, lateral semicircular canal, facial nerve, and antrum. Fluid collected at the antrum was suctioned. The antrum was normal without granulation tissue or cholesteatoma.

Dissection was then carried around the stapes and facial nerve area. Thick edematous mucosa and granulation tissues around the stapes, posterior sinus, promontory, and over the tympanic facial nerve were removed. The tympanic segment of the facial nerve was found to be partially dehiscence. The underlying facial nerve was erythematous and edematous. The fallopian canal was partially decompressed, just 2–3 mm distal and proximal to the defect, without incising epineurium and perineurium, to avoid complications (surgical video). The epitympanum, sinus tympani, retrotympanum, hypotympanum, protympanum, and eustachian tube area were evaluated to rule out disease. The type III reconstruction was done using tragal cartilage and perichondrium. No suture was applied, and the patient was admitted for one week to continue the antibiotic. The facial nerve paresis improved from House–Brackmann Grade V to Grade II. After six months of follow-up, her paresis recovered completely.

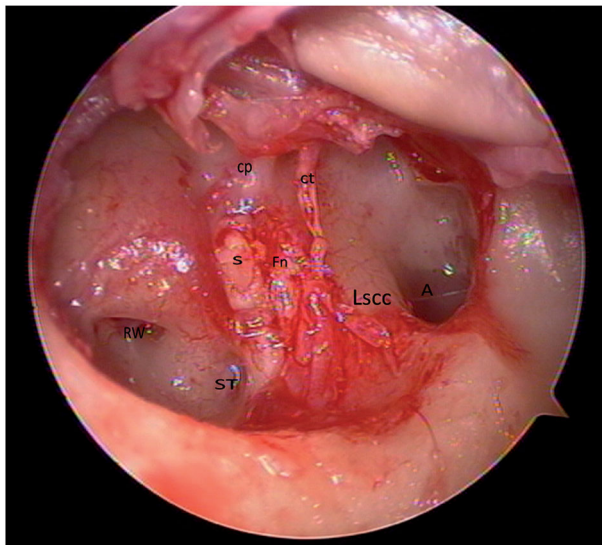
## Discussion

Complications following chronic otitis media are decreasing because of early diagnosis and appropriate interventions [5]. Nevertheless, it is still commonly seen in developing nations [6]. Facial nerve paralysis is one of the complications of chronic otitis media. The frequency of palsy ranges from 0.16%–5.1% [3].

The facial nerve is vulnerable to infection during chronic otitis media. Facial nerve paralysis is more frequently seen in cholesteatomatous COM [7]. Facial nerve paralysis secondary to COM without cholesteatoma is a rare and challenging situation [8]. One of the causes of palsy without cholesteatoma can be due to facial nerve canal dehiscence, with an incidence of



**Figure 2.** A. View after removal of lateral attic wall-with blockage of tympanic isthmus due to edematous mucosal folds. B. Incus removed from fossa incudis C. Normal attic seen via 30 degrees rigid endoscope. D. Decompression of facial nerve. Abbreviations: pis: posterior isthmus; ais: anterior isthmus; lif: lateral incudal fold.



**Figure 3.** Endoscopic wide-angle view. Abbreviations: A: antrum; cp: cochleariform process; ct: chorda tympani; Fn: dehiscent tympanic segment of facial nerve; Lscc: lateral semi-circular canal; ST: sinus tympani; RW: round window.

6.1%–23.8% [9]. However, there was no evidence of dehiscence in our case as the previous scan revealed an intact canal.

The pathogenesis of otogenic facial nerve palsy is still not known. Bone erosion, resorption, osteitis, edema, external compression, inflammation, and

release of neurotoxic substances by infection are the possible causes. These can be reasons in our case as well since we do not know the cause of palsy [1,6,7]. The facial nerve fills 35%–65% of its canal, and the rest with extraneural blood vessels and connective tissue, without leaving any space. Thus, the infection can effortlessly cause edema and affect neural transmission [6].

Most studies reported the tympanic segment of the facial nerve to be the most commonly involved part in facial nerve palsy due to chronic otitis media with or without cholesteatoma [1,6,10]. The tympanic part is the most common site because it is located on the floor of the middle ear, one of the common areas of dehiscence, and has thin bony coverage [5].

Though the recent Cochrane review on the surgical management of Bell's palsy revealed insufficient evidence of surgical intervention, most surgeons regard the management of facial palsy due to COM as urgent or semi-emergent surgery [5,11,12]. The risk of lasting cosmetic deformity seems to be high in patients with palsy due to chronic otitis media. Therefore, delay in treatment increases the risk and poor surgical outcomes [3]. Regarding the concern on decompression surgery, there are no definite guidelines or consensus regarding the treatment of chronic otitis media with facial nerve palsy. The surgical approach and



management depend on the surgeon's preference and expertise as well [13].

Kim et al. [3] performed surgical decompression in 42 patients using the transmastoid and translabyrinthine approach from the geniculate ganglion to the stylomastoid foramen with or without epineural incision. The epineural sheath was opened if the nerve had edema or redness. The authors concluded that early surgical intervention was crucial in the recovery of the facial function especially in the cases of shorter duration, sudden onset, and without cholesteatoma as in our case.

Choi et al. [5] published the surgical management of COM with facial nerve paralysis in 12 patients in which 10 patients (83%) had a complete recovery. They performed limited bony wall decompression around the dehiscence area and incision of the epineural sheath was not done, similar to our procedure. They reported early surgical intervention provided favorable outcomes. Yetisar et al. [6] performed total facial nerve decompression from the geniculate ganglion to the stylomastoid foramen in 24 patients, in which epineural sheath was not incised and had good recovery in 83% of the patients.

The study done by Altuntas et al. [1] had 20 patients with facial nerve palsy due to COM of which 14 patients had fallopian canal defects. In cases with the defect, the defect was widened from both ends to securely remove the pathological tissue from the nerve, similar to our case. In 6 cases without fallopian canal defect, the canal was opened from the geniculate ganglion to the stylomastoid foramen to explore the presence of the granulation tissue on the nerve. They removed epineurium only if it was invaded by the disease and kept perineurium intact that acted as the barrier to prevent infection. They had complete recovery in 75% of the patients and 25% had incomplete recovery. They concluded COM with facial nerve palsy should be treated as semi-emergent.

Savic and Djerić [10] reported surgical decompression on 46 patients with COM and facial paralysis in the 10-years 1973–1982. Facial nerve function recovered completely in 70%, partially in 24% and failure occurred in 6% of the patients. Harker and Pignatari [11] reviewed 6 cases of non-cholesteatomatous COM with facial palsy in which 3 patients underwent decompression and all had recovery. Ikeda et al. [2] performed partial decompression in 16 patients and postoperative facial nerve paralysis improved to Grade I in 11 patients (69%) and Grade II in 2 (13%). Overall, its improvement of 82%. Their surgical procedure is similar to ours which is partial decompression.

Ozbek et al. [8] reported a study on the treatment of 13 patients with facial palsy with non-cholesteatomatous COM over 12 years. Out of 13, 8 patients underwent decompression, 4 patients had total and 4 patients had partial decompression. There was a complete improvement in all of the 4 patients (100%) of partial decompression and a 50% improvement in total decompression. They also compared outcomes of decompression and no decompression and concluded against facial nerve decompression for the non-cholesteatomatous COM. However, the sample size is extremely small for such a conclusion [8].

In our case, we did very minimal decompression just a few 2–3 mm distal and proximal to the dehiscence nerve because there was granulation over it which was removed and the nerve at the dehiscence area was edematous. A similar procedure was also done by Choi et al. [5] and Ikeda et al. [2] with a good recovery rate. We did not perform total decompression nor did we incise epineurium or perineurium which would act like a barrier for infection as described by Yetisar et al. [6].

The two most common surgical approaches as described by Fisch and May in 1972 for facial nerve decompression include the transmastoid approach and the middle fossa craniotomy (MFC). The transmastoid approach has greater access to the tympanic or mastoid segments and can be further subdivided into different approaches, such as the retroauricular or endaural approach. MFC allows good exposure to the labyrinthine segment, geniculate ganglion, and tympanic segment but requires temporal lobe retraction [12]. Surgery dealing with the facial nerve is not exempted without complications. As reported by May and Klein, complications of facial nerve surgery include hearing loss conductive and sensorineural, trauma to the facial nerve itself, tinnitus, labyrinthine injury, dural injury, injury to the middle meningeal artery injury, the sigmoid plate, the superior petrosal vein, the stylomastoid artery, the dura and the brain [14]. Even though there is improvement in the patients undergoing decompression, it is clear that there is always a possible risk of iatrogenic injury to the facial during the surgery [8].

All these surgical procedures were carried out using the microscope and the microscope has been considered the gold standard for otological procedures. The use of an endoscope is rapidly increasing in otological and neuro-otological surgery in the past two decades as an adjunct to or as a replacement for the operative microscope [4]. Most of the endoscopic facial nerve decompression was reported for traumatic

palsy [15]. Marchioni et al. divided the tympanic segment into two segments as pre- and post-cochleariform, which had surgical consequences [16]. Endoscopy provides the advantage in viewing the extreme anterior segment of the tympanic part compared to microscopy in terms of visualization and surgical maneuvering [16].

The transcanal endoscopic approach allows a direct route to the postcochleariform segment of the facial nerve after incus and head of the malleus removal, sparing mastoid tissues, and wide external incisions [16]. In our case, we had to remove incus because it was necrosed and this allowed also us to gain access to aditus ad antrum. Endoscope allowed us to see healthy antrum. Unnecessary mastoid dissection, postaural incisions, and tissue retraction was spared. Minimally invasive surgery could be performed.

Advantages of endoscopic ear surgery are its wide-angle view, visualization around the corners, to see hidden areas as sinus tympani, retrotympanum, pro-tympanum, and eptympanum. It provides high-definition image, and magnification effect by just moving scope close to the objects [4,16]. The setup for endoscopic ear surgery is easy and because we can perform minimally invasive surgery, it becomes cost-effective as well which is ideal for developing nations where COM and its complications are still frequently observed [17]. However, the disadvantage includes single hand surgery and learning curve. Instrumentations in a narrow space can become difficult. Bleeding can be cumbersome to manage. With practice and techniques described in the literature, these difficulties can be overcome [4].

We had no complications during the surgery. Because of deemed potential complications, we perform very limited minimal decompression only. The plan to proceed with surgery using an endoscope proved to be beneficial for the patient. This showed the benefit of primary endoscopic ear surgery over secondary endoscopic ear surgery, also known as endoscopic assisted microscopic ear surgery as explained by Preyer S [18]. The transcanal approach prevented postaural incision and mastoidectomy. It decreased morbidity, surgical duration, and anesthetic exposure.

## Conclusion

Endoscopic ear surgery is an emerging concept in otology which is rapidly gaining acceptance among otologists. We conclude that minimally invasive

surgery, facial nerve decompression, and tympanoplasty can be performed using an endoscope.

## Disclosure statement

The authors declare that there is no conflict of interest regarding the publication of this paper.

## Consent

Informed consent was obtained from the patient.

## ORCID

Dipesh Shakya  <http://orcid.org/0000-0002-9957-0913>

## References

- [1] Altuntas A, Unal A, Aslan A, et al. Facial nerve paralysis in chronic suppurative otitis media: Ankara numune hospital experience. *Auris Nasus Larynx*. 1998;25(2):169–172.
- [2] Ikeda M, Nakazato H, Onoda K, et al. Facial nerve paralysis caused by middle ear cholesteatoma and effects of surgical intervention. *Acta Otolaryngol*. 2006;126:95–100. DOI:10.1080/00016480500265950.
- [3] Kim J, Jung GH, Park SY, et al. Facial nerve paralysis due to chronic otitis media: prognosis in restoration of facial function after surgical intervention. *Yonsei Med J*. 2012;53(3):642–648.
- [4] Shakya D, Arun KC, Nepal A. A comparative study of endoscopic versus microscopic cartilage type I tympanoplasty. *Int Arch Otorhinolaryngol*. 2020; 24(01):e80–e85.
- [5] Choi JW, Park YH. Facial nerve paralysis in patients with chronic ear infections: surgical outcomes and radiologic analysis. *Clin Exp Otorhinolaryngol*. 2015; 8(3):218–223.
- [6] Yetiser S, Tosun F, Kazkayasi M. Facial nerve paralysis due to chronic otitis media. *Otol Neurotol*. 2002;23(4):580–588.
- [7] Hartley C, Saeed SR, Lyons TJ. Non-cholesteatomatous suppurative otitis media: facial nerve palsy in an immunocompromised patient. *J Laryngol Otol*. 1995;109(8):755–758.
- [8] Ozbek C, Somuk T, Çiftçi O, et al. Management of facial nerve paralysis in noncholesteatomatous chronic otitis. 2009. 73–77.
- [9] Nomiya S, Kariya S, Nomiya R, et al. Facial nerve canal dehiscence in chronic otitis media without cholesteatoma. *Eur Arch Otorhinolaryngol*. 2014; 271(3):455–458.
- [10] Savić DL, Djerić DR. Facial paralysis in chronic suppurative otitis media. *Clin Otolaryngol Allied Sci*. 1989;14(6):515–517.
- [11] LA H, Ss P. Facial nerve paralysis secondary to chronic otitis media without cholesteatoma. *Am J Otol*. 1992;13:372–374.

- [12] I M, K M, D W, et al. Surgical interventions for the early management of bell's palsy. *Cochrane Database Syst Rev*. 2021;1:CD007468. DOI:[10.1002/14651858.CD007468.pub4](https://doi.org/10.1002/14651858.CD007468.pub4)
- [13] Sc P, Sh S, AR, et al. Current trends in the management of the complications of chronic otitis media with cholesteatoma. *Curr Opin Otolaryngol Head Neck Surg*. 2013;21:446–454.
- [14] Sr K MM. Facial nerve decompression complications. *Laryngoscope*. 1983;93:299–305.
- [15] Kahinga AA, Han JH, Moon IS. Total transcanal endoscopic facial nerve decompression for traumatic facial nerve palsy. *Yonsei Med J*. 2018;59(3):457–460.
- [16] Marchioni D, Soloperto D, Rubini A, et al. Endoscopic facial nerve surgery. *Otolaryngol Clin North Am*. 2016;49(5):1173–1187.
- [17] Patel N, Mohammadi A, Jufas N. Direct cost comparison of totally endoscopic versus open ear surgery. *J Laryngol Otol*. 2018;132(2):122–128.
- [18] Preyer S. Endoskopische ohrchirurgie – eine weiterentwicklung der modernen ohrchirurgie. *HNO*. 2017;65(S1):29–34.